

## Isolated Clavicular Metastasis in a Patient with Endometrial Adenocarcinoma

Gunjesh Kumar Singh<sup>1</sup>, Jaspreet Kaur<sup>1</sup>, Deepti Sharma<sup>1</sup>, Garima Singh<sup>1\*</sup> and Pragya Singh<sup>2</sup>

<sup>1</sup>Department of Radiation Oncology, VMCC and Safdarjung Hospital, New Delhi

<sup>2</sup>Department of Pathology, VMCC and Safdarjung Hospital, New Delhi

\*Corresponding author: Dr. Garima Singh, MD, Assistant Professor, Radiation Oncology, VMCC and Safdarjung Hospital, New Delhi 110029, Tel: +91-9953480093; E-mail: singh.garima3025@gmail.com

Received date: Oct 08, 2015, Accepted date: Dec 15, 2015, Published date: Dec 17, 2015

Copyright: © 2015 Singh GK, et al. This is an open-access article distributed under the terms of the Creative Commons Attribution License, which permits unrestricted use, distribution, and reproduction in any medium, provided the original author and source are credited.

### Abstract

Endometrial adenocarcinoma metastasizing to bones is rare, and isolated metastasis to clavicle is even more uncommon. We report a case of a 60-year-old woman diagnosed with endometrial adenocarcinoma found to have isolated metastasis to the clavicle during adjuvant radiotherapy. Following radiation therapy to the clavicle, patient was started on injection zoledronic acid. She was then planned for chemotherapy comprising of Paclitaxel and Carboplatin for six cycles. Due to lack of compliance, 5 months after the initial diagnosis, she developed severe dyspnea due to disease progression and expired. We hereby discuss the treatment options as well as review the literature of prior published reports on endometrial adenocarcinoma with bone metastasis.

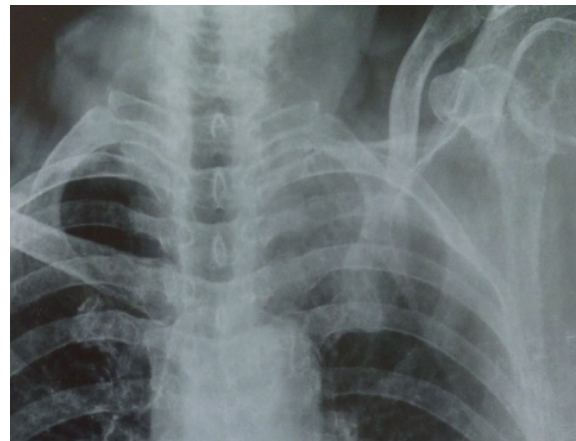**Keywords:** Endometrial cancer; Clavicle metastases; Palliative radiotherapy; FIGO staging

### Introduction

Endometrial carcinoma is the sixth most common cancer among females worldwide following breast, colorectal, lung and cervical cancer [1]. It is fourth most common in developed countries and seventh in ranking in developing countries in the females. About 90% of the uterine carcinomas are adenocarcinoma [2]. Endometrial carcinoma usually extends by local invasion or shows lymphatic spread. Hematogenous dissemination is relatively infrequent. The common sites for distant metastases are lung, liver and brain. Metastasis to bone occurs in less than 15% of the patients with advanced disease and is generally restricted to pelvis and the vertebrae [3]. We report herein a very rare case of endometrial adenocarcinoma (grade 3) with isolated metastasis to clavicle.

### Case Report

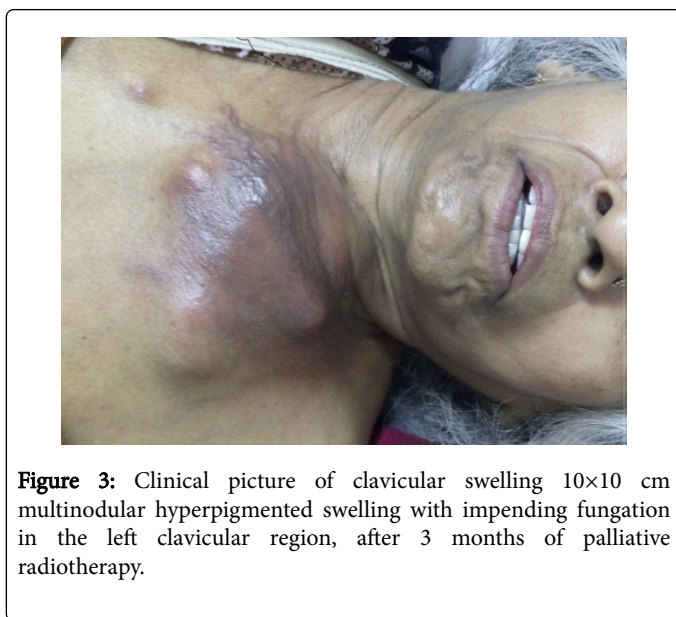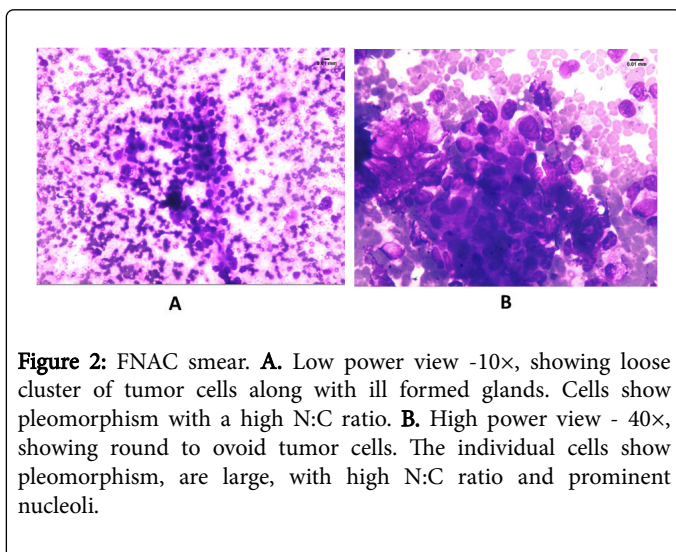
A 60 years old post-menopausal female presented to the gynecology OPD of another hospital with complains of vaginal bleeding and pelvic pain for 6 months. Endometrial biopsy revealed high grade endometrial adenocarcinoma. She underwent surgical staging with radical hysterectomy and bilateral salpingo-oophorectomy for the same 1 year back. Findings were consistent with FIGO stage IIIA grade 3 endometrial adenocarcinoma. She was referred to the outpatient department of our institute for postoperative radiotherapy. Patient was discussed in multidisciplinary clinic and was planned for adjuvant radiotherapy to whole pelvis to a dose of 50 Gy in 25 fractions by 4 field technique followed by Intra Vaginal Brachytherapy after proper consent. During the treatment (after receiving 14 Gy in 7 fractions of pelvic radiotherapy), she started complaining of pain and swelling in the left clavicular region. On local examination, the swelling was about 3×3 cm in size, hard, fixed to underlying structures; tender with normal overlying skin. The swelling was progressively increasing in size. The general physical examination was unremarkable.



**Figure 1:** Chest X-ray PA view showing irregular lytic lesion involving medial half of the clavicle and a soft tissue opacity seen in the left upper zone, extending into the neck. Margins of the opacity could not be well appreciated.

Chest X-ray PA view revealed a lytic lesion in medial one third of left clavicle (Figure 1). Fine Needle Aspiration Cytology (FNAC) from the swelling revealed metastatic adenocarcinoma (Figure 2). On this basis, a complete metastatic workup was done, which showed no evidence of disease elsewhere. The final diagnosis was stage IV B endometrial adenocarcinoma with isolated metastasis to clavicle. The ongoing adjuvant radiotherapy was stopped and the patient was administered palliative radiotherapy of 20 Gy in 5 fractions to clavicle. Zoledronic acid was also administered later on. She was subsequently planned for systemic chemotherapy with Paclitaxel and carboplatin but she defaulted and reported 3 months later with severe breathing difficulty and progression in size of metastatic swelling about 10 × 10 cm in size (Figure 3). In spite of the best supportive care, patient

expired after 5 months of initial diagnosis because of the disease progression.



## Discussion

Endometrial carcinoma is the most common gynaecological cancer accounting for 6% of all new cases of cancer in developed countries (e.g. USA) [1]. In India, the incidence is about 2.3% [2]. The tumor is confined to the uterus itself in 75% of the cases [3]. The incidence of bone metastasis from recurrent endometrial carcinoma is reported to be less than 15% [4]. In an autopsy study by Abdul-Karim et.al., the incidence of bone metastasis was found to be 25-27% [5], which is highest among the reported literatures and the vertebrae were the most common site, only 6/67 cases had known bone metastases while they were alive and all had high grade carcinomas. Among the reported cases, the most common locations of bone metastasis in patients with a high surgical stage and grade are appendicular skeleton.

Several case reports show unusual sites of bony metastases from endometrial carcinoma, such as the calcaneum, humerus, mandible,

talus, metatarsals and skull [6-10]. The survival after bone metastasis was poor in cases of poorly differentiated (grade 3) adenocarcinoma treated with only local palliative radiotherapy to the bone [9,11,12], which is similar in our case.

Ali et al. [10] reported a case with metastatic high grade endometrial adenocarcinoma with bone metastasis, who survived for more than 16 months on multimodality treatment i.e. surgery of bone metastasis, hormone therapy for primary disease and local radiotherapy for metastasis. Dosoretz et al. [7] reported a case of poorly differentiated endometrial adenocarcinoma with isolated mandibular metastasis. After total abdominal hysterectomy and bilateral salpingo-oophorectomy; she was given radiation therapy to the mandible, and chemotherapy consisting of Paclitaxel and Carboplatin for six cycles. She had a complete response and survived for more than 14 months.

To the best of our knowledge, there are only two reported cases of endometrial adenocarcinoma metastasis to clavicle. First case was along with multiple lung metastases and second case with humerus [13,14], with our patient presented with isolated clavicular metastasis.

Our report presented has three main peculiar features:

- Endometrial carcinoma presenting with bony metastasis, which is a rare entity.
- An extremely rare site of metastatic tumor, located in the clavicle.
- The lesion as a single bone metastasis, which is uncommon in such high grade cases.

According to review of literature, the most common treatment for metastasis to the bone is surgical removal of the lesion (if possible), radiation therapy to metastatic site and chemotherapy for a good clinical outcome [14]. Our patient received local radiotherapy to the clavicle, along with zoledronic acid. Bisphosphonate was added as it has been shown to have a modest improvement in skeletal-related event-free survival according to case report by Shigemitsu et al. [14]. Though planned for systemic chemotherapy, the patient did not comply, deteriorated rapidly and expired after about 3 months of initial diagnosis of bone metastasis.

## Conclusion

Rare, metastatic endometrial adenocarcinoma should be considered as a differential diagnosis in patients presenting with abnormal bony swelling and tenderness. Early diagnosis and treatment of such cases is essential as aggressive treatment with multimodality approach leads to prolonged survival [7,10]. For this, a high index of suspicion in these cases is required. Bone scans or conventional X-rays can be used. Palliation of symptoms should be done if combined modality is not possible.

## References

1. Ferlay J, Soerjomataram I, Dikshit R, Eser S, Mathers C, et al. (2015) Cancer incidence and mortality worldwide: sources, methods and major patterns in GLOBOCAN 2012. *Int J Cancer* 136: E359-86.
2. Hoffman BL, Schorge JO, Schaffer JL, Halvorson LM, Bradshaw KD, et al. (2012) Endometrial Cancer. In: *Williams Gynecology*. (2nd edn), McGraw-Hill Companies, Inc., United States.
3. Burke TW, Mundt AJ, Muggia FM (2005) Endometrial Carcinoma. In: *Cancer: Principles and Practice of Oncology*. (7th edn), Lippincott Williams & Wilkins, Philadelphia.

4. Albareda J, Herrera M, Lopez Salva A, Garcia Donas J, Gonzalez R (2008) Sacral metastasis in a patient with endometrial cancer: Case report and review of the literature. *Gynecol Oncol* 111: 583-588.
5. Abdul-Karim FW, Kida M, Wentz WB, Carter JR, Sorensen K, et al. (1990) Bone metastasis from gynaecologic carcinomas: a clinicopathologic study. *Gynecol Oncol* 39: 108-114.
6. Litton GJ, Ward JH, Abbott TM, Williams HJ Jr. (1991) Isolated calcaneal metastasis in a patient with endometrial adenocarcinoma. *Cancer* 67: 1979-1983.
7. Dosoretz DE, Orr DE Jr, Salenius SA, Orr PF (1999) Mandibular metastasis in a patient with endometrial cancer. *Gynecol Oncol* 72: 243-245.
8. Mustafa MS, Al-Nuaim L, Inayat-Ur-Rahman N (2001) Scalp and cranial bone metastasis of endometrial carcinoma: a case report and literature review. *Gynecol Oncol* 81: 105-109.
9. Dursun P, Gultekin M, Basaran M, Aydingöz U, Ayhan A (2003) Bilateral bone metastasis in endometrial adenocarcinoma. *Lancet Oncol* 4: 547.
10. Ali ZA, Wimbhurst JA, Ali AA, Tempest ME, Edwards DJ (2003) Endometrial cancer metastasis presenting as a grossly swollen toe. *Int J Gynecol Cancer* 13: 909-911.
11. Sahinler I, Erkal H, Akyazici E, Atkovar G, Okkan S (2001) Endometrial carcinoma and an unusual presentation of bone metastasis: a case report. *Gynecol Oncol* 82: 216-218.
12. Maxymiw WG, Wood RE (1991) Metastatic endometrial carcinoma to the mandible: a case report. *J Oral Maxillofac Surg* 49: 78-80.
13. Roger FFG, Markus W, Martin K, Sabine BE, German O, et al. (2012) Late lung metastasis of primary endometrial cancer. Two rare cases of patients with late lung metastasis of primary endometrial cancer 14 and 17 years after initial treatment: a case report. *Memo* 5: 262-265.
14. Shigemitsu A, Furukawa N, Koike N, Kobayashi H (2010) Endometrial cancer diagnosed by the presence of bone metastasis and treated with zoledronic acid: a case report and review of the literature. *Case Rep Oncol* 3: 471-476.

This article was originally published in a special issue, entitled: "**Cervical Carcinoma Research**", Edited by S3