

# Invasive Ductal Carcinoma of the Breast Presenting as Small Bowel Obstruction and Ruptured Appendix: A Rare Case Report and Review

Leela S Pillarisetty\*, Subhash Nagalla, Meridyth Buschardt, Sumanth Kumar Bandaru

Department of Health Sciences, Texas Tech University, Permian Basin, Texas, United States

## ABSTRACT

**Introduction:** Metastasis of breast carcinomas to the GI tract are uncommon, and when present is usually of the invasive lobular carcinoma subtype. This case report presents an even more unusual example of invasive ductal carcinoma metastasizing to the GI tract, and with the unusual presentation of a ruptured appendix and Small bowel obstruction.

**Case presentation:** This case report describes a 52-year-old female patient who was diagnosed with metastatic invasive ductal breast carcinoma, which had an extremely unusual presentation of severe abdominal pain, nausea, and vomiting and perforation of the appendix and small bowel obstruction. Although tumors themselves are not an uncommon cause of SBO, metastatic breast cancer is extremely uncommon. Suspicion of breast carcinoma was initially considered after CT scan performed for abdominal pain revealed a previously unknown breast nodule. Subsequent worsening of symptoms, caused by rupture of an appendiceal metastasis, required laparotomy revealed mass of the appendix.

**Conclusion:** This case report and review highlights that it is essential to keep an open mind regarding nonspecific symptoms, and always consider unusual presentations. Early diagnosis from appropriate and timely workup results in better patient outcomes and reduces morbidity and mortality. Invasive Ductal carcinomas of the breast very rarely metastasize to the GI tract, Invasive lobular carcinomas more commonly metastasize to the GI tract whereas invasive Ductal carcinoma metastasizes to lungs and liver. Throughout 23 years reviewing about 8699 appendectomy specimens only about 15 cases of secondary appendiceal tumors were identified.

## INTRODUCTION:

Breast Cancer is the most common cancer among women across the world and is also the leading cause of death from cancer in women [1]. In the United States, breast cancer is the most commonly diagnosed cancer in women and is the second leading cause of death from cancer in women.

Breast cancer diagnosis and treatment is a multidisciplinary approach and involves breast surgeon, medical oncologist, radiation oncologist, social worker, psychiatrist, and it has been proven to be active and reduces mortality and morbidity. Early diagnosis from appropriate and timely workup results in better patient outcomes and reduces morbidity and mortality [2].

Breast cancer is usually suspected in a patient with palpable breast mass with lymphadenopathy and is confirmed by biopsy. Immunohistochemical stains are used to identify the type of breast cancer, and to select appropriate treatment and determine prognosis [3]. Imaging studies like CT scan of the chest, Bone scan and ultrasound of the abdomen may be used to evaluate for metastatic disease.

The usual sites of breast cancer metastasis are lungs, chest wall and liver, very rarely breast cancer metastasizes to the gastrointestinal tract [4]. In this case report, we are presenting a patient with Breast cancer metastasizing to the appendix with perforation and causing small bowel obstruction.

\*Correspondence to: Leela S Pillarisetty, Department of Health Sciences, Texas Tech University, Permian Basin, Texas, United States, E-mail: Drleelasharath@yahoo.com

Received date: January 21, 2020; Accepted date: January 28, 2019; Published date: February 5, 2020

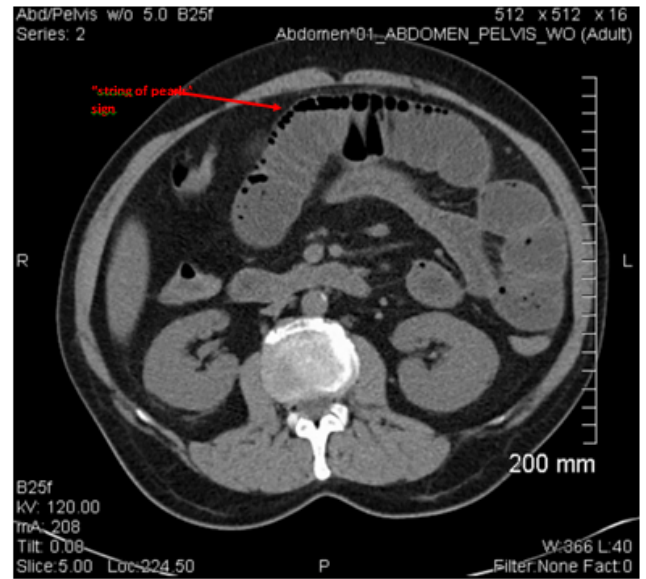
Citation: Pillarisetty LS, Nagalla S, Buschardt M, Bandaru SK (2020) Invasive Ductal carcinoma of the Breast presenting as Small bowel obstruction and Ruptured Appendix: A Rare Case Report and Review Gynecol Obstet (Sunnyvale) 10:518. doi: 10.24015/2161-0932/518

Copyright: © 2020 Pillarisetty LS, et al. This is an open-access article distributed under the terms of the Creative Commons Attribution License, which permits unrestricted use, distribution and reproduction in any medium, provided the original author and source are credited

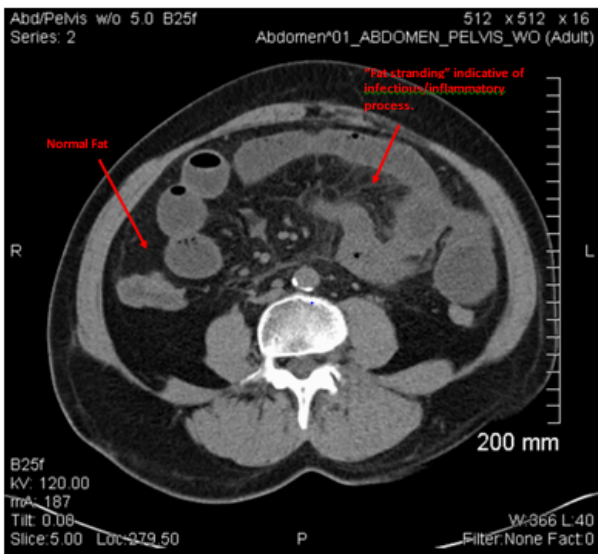
With the advent of novel diagnostic techniques, breast cancer presenting as an acutely ruptured appendix is very rare [5]. Invasive lobular carcinomas more commonly metastasize to the GI tract whereas invasive Ductal carcinoma frequently metastasizes to lungs, bone and liver [4]. The common pathogenesis for this presentation is that the breast cancer metastasizes to the appendix where it tends to obstruct the lumen causing rupture [6].

**CASE REPORT:**

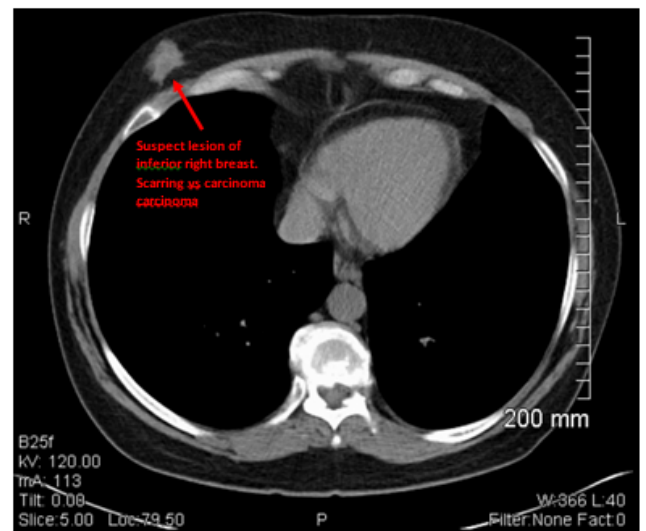
We present here a case of a 52-year-old female patient who was diagnosed with breast cancer metastasizing to the appendix. Her course was complicated by perforation and small bowel obstruction. Initially, she presented to the emergency department with a three-day history of abdominal pain, nausea, vomiting, and fever. Physical exam revealed diffuse abdominal tenderness without rebound tenderness or guarding. Labs showed leukocytosis. CT scan revealed possible partial or early complete small bowel obstruction, secondary to inflammation. A 1.8 × 1.3 cm irregular soft tissue attenuation nodule of the inferior right breast was also identified [Figure 1-4]. Biopsy of the breast lesion offered; however, the patient declined. She decided to wait to follow up until after her GI condition is stabilized.



**Figure 2:** CT Abdomen and Pelvis (series 2 image 36) showed dilation of small bowel (mid and proximal), likely from early complete/partial SBO. “String of Pearls” sign noted in the jejunum indicating increased fluid content in bowel.

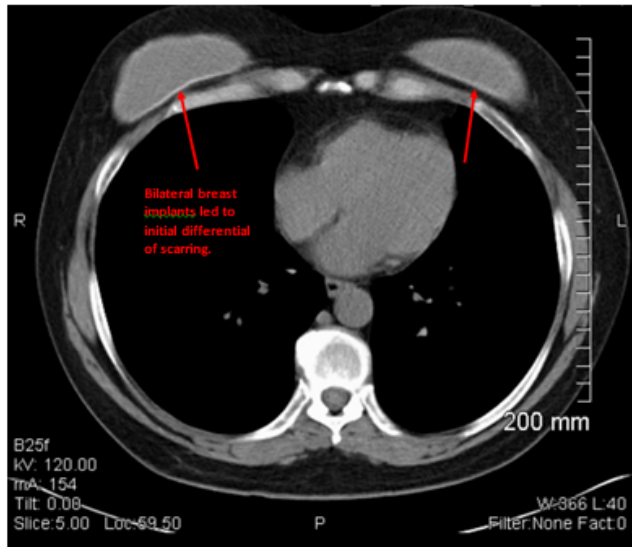


**Figure 1:** CT Abdomen and Pelvis (series 2 image 47) Revealed thickening of the distal portion of small bowel, as well as, stranding. Suggestive of inflammatory/infectious colitis.



**Figure 3:** CT Abdomen and Pelvis w/o Contrast showing an irregular nodule of the inferior aspect of right breast, measuring 1.8 × 1.3 cm (series 2, image 7). Differential scarring vs. carcinoma.





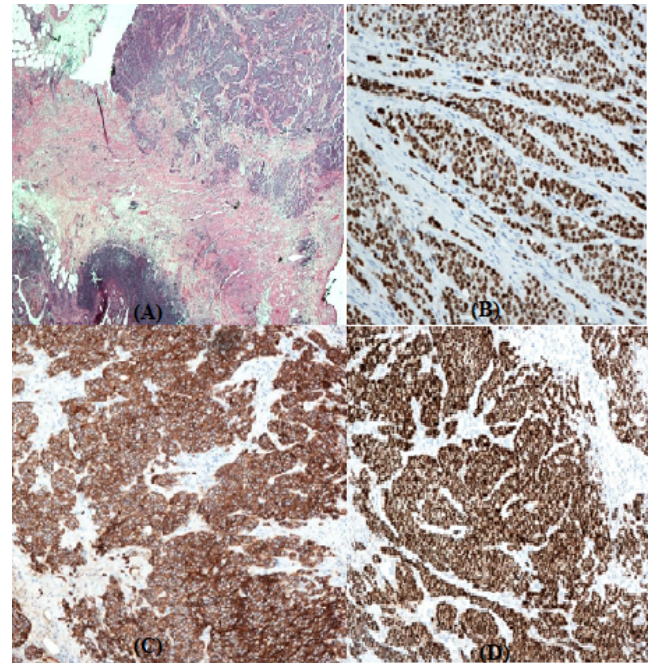
**Figure 4:** CT Abdomen and Pelvis w/o Contrast (Series 2, image 11), showing bilateral breast implants, suspect lesion lay just distal on the right side.

A provisional diagnosis of small bowel obstruction secondary to inflammatory or infectious enteritis with luminal narrowing was made. Conservative management was initially pursued, with an expected resolution of the obstruction with time. Intravenous fluids and antibiotics were started. She was made NPO, and a nasogastric tube was placed. Initial improvement of her leukocytosis and abdominal pain was seen; however, within 24 hours she began to experience worsening abdominal pain, nausea, and vomiting. She underwent emergent laparotomy, which revealed significant inflammation of the distal small bowel loops and an intra-abdominal abscess, sealed off by small bowel loops.

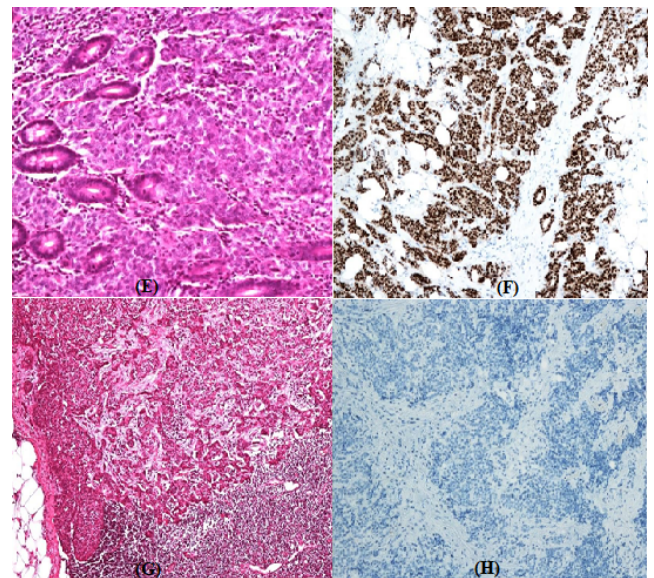
Thorough surgical examination revealed a tumor at the base of the appendix, with associated ischemia and rupture at the tip of the appendix. The appendiceal rupture was determined to be the source of the abscess. The abscess was drained and appendectomy, including a thin rim of the caecum, was performed. A nodule was also found in the iliac mesentery. The appendix specimen and iliac mesenteric nodule were both sent for frozen section.

The preliminary pathology report showed a carcinoid tumor of the appendix, with positive margins. The ileal mesenteric node was also positive for carcinoid tumor. The patient underwent right hemicolectomy and extended small terminal resection. Her postoperative course was uneventful, and she recovered without complications. An oncologist saw the patient in the postoperative period and was discharged to be followed up by the oncologist in the outpatient clinic.

The final pathology report described the appendix and mesenteric nodule specimen as Metastatic ductal carcinoma of the breast, which stained strongly positive for estrogen, progesterone receptors, GATA-3, GCDPF-15 and E-Cadherin (Figure 5A-5H). Four serosal lymph nodes from the right hemicolectomy specimen were also positive for cancer (Figure 5G).



**Figure 5:** (A): Tumor in appendiceal serosa and wall; (B): Gata stain positive; (C): E-Cadherin stain positive and (D): Estrogen receptor positive.



**Figure 5:** (E): Tumor infiltrating appendiceal mucosa; (F): Progesterone receptor positive; (G): lymph node metastasis and (H): Garza S 100 stain negative.

## DISCUSSION

Metastatic tumors to appendix are usually rare. Over 23 years reviewing about 8699 appendectomy specimens only about 15 cases of secondary appendiceal tumors were identified [7]. Breast cancer presenting as ruptured appendix has a poor prognosis and the median survival after a diagnosis of secondary appendiceal tumors was 22.6 months [8,9]. Some studies have also recommended prophylactic appendectomy along with salpingo-oophorectomy in patients with BRCA mutations [10]. Invasive lobular carcinomas more commonly metastasize to the

GI tract whereas invasive Ductal carcinoma frequently metastasizes to lungs, bone and liver [4].

Estrogen receptor (ER) positive tumors usually metastasize to bones whereas ER-negative tumors metastasize to viscera [11]. The main aim of metastatic breast cancer is to improve quality of life. Systemic chemotherapy with endocrine and biologic therapies is the mainstay of treatment.

Selection of treatment depends on hormone status and HER-2 expression. Estrogen and progesterone receptor(ER, PR) positive tumors are treated with endocrine therapy, HER2 positive tumors are treated with trastuzumab, and Chemotherapy is used in Hormone Receptor (HR) negative disease [12]. Endocrine therapy mainly targets to reduce the effect of estrogen on the tumor either by depleting estrogen or by acting on the estrogen receptors. Aromatase inhibitors such as anastrozole and letrozole decrease the production of estrogen. Selective Estrogen Receptor Modulators (SERM) such as Tamoxifen has opposing effects on breast tissue and has an agonistic effect on bone and endometrial tissue [13]. Fulvestrant, a Selective estrogen receptor down Regulator (SERD) downregulates the estrogen receptors, and recent studies have shown it to have superior efficacy over 3rd generation aromatase inhibitors in Hormone receptor-positive metastatic breast cancer[15].CDK 4/6 inhibitors such as pablociclib, ribociclib have shown efficacy and synergy when used with endocrine therapy in ER-positive metastatic breast cancers[14].

The first line of treatment in a postmenopausal patient with De novo metastatic breast cancer is a combination of CDK 4/6 Inhibitor and an aromatase inhibitor [13]. Palbociclib in combination with letrozole has shown longer progression-free survival and Objective response rates when compared with letrozole alone [13,16]. Other combinations such as ribociclib plus letrozole and abemaciclib with letrozole have also shown better efficacy than monotherapy [17,18]. The most common reported adverse effects included Neutropenia, leukopenia, fatigue and Nausea [16-18].

Alternative regimens include fulvestrant alone or in combination with CDK 4/6 Inhibitor and monotherapy with aromatase inhibitors [13,15]. Visceral metastasis of Breast cancer carries a poor prognosis with median survival less than 22 months while Non-Visceral metastasis has a median survival of more than 33 months. Survival is shown to be better in patients with HR-positive tumors when compared to HR-negative tumors. Younger Age at initial diagnosis has a worse prognosis because of aggressive disease [19]. Post Menopause, Lymphovascular invasion is poor independent prognostic factors [20].

## CONCLUSION

Invasive Ductal carcinomas of the breast very rarely metastasize to the GI tract, Invasive lobular carcinomas more commonly metastasize to the GI tract whereas invasive Ductal carcinoma metastasizes to lungs and liver. Over a period of 23 years reviewing about 8699 appendectomy specimens only about 15 cases of secondary appendiceal tumors were identified.

Young age at diagnosis of Breast cancer with visceral metastasis and lymphovascular invasion carries a very poor prognosis. Breast cancer diagnosis and treatment is a multidisciplinary approach and involves breast surgeon, medical oncologist, radiation oncologist, social worker, and a psychiatrist, and it has been proven to be effective and reduces mortality and morbidity. The first line of treatment in a postmenopausal patient with De novo metastatic breast cancer is a combination of CDK 4/6 Inhibitor and an aromatase inhibitor.

## REFERENCES

- Anastasiadi Z, Lianos GD, Ignatiadou E, Harissis HV, Mitsis M. Breast cancer in young women: an overview. *Updates Surg.* 2017; 69:313-317.
- Molina-barea R, Rios-peregrina RM, Slim M, Calandre EP, Hernández-garcía MD, Jimenez-rios JA, et al. Lobular breast cancer metastasis to the colon, the appendix and the gallbladder. *Breast Care Basel.* 2014;9:428-30.
- Zaha DC. Significance of immunohistochemistry in breast cancer. *World J Clin Oncol.* 14;5:382-392.
- Kwan, Edmond & Houli, Nezor & Pitcher, Meron & Wong, Shirley. Appendiceal Metastasis in a Patient with Advanced Breast Cancer on Hormonal Therapy. *Int J Cancer Clin Res.* 2016;3.
- Dirksen JL, Souder MG, Burick AJ. Metastatic Breast Carcinoma Presenting as Perforated Appendicitis. *Breast Care (Basel).* 2010;5:409-410.
- Latchis, Kenneth S. Acute appendicitis secondary to metastatic carcinoma. *Am J Surg.* 1995;111;2:220-223.
- Schmutzer KJ, Bayar M, Zaki AE, Regan JF, Poletti JB. Tumors of the appendix. *Dis Colon Rectum.* 1975;18:324-331.
- Yoon WJ, Yoon YB, Kim YJ, Ryu JK, Kim YT. Secondary appendiceal tumors: a review of 139 cases. *Gut Liver.* 2010;4:351-366.
- JL, Araujo BSM, Cavalcanti MCDV, Soares UW, Sousa GPD, Medeiros. Metastases of breast cancer causing acute appendicitis: A case report. *Cancer Reports and Reviews.*
- Sitzmann JV, Wiebke EA. Risk-reducing appendectomy and the elimination of BRCA1- associated intraperitoneal cancer. *JAMA Surg.* 2013;148:285-291.
- Hess KR, Puztai L, Buzdar AU. *Breast Cancer Res Treat.* 2010;78:105.
- Burstein HJ, Vora SR. Systemic treatment for metastatic breast cancer: General principles. In: *UpTo Date.* Waltham,Mass.:UpToDate. 2019.
- Ma CX, Sparano JA. Treatment approach to metastatic hormone receptor-positive, HER2- negative breast cancer: Endocrine therapy and targeted agents. *UpToDate.* Waltham,Mass.:UpToDate,2019
- Pernas S, Tolaney SM, Winer EP, Goel S. CDK4/6 inhibition in breast cancer: current practice and future directions. *Ther Adv Med Oncol.* 2018;10:1758835918786451.
- Robertson JFR, Bondarenko IM, Trishkina E . Fulvestrant 500 mg versus anastrozole 1 mg for hormone receptor-positive advanced breast cancer (FALCON): an international, randomised, double-blind, phase 3 trial. *Lancet.* 2016;388:2997-3005.
- Finn RS, Martin M, Rugo HS . Palbociclib and Letrozole in Advanced Breast Cancer. *N Engl J Med.* 2016;375:1925-1936.
- Hortobagyi GN, Stemmer SM, Burris HA. Updated results from MONALEESA-2, a phase III trial of first-line ribociclib plus letrozole versus placebo plus letrozole in hormone receptor-positive, HER2-negative advanced breast cancer. *Ann Oncol.* 2018; 29:1541-1547.

18. Goetz MP, Toi M, Campone M . MONARCH 3: Abemaciclib As Initial Therapy for Advanced Breast Cancer. *J Clin Oncol.* 2017;35:3638-3646.
19. Largillier R, Ferrero JM, Doyen J. Prognostic factors in 1,038 women with metastatic breast cancer. *Ann Oncol.* 2008;19:2012-2019.
20. Yücel B, Bahar S, Kaçan T, Şeker MM, Celasun MG, Importance of Metastasis Site in Survival of Patients with Breast Cancer. *Austin J Med Oncol.* 2014;12:7.