

In Vitro Biocompatibility of Silicone Oil Siluron Xtra® on Porcine Retina in a Perfusion Culture System

Katharina L. Neuer*, Sabrina Bohnacker, Nikolaus Feucht, Chris P. Lohmann and Mathias Maier

Klinik und Poliklinik für Augenheilkunde, Klinikum rechts der Isar, Technische Universität München, Munich, Germany

*Corresponding author: Katharina Neuer, Klinik und Poliklinik für Augenheilkunde, Klinikum rechts der Isar, Technische Universität München, Munich, Germany, Tel: +49 89/4140-2320; E-mail: katharina.neuer@gmail.com

Received date: April 23, 2017; Accepted date: September 04, 2017; Published date: September 07, 2017

Copyright: © 2016 Neuer KL, et al. This is an open-access article distributed under the terms of the Creative Commons Attribution License, which permits unrestricted use, distribution, and reproduction in any medium, provided the original author and source are credited.

Abstract

Purpose: To examine the biocompatibility of Siluron Xtra® (Fluoron, Ulm, Germany), a silicone oil used as a vitreous substitute in vitreo-retinal surgery on porcine retinal tissue *in vitro*.

Methods: Retinal tissue of 37 porcine eyes was immediately prepared post mortem and placed into Minucell perfusion systems (Minucell, Bad Abbach, Germany) to be perfused with liquid culture medium over a period of 4-8 days. 23 retinal tissue samples including retinal pigment epithelium (RPE) were covered by silicone oil (group 1) during the perfusion and compared to a control group of 7 samples (group 2) without silicone oil. Group 3 included 7 single RPE tissues without retinal tissue layer in direct contact with silicone oil, thus imitating a retinal tear, during the perfusion.

The morphology of the retina and RPE was examined by light microscopy and stained with immunohistochemical markers to determine Müller cell damage in the retina with Glial fibrillary acidic protein (GFAP) and proliferation in the RPE with Ki67.

Results: Ki67 staining showed significantly less proliferation in the tissue covered by silicone oil (group 1) compared to the control samples in group 2 ($p=0.001$). Direct contact of silicone oil and RPE (group 3) showed no significant increase in proliferation compared to the controls ($p=1$). GFAP staining also did not show any significant Müller cell damage related to Siluron Xtra® ($p=0.9$).

No structural changes in the retinal tissue were observed related to silicone oil by HE staining.

Conclusion: The results of our *in vitro* examination verified good structural biocompatibility of silicone oil (Siluron Xtra®) on porcine retina and RPE *in vitro*. Furthermore, silicone oil may exert a protective layer preventing proliferation on retinal tissue. Further examination of other silicone oils and alternative vitreous substitutes, such as gas and water are necessary to determine the protective advantage of Siluron Xtra® on retinal tissue proliferation.

Keywords: Retina; Silicone oil; Retinal pigment; Ki67; Minucell

Introduction

Following their invention in the 60 ties by Paul A.Cibis, silicone oils have been used routinely as a substitute to replace vitreous humour post vitrectomy surgery [1,2]. While most commonly gas is used as an endotamponade during standard vitrectomy surgery, silicone oils have shown good post-operative results in the treatment of persistent macular holes [3] and especially in more complicated procedures such as giant retinal tear [4] and patients with retinal detachment due to proliferative diabetic retinopathy [5] and proliferative vitreopathy [6]. Usually, air or expanding gases are used as an endotamponade for macular holes in vitrectomy surgery [7-9].

Porcine retina is often used as a model for *in vivo* and *in vitro* experimentation because of its similar micro and macroscopic features to the human retina. Previous studies have used porcine eyes to test new endotamponades [10] and autologous RPE-Choroid grafts [11] that had not been approved for use in humans.

This *in vitro* examination was dedicated to examine the biocompatibility of the silicone oil Siluron Xtra® (Fluoron, Ulm, Germany) on porcine retina. To current date, the interaction of porcine retinal tissue and silicone oil has never before been examined histologically in an *in vitro* experiment although clinical use of silicone oil has shown good long term results in patients [12]. Purpose of the examination was to verify positive results shown in patients undergoing vitrectomy surgery using silicone oil tamponades with objective histological findings.

The perfusion system used in our investigation (Minucells and Minutissue, Bad Abbach, Germany) has previously been used for various organ cultures, including embryonic retinal epithelial cells [13,14], RPE [15] and tissue cultivation [16]. The pump driven system enables a continuous supply of nutritious culture medium and oxygen to the specimens whilst simultaneously deporting waste materials and carbon dioxide out of the perfusion chambers. Hereby imitating the *in vivo* blood supply to the retinal tissue. Previous work has shown good preservation of porcine retina and RPE using this *in vitro* perfusion model before [17].

Immunohistochemical markers GFAP and Ki67 were used to identify destruction in muller cells and retinal proliferation in retinal tissue.

Glial fibrillary acidic protein (GFAP) is a protein that is expressed in the central nervous system as well as in healthy ganglion cells of the retina. The protein has shown to play a vital part during repair mechanisms in the central nervous system [18]. Increased vitreous GFAP expression has also recently been observed in correlation to retinal gliosis [19]. Healthy retinal tissue does not express GFAP in its muller cells tissue layer. Thus a correlation is suggested between GFAP expression and damaged muller cell tissue in the retina [20,21].

The Ki-67 protein is an antigen expressed in proliferating cells [22] during all active phases of replication (G1, S, G2 and mitosis) and thus is suitable as a marker to detect proliferation in the retinal tissue [23].

Material and Methods

Tissue preparation

Fresh porcine eyes were collected from a local abattoir and transported to our laboratory suspended in 0.9% NaCl solution. Assisted by a surgical microscope (Zeiss Universal S3, Jena, Germany) the globes were dissected under sterile conditions within 1 h post mortem.

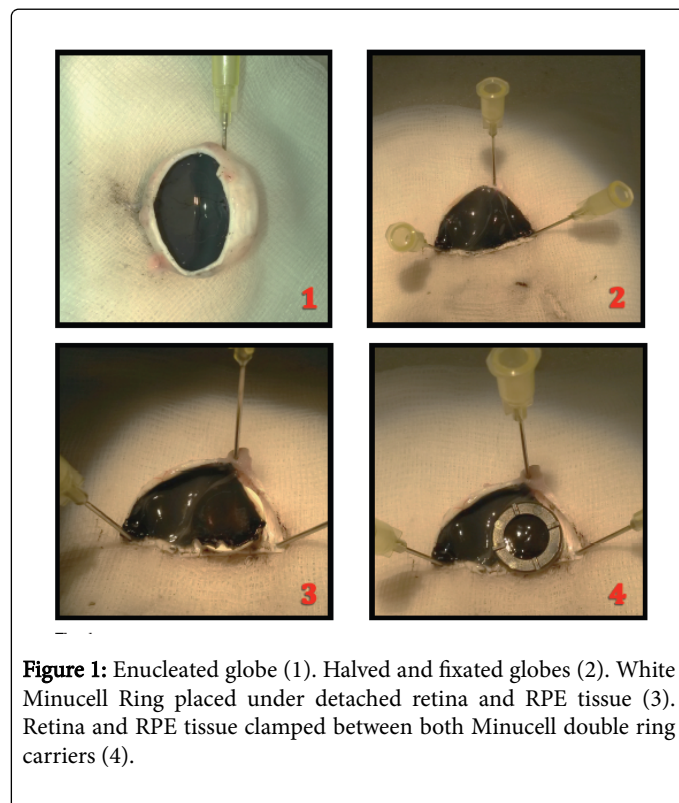


Figure 1: Enucleated globe (1). Halved and fixated globes (2). White Minucell Ring placed under detached retina and RPE tissue (3). Retina and RPE tissue clamped between both Minucell double ring carriers (4).

After removal of remaining muscle tissue, the anterior section, including cornea, iris, lens and vitreous, was removed by a circular incision into the pars plana region (Figure 1.1). The empty globes were carefully halved and the larger half pinned down through the sclera onto a styrofoam surface for fixation (Figure 1.2). Using a forceps and a

microsurgical knife, the retinal tissue including RPE was slowly separated from the sclera without rupturing the fragile tissue with the sharp instruments. Both tissues were clamped between a double ring tissue carrier with an outer diameter of 13 mm and an inner diameter of 9 mm (Minucells and Minutissue, Bad Abbach, Germany). The retinal tissue and RPE were carefully lifted off the sclera and placed onto the smaller white ring, covering the inner hole completely (Figure 1.3). The slightly larger black ring was placed on top and firmly pressed downward to enclose the tissue inside the double ring carriers (Figure 1.4).

Perfusion culture

The tissue carriers were placed into double compartmented perfusion containers by Minucell containing 3 consecutive spaces per compartment with the retinal tissue facing upwards.

Each compartment was connected to two gas-permeable silicone tubes with a 1 mm inner diameter supplying the chambers with medium from a sterile supply of Dulbecco's modified Eagle's medium (DMEM, Sigma-Aldrich, Seelze, Germany), supplemented with 15% porcine serum, 2.5% HEPES buffer solution and 1% penicillin/streptomycin (Gibco Life Technologies, Eggenstein, Germany). Two additional silicone tubes for each compartment transferred the consumed medium out of the containers and into empty bottles.

The culture medium was kept cool using ice packets and pumped through the silicone tubes and into the perfusion containers at a speed of 1 ml/h using a peristaltic pump (IPC N8, Ismatec, Wertheim, Germany).

The containers were kept on a warming plate (Medax, Kiel, Germany) at a constant temperature of 37°C. The retinal tissues enclosed in the sealed chambers were perfused for 24 h over a period of 4-7 days, in a room kept under a physiological light/dark rhythm. The perfusion system was checked 3 times per day to ensure a steady flow of medium running through the perfusion chambers.

Overall 37 specimens were randomly selected into 3 different groups (Table 1). 23 retinal tissues attached to RPE were coated with a drop of silicone oil Siluron Xtra® in group 1. 7 control samples (group 2) were perfused without silicone oil. An additional set of 7 specimens containing only RPE tissue was also coated with silicone oil during the perfusion (group 3). Thus imitating a retinal tear situation in which RPE would be in direct contact with silicone oil (Figures 2 and 3).

Histology

Following the perfusion the tissue samples were carefully removed from the double ring carriers and fixed with paraformaldehyde 4% in phosphate buffered saline (PBS, Sigma-Aldrich) over night. The samples were washed in PBS 0.1 M, dehydrated in ascending alcohol and embedded in paraffin. Xylol was used for deparaffinisation and rehydration.

Finally, the embedded tissues were cut into 2-5 µm slices and placed onto slides (Superfrost Plus, Menzel, Braunschweig, Germany). A sample of each specimen was stained with haematoxylin-eosin and examined using a light microscope (Axiotech, Zeiss). The visible results at a 10X, 20X and 40X magnifications were documented by digital camera (Canon, Tokio Japan) and transferred to the computer.




Figure 2: Minucell perfusion system. From right to left: Bottles containing fresh medium, cooled on ice; electrical pump; Minucell chambers containing specimens, placed on heating place; empty collecting bottles for used up medium.




Figure 3: Open perfusion chambers containing double carrier rings with retinal tissue. Silicone oil still visible on retinal tissue post perfusion (arrow).

Test group	Porkine tissue	Siluron Xtra®	No. of specimens
1	Retina+RPE	yes	23
2	Retina+RPE	no	7
3	RPE	yes	7

Table 1: Arrangement of test groups.

Immunohistochemistry

All samples were stained using GFAP and Ki-67 markers. Immunohistochemical markers GFAP and Ki-67 were used to examine muller cell damage and proliferation within the specimens further. Therefore the paraffin embedded samples were de-paraffinised and rehydrated. Incubation in H₂O₂ 3% was used to disable endogenous

peroxide in the tissue section. The samples were then incubated by specific primary and secondary antibodies and horseradish peroxidase conjugation (HRP) consecutively. Chromogen solution (AEC) was added to the specimens in the final step, causing an enzymatic reaction with peroxide. AEC caused visible red colored staining at primary antibody binding sites as can be seen in Figures 4 and 5.

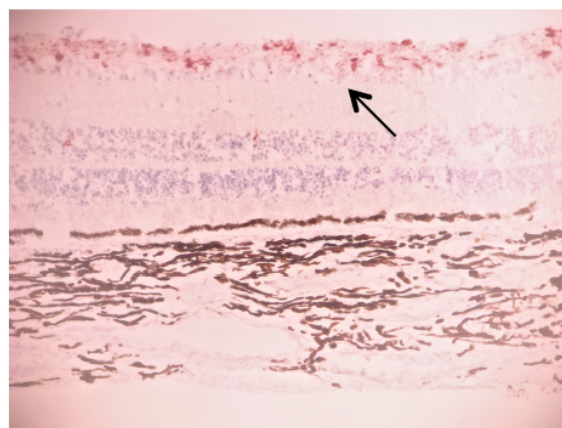
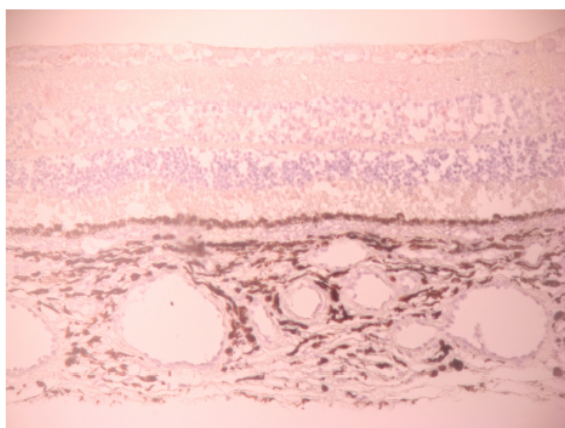


Figure 4: GFAP negative muller cells vs. GFAP positive muller cells. 10X magnification of retinal tissue. Arrow showing presence of GFAP in muller cell tissue, stained in red.

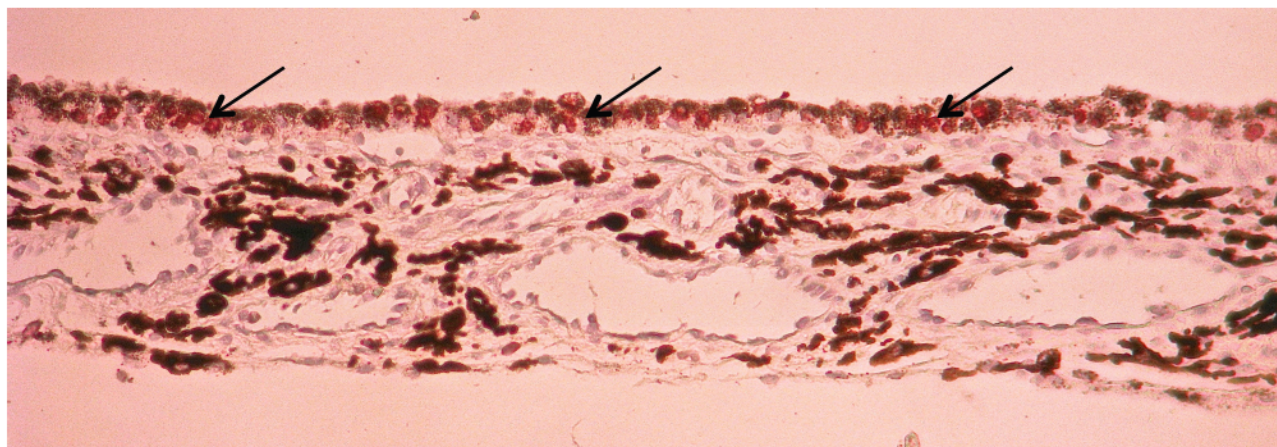


Figure 5: 20X enlargement of RPE tissue taken from group 3. Arrows showing enhanced sites of proliferation in RPE, stained in red, post Siluron Xtra exposure.

Statistical analyses

SPSS® version 22.0 for Windows (IBM Corporation, Armonk, NY, USA) was used for statistical analyses. The non-parametric Mann-Whitney U Test was used to determine the correlation between positive GFAP stained muller cells and silicone oil coverage. Mann-

Whitney U Test was also used to compare the number of proliferative sites visible through Ki67 staining and silicone oil coverage. P values of less than 0.05 were considered statistically significant. The results of the statistical analysis can be seen in Table 2 for GFAP and Table 3 for Ki67.

Ranks				
GFAP	Group	H	Mean Rank	Sum of Ranks
	Group 1	18	12,08	217,50
	Group 2	5	11,70	58,50
	Total	23		
Test Statistics	GFAP			
Mann-Whitney-U-Test	43,500			
Wilcoxon-W	58,500			
U	-0.170			
Asymp. Sig. (2-tailed)	.865			
Exact Sig. (2*(1-tailed Sig.))	.914b			
^a Grouping Variable: Group ^b Not corrected for ties.				

Ranks				
Ki67	Group	H	Mean Rank	Sum of ranks
	Group 2	7	7,50	52,50
	Group 3	7	7,50	52,50
	Total	14		
Test statistics	Ki67			
Mann-Whitney-U-Test	24,500			
Wilcoxon-W	52,500			
U	0,000			
Asymp. Sig. (2-tailed)	1,000			
Exact Sig. (2*(1-tailed Sig.))	1,000b			
^a Grouping Variable: Group ^b Not corrected for ties.				

Table 2: Muller cell damage expressed in immunohistochemical staining with GFAP. Analysis of statistical significance of GFAP staining, comparing group 1 and group 2, using the Mann-Whitney U-Test.

Table 3: Proliferation expressed in immunohistochemical staining with Ki67. Analysis of statistical significance of Ki67 staining, comparing group 1 and group 2, using the Mann-Whitney U-Test.

Ranks				
Ki67	Group	H	Mean Rank	Sum of Ranks
	Group 1	23	12.85	295.5
	Group 2	7	24.21	169.5
	Total	30		
Test statistics	Ki67			
Mann-Whitney-U-Test	19,500			
Wilcoxon-W	295,500			
U	-3,309			
Asymp. Sig. (2-tailed)	0.001			
Exact Sig. (2*(1-tailed Sig.))	0.001b			
^a Grouping Variable: Group ^b Not corrected for ties				
Analysis of statistical significance of Ki67 staining, comparing group 2 and group 3, using the Mann-Whitney U-Test.				

Results

Tissue preparation and perfusion

The perfusion was tolerated well by all 38 specimens, showing no visible damage to the tissues upon removal from the perfusion chambers after duration of 4-8 days. Silicone oil was visible on all specimens, thus ensuring total silicone oil coverage of the samples throughout the entire perfusion. 8 retinal tissues in group 1 and 2 were irreparably damaged during the preparation of the paraffin cuts post perfusion. However, all RPE samples stayed intact and could be used for further evaluation.

Structural evaluation in HE staining

All test groups showed intact structure of retinal and RPE tissue in HE staining at 10X, 20X and 40X magnification using a light microscope. There was no silicone oil imprinting visible in any of the samples. Figure 6 pictures the intact retinal structures within all retinal layers in HE staining of a sample taken from group 1 post perfusion.

Immunohistochemistry

GFAP was used to identify damage in muller cells. Only the samples containing retinal tissue could be used, as muller cells are only found in the retinal tissue. Therefore, group 3 was excluded from GFAP staining and evaluation. Damage to the muller cells was unspecific to silicone oil perfusion with 71% of the specimens in the silicone oil coated group showing positive muller cell staining versus 80% in the control group respectively (p=0.9). The results of the GFAP staining are pictured in Figure 7 showing that there was no correlation between GFAP expression and silicone oil coverage of retinal tissue.

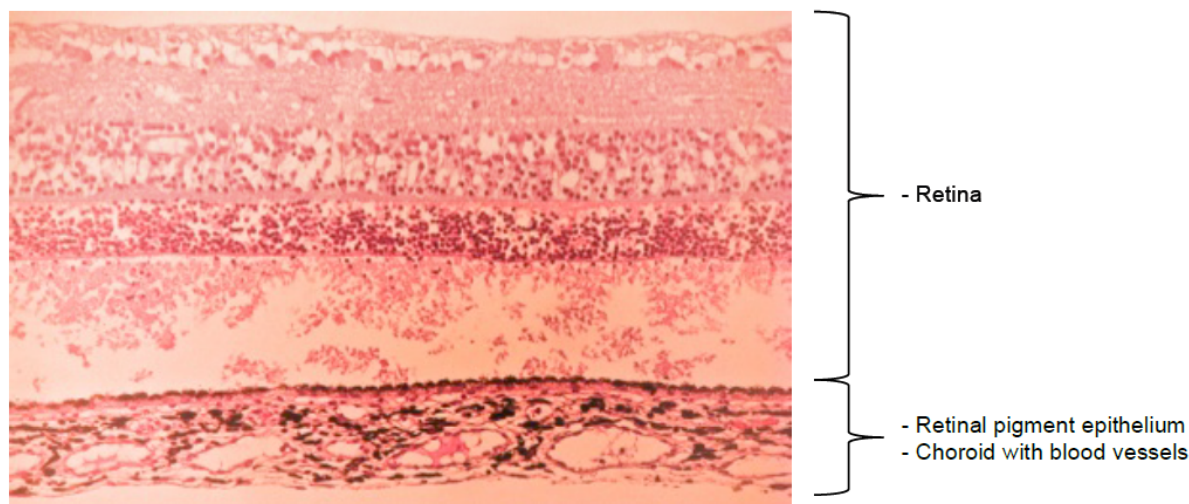


Figure 6: 40X magnification of retina and RPE tissue taken from the test group in HE staining. Showing intact retina and RPE tissue post perfusion with Siluron Xtra®.

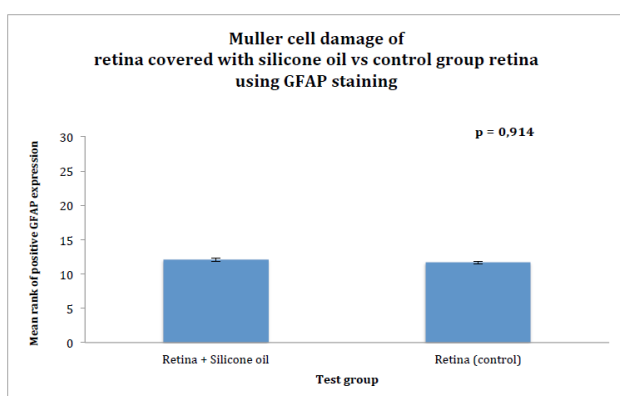


Figure 7: Insignificant GFAP expression in retina perfused with silicone oil and retina without silicone oil coverage.

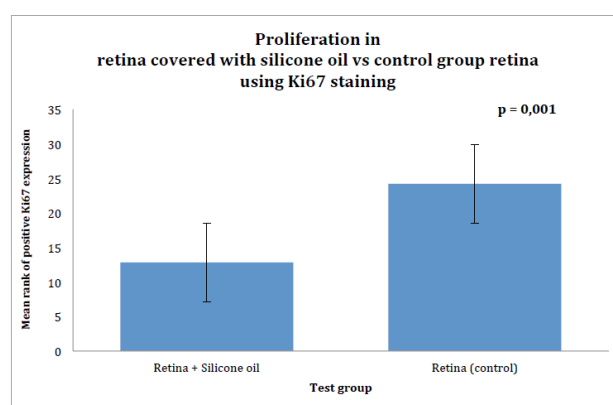


Figure 8: Significant Ki67 expression in retina perfused with silicone oil and retina without silicone oil coverage post perfusion.

Ki67 was used as a marker for proliferation. All samples were photographed in 20X magnification and the number of proliferation sites was counted on the computer using a grid of evenly distributed quadrants. Overall only 33% of the retinal samples coated with silicone oil showed positive Ki67 staining at all, whereas the control groups without silicone oil coverage showed significantly higher proliferation with Ki67 staining in 87% of the samples ($p=0.001$). Figure 8 pictures the significantly lower expression of Ki67 in retinal tissue covered by silicone oil during the perfusion.

RPE in direct contact with silicone oil showed 87% proliferation as well ($p=0.9$). Figure 9 pictures that the expression of Ki67 in RPE covered by silicone oil is equal to the expression of Ki67 in retina

covered by silicone oil.

The length of post mortem time, caused by transport and preparation of the specimens, the number of days of perfusion and relative oxygen and nutrient supply, depending on the position of specimens in the perfusion chambers were recorded for each specimen. However, none of the variants showed significant correlation to the tissue damage evaluated with GFAP and Ki67 immunohistochemistry.

GFAP enhancement, confirming structural tissue impairment could be identified in both groups 1 and 2 and could not be correlated to contact with silicone oil.

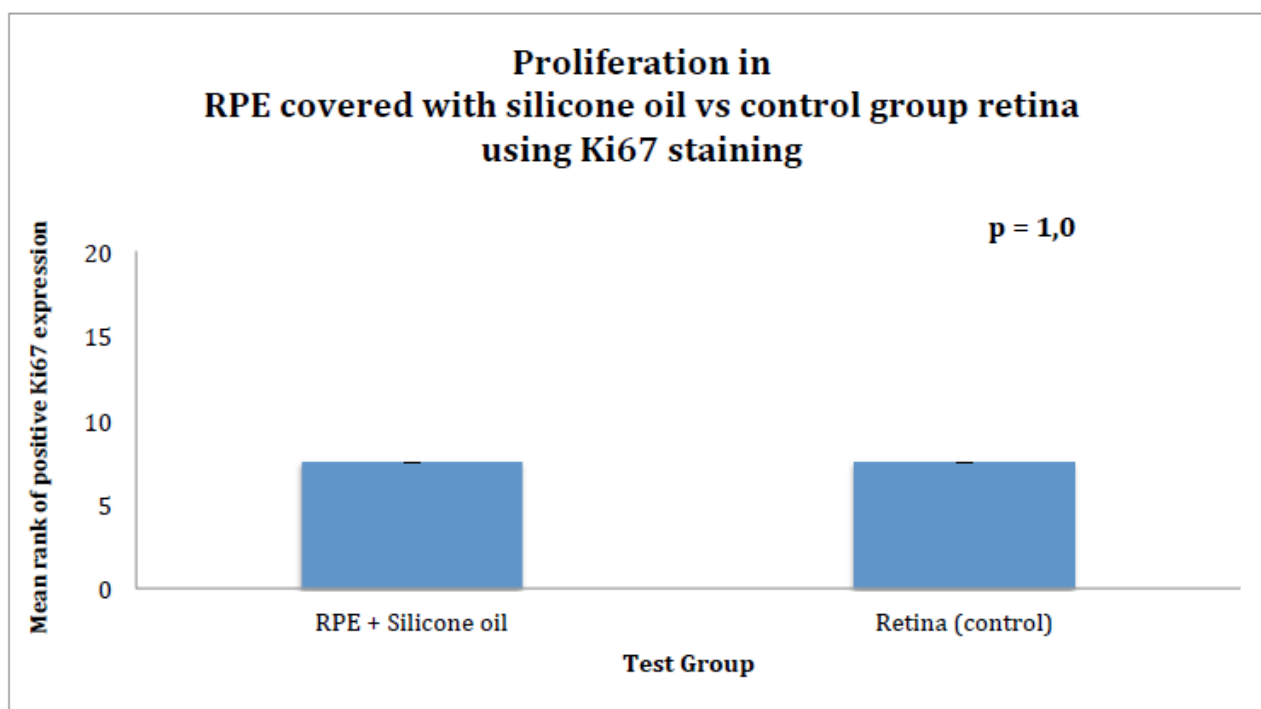


Figure 9: Insignificant Ki67 expression in RPE perfused with silicone oil and retina without silicone oil coverage post perfusion.

Air bubbles in the perfusion chamber

Occasionally air bubbles occurred in the silicone tubes and travelled into the chambers, compressing the tissue samples and restricting medium supply to the specimens. Most of the bubbles appeared only temporarily and eventually dissolved on their own accord. However, in 4 of the overall 37 samples that were perfused it was not possible to get rid of larger air bubbles. Nonetheless, there seemed to be no impairment to the specimens that were tamponaded by air bubbles for a period of time extending up to 48 h during the perfusion.

Discussion

Clinical results of silicone oil endotamponades in pars plana vitrectomy

Silicone oils have been used as ocular endotamponades in ophthalmological surgery since their introduction in the 60 ties by Paul A. Cibis [1,2].

As verified in previous studies, the use of silicone oil has been successfully applied in the treatment of difficult retinal detachment, showing good anatomical results, improved vision and reduced metamorphopsia in patients [3,5,6].

In the post-surgical stage it has been shown that there are reversible effects to the biomechanics of the anterior chamber associated with silicone oil. These may result in an increase of anterior chamber depth and thickening of the central cornea. Although, these effects are most likely linked to the fact that silicone oil injected eyes are more

complicated cases in the first place, the surgery itself or changes in intraocular pressure [24,25].

In 2014 Caramoy, A. et al. published a study comparing retinal tissue in healthy and silicone oil tamponaded eyes. Using SD-OCT (spectral domain optical coherence imaging) and ImageJ software they determined thinning of the inner retinal layers, especially affecting ganglion cells and inner plexiform layer, that were associated with silicone oil use [26].

Whilst silicone oils have never before been tested on porcine models in an *in vitro* perfusion system, *in vivo* injection of silicone oils in rabbits post pars plana vitrectomy has been performed in current literature. ELISA and immunohistochemical staining of hypoxia inducing factor-1-alpha (HIF-1 α) and growth factor VEGF (vascular endothelial growth factor) did not show any pathological vascular or hypoxic signs in the retina [26]. In addition no retinal toxicity has been detected in silicone oil tamponaded eyes in past clinical studies [27].

However, unlike gaseous and air filled endotamponades, silicone oil needs to be removed from the patients eye within several months in a second surgical procedure. This is necessary to avoid silicone oil emulsification and toxic effects on the retina [28-30]. Although showing good anatomical results, the removal of silicone oil has been associated with several complications including cataracts in phakic eyes, keratopathy, hypotonia and most frequently, re-detachment of the retina [28,31].

Proliferation

Significantly less proliferation was observed, using Ki67 immunohistochemistry, in the specimens coated with silicone oil. This

indicated that silicone oil may exhibit protective, anti-proliferative effect on the retinal tissue. Silicone oil coating of the RPE did not reduce proliferation in the RPE compared to the control group that was protected by retinal tissue; however, no evidence of increased proliferation in the RPE related to silicon oil could be determined either. This makes silicone oil a very tolerable agent in the treatment of retinal holes, where tamponade oil can leak through the retinal fissure and onto the RPE. In 1992 Heidenkummer et al. investigated proliferative activity in epiretinal membranes using Ki67 too. Here, highly proliferative activities were observed in 6 of 11 recurrent membranes after intraocular silicone oil tamponade [32].

In the same year, Shikishima et al. investigated the effects of intravitreally injected silicone oil in rabbit retina and detected silicone oil in the inner retinal layer and in phagocytes in the vitreous cavity as well as prominent subretinal and epiretinal proliferation with abundant phagocytes containing silicone oil particles. They hereby suggested that silicone oil may be the cause of excessive subretinal and epiretinal proliferation [33].

Both studies contradict our current findings that have in fact shown decreased proliferation in porcine retina post silicone oil exposure.

Muller cell affection/GFAP expression

GFAP enhancement in the muller cells could not be correlated to silicon oil, suggesting that it must have been caused by other factors. A previous study examining healthy, grown up, human eyes embedded in 2% PFA (paraformaldehyde) determined that GFAP expression is not correlated to the time of preservation in PFA. 4% PFA was used as an agent to fixate our specimens. The study showed that GFAP enhancement significantly rose with prolonged post mortem time exceeding 30 h [34].

Post mortem decay during transportation from the abattoir to the lab and preparation of the tissue before the perfusion with culture medium varied between 1-4 h in our examination but may have contributed to the enhanced GFAP expression in our specimens.

Although it was impossible to identify structural damage associated to post mortem decay using light microscopy, this does not rule out retinal damage on an ultramicroscopic level.

Air bubbles in the perfusion

The air bubbles that occurred in our perfusion system during the experiment did not have an effect on the specimens. In fact, air is successfully being used clinically on patients as an intravitreal tamponade after retinal detachment [35] and pars plana vitrectomy and has shown an increased closure rate of macular holes [36]. Some findings have considered air to be equally effective as a intravitreal tamponade whilst even reducing complications compared to the most commonly used gas tamponade [7,37].

Post-operative findings have shown that air bubbles in the human eye tend to dissolve within 7-10 days [35] showing no clinical damage whereas none of our air bubbles even lasted for more than 48 h.

Both air and silicone oil have shown good properties as an intravitreal tamponade for retinal detachment in previous studies [35,36].

In terms of our examination we can conclude that for a period of 48 h porcine retina can survive without showing signs of structural damage if tamponaded by air.

Conclusion

In conclusion, silicone oil Siluron Xtra® has shown good histological biocompatibility for porcine retina and retinal pigment epithelium. In fact, protective features, decreasing proliferation in retinal tissue could potentially be linked to Siluron Xtra®.

Siluron Xtra® has also shown good biocompatibility towards retinal pigment epithelium. In case of post-operative retinal tear or insufficient closure of retinal tear, this suggests that silicone oil does not exhibit damaging effects on retinal tissue.

The question which arises in this context is whether the antiproliferative properties of silicone oils are possibly superior to other retinal tamponades such as water or gas. Thus, further investigation of the biocompatibility of other silicone oils and alternative retinal tamponades is of interest, to determine a significant protective advantage of Siluron Xtra® and other silicone oils on retinal tissue.

References

1. Petersen J (1987) The physical and surgical aspects of silicone oil in the vitreous cavity. *Graefes Arch Clin Exp Ophthalmol* 225: 452-456.
2. Feibel RM, Blodi CF (2013) Paul A. Cibis, MD: a pioneer of modern vitreoretinal surgery. *JAMA Ophthalmol* 131: 1077-1082.
3. Ivanovska-Adjevska B, Boskurt S, Semiz F, Yuzer H, Dimovska-Jordanova V (2012) Treatment of idiopathic macular hole with silicone oil tamponade. *Clin ophthalmol* 6: 1449-1454.
4. Dabour SA (2014) The outcome of surgical management for giant retinal tear more than 180°. *BMC Ophthalmol* 14: 86.
5. Shen YD, Yang CM (2007) Extended silicone oil tamponade in primary vitrectomy for complex retinal detachment in proliferative diabetic retinopathy: a long-term follow-up study. *Eur J Ophthalmol* 17: 954-960.
6. Schwartz SG, Flynn HW, Lee WH, Wang X (2014) Tamponade in surgery for retinal detachment associated with proliferative vitreoretinopathy. *Cochrane Database Syst Rev* 2:CD006126.
7. Gesser C, Eckert T, Eckardt U, Porkert U, Eckardt C (2010) Macular hole surgery with air tamponade. Does air suffice for short-term tamponade? *Ophthalmologie* 107:1043-1050.
8. Hoing C, Kampik A, Heidenkummer HP (1994) Results of pars plana vitrectomy with intraocular SF-6 gas tamponade in complicated retinal detachment. *Ophthalmologie* 91: 312-318.
9. Janco L, Vida R, Bartos M, Villemova K (2013) Surgical treatment of the idiopathic macular hole-our experience. *Cesk Slov Oftalmol* 69: 102-105.
10. Rodrigues EB, Shiroma H, Penha FM, Maia M, Moraes-Filho MN, et al. (2014) Development and initial experience with a colored perfluorocarbon liquid for intraocular tamponade in vitreoretinal surgery. *Retina* 34: 1103-1111.
11. Fernandez-Bueno I, Rodriguez de la Rua E, Hileeto D, Parrado ML, Regueiro-Purrinos M, et al. (2013) Histology and immunohistochemistry evaluation of autologous translocation of retinal pigment epithelium-choroid graft in porcine eyes. *Acta Ophthalmol* 91: e125-132.
12. Janco L, Tkacova Villemova K, Ondrejкова M, Vida R, Bartos M, et al. (2014) Retinal tamponade with silicone oil - long term results. *Cesk Slov Oftalmol* 70: 178-182.
13. Minuth WW, Stockl G, Kloth S, Dermietzel R (1992) Construction of an apparatus for perfusion cell cultures which enables in vitro experiments under organotypic conditions. *Eur J Cell Biol* 57: 132-137.
14. Schumacher K, Strehl R, de VU, Minuth WW (2002) Advanced technique for long term culture of epithelia in a continuous luminal-basal medium gradient. *Biomaterials* 23: 805-815.
15. Framme C, Kobuch K, Eckert E, Monzer J, Roeder J (2002) RPE in perfusion tissue culture and its response to laser application. Preliminary report. *Ophthalmologica* 216: 320-328.

16. Minuth WW, Schumacher K, Strehl R, Kloth S (2000) Physiological and cell biological aspects of perfusion culture technique employed to generate differentiated tissues for long term biomaterial testing and tissue engineering. *J Biomater Sci Polym Ed* 11: 495-522.
17. Kobuch K, Herrmann WA, Framme C, Sachs HG, Gabel VP, et al. (2008) Maintenance of adult porcine retina and retinal pigment epithelium in perfusion culture: characterisation of an organotypic in vitro model. *Exp Eye Res* 86: 661-668.
18. Eng LF, Ghirnikar RS, Lee YL (2000) Glial fibrillary acidic protein: GFAP-thirty-one years (1969-2000). *Neurochem Res* 25: 1439-1451.
19. Junemann AG, Rejdak R, Huchzermeyer C, Maciejewski R, Grieb P, et al. (2015) Elevated vitreous body glial fibrillary acidic protein in retinal diseases. *Graefes Arch Clin Exp Ophthalmol* 253 :2181-2186.
20. Eisenfeld AJ, Bunt-Milam AH, Sarthy PV (1984) Muller cell expression of glial fibrillary acidic protein after genetic and experimental photoreceptor degeneration in the rat retina. *Invest Ophthalmol Vis Sci* 25: 1321-1328.
21. Sarthy PV, Fu M, Huang J (1991) Developmental expression of the glial fibrillary acidic protein (GFAP) gene in the mouse retina. *Cellular Mol Neurobiol* 11: 623-637.
22. Bullwinkel J, Baron-Luhr B, Ludemann A, Wohlenberg C, Gerdes J, et al. (2006) Ki-67 protein is associated with ribosomal RNA transcription in quiescent and proliferating cells. *J Cell Physiol* 206: 624-635.
23. Scholzen T1, Gerdes J (2000) The Ki-67 protein: from the known and the unknown. *J Cell Physiol* 182: 311-322.
24. Calik B, Ozturk M, Serdarogullari H, Elcioglu M (2013) Evaluation of anterior segment parameters using pentacam in silicone oil-injected patients after pars plana vitrectomy. *Indian J Ophthalmol* 61: 621-625.
25. Teke MY, Elgin U, Sen E, Ozdal P, Ozturk F (2014) Intravitreal silicone oil induced changes in corneal biomechanics. *Int Ophthalmol* 34: 457- 463.
26. Caramoy A, Droege KM, Kirchhof B, Fauser S (2014) Retinal layers measurements in healthy eyes and in eyes receiving silicone oil-based endotamponade. *Acta Ophthalmol* 92: e292-297.
27. Lucke KH, Foerster MH, Laqua H (1987) Long-term results of vitrectomy and silicone oil in 500 cases of complicated retinal detachments. *Am J Ophthalmol* 104: 624-633.
28. Zafar S, Bokhari SA, Kamil Z, Shakir M, Rizvi SF, et al. (2013) Outcomes of silicone oil removal. *J Coll Physicians Surg Pak* 23: 476-479.
29. Khoroshilova-Maslova IP, Nabieva MK, Leparskaia NL (2012) Morphogenesis of complications after long-term intraocular silicon oil filling (clinical histopathological study). *Vestn Oftalmol* 128: 57-61.
30. Maier MM, Engelmann V, Pfrommer S, Perz C, Lohmann C (2011) [Early emulsification of silicone oil (2000 cs) in minimally invasive transconjunctival vitreoretinal surgery]. *Klin Monbl Augenheilkd* 228: 477-479.
31. Al-Wadani SF, Abouammoh MA, Abu El-Asrar AM (2014) Visual and anatomical outcomes after silicone oil removal in patients with complex retinal detachment. *Int Ophthalmol* 34: 549-556.
32. Heidenkummer HP, Kampik A, Petrovski B (1992) Proliferative activity in epiretinal membranes. The use of the monoclonal antibody Ki-67 in proliferative vitreoretinal diseases. *Retina* 12: 52-58.
33. Shikishima K, Ohki K, Machi N, Sano Y (1992) Effects and distribution of intravitreally or subretinally injected silicone oil identified in rabbit retina using osmium tetroxide method. *Jpn J Ophthalmol* 36: 469-478.
34. Wu KH, Penfold PL, Billson FA (2002) Effects of post-mortem delay and storage duration on the expression of GFAP in normal human adult retinae. *Clin Exp Ophthalmol* 30: 200-207.
35. Mateo-Montoya A1, de Smet MD (2014) Air as tamponade for retinal detachments. *Eur J Ophthalmol* 24: 242-246.
36. Eckardt C, Eckert T, Eckardt U, Porkert U, Gesser C (2008) Macular hole surgery with air tamponade and optical coherence tomography-based duration of face-down positioning. *Retina* 28: 1087-1096.
37. Zhou C, Qiu Q, Zheng Z (2015) Air versus gas tamponade in rhegmatogenous retinal detachment with inferior breaks after 23-gauge pars plana vitrectomy: A Prospective, Randomized Comparative Interventional Study. *Retina* 35: 886-891.