

## Idiopathic Macular Hole Displaced Toward Optic Disc after Vitrectomy with Internal Limiting Membrane Peeling

Kouichi Ohta\*, Atsuko Sato and Emi Fukui

Department of Ophthalmology, Matsumoto Dental University, Japan

\*Corresponding author: Kouichi Ohta, MD, PhD, Department of Ophthalmology, Matsumoto Dental University, 1780 Gobara, Hirooka, Shiojiri, 399-0781, Nagano, Japan, Tel: +81-263-51-2210; Fax: +81-263-51-2210; E-mail: [ohta@po.mdu.ac.jp](mailto:ohta@po.mdu.ac.jp)

Received date: Mar 03, 2014, Accepted date: Mar 27, 2014, Published date: Apr 03, 2014

Copyright: © 2014 Ohta K, et al. This is an open-access article distributed under the terms of the Creative Commons Attribution License, which permits unrestricted use, distribution, and reproduction in any medium, provided the original author and source are credited.

### Abstract

**Purpose:** To compare the distance between the optic disc and the fovea (disc-to-fovea distance) before and after a successful closure of an idiopathic macular hole (MH) by pars plana vitrectomy (PPV) with internal limiting membrane (ILM) peeling.

**Methods:** This was a retrospective observational study of 37 eyes of 36 patients with a MH that had undergone PPV. The distance between the point of intersection of a blood vessel and the disc margin and the center of the opened or closed MH at 6 months after surgery was measured in the Spectralis HRA+OCT (Heidelberg Engineering, Germany) images.

**Results:** The mean disc-to-fovea distance was significantly shorter postoperatively than preoperatively ( $3,783.7 \pm 308.5 \mu\text{m}$  and  $3,914.5 \pm 320.4 \mu\text{m}$ , respectively;  $P < 0.0001$ ). The distance in eyes with Stage 3 and 4 MH ( $n = 22$ ) was significantly greater than that in eyes with Stage 2 MH ( $136.7 \pm 134.9 \mu\text{m}$  vs.  $107.8 \pm 107.8 \mu\text{m}$ , respectively;  $P = 0.012$ ;  $n = 15$ ).

**Conclusions:** The significantly shorter postoperative disc-to-fovea distance in eyes with a closed MH especially Stage 3 and 4 MHs suggests that the fovea moves nasally after PPV with ILM peeling.

**Keywords:** Idiopathic macular hole; Internal limiting membrane; Retinal thickness; Spectral-domain optical coherence tomography; Vitrectomy

Thus, the purpose of this study was to determine whether the center of the MH is displaced after a MH is closed by vitrectomy with ILM peeling.

### Introduction

Kelly and Wendel reported that idiopathic macular holes (MHs) can be closed by pars plana vitrectomy (PPV) with fluid-gas exchange [1,2]. Since then, the surgical technique for closing a MH has been modified, e.g., removal of the internal limiting membrane (ILM), which has increased the anatomic success rates and improved the functional results [3-6]. However, an unusual postoperative appearance called a dissociated optic nerve fiber layer (DONFL) appearance was reported after ILM peeling [7-9].

Earlier, we found that the parafoveal nasal retina was significantly thicker and the temporal retina was significantly thinner than the corresponding areas of the fellow eyes in the spectral-domain optical coherence tomographic (SD-OCT) images [10,11]. In addition, Kumagai et al. reported that this phenomenon was observed not only in eyes after MH closure but also after epiretinal membrane (ERM) removal with ILM peeling [12]. These findings indicated that there are alterations of the retina were related to the vitrectomy with ILM peeling.

Yanagita et al. reported that the retina around a MH moved toward the foveal pit after vitrectomy [13]. On the other hand, Kawano et al. recently showed a displacement of the macula toward the optic disc [14]. There has not been an explanation for this discrepancy.

### Methods

#### Patients

A non-randomized, retrospective chart review was performed on 37 eyes of 36 Japanese patients with a full-thickness MH (16 men, 20 women) who were treated at the Matsumoto Dental University Hospital between June 2008 and July 2012. Twenty-two eyes with a MH were the same eyes studied in our earlier report [11]. Eyes with a MH of duration >6 months or with a MH >1,000  $\mu\text{m}$  in diameter were excluded. Patients with other ocular diseases, such as ERM, macular edema, rhegmatogenous retinal detachment, glaucoma, diabetic retinopathy, uveitis, and high pathological myopia were also excluded. Of the 41 remaining eyes of 40 patients with an idiopathic MH, 4 eyes were excluded; 3 eyes were not closed after the initial operation, and the other eye developed macular edema.

All of the procedures adhered to the tenets of the Declaration of Helsinki. The protocol of this study was approved by the Institutional Review Board and Ethics Committee of Matsumoto Dental University, and a written informed consent for the examination and surgery was obtained from all of the patients.

## Surgical procedures

The vitreoretinal surgery was performed with standard 23-gauge (23-G; n=18) or 25-G (n=19) instruments by a single surgeon (KO). Phacoemulsification and placement of a Tecnis® ZA9003 (Abbott Medical Optics, Santa Ana, CA, USA) posterior chamber intraocular lens (IOL) were done in 35 of the eyes. After core vitrectomy, a posterior vitreous detachment (PVD) was created by suction with the vitrectomy cutter after triamcinolone acetonide (TA, Kenakolt-A; Bristol Pharmaceuticals KK, Tokyo, Japan or Maquaid, Wakamoto Pharmaceuticals Co., Ltd, Tokyo, Japan ) was injected into the vitreous cavity [11]. A PVD was already present in two eyes with a Stage 4 MH.

During the MH surgery, the ILM was stained with approximately 0.5 mL of 0.25% indocyanine green (ICG) injected intravitreally for 1 min in 11 eyes or with Brilliant Blue G (BrilliantPeel®, Geuder, Heidelberg, Germany) in 4 eyes. The ILM of all other eyes was made more visible with TA. The ILM was grasped at the temporal raphe and peeled approximately 1 to 5 disc diameter around the MH. Then fluid-air exchange was performed with the air pressure set at 35 mmHg. Twenty percent sulfur hexafluoride (SF<sub>6</sub>) was used for the gas tamponade. The patients were instructed to remain in a prone position for at least 7 days.

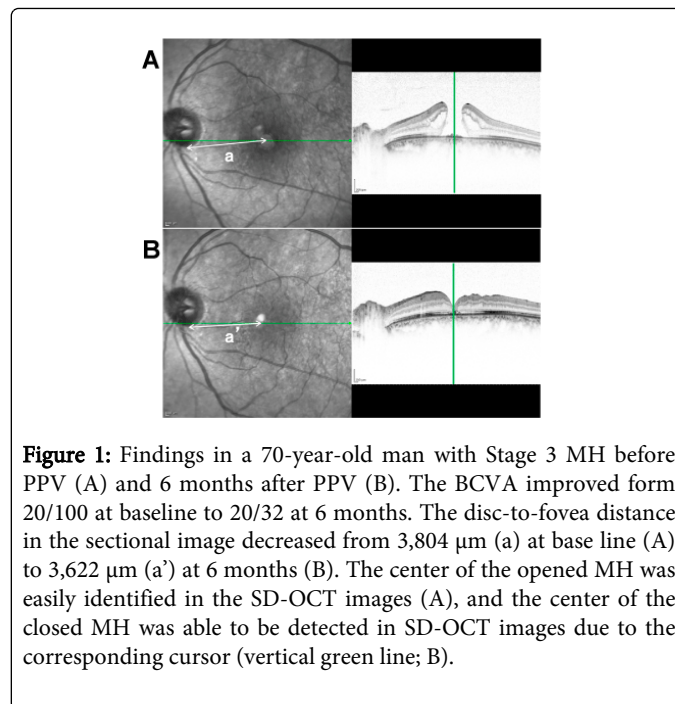
## Optical coherence tomography

The spectral-domain (SD)-OCT examinations were performed before and at 6 months after the PPV with the Spectralis HRA+OCT (Heidelberg Engineering, Heidelberg, Germany). The horizontal and vertical images centered on the fovea in the cross-hair mode (30°) were evaluated. We determined the center of the opened MH manually on enlarged images of the retina on a monitor screen (Figure 1A). We also determined the site of a small retinal vessel crossing the temporal-inferior edge of the optic disc. We then manually measured the distance from the selected site on the disc margin to the selected center of the opened (Figure 1A; a) or closed MH as the disc-to-fovea distance (Figure 1B; a').

The macular thickness and volume were obtained with the volume scan mode of the OCT instrument as described [11,12]. With the retinal thickness map analysis protocol of the Spectralis (ver. 4c), the full thicknesses of the fovea (within the 1 mm diameter circle), the parafoveal area (within the annulus of diameters of 1 and 3 mm), and the perifoveal region (within the annulus diameters of 3 and 6 mm) were automatically measured [15,16].

## Statistical analyses

The results are expressed as the means ± SD. The data were analyzed with the IBM SPSS Statics software (version 21, IBM Corp., Armonk, New York). The significance of differences in the pre- and postoperative values was determined with paired *t* tests. The significance of differences between the Stage 2 MH eyes and Stage 3 or 4 MH eyes was determined by unpaired *t* tests. Simple linear regression analysis was used to determine the correlation between the disc-to-fovea distance and retinal thickness. A difference was considered to be statistically significant when the *P* was <0.05.



**Figure 1:** Findings in a 70-year-old man with Stage 3 MH before PPV (A) and 6 months after PPV (B). The BCVA improved from 20/100 at baseline to 20/32 at 6 months. The disc-to-fovea distance in the sectional image decreased from 3,804 μm (a) at base line (A) to 3,622 μm (a') at 6 months (B). The center of the opened MH was easily identified in the SD-OCT images (A), and the center of the closed MH was able to be detected in SD-OCT images due to the corresponding cursor (vertical green line; B).

## Results

The clinical characteristic of all of the eyes are summarized in Table 1. The MH was closed in all of the eyes after the first operation.

Characteristics	
Eyes	37
Men, Women	16, 20
age, mean ± SD, year (range)	65.0 ± 5.6 (51-74)
Axial length, mean ± SD, mm (range)	23.7 ± 0.9 (22.5-25.6)
<b>Macular hole Stage (n)</b>	
2	14
3	21
4	2
Preoperative mean BCVA, logMAR units	0.46 ± 0.25
Postoperative mean BCVA, longMAR units	-0.023 ± 0.24
Macular hole size, μm	392.5 ± 140.4
ILM peeling	37
TA only	22
TA + ICG	11
TA + BBG	4
BCVA: Best-Corrected Visual Acuity; ILM: Internal Limiting Membrane; TA: Triamcinolone Acetonide; ICG: Indocyanine Green; BBG: Brilliant Blue G	

**Table 1:** Descriptive data of eyes undergoing pars plana vitrectomy.

### Inter-examiner reproducibility

The correlation between the values obtained by the 2 examiners who measured the disc-to-fovea distance was significant, i.e., the interclass correlation coefficient (ICC) was 0.671 (95% CI, 0.449-0.815). We also measured the horizontal and vertical distances at 6 months after the surgery. The ICC for the disc-to-fovea distance in the postoperative eyes was 0.664 (95% CI, 0.439-0.811), and in the normal fellow eyes it was 0.965 (95% CI, 0.934-0.982).

### Disc-to-fovea distance before and after PPV

The mean disc-to-fovea distance was significantly shorter 6 months after PPV than that at the baseline ( $3,783.7 \pm 308.5 \mu\text{m}$  vs.  $3,914.5 \pm 320.4 \mu\text{m}$ ;  $P < 0.0001$ ). This indicated that the center of the fovea had moved toward the optic disc by  $135.5 \pm 133.8 \mu\text{m}$ .

To eliminate the effect of the IOL, 20 eyes of 20 cataract patients (8 men, 12 women; mean age,  $71.8 \pm 8.0$  years) were also examined as control. They underwent phacoemulsification and placement of a posterior chamber IOL as is usually done on MH patients. The mean axial length was  $24.0 \pm 1.4$  mm which was not significantly different than that in the MH group (Table 1).

In contrast to MH group, the mean disc-to-fovea distance was not significantly shorter 6 months after PPV than that at the baseline ( $3,771.3 \pm 322.8 \mu\text{m}$  vs.  $3,754.0 \pm 304.6 \mu\text{m}$ ;  $P = 0.504$ ). The mean change of disc-to-fovea distance was  $17.4 \pm 114.0 \mu\text{m}$ .

### Comparison of disc-to-fovea distance for different MH stages

We measured the disc-to-fovea distance at the baseline and at 6 months, and compared the values for Stage 2 MHs to that for Stage 3 and 4 MHs. There were significant differences in the disc-to-fovea

distance between the baseline and 6 months for both Stage 2 MHs ( $107.8 \pm 107.8 \mu\text{m}$ ,  $P = 0.028$ ) and Stage 3 and 4 MHs ( $136.7 \pm 134.9 \mu\text{m}$ ,  $P = 0.012$ ). The change in the disc-to-fovea distance in Stage 3 and 4 MHs was significantly greater than that in Stage 2 MHs ( $P = 0.012$ ).

The postoperative disc-to-fovea distances were shorter than the preoperative distance for all 22 eyes with Stage 3 or 4 MHs (range from 7 to  $540 \mu\text{m}$ ) although the variance was large. The postoperative disc-to-fovea distance was greater than the preoperative distance in 3 of 15 eyes with Stage 2 MH.

We next determined whether the difference in the disc-to-fovea distance between Stage 2 and Stage 3 and 4 was correlated with the BCVA, the MH size, and the area of ILM peeling (Table 2). There was no significant difference in these factors between Stage 2 and Stage 3/4 eyes. In addition, we compared the disc-to-fovea distances between eyes with the use of ICG and those with TA only and TA+BBG. However, there was no significant difference (data not shown).

Because the disc-to-fovea distance was greater in Stage 3/4 MHs, the nasal and temporal edge to center of MH was compared before and 6 months after the MH surgery. We identified the center of the opened MH, and there was no significant difference between the distance of the nasal edge-to-fovea and the temporal edge-to-fovea before surgery ( $206.7 \pm 60.3 \mu\text{m}$  and  $205.1 \pm 69.1 \mu\text{m}$ , respectively, N.S.). In contrast, the distance of the nasal edge-to-fovea was much shorter than that of the temporal edge-to-fovea ( $29.0 \pm 154.2 \mu\text{m}$  and  $373.2 \pm 153.9 \mu\text{m}$ , respectively,  $P < 0.0001$ ).

### Correlations between disc-to-fovea distance and best-corrected visual acuity (BCVA) and macular hole size

The correlation between shortening of the disc-to-fovea distance and pre- and postoperative BCVA at 6 months was evaluated by simple linear regression analysis. The BCVA of both Stage 2 and Stage 3/4 MHs was not correlated with the disc-to-fovea distance (Table 3). The correlation between disc-to-fovea distance and preoperative MH size was also not significant ( $P = 0.055$ ).

Stage	2	3 and 4	P*
Number of eyes	15	20 and 2	
Shortening of disc-to-fovea distance, $\mu\text{m}$	$107.8 \pm 107.8$	$136.7 \pm 134.9$	0.012
Preoperative mean BCVA, logMAR units	$0.43 \pm 0.24$	$0.47 \pm 0.23$	0.61
Postoperative mean BCVA, logMAR units	$-0.098 \pm 0.23$	$0.027 \pm 0.17$	0.17
Macular hole size, $\mu\text{m}$	$402 \pm 164.1$	$385.5 \pm 125.5$	0.74
Basal macular hole size, $\mu\text{m}$	$539.9 \pm 212.2$	$674.1 \pm 266.6$	0.098
Staining (TA / ICG / BBG)	10 / 4 / 1	12 / 7 / 3	
Area of ILM peeling (DA)	$3.8 \pm 2.3$	$3.9 \pm 2.3$	0.91
Data are expressed as the means $\pm$ standard deviation			
* Unpaired t tests			
TA: Triamcinolone acetonide; ICG: Indocyanine Green; BBG: Brilliant Blue G; DA: Approximate Disc Area			

**Table 2:** Comparison of OCT measurements and demographic features of Stage 2 and 3/4.

	Stage 2		Stage 3 / 4	
	<i>r</i>	<i>P</i> *	<i>r</i>	<i>P</i> *
Preoperative mean BCVA	0.13	0.66	0.17	0.46
Postoperative mean BCVA	0.005	0.98	0.01	0.96
Preoperative MH size	0.50	0.05	0.009	0.97
Preoperative basal MH size	0.03	0.90	0.31	0.20

\* Pearson's correlation coefficient

**Table 3:** Correlation between shortening of disc to fovea distance and demographic features.

### Correlation between disc-to-fovea distance and parafoveal thickness

We found that the shortening of the disc-to-fovea distance was significantly and positively correlated with the parafoveal nasal retinal thickness at 6 months in only Stage 3/4 MH eyes ( $r=0.52$ ;  $P=0.013$ ; Table 4). The shortening was also correlated with all of the perifoveal retinal sectors at 6 months. There were significant correlations of the disc-to-fovea distance and the nasal and superior parafoveal thicknesses ( $r=0.49$ ,  $P=0.03$ ;  $r=0.48$ ,  $P=0.036$ ; respectively). However, a significant correlation was not found for the preoperative or the change after MH surgery (thickness at 6 months – preoperative thickness) in all 4 sectors. In contrast to the positive correlation between the shortening and retinal thickness in Stage 3/4 MH eyes, there was no significant correlation in Stage 2 MH eyes (data not shown).

### Discussion

Our results showed that the center of the fovea moved toward the optic disc by  $135.5 \pm 133.8 \mu\text{m}$  after PPV with ILM peeling for an idiopathic MH. Kawano et al. reported that the mean preoperative center of the MH to optic disc (MH-OD) distance decreased significantly to postoperative center of the fovea to optic disc (F-OD) distance ( $2.77 \pm 0.33 \text{ DD}$  and  $2.67 \pm 0.33 \text{ DD}$ , respectively) [14]. A shortening of 0.1 DD can be calculated be about 150-160  $\mu\text{m}$ . Thus, our results are comparable to theirs. This confirms that the macula is displaced toward the optic disc after ILM peeling although the mechanism was not determined.

Our results showed that the disc-to-fovea distance before and after PPV with ILM peeling for an idiopathic MH was shortened in all 22 eyes with Stage 3/4 MHs. In contrast, the postoperative distances were longer than the preoperative distances in 3 of 15 eyes with Stage 2 MH (data not shown). Thus, the shortening was significantly greater in eyes with Stage 3/4 MHs than in those with Stage 2 MH.

We examined the possible factors associated with these differences for both stages. In this small retrospective series, there were no significant differences in the pre- and postoperative mean BCVA, preoperative diameters of the MH, and the preoperative basal diameters, and the area of ILM peeling. Taken together, our results

showed that the shortening of disc-to-fovea distance was related only to the stage of the MH.

	Before	(n=21)	6 months	(n=22)	delta	(n=21)
	<i>r</i>	<i>P</i> *	<i>r</i>	<i>P</i> *	<i>r</i>	<i>P</i> *
Fovea	0.36	0.12	0.01	0.95	0.34	0.14
Parafovea						
Nasal	0.38	0.09	0.52	0.013	0.28	0.22
Temporal	0.27	0.24	0.14	0.54	0.24	0.29
Superior	0.25	0.28	0.39	0.08	0.16	0.48
Inferior	0.44	0.048	0.33	0.13	0.34	0.13
Peripfovea						
Nasal	0.27	0.25	0.49	0.03	0.09	0.71
Temporal	0.27	0.25	0.43	0.056	0.18	0.46
Superior	0.32	0.22	0.48	0.036	0.11	0.69
Inferior	0.37	0.16	0.42	0.07	0.02	0.94

\*Pearson's correlation coefficient test; Delta: preoperative mean retinal thickness – postoperative mean retinal thickness.

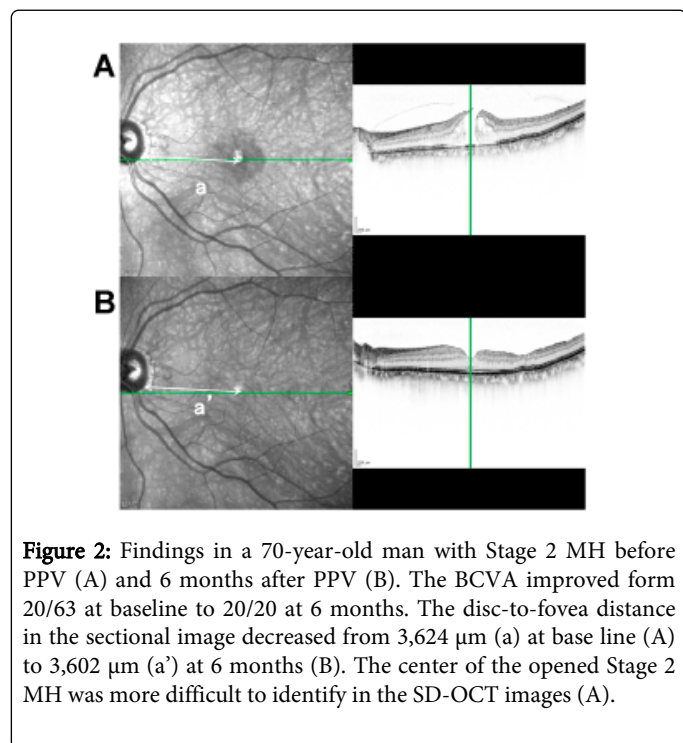
**Table 4:** Correlation between shortening of disc to fovea distance and retinal thickness in Stage 3 and 4.

Another important issue is our difficulty in identifying the real center in an oval or horseshoe-shaped Stage 2 MH. We believe that this might be the reason why the disc-to-fovea distance in Stage 2 MH was significantly shorter than that in eyes with Stage 3 and 4 MHs. Thus, the center of preoperative round Stage 3/4 MH (Figure 1) was more easily and correctly identified than those of Stage 2 MH (Figure 2) in the SD-OCT images.

We also found a positive significant correlation between the shortening of the disc-to-fovea distance and the postoperative mean nasal retinal thickness. We suggest that the thicker postoperative nasal retina might exert some traction toward the temporal side during the MH opening. In other words, the thickening of the nasal retina might have been caused by the direction of the opening of the MH. Although there is no related report or animal experiments, we hypothesize that the nasal parafoveal retina is thickened because the fovea is displaced



nasally. This displacement, which is probably caused by the ILM removal, curls up the nasal retina or pushes it together. However, we cannot exclude the possibility that the thicker postoperative nasal retina and the shortening of disc-to-fovea distance after ILM peeling occurred independently.



**Figure 2:** Findings in a 70-year-old man with Stage 2 MH before PPV (A) and 6 months after PPV (B). The BCVA improved from 20/63 at baseline to 20/20 at 6 months. The disc-to-fovea distance in the sectional image decreased from 3,624  $\mu\text{m}$  (a) at baseline (A) to 3,602  $\mu\text{m}$  (a') at 6 months (B). The center of the opened Stage 2 MH was more difficult to identify in the SD-OCT images (A).

Our study has some limitations. The most important issue was whether the center of the preoperative opened MH was correctly identified. Because the BCVA and fixation were not good preoperatively, the center of the MH was not always scanned in the horizontal or vertical planes. In addition, we identified the center of the MH manually, and thus the disc-to-fovea distance may not be correct in some cases. Indeed, the ICC was not high in this study. However, the shortening of the disc-to-fovea distance was obtained in all stage 3 MH eyes. Yoshikawa et al. also reported a similar macular migration toward the optic disc in patients with diabetic macular edema [17]. Thus, we believe that the real distance may not differ from our measurements.

Another important issue was the possible effect of phacoemulsification/IOL implantation for the measurement disc-to-fovea distance. We had less effect based on 20 cataract patients using with same IOL. However, the range of change of disc-to-macula distance was large. Thus, we may have to consider the possible effects of cataract surgery on the measurements of the OCT images.

Another limitation of this study was the number of patients studied was small which may have affected the reliability of the statistical analyses. However, our measurements were most likely accurate based on the excellent reproducibility of the Spectralis OCT retinal thickness measurements [18]. In addition, the vitrectomy was done by a single surgeon thus minimizing the effect of surgical procedures. Based on these points, we believe our findings are reliable.

Long-term follow-up studies are needed. Treumer et al. reported the persistence of nasal parafoveal thickening after ERM and ILM peeling after ERM surgery [19]. Recently, a progressive macular

thinning for more than 6 months after MH surgery with ILM peeling was also reported [20]. The shortening of the disc-to-fovea distance after ILM peeling and correlation to the macular thickness and shortening should be investigated in long-term longitudinal studies.

In conclusion, we showed that the fovea was displaced toward the optic disc after PPV with ILM peeling especially in Stage 3/4 MHs. We also found a significant positive correlation between the shortening of disc-to-fovea distance and the postoperative mean nasal retinal thickness. Additional studies, especially comparisons of the disc-to-fovea distance in eyes before and after the development of a MH, and after a successful closure of the MH could confirm our results.

### Acknowledgement

We thank Prof. Duco Hamasaki of the Bascom Palmer Eye Institute for editing the manuscript.

### Ethics Approval

Ethics approval was provided by the Institutional Review Board of the Matsumoto Dental University, Shiojiri, Japan.

### References

1. Kelly NE, Wendel RT (1991) Vitreous surgery for idiopathic macular holes. Results of a pilot study. *Arch Ophthalmol* 109: 654-659.
2. Wendel RT, Patel AC, Kelly NE, Salzano TC, Wells JW, et al. (1993) Vitreous surgery for macular holes. *Ophthalmology* 100: 1671-1676.
3. Olsen TW, Sternberg P Jr, Capone A Jr, Martin DF, Lim JI, et al. (1998) Macular hole surgery using thrombin-activated fibrinogen and selective removal of the internal limiting membrane. *Retina* 18: 322-329.
4. Park DW, Sipperley JO, Sneed SR, Dugel PU, Jacobsen J (1999) Macular hole surgery with internal-limiting membrane peeling and intravitreal air. *Ophthalmology* 106: 1392-1397.
5. Mester V, Kuhn F (2000) Internal limiting membrane removal in the management of full-thickness macular holes. *Am J Ophthalmol* 129: 769-777.
6. Brooks HL Jr (2000) Macular hole surgery with and without internal limiting membrane peeling. *Ophthalmology* 107: 1939-1948.
7. Tadayoni R, Paques M, Massin P, Mouki-Benani S, Mikol J, et al. (2001) Dissociated optic nerve fiber layer appearance of the fundus after idiopathic epiretinal membrane removal. *Ophthalmology* 108: 2279-2283.
8. Ito Y, Terasaki H, Takahashi A, Yamakoshi T, Kondo M, et al. (2005) Dissociated optic nerve fiber layer appearance after internal limiting membrane peeling for idiopathic macular holes. *Ophthalmology* 112: 1415-1420.
9. Mitamura Y, Ohtsuka K (2005) Relationship of dissociated optic nerve fiber layer appearance to internal limiting membrane peeling. *Ophthalmology* 112: 1766-1770.
10. Ohta K, Sato A, Fukui E (2010) Asymmetrical thickness of parafoveal retina around surgically closed macular hole. *Br J Ophthalmol* 94: 1545-1546.
11. Ohta K, Sato A, Fukui E (2013) Retinal thickness in eyes with idiopathic macular hole after vitrectomy with internal limiting membrane peeling. *Graefes Arch Clin Exp Ophthalmol* 251: 1273-1279.
12. Kumagai K, Ogino N, Furukawa M, Hangai M, Kazama S, et al. (2012) Retinal thickness after vitrectomy and internal limiting membrane peeling for macular hole and epiretinal membrane. *Clin Ophthalmol* 6: 679-688.
13. Yanagita T, Shimizu K, Fujimura F, Takano M (2009) Fixation point after successful macular hole surgery with internal limiting membrane peeling. *Ophthalmic Surg Lasers Imaging* 40: 109-114.

14. Kawano K, Ito Y, Kondo M, Ishikawa K, Kachi S, et al. (2013) Displacement of foveal area toward optic disc after macular hole surgery with internal limiting membrane peeling. *Eye (Lond)* 27: 871-877.
15. Early Treatment Diabetic Retinopathy Study Research Group (1985) Photocoagulation for diabetic macular edema. Early Treatment Diabetic Retinopathy Study report number 1. Early Treatment Diabetic Retinopathy Study research group. *Arch Ophthalmol* 103: 1796-1806.
16. Grover S, Murthy RK, Brar VS, Chalam KV (2009) Normative data for macular thickness by high-definition spectral-domain optical coherence tomography (spectralis). *Am J Ophthalmol* 148: 266-271.
17. Yoshikawa M, Murakami T, Nishijima K, Uji A, Ogino K, et al. (2013) Macular migration toward the optic disc after inner limiting membrane peeling for diabetic macular edema. *Invest Ophthalmol Vis Sci* 54: 629-635.
18. Menke MN, Dabov S, Knecht P, Sturm V (2009) Reproducibility of retinal thickness measurements in healthy subjects using spectralis optical coherence tomography. *Am J Ophthalmol* 147: 467-472.
19. Treumer F, Wacker N, Junge O, Hedderich J, Roeder J, et al. (2011) Foveal structure and thickness of retinal layers long-term after surgical peeling of idiopathic epiretinal membrane. *Invest Ophthalmol Vis Sci* 52: 744-750.
20. Kumagai K, Hangai M, Larson E, Ogino N (2013) Progressive changes of regional macular thickness after macular hole surgery with internal limiting membrane peeling. *Invest Ophthalmol Vis Sci* 54: 4491-4497.