

## How Do I Perform Temporary Occlusion of the Uterine Arteries During Laparoscopic Myomectomy?

Rafael Luis dos Santos Martin<sup>1,2</sup>, Monica Tessmann Zomer<sup>1,2</sup>, Renata Hayashi<sup>1,2</sup>, Reitan Ribeiro<sup>1,2</sup> and William Kondo<sup>1,2\*</sup>

<sup>1</sup>Department of Gynecology, Sugisawa Medical Center-Curitiba, Parana, Brazil

<sup>2</sup>Department of Gynecology, Vita Batel Hospital, Curitiba-Curitiba, Parana, Brazil

\*Corresponding author: William Kondo, Avenida Getulio Vargas, 3163 ap 21 Curitiba – PR, 80240-041, Brazil, Tel: (55) (41)9222-1065; E-mail: [williamkondo@yahoo.com](mailto:williamkondo@yahoo.com)

Received date: 15 Feb, 2015; Accepted date: 09 March, 2015; Published date: 11 March, 2015

Copyright: © 2015 dos Santos Martin RL, et al. This is an open-access article distributed under the terms of the Creative Commons Attribution License, which permits unrestricted use, distribution, and reproduction in any medium, provided the original author and source are credited.

### Abstract

Myomectomy is been considered a treatment of choice for women with uterine leiomyomas who desire a safe pregnancy or wish to maintain their fertility. Depending on the uterine location and size of the leiomyomas, the surgical procedure may be conducted by hysteroscopy, laparotomy or laparoscopy/robotics. In some situations, laparoscopic myomectomy may be a challenging procedure especially because of the potential risk of bleeding. In this paper, the authors describe in detail the surgical steps of the temporary occlusion of the uterine artery in the beginning of the laparoscopic myomectomy in order to minimize the intraoperative blood loss.

**Keywords:** Leiomyoma; Myomectomy; Laparoscopy

### Introduction

Uterine leiomyomatosis is the most common genital tract pathology in women [1,2]. It has 20-40% prevalence in women over 35 years old [2]. Although a significant percentage of the patients are asymptomatic, the presence of abnormal uterine bleeding, pelvic pain and/or infertility may need therapeutic management. Myomectomy has been considered a treatment of choice for women with uterine leiomyomas who desire a safe pregnancy or wish to maintain their fertility [3].

According to the uterine location and size of the leiomyomas, the surgical procedure may be conducted by hysteroscopy, laparotomy or laparoscopy/robotics [4]. To date, the most common choice of minimally invasive approach for large leiomyomas is the laparoscopic procedure, offering minimal postoperative discomfort, shorter hospitalization, faster return to normal activities, reduced risk of transfusion and intraabdominal adhesions [5,6]. However, laparoscopic myomectomy is a challenging procedure especially because of the potential risk of bleeding [3]. This is the most frequent intraoperative complication independently from the surgeons' experience [7].

Several techniques have been described in order to reduce intraoperative blood loss during laparoscopic myomectomy, such as vasoconstrictor agents use, premyomectomy uterine artery embolization, uterine artery ligation and compression of the uterine artery [8-11].

In this paper, the authors describe in detail the surgical steps of the temporary occlusion of the uterine artery in the beginning of the laparoscopic myomectomy in order to minimize the intraoperative blood loss.

### Rationale

The uterus has an extremely rich and diverse vascular supply. The uterine artery is the main artery that irrigates the uterus and has about 2 to 6 mm in diameter [12,13]. It is a branch from the anterior division of the internal iliac artery. As a complement, there are still the communicating arteries (up to 0.5 mm in diameter) that connect arteries from the uterus and ovaries [13]. Also, the inferior mesenteric, lumbar, vertebral, medial sacral, deep iliac circumflex, inferior epigastric, medial femoral circumflex and lateral femoral circumflex contributes to the uterine vascularization. Finally, numerous unnamed small arteries supply the uterus from the broad ligament and the retroperitoneum as well.

It has been the common teaching that there is a vascular pedicle at the base of each leiomyoma, and that ligation of this pedicle will achieve hemostasis during myomectomy. However, a study using vascular corrosion casting and electron microscopy revealed that myomas are surrounded completely by a dense vascular layer supplying the myoma, which is separated from the myometrium by a narrow avascular cleft [14].

Indeed, the blood supply to the leiomyoma comes exclusively from the uterine arteries [2]. Therefore, the temporary occlusion of the uterine arteries in the beginning of the procedure ensures reduction in the intraoperative bleeding during myomectomy.

### Surgical Technique

#### Patient's position and laparoscopic installation

Under general anesthesia, the patient is positioned in dorsal decubitus with arms alongside her body and lower limbs in abduction, accommodated in a way that is slightly elevated when compared to the trunk. The buttock must lie 5 to 10 cm away from the table allowing for effective uterine manipulation. A bladder catheter is placed to empty the bladder and to control the urine output. The stomach is

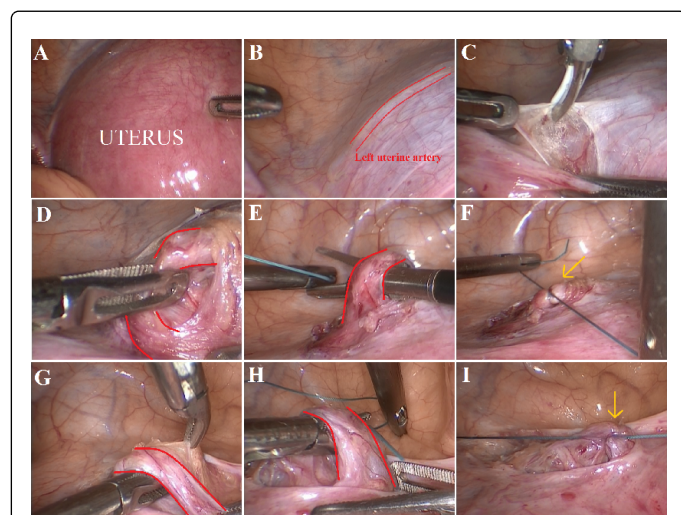
emptied with the insertion of an orogastric tube. A curette is placed through the cervix to manipulate the uterus.

The surgeon stays on the left side of the patient, the first assistant on the right side, the second assistant in between the patient's legs for uterine manipulation, and the scrub nurse by the surgeon's side.

Pneumoperitoneum is achieved using a Veres needle placed at the umbilicus or at the left hypochondrium (Palmer's point). Four trocars are placed: a 10-mm at the umbilicus for the zero-degree laparoscope, a 5-mm at the right anterosuperior iliac spine, a 5-mm in the midline between the umbilicus and the pubic symphysis, approximately 8 to 10 cm inferior to the umbilical trocar, and a 5-mm at the left anterosuperior iliac spine.

### Technical aspects

After a thorough exploration of the pelvic cavity, the surgeon may evaluate the leiomyomas in order to define the necessity or not of performing temporary occlusion of the uterine arteries. Three different approaches may be used to achieve it, depending on the uterine anatomy and the position of the leiomyomas [2].



**Figure 1:** (A) Laparoscopic visualization of the enlarged uterus for myomectomy. (B) Visualization of the impression of the left uterine artery (in red) on the anterior and lateral aspect of the uterine cervix. (C) The peritoneum is opened over the left uterine artery. (D to F) Dissection of the left uterine artery and placement of a ligature using 2-0 polyester suture (yellow arrow). (G to I) The same procedure is conducted at the right side

### Anterior approach

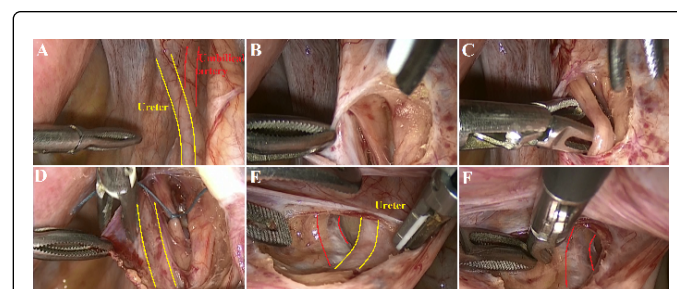
The impression of the uterine vessels can usually be seen anterior and laterally to the uterine cervix. After the identification of the path of the uterine arteries (Figures 1A and 1B), the peritoneum of the anterior cul-de-sac is opened over the vessels (Figure 1C) and the uterine artery is carefully dissected next to the lateral border of the uterine cervix. This dissection must be extremely cautious because the uterine veins are very close to the artery. A venous bleeding at this point of the dissection can be very difficult to control without ligating the vessels. After the circumferential dissection of the artery, the temporary occlusion is conducted using 2-0 polyester suture (Figures

1D to 1I). One single thread is usually enough to block the blood flow and is easy to remove at the end of the procedure.

This is a good option in those patients with myomas located at the posterior uterine wall. In some instances, such myomas displace the uterine vessels anteriorly and it may be easy to identify the arteries bordering the uterine cervix.

### Posterior approach, medial to the infundibulopelvic ligament

For the ligation of the uterine artery posteriorly to the uterus and medially to the pelvic infundibulum, the ureter should be first identified. The surgeon may grab the obliterated umbilical artery at the anterior abdominal wall and retract it. The movement of the umbilical artery may be seen at the ovarian fossa perpendicular to the ureter (Figure 2A). The peritoneum of the ovarian fossa should be opened above the ureter and over the impression of the umbilical artery (Figure 2B). The ureter is retracted medially and the umbilical artery is dissected vertical and cranially. Usually, one will identify the origin of the uterine artery at this point, which goes medial to the umbilical artery and almost parallel to the ureter. The artery may be grabbed and dissected circumferentially. The occlusion of the artery is performed as described above (Figures 2C to 2F).



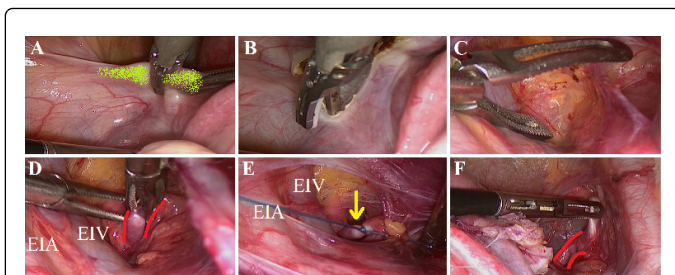
**Figure 2:** (A) Visualization of the right ureter (in yellow) crossing over the umbilical artery (in red). (B) The peritoneum of the ovarian fossa is opened over the umbilical artery and the structures are identified and isolated. (C) Dissection of the right uterine artery. (D) Placement of a ligature on the right uterine artery using 2-0 polyester suture. (E and F) The same procedure is performed at the right side

### Posterior approach, lateral to the infundibulopelvic ligament

For the ligation of the uterine artery posteriorly to the uterus and laterally to the pelvic infundibulum, the opening of the peritoneum of the broad ligament should start immediately below the round ligament, parallel and medial to the external iliac vessels towards the base of the pelvic infundibulum (Figures 3A and 3B). The avascular space is dissected by blunt dissection (traction and counter-traction) identifying the following landmarks (Figures 3C and 3D):

- Lateral: external iliac vessels;
- Medial: pelvic infundibulum and the ureter attached to the peritoneum of the ovarian fossa.

The external iliac artery is dissected cranially in order to find the bifurcation of the common iliac artery and the internal iliac artery. The first medial branch of the anterior division of the internal iliac is normally the uterine artery. After circumferential dissection of the uterine artery it may be ligated according to the same technique described above (Figures 3E and 3F).



**Figure 3:** (A) The assistant grabs the left round ligament (in green). (B) The peritoneum of the broad ligament is opened towards the pelvic infundibulum. (C and D) The avascular space is dissected medial to the external iliac artery (EIA and vein (EIV), identifying the uterine artery. The ureter should remain attached to the peritoneum medially. (E) The ligature is placed on the left uterine artery using 2-0 polyester suture (yellow arrow). (F) The same procedure is performed at the right side. The right uterine artery is demonstrated in red

## Discussion

Several randomized control trials have shown the advantages of laparoscopic myomectomy compared with its open counterpart [15]. However, laparoscopic myomectomy is affected by some limits according to the number and size of uterine leiomyomas [16,17]. Intramural myomas larger than 8 cm and subserosal ones larger than 12cm may be considered as a surgical challenge [4]. The most frequent complication remains the severe intraoperative bleeding that may occur in up to 20% of cases [7].

Some authors demonstrate that temporary clipping of the uterine artery during myomectomy reduces hemoglobin loss during the procedure [18,19]. In this paper the authors have demonstrated different surgical approaches to achieve it in the beginning of the laparoscopic myomectomy.

Laparoscopic identification and occlusion of the uterine arteries require an excellent knowledge of retroperitoneal anatomy, expertise and skills [3]. Suture ligation is the standard method of controlling the uterine artery in open surgery [20]. In laparoscopic surgery, the surgeon may occlude the uterine artery by suture ligation or clips. In the experience of Vercellino et al. [18], the time needed to occlude the uterine arteries using clips varied between 6 and 40 minutes. In our experience we prefer to occlude the uterine arteries using suture ligation. It is usually performed using a single knot (2-0 polyester suture) after circumferential dissection of the uterine artery. The time required for this step of the procedure ranges between 15 to 30 minutes.

The complications of uterine artery ligation include thermal damage to the ureter owing to use of bipolar diathermy [20] and vascular injury during dissection. If clips are applied to the artery, the surgeon may take care during clips removal in order not to damage the vessel. That is why the authors prefer to ligate the artery with suture. It is easier and less dangerous to remove!

There are some disagreements about the effectiveness of the temporary occlusion of the uterine arteries regarding the perfusion damage it may cause. Critics of this method state that it may induce irreversible damage to the myometrium after 2 hours of occlusion

[20]. Nevertheless, experienced surgeons usually perform the uterine repair quickly, especially in a relatively bloodless situation provided by the temporary occlusion of the uterine arteries during laparoscopic myomectomy. In our practice, we have never experienced any patient with postoperative symptoms that suggested perfusion damage to the uterus such as intense pelvic pain. Most of laparoscopic myomectomies do not last longer than 2 hours; therefore, this is not the main concern during this type of procedure. Whenever we have multiple myomectomies to be done, we place the sutures deeply on the myometrium for hemostasis and we close the superficial layers after releasing the uterine artery ligature. In this way we can reduce the ischemia time and we can check for any bleeding coming from the internal surface of the myometrium.

## Conclusion

Temporary occlusion of the uterine arteries may be an alternative approach to minimize intraoperative blood loss during laparoscopic myomectomy. It should be considered in all patients with challenging myomas at higher risk of bleeding.

## References

1. Salman T, Davis C (2010) Uterine fibroids, management and effect on fertility. *Curr Opin Obstet Gynecol* 22: 295-303.
2. Sinha R, Sundaram M, Mahajan C, Raje S, Kadam P, et al. (2011) Laparoscopic myomectomy with uterine artery ligation: review article and comparative analysis. *J Gynecol Endosc Surg* 2: 3-10.
3. Holub Z (2008) Clinical experience and fertility outcome after uterine artery occlusion and embolization. *Gynecol Surg* 5: 7-14.
4. Saccardi C, Gizzo S, Noventa M, Ancona E, Borghero A, et al. (2014) Limits and complications of laparoscopic myomectomy: which are the best predictors? A large cohort single-center experience. *Arch Gynecol Obstet* 290: 951-956.
5. Sami Walid M, Heaton RL (2011) The role of laparoscopic myomectomy in the management of uterine fibroids. *Curr Opin Obstet Gynecol* 23: 273-277.
6. Litta P, Fantinato S, Calonaci F, Cosmi E, Filippeschi M, et al. (2010) A randomized controlled study comparing harmonic versus electrosurgery in laparoscopic myomectomy. *Fertil Steril* 94: 1882-1886.
7. Dubuisson JB (2006) [How I perform... a laparoscopic myomectomy]. *Gynecol Obstet Fertil* 34: 526-528.
8. Ananthakrishnan G, Murray L, Ritchie M, Murray G, Bryden F, et al. (2013) Randomized comparison of uterine artery embolization (UAE) with surgical treatment in patients with symptomatic uterine fibroids (REST trial): subanalysis of 5-year MRI findings. *Cardiovasc Intervent Radiol* 36: 676-681.
9. Valentin L, Canis M, Mage G, Bourdel N (2012) [How I do... a transient uterine artery occlusion by laparoscopy]. *Gynecol Obstet Fertil* 40: 623-624.
10. Bae JH, Chong GO, Seong WJ, Hong DG, Lee YS (2011) Benefit of uterine artery ligation in laparoscopic myomectomy. *Fertil Steril* 95: 775-778.
11. Ciavattini A, Tsiroglou D, Piccioni M, Lugnani F, Litta P, et al. (2004) Laparoscopic cryomyolysis: an alternative to myomectomy in women with symptomatic fibroids. *Surg Endosc* 18: 1785-1788.
12. Lipshutz B (1918) A COMPOSITE STUDY OF THE HYPOGASTRIC ARTERY AND ITS BRANCHES. *Ann Surg* 67: 584-608.
13. BORELL U, FERNSTROM I (1953) The adnexal branches of the uterine artery; an arteriographic study in human subjects. *Acta radiol* 40: 561-582.
14. Walocha JA, Litwin JA, Miodowski AJ (2003) Vascular system of intramural leiomyomata revealed by corrosion casting and scanning electron microscopy. *Hum Reprod* 18: 1088-1093.

15. Jin C, Hu Y, Chen XC, Zheng FY, Lin F, et al. (2009) Laparoscopic versus open myomectomy--a meta-analysis of randomized controlled trials. *Eur J Obstet Gynecol Reprod Biol* 145: 14-21.
16. Marret H, Chevillot M, Giraudeau B (2006) Study Group of the French Society of Gynaecology and Obstetrics (Ouest Division) Factors influencing laparoconversions during the learning curve of laparoscopic myomectomy. *Acta Obstet Gynecol Scand* 85: 324-329.
17. Seracchioli R, Rossi S, Govoni F, Rossi E, Venturoli S, et al. (2000) Fertility and obstetric outcome after laparoscopic myomectomy of large myomata: a randomized comparison with abdominal myomectomy. *Hum Reprod* 15: 2663-2668.
18. Vercellino G, Erdemoglu E, Joe A, Hopfenmueller W, Holthaus B, et al. (2012) Laparoscopic temporary clipping of uterine artery during laparoscopic myomectomy. *Arch Gynecol Obstet* 286: 1181-1186.
19. Kwon YS, Jung DY, Lee SH, Ahn JW, Roh HJ, et al. (2013) Transient occlusion of uterine arteries with endoscopic vascular clip preceding laparoscopic myomectomy. *J Laparoendosc Adv Surg Tech A* 23: 679-683.
20. Wang CJ, Yuen LT, Han CM, Kay N, Lee CL, et al. (2008) A transient blocking uterine perfusion procedure to decrease operative blood loss in laparoscopic myomectomy. *Chang Gung Med J* 31: 463-468.