

Hepatic, Pancreatic, and Renal Histo-Morphologic Alterations in Administration of Aqueous and Ethanol Seed Extract of *Buchholzia Coriacea* in Alloxan-Induced Diabetic Rats

Gbagbeke KO, Odigie OM* and Naiho AO

Department of Human Physiology, Faculty of Basic Medical Sciences, College of Health Sciences, Delta State University, Abraka, Delta State, Nigeria

Abstract

Physiologically, Insulin is a hormone that helps the body's cells to absorb glucose (sugar) so it can be used as a source of energy. In diabetics however, due to pancreatic production of insufficient amounts of insulin or failure of body's cells to respond to available insulin, blood and urine glucose levels build up to cause excessive urination, thirst, hunger, and problems with fat and protein break down. Recently, medicinal herbs have been implicated in traditional medical practice for the treatment of this ailment (Diabetes Mellitus, DM). Present study sought to investigate the effect(s) of oral administration of aqueous and ethanol extracts of *Buchholzia Coriacea* on the liver, pancreas and kidney in normal and alloxan-induced diabetic rats. Forty adult rats of both sexes were randomly assigned into two groups (normoglycemic and hyperglycemic). While group 1 (normoglycemic) had normal control, metformin, aqueous extract (250 mg/kg) and ethanol extract (250 mg/kg) treated sub-groups respectively, Group 2 (hyperglycemic) contained the diabetic control, metformin, aqueous extract (250 mg/kg), and ethanol extracted (250 mg/kg) treated sub-groups dosed daily by oral gavage for 14 days. At the end of treatment, rats were euthanized via cervical dislocation; with selected visceral (liver, pancreas and kidney) harvested and observed for histo-architectural changes. Blood samples were also collected and checked for sugar levels. Slight modulations were seen in the histo-morphology of the pancreas, liver and renal tissues as *Buchholzia Coriacea* apparently posed some hypoglycemic effects. Hitherto, there was an appreciable improvement and merit in the use of the extract in the management of diabetes across groups.

Keywords: *Buchholzia Coriacea*; Alloxan; Histo-architecture; Blood glucose

Introduction

Primarily, effect of insulin on glucose breakdown is to aid its efficient uptake and utilization by most cells of the body, except those of the brain [1,2]. Defects in insulin secretion or its action leads to an increase in blood glucose level with consequence in derangement of carbohydrate, protein and fat metabolism [3]. Diabetes is characterized by increased thirst, hunger and loss of weight [4,5]; resulting in chronic complications like macrovascular, microvascular, and neuropathic disorders [6]. Long term consequences of diabetes are diseases of the coronary arteries and cerebrovascular system; renal failure, neuropathy, retinopathy and premature death [4].

There is a rapid increase in the prevalence of diabetes globally and the World Health Organization (WHO) has predicted that by 2030 the number of adults with diabetes would have almost doubled globally, from 177 million in 2000 to 370 million [7]. According to Rowley et al., experts have estimated that the cases of adults with diabetes is set to increase rapidly by 64% by 2025, which means that a shocking 53.1 million people will be affected by the disease. The prevalence of diabetes among adults worldwide in 2010 was 285 million (6.4%) and this value is predicted to rise to around 439 million (7.7%) by 2030 [8].

In Nigeria, according to Olatunbosun et al, the prevalence of diabetes ranged from low level of 0.8% among adults in rural highland dwellers to over 7% in urban Lagos with an average of 2.2% nationally [9]. Despite the availability of several oral anti-hyperglycemic agents and insulin for the management of diabetes, there is still an increasing demand by sufferers to use herbal drugs even when their biologically active compounds are unknown due to their effectiveness, fewer side effects, and relative low cost [10]. This has prompted active research

efforts to provide a more effective, safer and cheaper alternative agent of plant origin that possess anti-hyperglycemic properties.

Buchholzia Coriacea (Wonderful kola) is an evergreen shrub belonging to the family Capparidaceae. It is found in many tropical countries like Ghana, Gabon, Cameroon, Central African Republic, Congo, Angola, Nigeria, among others [11]. Previous studies have shown that the ethanol extract of *Buchholzia Coriacea* elicit hypoglycemic effects that exhibits synergistic actions with the hypoglycemic agent metformin. Traditional medicine and scientific research on different parts of the plant has claimed that it is a valuable alternative therapy for treatment of Diarrhea [12], malaria [13], worm infection [14], rheumatism [15], diabetes [10], hypertension, psychiatric disorders, asthma and cough, impotence, among others.

Aim of Study

Study sought to investigate the effect of *Buchholzia Coriacea* (wonderful kola) seed extract on the histo-architecture of selected organs (liver, kidney and pancreas), in alloxan-induced diabetic wistar rats. Specifically, study:

*Corresponding author: Odigie OM, Department of Human Physiology, Faculty of Basic Medical Sciences, College of Health Sciences, Delta State University, Abraka, Delta State, Nigeria, E-mail: osgiedeprof@yahoo.com

Received May 07, 2018; Accepted May 18, 2018; Published May 24, 2018

Citation: Gbagbeke KO, Odigie OM, Naiho AO (2018) Hepatic, Pancreatic, and Renal Histo-Morphologic Alterations in Administration of Aqueous and Ethanol Seed Extract of *Buchholzia Coriacea* in Alloxan-Induced Diabetic Rats. Anat Physiol 8: 295 doi:10.4172/2161-0940.1000295

Copyright: © 2018 Gbagbeke KO, et al. This is an open-access article distributed under the terms of the Creative Commons Attribution License, which permits unrestricted use, distribution, and reproduction in any medium, provided the original author and source are credited.

- i. Examined the effect(s) of wonderful kola on blood glucose level
- ii. Determined the effect(s) of wonderful kola on body weight
- iii. Examined the effect(s) of wonderful kola on liver, pancreas, and renal histo-architectures

Methodology

Study design

Fourty rats, weighing an average of 128.6 g were divided into eight groups of five rats each as follows:

Normoglycemic groups

Normal control: neither given Alloxan monohydrate, nor administered with *Buchholzia Coriacea* extract. They received normal feed and water *ad libitum* for the duration of study.

Metformin (Normal rats): administered 50 mg/kg of Metformin

Aqueous extract (Normal rats): administered 250 mg/kg of aqueous *Buchholzia Coriacea* seed extract [11]

Ethanol extract (Normal rats): administered 250 mg/kg of ethanol extract from *Buchholzia Coriacea* seed

Diabetic groups

Diabetic Control (Diabetic rats): induced with DM from administration of 50mg/kg of Alloxan monohydrate. Neither treated with metformin nor *Buchholzia Coriacea* seed extract

Metformin (Diabetic rats): induced with DM from administration of 50 mg/kg Alloxan monohydrate. Treated with standard oral hypoglycemic drug, 50 mg/100 g BW of metformin

Aqueous extract (Diabetic rats): induced with DM from administration of 50 mg/kg Alloxan monohydrate and treated with 250 mg/kg of *Buchholzia Coriacea* seed aqueous extract

Ethanol extract (Diabetic rats): induced with DM from administration of 50 mg/kg Alloxan monohydrate and treated with 250 mg/kg of *Buchholzia Coriacea* seed ethanol extract

Preparation of Plant's extract

Fresh seeds of *Buchholzia Coriacea* were collected and identified by renown botanists from the Department of Botany, Faculty of Science, Delta State University, Abraka. The seeds were immediately cleaned off debris, peeled, chopped and shade-dried for one week in laboratory trays. The dried seeds were pulverized into powder with sterilized machine and weighed. 500 g of the powder was then divided into two equal parts and macerated in 4500 ml distilled water and 4500 ml of ethanol respectively, following intermittent shaking for 48 hours. Extract was then obtained with rotary evaporator (an electrical evaporator extraction apparatus). The solvent was extracted at temperature of 45°C and pressure of 60 mmhg of water. Paste-like extract was obtained and oven-dried to complete solid, then, grinded to smooth powdered form and stored in a refrigerator till use.

Procedure

Ethical clearance: Ethical clearance was obtained from the Research and Ethics Committee of the Faculty of Basic Medical Sciences, College of Health Sciences, Delta State University, Abraka, Delta State.

Acute toxicity test: Graded doses (250, 500, 1000, 2000, and

5000) mg/kg of the aqueous and ethanol extracts of wonderful kola was administered to the different groups orally. They were then observed for acute toxicity signs like behavioural changes or death over 24 h. though no deaths were recorded, dizziness was however observed at the dose of 2,000 and 5000 mg/kg body weight.

Sample collection: Blood glucose levels were checked every seven days (weekly), using the ACCUCHEK glucometer. To achieve this, blood sample was taken from tail vein of the rats on each occasion. After an overnight fast on the last day of the experiment, a final blood glucose check was done. Then rats were sacrificed by cervical decapitation and each rat was placed on its dorsal surface, and a laparotomy was carried out to expose the internal organs. Blood was collected by cardiac puncture, using 5 ml syringes and 21 G needle. Obtained blood samples were centrifuged at a rate of 4000 rpm for 10 minutes, and serum was collected and stored in a refrigerator at 4°C for analysis of the liver enzymes.

Inducing diabetes: To induce diabetes, Alloxan monohydrate was dissolved in 0.9% sodium chloride buffer (pH 7) intraperitoneally at a dose of 50 mg/kg body weight. Rats in control group were administered with equal volume of 0.9% sodium chloride, pH 7 (that was used to prepare the Alloxan monohydrate solution). Thereafter, rats were fed with normal feed and water. Three days (72 hours) after induction, diabetes was confirmed at a random blood glucose level of ≥ 200 mg/dl, using the ACCUCHEK glucometer.

Preparation of tissue for microscopic examination: The process of preparation of tissue for histological examinations was done for liver, kidney and pancreas; First, the tissues were processed by impregnating the specimen into embedding medium to provide support and suitable consistency for microtomy sectioning using different graded solutions of alcohol from 70% to 100% to dehydrate, them (tissues). Thereafter tissues were processed with paraffin wax, using an automatic tissue processor. Samples were then embedded in paraffin wax at 70 degrees centigrade and cut with a rotary microtone to 4 μ . The staining technique employed in this study was the haematoxylin and eosin staining techniques (Plates 1-24).

Photomicrography: Stained tissue images were captured with digital microscopic eyepiece 'Scoptek' Dcm 500, 5.0 mega pixels connected to USB 2.0 computer.

Statistical approach

Results were expressed as Mean \pm SEM (standard error of mean) and statistical significance of the treatment effect was analysed with one

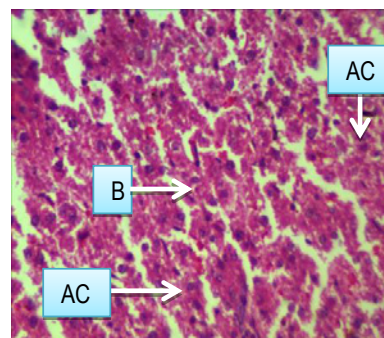


Plate 1: Coronary section of liver of normal control (rats normal control). H&E \times 400 magnification. **AC:** hepatocytes with oval nuclei and abundant cytoplasm. **B:** Congested sinusoids.

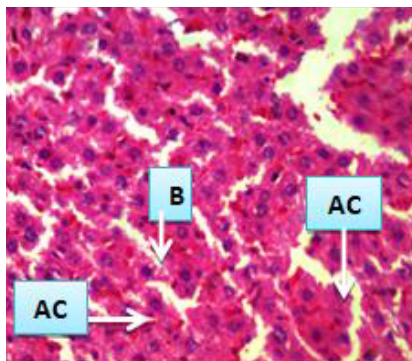


Plate 2: Coronary section of normal rats administered Metformin 50 mg/kg/bw/day (Metformin). H&E × 400 magnification. **AC:** hepatocytes with oval nuclei and abundant cytoplasm. **B:** Congested sinusoids.

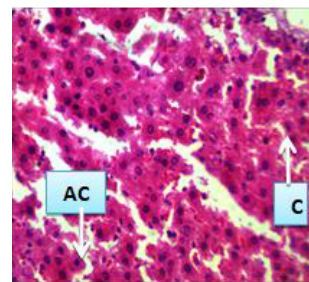


Plate 6: Coronary section of diabetic rats administered Metformin 50 mg/kg/bw/day. H&E × 400 magnification. **AC:** hepatocytes with oval nuclei and abundant cytoplasm. **C:** Lymphatic space.

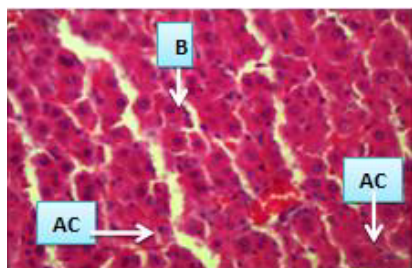


Plate 3: Coronary section of the liver of normal rats administered *Buchholzia Coriacea* seed 250 mg/kg/bw/day aqueous. H&E × 400 magnification. **AC:** hepatocytes with oval nuclei and abundant cytoplasm. **B:** Congested sinusoids.

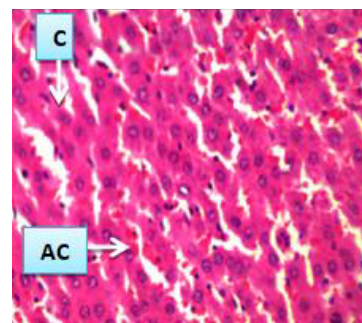


Plate 7: Coronary section of the liver of diabetic rats administered *Buchholzia Coriacea* seed 250 mg/kg/bw/day aqueous. H&E × 400 magnification. **AC:** hepatocytes with oval nuclei and abundant cytoplasm. **C:** Lymphatic space.

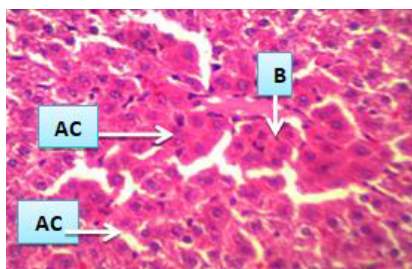


Plate 4: Coronary section of the liver of normal rats administered *Buchholzia Coriacea* seed 250 mg/kg/bw/day ethanol. H&E × 400 magnification. **AC:** hepatocytes with oval nuclei and abundant cytoplasm. **B:** Congested sinusoids.

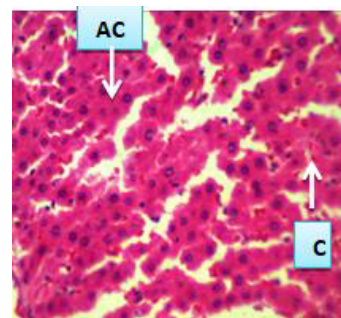


Plate 8: Coronary section of the liver of diabetic rats administered *Buchholzia Coriacea* seed 250 mg/kg/bw/day ethanol. H&E × 400 magnification. **AC:** hepatocytes with oval nuclei and abundant cytoplasm. **C:** Lymphatic space.

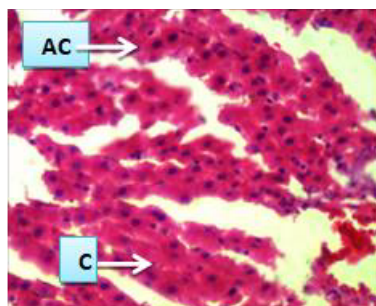


Plate 5: Coronary section of the liver of Diabetic rats Control. H&E × 400 magnification. **AC:** hepatocytes with oval nuclei and abundant cytoplasm. **C:** Lymphatic space.

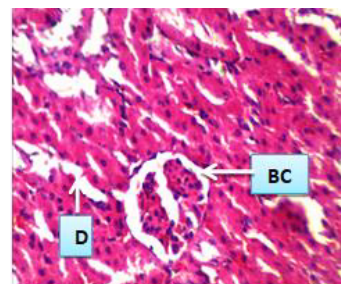


Plate 9: Coronary section of the kidney of normal control rats. H&E × 400 magnification. **BC:** Glomerulus. **D:** Renal tubules lined by single layer of endothelium.

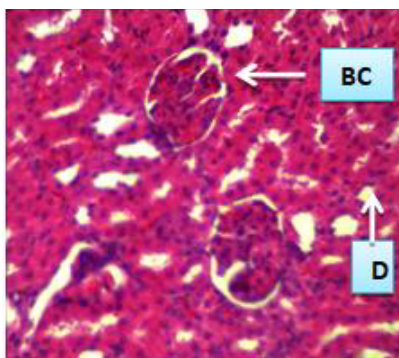


Plate 10: Coronary section of the kidney of normal rats administered Metformin 50 mg/kg/bw/day. H&E × 400 magnification. **BC:** Glomerulus. **D:** Renal tubules lined by single layer of endothelium.

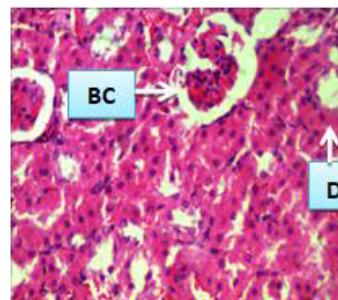


Plate 14: Coronary section of the kidney of diabetic rats administered Metformin 50 mg/kg/bw/day. H&E × 400 magnification. **BC:** Glomerulus. **D:** Renal tubules lined by single layer of endothelium.

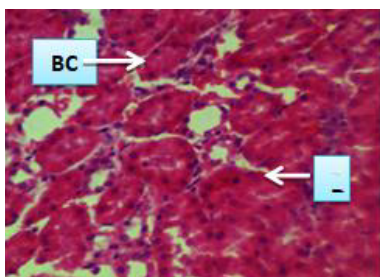


Plate 11: Coronary section of the kidney of normal rats administered *Buchholzia Coriacea* seed 250 mg/kg/bw/day Aqueous. H&E × 400 magnification. **BC:** Glomerulus. **D:** Renal tubules lined by single layer of endothelium

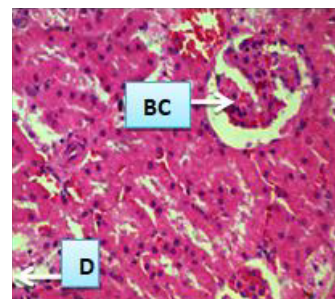

Plate 15: Coronary section of the kidney of diabetic rats administered *Buchholzia Coriacea* seed 250 mg/kg/bw/day Aqueous. H&E × 400 magnification. **BC:** Glomerulus. **D:** Renal tubules lined by single layer of endothelium.

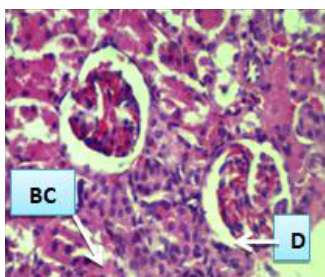


Plate 12: Coronary section of the kidney of normal rats administered *Buchholzia Coriacea* seed 250 mg/kg/bw/day ethanol. H&E × 400 magnification. **BC:** Glomerulus. **D:** Renal tubules lined by single layer of endothelium.

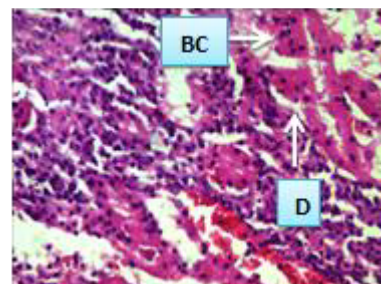


Plate 16: Coronary section of the kidney of normal rats administered *Buchholzia Coriacea* seed 250 mg/kg/bw/day ethanol. H&E × 400 magnification. **BC:** Glomerulus. **D:** Renal tubules lined by single layer of endothelium.

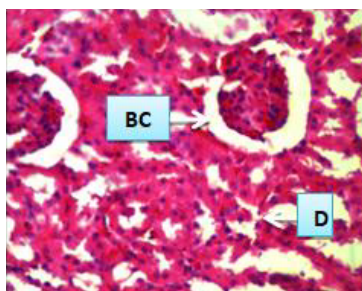


Plate 13: Coronary section of the kidney of diabetic control rats. H&E × 400 magnification. **BC:** Glomerulus. **D:** Renal tubules lined by single layer of endothelium.

Histology of the Pancreas

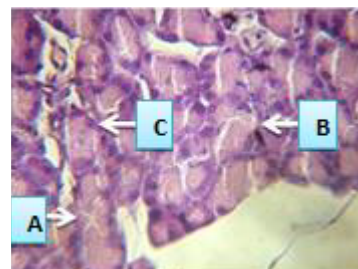


Plate 17: Coronary section of the pancreas of normal control rats. H&E × 400 magnification. **A:** Less karyolysis and improved islet cells with light hyaline changes in the majority of cells. **B:** Acinus. **C:** Intercalated duct.

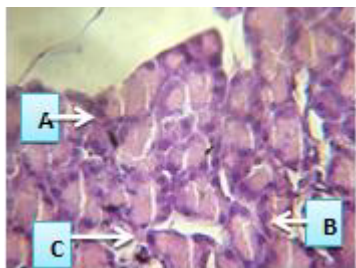


Plate 18: Coronary section of the pancreas of normal rats administered Metformin 50mg/kg/bw/day. H&E × 400 magnification. **A:** Less karyolysis and improved islet cells with light hyaline changes in the majority of cells. **B:** Acinus. **C:** Intercalated duct.

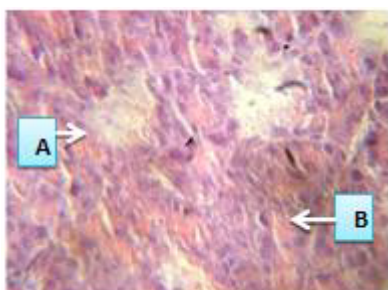


Plate 19: Coronary section of the pancreas of normal rats administered *Buchholzia Coriacea* seed 250 mg/kg/bw/day Aqueous. H&E × 400 magnification. **A:** Less karyolysis and improved islet cells with light hyaline changes in the majority of cells. **B:** Acinus.

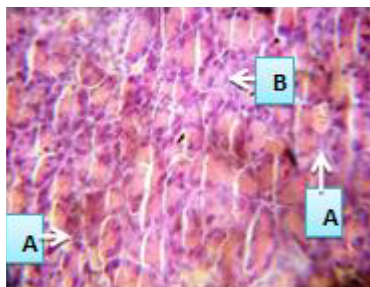


Plate 20: Coronary section of the pancreas of normal rats administered *Buchholzia Coriacea* seed 250 mg/kg/bw/day Aqueous. H&E × 400 magnification. **A:** Less karyolysis and improved islet cells with light hyaline changes in the majority of cells. **B:** Acinus.

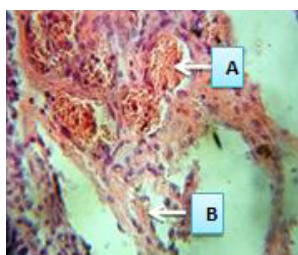


Plate 21: Diabetic control rats. H&E × 400 magnification. **A:** Islets with irregular outline decrease populated cells and homogenization of the center, some islet-cells showing pyknotic nuclei, ballooning of cells and vacuolated cytoplasm. **B:** Pyknotic nuclei of some acinar cells with severely damaged vacuolated acini.

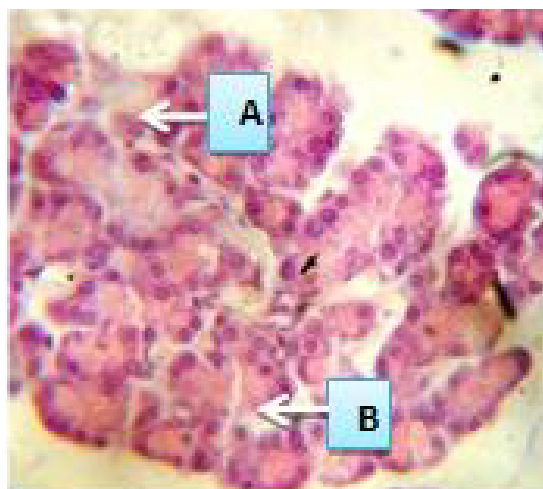


Plate 22: Diabetic rats treated with Metformin 50 mg/kg. H&E × 400 magnification. **A:** Less karyolysis and prominent islet cells appeared with mild enlargement in size and displayed increase in size and light hyaline changes in the majority of cells. **B:** Improved pyknotic nuclei of some acinar cells with severely damaged vacuolated acini.

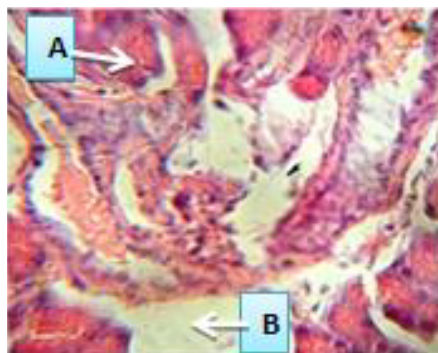


Plate 23: Diabetic rats treated with 250 mg/kg of *Buchholzia Coriacea* seed aqueous H&E × 400 magnification. **A:** Less karyolysis and prominent islet cells appeared with mild enlargement in size and displayed increase in size and light hyaline changes in the majority of cells. **B:** Improved pyknotic nuclei of some acinar cells with severely damaged vacuolated acini.

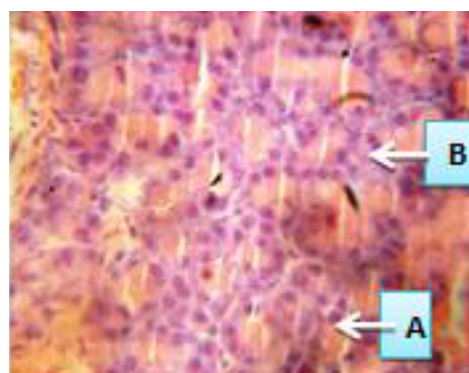


Plate 24: Diabetic rats treated with 250 mg/kg of *Buchholzia Coriacea* seed ethanol. H&E × 400 magnification. **A:** Less karyolysis and prominent islet cells appeared with mild enlargement in size and displayed increase in size and light hyaline changes in the majority of cells. **B:** Improved pyknotic nuclei of some acinar cells with severely damaged vacuolated acini.

way analyses of variance (ANOVA), followed by post Hoc LSD's test for multiple comparison, using software social science (SPSS) version 22. P-values <0.05 were considered to be statistically non-significant.

Results

See Figures 1 and 2 for results.

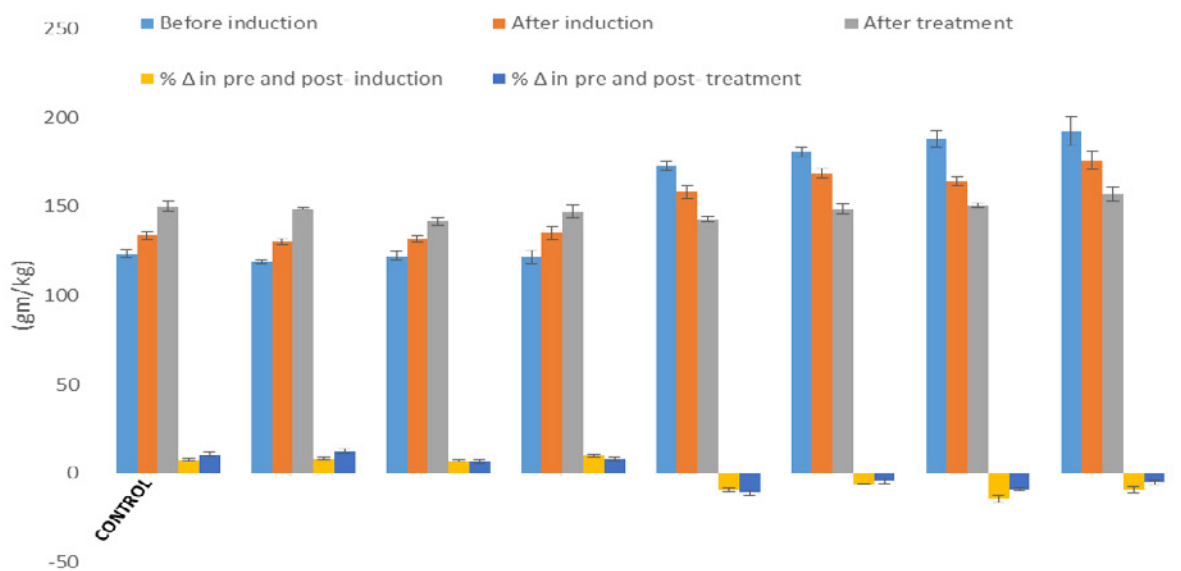


Figure 1: Showing body weights of normal and diabetic rats before induction and after of treatment. Values are expressed as mean \pm SEM. ANOVA followed by LSD's multiple range tests. Values not sharing a common superscript differ significantly at $P < 0.05$

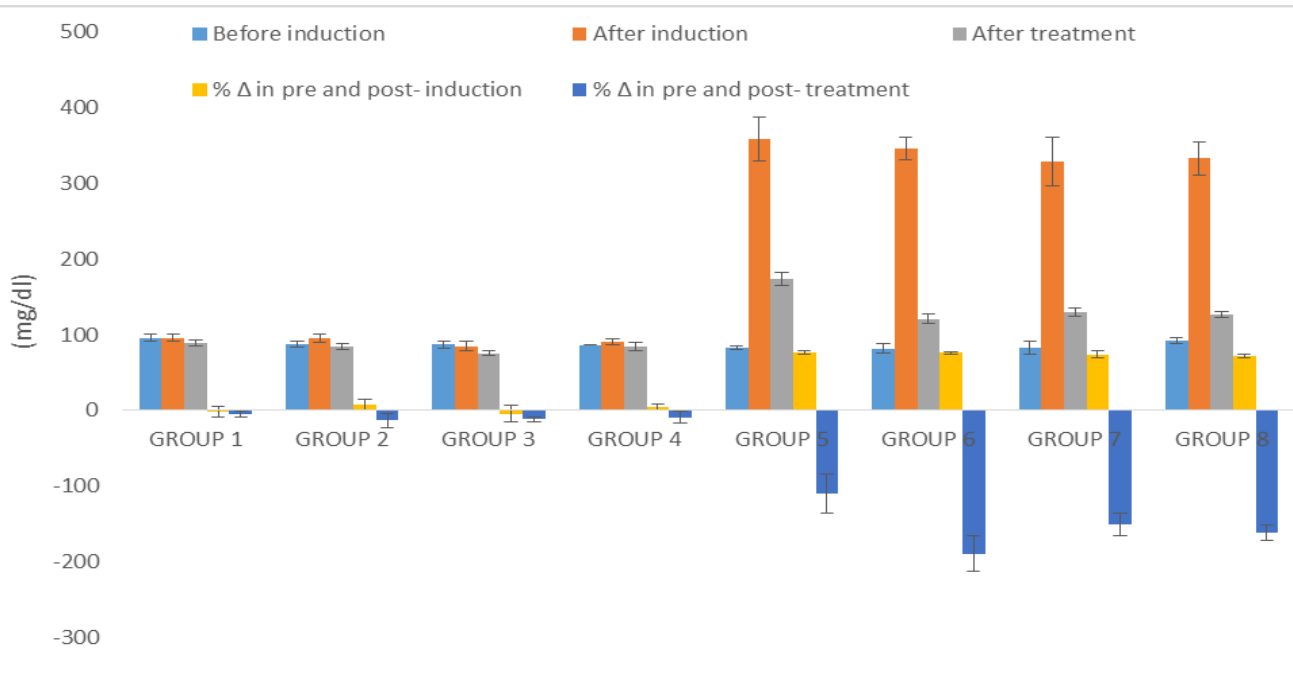


Figure 2: Changes in glucose levels of normal and diabetic rats administered with Metformin 50 mg/kg and aqueous 250 mg/kg and ethanol 250 mg/kg extracts of Wonderful Kola. Values are expressed as mean \pm SEM. ANOVA followed by LSD's multiple range tests. Values not sharing a common superscript differ significantly at $P < 0.05$ (*= $p < 0.001$; a= $p < 0.005$; b= $p < 0.05$)

Discussion

Numerous advantageous effects of *Buchholzia coriacea* seed extracts have been identified in literatures, earning it the name “wonderful kola [16,17].

The body weight of normal and diabetic rats before induction and after of treatment is shown in Figure 1. There was a significant elevation in the body weight of normal control rats when compared baseline (0 day before induction) body weight to final (day 14 after treatment). The administration of Metformin (50 mg/kg) and aqueous 250 mg/kg and ethanol 250 mg/kg extracts also showed moderate increase ($p>0.05$) in the body weight of normal rats as compared to day 0 and day 14 after treatment. There was a significant ($p<0.05$) reduction in the body weight of rats in diabetic control group when compared baseline (0 day after induction) body weight to final (day 14 after treatment). The treatment with Metformin (50 mg/kg) and aqueous 250 mg/kg and ethanol 250 mg/kg extracts showed a significant decrease in the body weight of diabetic rats as compared baseline (0 day after induction) body weight to final (day 14 after treatment). There was no significant difference ($p>0.05$) in the body weight of normoglycemic treated groups when compared with the normoglycemic control group (normal control) before induction and after treatment. A mild decrease ($p<0.05$) in metformin diabetes treated group, aqueous extract diabetes treated group and ethanol extract diabetes treated group when compared to the diabetes control group

Figure 2 shows changes in glucose levels of normal and diabetic rats administered with Metformin (50 mg/kg) and aqueous 250 mg/kg and ethanol 250mg/kg extracts in. Here, there was a mild change in fasting blood glucose level in normal control rats when compared with baseline (0 day before induction) body weight to final (day 14 after treatment). There was also a mild but not significant ($p>0.05$) decrease in the metformin normoglycemic treated group, AEBC normoglycemic treated group and EEBC normoglycemic treated group when compared to the normal control group after day 14 treatment. The administration of Metformin (50 mg/kg) and aqueous 250 mg/kg and ethanol 250mg/kg extracts also shows mild alteration ($p>0.05$) in the fasting blood glucose level of normal rats after day 14 treatment as compared to day 0. Findings from this study showed a significant ($p<0.05$) increase in the glucose level of diabetic rats when compared to glucose level of the rats at the commencement (0 day before induction) fasting blood glucose level to day 4 (after induction) of the experiment ranging from 72.04 to 76.43%.

It was also observed that the values of glucose level of the diabetic rats treated with Metformin (50mg/kg) and aqueous 250 mg/kg and ethanol 250mg/kg extracts were not up to the glucose level of diabetic control rats. Despite this, there was statistical significance ($p<0.05$) in percentage changes between Metformin (50mg/kg) and aqueous ethanol (250mg/kg) extracts. The metformin treated group showed more effect ($-189.60 \pm 23.36^{\circ}\text{c}$), followed by ethanol extract treated group ($-161.96 \pm 9.81^{\circ}\text{a}$) and aqueous extract treated group ($-151.10 \pm 14.92^{\circ}\text{a}$) when compared to diabetic control rats (-109.78 ± 26.33).

Relevance of Study

Since diabetes became a global monster to earthlings, any study that is directed towards its amelioration is not only Jermaine, but hugely recommended. This study will provide basic information on histologic changes in pancreas, liver, and kidneys; being the major organs that directly or indirectly part-take in glucose homeostasis as a result of graded-dose use of *Buchholzia coriacea* seed extracts. This

implies that administration of this extract with dose and administration duration considered will be of scientific merit in the folkloric use of the extract for management of this ailment.

Conclusion

Administration of aqueous and ethanol seed extract of *Buchholzia coriacea* for treatment of Alloxan-Induced diabetic rats modulated key carbohydrate metabolic enzymes, resulting in normal blood glucose homeostasis. This implies that administration of this extract with dose considered and the duration of administration has anti-hyperglycemic and glycolytic effects with adverse effects on liver and kidney functions. Thus, there could be scientific merit in the folkloric use of the extract in the management of diabetes.

Recommendations

Being just a preliminary work, we recommend further study on this, however with more sophisticated and high-tech stains/equipment that can reveal deeper tissue structures and cellular components.

References

1. Hu FB, Stampfer MJ, Solomon CG, Liu S, Willett WC, et al. (2001) The impact of diabetes mellitus on mortality from all causes and coronary heart disease in women: 20 years of follow-up. *Arch Intern Med* 161: 1717-1723.
2. El-Shenawy NS, Abdel-Nabi IM (2006) Hypoglycemic effect of *Cleome Droserifolia* ethanolic leaf extract in experimental diabetes and on non-enzymatic anti-oxidant, glycogen, thyroid hormone and insulin levels. *Diabetol Croatica* 35: 15-22.
3. Nayak BS, Roberts L (2006) Relationship between inflammatory markers, metabolic and anthropometric variables in the Caribbean type 2 diabetic patients with and without microvascular complications. *J of Inflammation* 3: 17.
4. Rang HP, Dale MM, Moore JM, Ritter PK (1999) The endocrine pancreas and the control of blood glucose, 5th edn. Livingston publication, London; pp: 380-393.
5. Rang HP, Dale MM, Moore JM, Ritter PK (2009) The endocrine pancreas and the control of blood glucose, 7th edn. Livingston publication, London; pp: 380-393.
6. Triplitt CL, Reasner CA, Isley WL (2005) Diabetes mellitus In: Pharmacotherapy; A pathophysiological approach 6th edn. Dipro JT, Talbert RL, Yee GC, Matzke GR, Posey ML, eds. McGraw- Hill Companies Inc, New York; pp: 1333-1356.
7. Rowley WR, Bezold C (2012) Creating public awareness: State 2025 diabetes forecasts. *Popul Health Manag* 15: 194-200.
8. Shaw JE, Sicree RA, Zimmet PZ (2010) Global estimates of the prevalence of diabetes for 2010 and 2030. *Diabetes Res Clin Pract* 87: 4-14.
9. Olatunbosun ST, Ojo PO, Fineberg NS, Bella AF (1998) Prevalence of diabetes mellitus and impaired glucose tolerance in a group of urban adults in Nigeria. *J Natl Med Assoc* 90: 293-301.
10. Ezeigbo II (2010) Anti-diabetic potential of methanolic leaf extracts of *Icacina trichanthain* Alloxan-diabetic mice. *Int J Diab Dev Countr* 30: 150-152.
11. Theophine CO, Peter AA, Chinenye L, Adaobi CE, Collins AO (2012) Anti-diabetic effects of methanol extract of the seeds of *Buchholzia Coriacea* and its synergistic effects with metformin. *Asian J Biomed Pharm Sci* 2: 32-36.
12. Chinedu FA, Chibeze I, Emma E, Chukwuenweiwe E (2012) The phytochemical, antispasmodic and anti-diarrhoea properties of the methanol extract of the leaves of *Buchholzia coriacea* family capparaceae. *Int J Curr Pharm Res* 4: 340-345.
13. Okoli BJ, Okere OS, Adeyemo SO (2010) The antiplasmodial activity of *Buchholzia Coriacea*. *J Med Appl Biosci* 2: 21-29.
14. Ajaiyeoba EO, Onocha PA, Olanrewaju OT (2001) In vitro anti-helminthic properties of *Buchholziacoriacea* and *Gynandropsisgynandra*. *Pharm Biol* 39: 217-220.
15. Ezeja MI, Ezeigbo II, Madubiike KG (2011). Analgesic activity of the methanolic seed extract of *Buchholzia coriacea*. *Res J Pharm Biol Chem Sci* 2: 187-193.

16. Adisa RA, Choudhary MI, Olorunsogo OO (2011) Hypoglycemic activity of *Buchholzia coriacea* (Capparaceae) seeds in streptozotocin-induced diabetic rats and mice. *Exp Toxicol Pathol* 63: 619-625.
17. Mbata TI, Duru CM, Onwumelu HA (2009) Antibacterial activity of crude seed extracts of *Buchholzia coriacea* on some pathogenic bacteria. *J Dev Biol Tissue Eng* 1: 001-005.