

# Healing Effect of *Moringa oleifera* Lam against UV-B Induced Psoriasis form Changes in Rats

Dilawar S<sup>\*</sup>, Shah A, Hussain S, Sajjad M and Khan S

Department of Science and Technology, Bannu University, Pakistan

\*Corresponding author: Dilawar S, Department of Science and Technology, Bannu University, Pakistan, Tel: 923329745778; E-mail: dshdilawar@yahoo.com

Received date: Jan 29, 2017; Accepted date: Feb 13, 2017; Published date: March 02, 2017

Copyright: © 2017 Dilawar S, et al. This is an open-access article distributed under the terms of the Creative Commons Attribution License, which permits unrestricted use, distribution, and reproduction in any medium, provided the original author and source are credited.

## Abstract

*Moringa oleifera* extracts have been used in herbal medicines by various communities in different parts of the world. It is a multipurpose tree with a magnificent profile of medicinal uses, high nutritional values and pharmacological activities. Various parts of this plant such as the flower, seed, immature pod, stem bark, leaf and root, possesses anti-oxidant, anticancer, antimicrobial, anti-ulcer, anti-hepatotoxic, antihypertensive, anti-hyperlipidemia, antidiabetic, antispasmodic, antiepileptic, antipyretic, anti-inflammatory and analgesic properties. An attempt was made to evaluate the healing properties of the methanolic extract of different aerial parts of *Moringa oleifera* against UV-B induced psoriasis form changes in rats. Irradiated rats were divided into 8 groups (6 rats/groups). The first group left untreated served as a control were given normal lab feed and a second group which served as the standard was administered retinoic acid (0.5 mg/kg) orally. Group III to Group VIII were administered orally with the methanolic extracts from aerial parts of *M. oleifera* (200 mg/kg bw) and (400 mg/kg bw). Data collected in this study was analyzed using statistical package for social sciences (SPSS) version 16. There was a significant difference ( $P < 0.05$ ) in epidermal thickness of control and drugs treated group. The methanolic extracts from aerial parts of *M. oleifera* used for treatment, enhanced fibroplasia, reduced inflammation and produced high amounts of scar tissue and enhanced the rate of wound healing and re-epithelisation compared to control. The plant extracts were effective against psoriasisform changes in rats. Though, more studies are required to assess which of its known ingredients are responsible for the antipsoriatic effects. The constituents of *M. oleifera* should be considered for further studies.

**Keywords:** Anti-psoriatic; flavonoids; *Givotia rottleriformis*; UV-B photodermatitis model

## Introduction

Psoriasis is a chronic skin disease which is characterized by the presence of papules and plaques, which are well defined, erythematous and scaly. Global prevalence of psoriasis varies from 1-2% indicating that it is a common dermatosis [1-3]. It is a multifactorial immunologic disease in which patients inherit the predisposition to develop psoriasis [4]. Psoriasis is characterized by hyperproliferation and abnormal differentiation of epidermal keratinocytes, infiltration by T-lymphocytes [5]. The exact cause of psoriasis is still unknown [6-9]. Systemic and topical treatments are frequently available for psoriasis, but these treatments have unpredictable efficiency and often cause side effects. Topical treatments are the standard set of treatment regimens including emollients, tar, dithranol, retinoids and glucocorticoids. Amongst these the last one is most frequently used in clinical practices [10]. The glucocorticoids are relatively successful in producing a desired result, but on the other hand, its long term use may lead to cutaneous atrophy and its discontinuation may result in a relapse of the disease [11]. Similarly systemic conventional treatments which involve long term use of oral retinoid cause teratogenicity, methotrexate cause hepatotoxicity; cyclosporine and PUVA cause cancer and nephrotoxicity [12]. Biologic products are usually safe and tolerable. But, like all medications, they have side effects and can prone the patients to infections and increased their risk of developing a malignancy [13-16].

Traditional plants are important resources of conventional medicines used against various ailments. Scientists are trying to establish a link between phytochemical constituents with their pharmacological activities. In different studies phytochemicals such as glycosides, terpenoids, alkaloids, flavonoids and lignins, are identified scientifically for its anti-psoriatic activity [17,18].

Traditional plants are acknowledged to be a rich source of variety of chemical compounds and have appealed researcher's attention to find new treatment for psoriasis [19]. *Moringa oleifera*, a tree belonging to the Moringaceae family, is native to the southern foothills of the Himalayas and is now cultivated in practically all tropical, subtropical and semi-arid regions of the world. It is known by different vernacular names, such as marango, moringa, reseda, radish tree, tree of the stick, angel, asparagus tree, pear tree, ben tree, tree of life and tree of miracles [20]. This last name is a measure of the importance of this plant to solve health problems that might otherwise be considered incurable. For millennia, virtually all parts of *M. oleifera* have been used by the man. In many tropical countries it is difficult to differentiate between food and medicinal uses of *M. oleifera*, since it is used both for its nutritional qualities and for its medical attributes, which have been recognized for millennia. In India, Ayurvedic medicine contemplated the use of this plant to prevent, mitigate or cure 'more than 300 diseases'. It is said that leaves, fruits, roots and seeds are useful to combat anaemia, anxiety, asthma, paralysis attacks, bronchitis, catarrh, cholera, chest congestion, conjunctivitis, sperm deficiency, milk deficit in lactating mothers, diabetes, Diarrhoea, erectile dysfunction, joint pain, headaches, sore throat, scurvy, sprains, blackheads, lack of female sexual desire, fever, gonorrhoea, glandular swelling, hypertension, hysteria, impurities in the blood, Sores,

malaria, otitis, intestinal parasitism, poisonous Erectile dysfunction, joint pain, headaches, sore throat, scurvy, sprain, blackheads, lack of female sexual desire, fever, gonorrhoea, glandular swelling, hypertension, hysteria, blood impurities, skin infections, Malaria, otitis, intestinal parasitism, venomous stings, bladder and prostate problems, psoriasis, respiratory disorders, cough, tuberculosis, abdominal tumours, ulcers [20].

The presence of important phytochemicals in *M. oleifera* is responsible for their healing properties have recently been demonstrated. In one of the first exhaustive studies on the chemical composition of this species, it was found to be rich in several very peculiar substances, such as glucosinolates, isothiocyanates, flavonoids, anthocyanins, proanthocyanidins and cinnamates [21]. The distribution of phytochemicals was also included in the different parts of the tree. This characteristic could be advantageous for the treatment of multi-causal diseases, such as psoriasis.

In view of the importance of this plant, an effort was made to investigate the phytochemical screening and healing activity of *M. oleifera* leaves, bark, fruit, flower, seed and stem, obtained from different regions of Pakistan. No systematic study to date has examined the healing activity of the extracts of *M. oleifera* aerial parts. The present study sought to establish the scientific validity for the healing effect of *M. oleifera* extract on UV induced psoriasiform changes in experimental rats. This study will be the first in Pakistan to deal with the healing activity of *M. oleifera* extracts on UV induced psoriasiform changes in rats.

## Materials and Methods

### Sampling

Aerial parts of *Moringa oleifera* were collected from different regions of Pakistan and the herbarium specimens were subjected to analysis in Quaid-e-Azam University, Islamabad Pakistan. Plant samples were identified by (Plant taxonomist) Department of plant Sciences, Quaid-e-Azam university, Islamabad (Voucher Specimen No. ISL 1367).

### Sample preparation

The freshly collected different aerial parts of *M. olifera* were washed with distilled water and dried at 40°C. The dried samples were extracted with methanol. The extracts were filtered through Whatman filter paper I and then concentrated on rotary evaporator model (Eyela Tokyo Rikakikakki Co. Ltd., Japan) at 45°C. Dried samples were kept at 4°C till used for the assay. The extracts were solubilised and diluted with sterile water to get the desired concentration. The prepared extracts were analyzed for phytochemical screenings by standard methods (Table 1) [22,23].

### Photo dermatitis model for psoriasis

The dorsal skin of the rat after depilating was irradiated with UV-B radiation using Photo dermatitis Model for Psoriasis. The initial lesions (erythema) appeared instantly after irradiation that disappeared after 30 min. The second phase of erythema (aggressive lesions) started after 6 hrs and progressively become swollen between 24 and 48 hrs. The reaction was restricted only to the exposed area and later on an erythematous ulcerated lesions with crust formation developed. After 48-72 hrs silvery white scale appeared on the erythematous lesion.

Different stages of skin lesion in irradiated area of rat skin are shown in figure.

Phytochemicals	Leaf	Stem	Bark	Flower	Fruit	Seed
Alkaloids	+	+	+	+	+	+
Flavonoids	++	+	++	+	+	+
Phenolics compounds	++	+	++	+	+	+
Saponin	+	+	+	+	+	+
Terpenoids	-	+	+	+	+	-
Carbohydrates	+	+	-	+	+	+
Protein and amino acids	++	+	+	+	+	+
Reducing sugars	++	++	++	+	+	++
Cardiac glycoside	++	+	+	+	+	++
Steroids	+	-	-	+	+	++

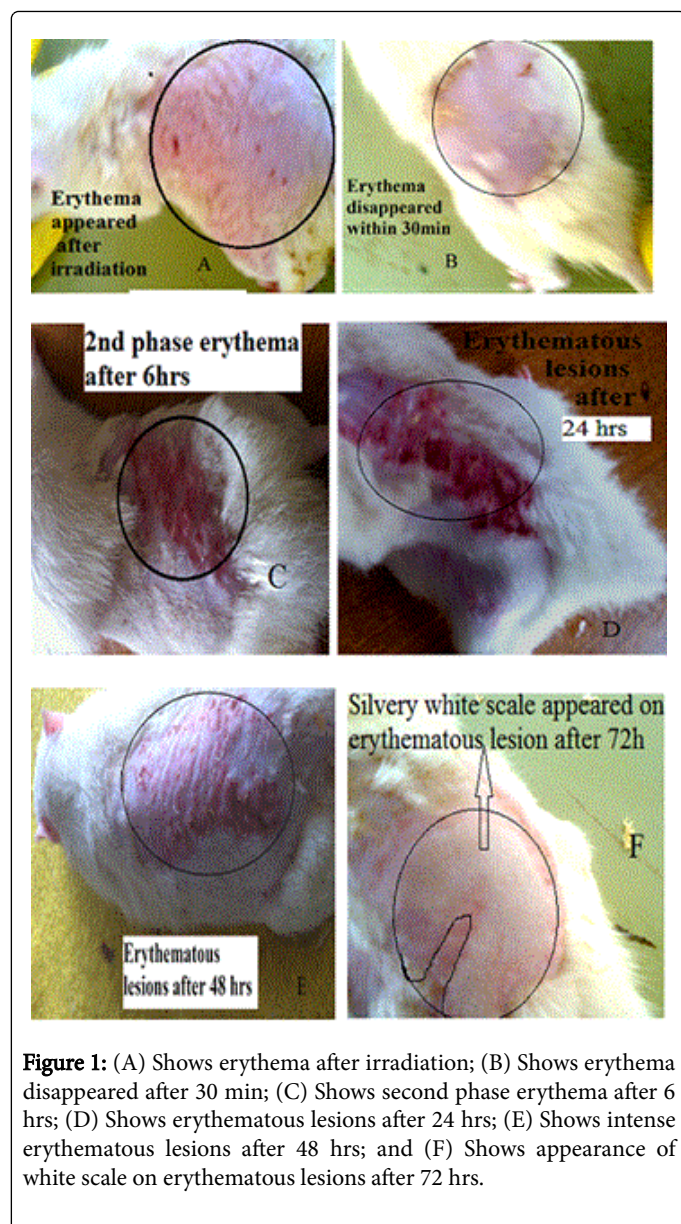
**Table 1:** Qualitative analysis of phytochemicals from aerial parts of *Moringa oleifera*.

### Acute toxicity

The Institutional Animal Ethics Committee (IAEC) approved the protocol. In this test, five male rats were used. The methanolic extract of leaf, bark, stem, flower and fruit being tested is given to them orally and were observed for mortality. No mortality was observed in rats treated with 2000 mg/kg of methanolic extracts. All the rats were normal and no unpleasant behavioral changes were observed till the end of the study period.

### Assortment of animals

Sprague-Dawley Albino rats (male, 245 g) were selected for experiment, were housed in the animal house department of National Institute of Health Islamabad. 3 animals were kept per cage and rice husk was used as a bedding material. They were sustained on standard conditions of temperature (25°C) humidity (50%) and photoperiod (12 hrs). Rats were fed under standard laboratory feed and water ad libitum. The animals were accustomed to the laboratory conditions for at least one week prior to dosing. 48 male albino rats were divided into 8 groups (6 animals/group) were exposed to UVB radiation. The hairs on the dorsal part of the body were shaved by electrical shaver taking measure to prevent skin from injury. To prevent their movement rats were then placed in a rectangular wooden restrainer of the size 80 × 40 × 25 cm during exposure to UV radiation. The shaved area of the dorsal skin 1.5 × 2.5 cm was exposed to UVB radiation (290-320 nm); while the whole body of animal was covered with a UV-resistant foil. The exposed area of 1.5 × 2.5 cm was then irradiated for 45 min with a UV-B lamp model No. SP-600 Toyo Seisakusho Co. Ltd., Japan was kept at a vertical distance of 20 cm from the rat skin.



### Administration of the drug

The irradiated rats were divided into 8 groups (6 rats/ group). The first group served as control. The second group served as standard was administered retinoic acid (0.5 mg/kg) orally. Group 3 to 8 were administered orally with the methanolic extracts of aerial parts of *Moringa olifera*. Group's (3A and 3B) were administered orally 200 mg/kg (body weight) and 400 mg/kg (body weight) methanolic extract of MOL. Group's (4A and 4B) were administered orally 200 mg/kg bw and 400 mg/kg bw methanolic extract of MOB. Group's (5A and 5B) were administered orally 200 mg/kg bw and 400 mg/kg bw methanolic extract of MOFr. Group's (6A and 6B) were administered orally 200 mg/kg bw and 400 mg/kg bw methanolic extract of MOFl Group's (7A and 7B) were administered orally 200 mg/kg bw and 400 mg/kg bw methanolic extract of MOSe Group's (8A and 8B) were administered 200 mg/kg bw and 400 mg/kg bw methanolic extract of MOST once daily, 6 times a week, for one month. Animals were anaesthised under

ether anesthesia after last dose, and longitudinal sections of the dorsal skin was cut open by surgical incision and were preserved in 10% buffered formalin solution. By using hematoxylin-eosin staining techniques sections of the skin were prepared for histological results by light microscopy at a magnification of  $4 \times 10$  using Olympus microscope and then examined for the characteristics features of psoriasis i.e., epidermal thickness, presence of Munro's micro abscess, rete ridges elongation and capillary loop proliferation and dilation.

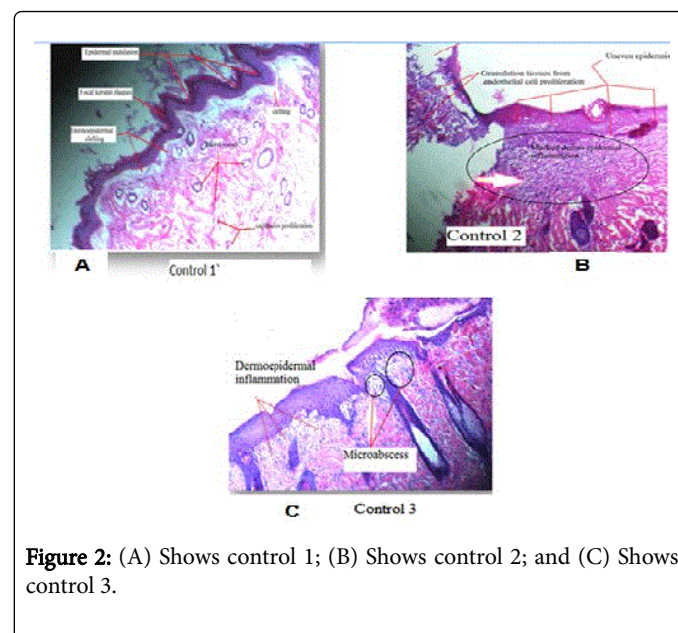
### Statistical analysis

Data collected in this study was analyzed using statistical package for social sciences (SPSS) version 16. Statistical calculations were done using Graph Pad Prism software. P-value <0.05 was considered as significant.

### Results

#### Histopathology

The characteristic features were observed in the UV irradiated rat skin shown in Figure 2A-2C. Figure 2A (control 1) reveals focal keratin plaques, epidermal undulation, dermoepidermal clefts formation, prominent dermal capillaries. Figure 2B (Control 2) shows formation of bullous granulation tissue with endothelial cell proliferation, marked dermoepidermal inflammation and uneven thickness of epidermis. Figure 2C (Control 3), shows dermoepidermal inflammation, microabscess formation with spongiosis.



#### Histopathological results of the treated rats groups

In case of standard group shown in Figure 3A, the characteristics histopathological changes i.e., Munro's microabscess, capillary proliferation and dilation along with elongation of epidermal rete ridges in the sections were absent, only slightly thinned out epidermis is there, whereas the following changes were noted having good therapeutic effects.

In case of leaf extract treated group shown in Figure 3B, there occurred healing of lesion like dermal scarring (fibroblastic proliferation), epidermal reepitheliasation and epidermal clefting artifact. All these changes favours healing process of leaf extract treatment for the induced psoriasiform changes in rats.

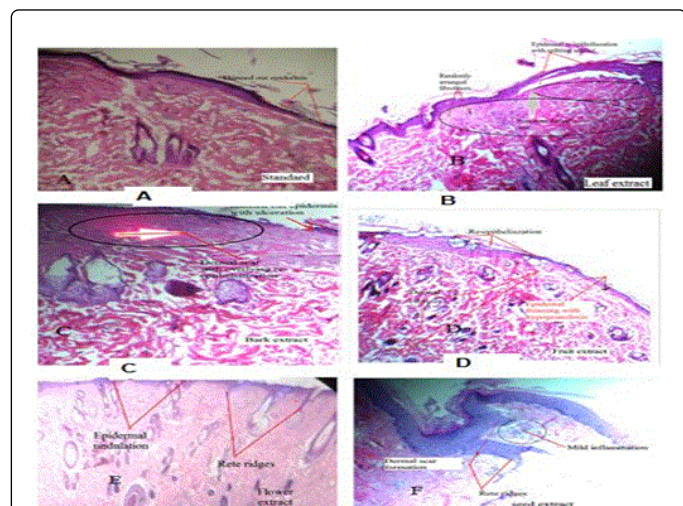
In case of bark extract treated group shown in Figure 3C, only thinned out epidermis with mild inflammation was seen as well as dermal scar with overlying re-epithelization were noted.

In case of fruit extract treated group shown in Figure 3D, histological findings showed Epidermal thinning with hypogranulosis and associated parakeratosis, dermal fibrosis with entrapped adnexae, epidermal re-epithelialization with splitting artifact and Prominent dermal scar with randomly arranged fibroblasts.

In case of flower extract treated group shown in Figure 3E showed epidermal undulation, mildly elongated rete ridges and dermoepidermal inflammation. The overall therapeutic effect is mild to moderate.

In case of seed extract treated group shown in Figure 3F, low grade inflammatory changes with decrease in elongation of rete ridges, Munro's microabscess as well as other characteristics features of psoriasis were either absent or minimum showing mild therapeutic effects of the psoriasiform changes.

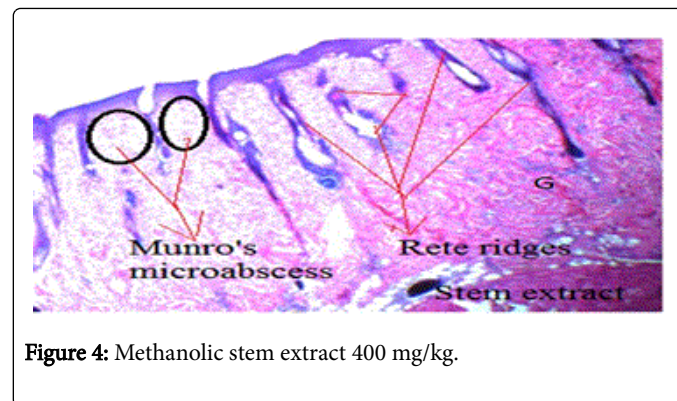
In case of stem extract treated group shown in Figure 4, thinned out epidermis with elongated rete ridges and Munro's micro-abscess showed a very minor therapeutics effects as compared to other extracts. The efficacies of the different extracts are in the range of Standard>leaf extract>bark extract>flower extract>fruit extract>seed extract>stem extract>control.



**Figure 3:** (A) Standard retinoic acid 0.5 mg/kg; (B) Methanolic leaf extract 400 mg/kg; (C) Methanolic bark extract 400 mg/kg; (D) Methanolic fruit extract 400 mg/kg; (E) Methanolic flower extract 400 mg/kg; (F) Methanolic seed extract 400 mg/kg.

Epidermal thickness in normal, standard and extract treated groups shown in Figures 5-7. Figure 5A Normal rat skin ( $12.3333 \pm 2.516 \mu\text{m}$ ); 5B Control ( $60 \pm 10 \mu\text{m}$ ); 5C Standard ( $17.666 \pm 2.51 \mu\text{m}$ ) Figure 6A Leaf extract ( $19 \pm 3.60 \mu\text{m}$ ); 6B Bark extract ( $20 \pm 2 \mu\text{m}$ ); 6C Flower extract ( $24 \pm 1 \mu\text{m}$ ); Figure 7A Fruit extract ( $21 \pm 4.58 \mu\text{m}$ ); 7B Seed extract ( $23.33 \pm 1.52 \mu\text{m}$ ); 7C Stem extract ( $27.33 \pm 3.05 \mu\text{m}$ ). The mean

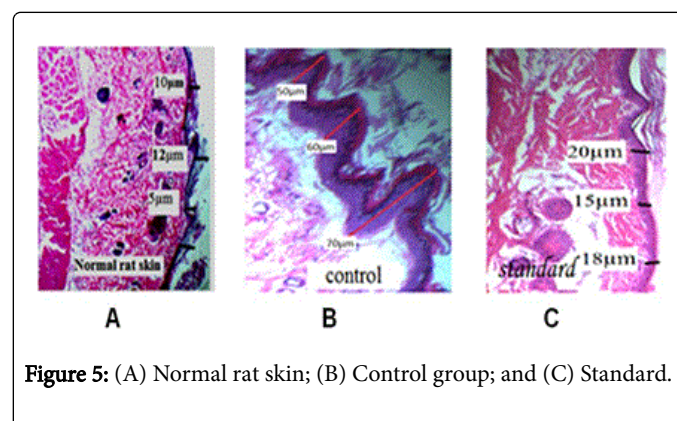
epidermal thickness of the normal, control and treatment groups were compared shown in Figures 5-7; Table 2 showing significant difference ( $P < 0.05$ ) in epidermal thickness of normal, control and drugs treated group.



**Figure 4:** Methanolic stem extract 400 mg/kg.

Groups	Treatment	Epidermis thickness ( $\mu\text{m}$ )
Normal	-	$12.3333 \pm 2.516$
Positive control	-	$60 \pm 10$
Standard	Retinoic acid 0.5% mg/kg bw	$17.666 \pm 2.51$
4B(Leaf)	Met extract of MOL 400 mg/kg bw	$19 \pm 3.60$
5B (Bark)		$20 \pm 2$
6B (Fruit)		$21 \pm 4.58$
7B (Flower)		$24 \pm 1$
8B (seed)		$23.33 \pm 1.52$
9B (Stem)		$27.33 \pm 3.05$

**Table 2:** Comparison of epidermal thickness (corneum stratum) in normal, control and drug treated animals.



**Figure 5:** (A) Normal rat skin; (B) Control group; and (C) Standard.

## Discussion

The study aimed to investigate the healing efficiency of methanolic extracts of *Moringa oleifera* on UV induced psoriasiform changes in a rat model in comparison with that of standard retinoic acid. The

evaluation of the healing process was carried out through histological analysis, reduced epidermal thickness and scar formation.

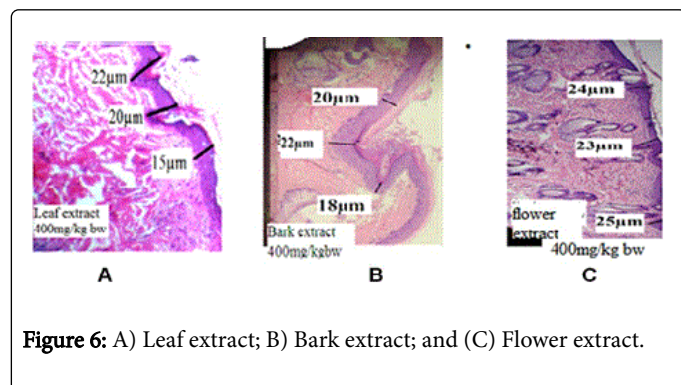


Figure 6: A) Leaf extract; B) Bark extract; and C) Flower extract.

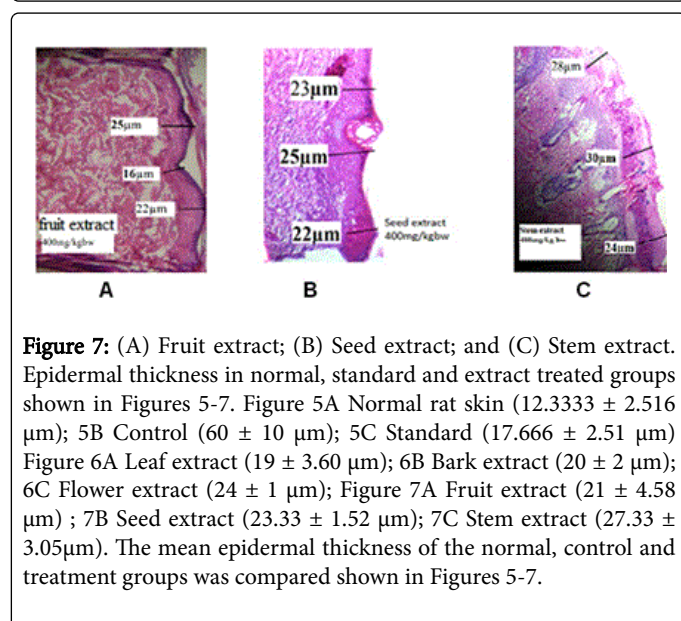


Figure 7: (A) Fruit extract; (B) Seed extract; and (C) Stem extract. Epidermal thickness in normal, standard and extract treated groups shown in Figures 5-7. Figure 5A Normal rat skin ( $12.3333 \pm 2.516 \mu\text{m}$ ); 5B Control ( $60 \pm 10 \mu\text{m}$ ); 5C Standard ( $17.666 \pm 2.51 \mu\text{m}$ ) Figure 6A Leaf extract ( $19 \pm 3.60 \mu\text{m}$ ); 6B Bark extract ( $20 \pm 2 \mu\text{m}$ ); 6C Flower extract ( $24 \pm 1 \mu\text{m}$ ); Figure 7A Fruit extract ( $21 \pm 4.58 \mu\text{m}$ ); 7B Seed extract ( $23.33 \pm 1.52 \mu\text{m}$ ); 7C Stem extract ( $27.33 \pm 3.05 \mu\text{m}$ ). The mean epidermal thickness of the normal, control and treatment groups was compared shown in Figures 5-7.

Comparing the leaf-treated group with those of the other aerial parts treated group, untreated group and with the reference group, the methanolic extract of leaf showed greater improvements than the standard treated group, other aerial parts treated group and the untreated group. The Preliminary phytochemical screening of the various parts of the plant (leaves, stem, bark, flower, fruit and seeds) extracts reveals that *Moringa* contains bioactive compounds such as moringine, moringinine, oleic acid, thiocarbamates and isothiocyanate glycosides, all of which can help induce healthy skin in psoriasis. Extracts from *M. oleifera* leaves have been shown to modulate cellular and humoral immunity in mice and rats [24,25]. The leaves extract exhibited strong anti-inflammatory properties in rodent models of chemically induced inflammation of the paw [26,27]. These features have been more widely studied with seed and fruit extracts [27-29]. The micronutrients in *Moringa oleifera* leaves are essential in the growth, differentiation, and proliferation of immune system [30]. *Moringa oleifera* contains various amino acids, vitamins, phytochemicals and trace elements such as iron, copper, selenium, zinc, flavonoids, and saponins [30-32]. Hence different parts of *M. oleifera* have potential therapeutic value. The micronutrients in *M. oleifera* leaves are essential in the growth, differentiation, and proliferation of immune system cells. Hence different parts of *M. oleifera* play potential therapeutic role in numerous

immunosuppressing clinical conditions. The abnormal skin response to Ultraviolet (UV) rays, particularly sunlight is called photodermatitis. Evidences accumulating from the different studies of human and animals [31] suggest that UV-B radiation induces anatomical changes like epidermal thickening (hyperplasia), thickening of the stratum corneum (hyperkeratosis). The screening of the activity of methanol extract of *M. oleifera* was carried out using UV-B-induced psoriasisform changes in rats. The irradiated rat skin treated with methanol extract of *M. oleifera* leaf and bark (400 mg/kg) has shown a significant decrease in the epidermal thickness when compared to control indicates that both leaf and bark have a potential to retard the hyper proliferation of the keratinocytes that occurs when the skin is exposed to UV radiation. Further, methanolic extract of leaf and bark (400 mg/kg) produced beneficial changes in the epidermis of the irradiated skin. The leaves of this species have a high content of vitamins, provitamins and minerals [33]. The pharmacological activities of *M. oleifera* may be due to various secondary plant metabolites present in *M. oleifera* such as flavonoids, phenolics, vitamins, carotenoids, minerals, sterols, amino acids, alkaloids, and glycosides [34]. *M. oleifera* leaves contains phenolic acids such as quinic acid and chlorogenic acid that exhibit high antioxidant activities [35,36] and recently  $\beta$ -sitosterol, was isolated from *Moringa* leaves fraction [37]. The antipsoriatic activity observed in the present study may be due to the presence of various phytoconstituents especially flavonoids in the extract which inhibited the proliferation of keratinocyte and enhanced the keratinization process.

## Conclusion

Natural herbs are effective alternatives to conventional medicines. Conventional medicines used for the management of psoriasis are costly and have many adverse effects. Phototherapy plays a significant role in the management of psoriasis. The results of the present study are encouraging and indicate that aerial parts of *Moringa oleifera* should be studied more extensively to confirm the potent antipsoriatic activity and to develop potent phytomedicine for treatment of psoriasis.

## Acknowledgment

The authors would like to sincerely appreciate the Deanship of Scientific Research at King Saud University for its funding of this research through the Research Group No. RGP-255.

## Conflict of Interest Statement

The authors stated that there are no conflicts of interest regarding the publication of this article.

## References

1. Wakkee M, Thio H, Prens E, Sijbrands E, Neumann H (2007) Unfavorable cardiovascular risk profiles in untreated and treated psoriasis patients. *Atherosclerosis* 190: 1-9.
2. Stern RS, Nijsten T, Feldman SR, Margolis DJ, Rolstad T (2004) Psoriasis is common carries a substantial burden even when not extensive and is associated with widespread treatment dissatisfaction. *Nature Publishing Group* 9: 136-139.
3. Neimann AL, Porte SB, Gelfand JM (2006) The epidemiology of psoriasis. *Expert Rev Dermatol* 1: 63-75.
4. Menter A, Gottlieb A, Feldman SR, Van Voorhees AS, Leonardi C, et al. (2008) Guidelines of care for the management of psoriasis and psoriatic

- arthritis: Section 1 Overview of psoriasis and guidelines of care for the treatment of psoriasis with biologics. *J Am Acad Dermatol* 58: 826-850.
5. Azfar RS, Gelfand JM (2008) Psoriasis and metabolic disease: epidemiology and pathophysiology. *Curr Opin Rheumatol* 20: 416-422.
  6. Barker JN (1998) Pathogenesis of psoriasis. *J Dermatol* 25: 778-781.
  7. Sabat R, Philipp S, Hoflich C, Kreutzer S, Wallace E, et al. (2007) Immunopathogenesis of psoriasis. *Exp Dermatol* 16: 779-798.
  8. Rocha-Pereira P, Santos-Silva A, Rebelo I, Figueiredo A, Quintanilha A, et al. (2004) The inflammatory response in mild and in severe psoriasis. *Br J Dermatol* 150: 917-928.
  9. Guenther L, Gulliver W (2009) Psoriasis comorbidities. *J Cutan Med Surg* 13: S77-S87.
  10. Magin PJ, Adams J, Heading GS, Pond CD (2009) Patients with skin disease and their relationships with their doctors: a qualitative study of patients with acne, psoriasis and eczema. *Med J Aust* 190: 62-64.
  11. Traub M, Marshall K (2007) Psoriasis-pathophysiology, conventional, and alternative approaches to treatment. *Altern Med Rev* 12: 319-330.
  12. Yuqi TT (2005) Review of a treatment for psoriasis using herose, a botanical formula. *J Dermatol* 32: 940-945.
  13. Keane J, Gershon S, Wise RP, Mirabile-Levens E, Kasznica J, et al. (2001) Tuberculosis associated with infliximab, a tumor necrosis factor alpha-neutralizing agent. *N Engl J Med* 345: 1098-1104.
  14. Day R (2002) Adverse reactions to TNF-alpha inhibitors in rheumatoid arthritis. *Lancet* 359: 540-541.
  15. Raychaudhuri SP, Nguyen CT, Raychaudhuri SK, Gershwin ME (2009) Incidence and nature of infectious disease in patients treated with anti-TNF agents. *Autoimmun Rev* 9: 67-81.
  16. Pallavicini FB, Caporali R, Sarzi-Puttini P, Atzeni F, Bazzani C (2010) Tumor necrosis factor antagonist therapy and cancer development: Analysis of the LORHEN registry. *Autoimmun Rev* 9: 175-180.
  17. Zheng CJ, Tang WZ, Huang BK, Han T, Zhang QY (2009) Bioactivity-Guided Fractionation for Analgesic Properties and Constituents of *Vitex negundo* L. Seeds. *Phytomedicine* 16: 560-567.
  18. Sara V, Franca T, Gelsomina F (2009) Traditional uses of medicinal Plants in Valvestino (Italy). *J Ethnopharmacol* 121: 106-116.
  19. Kaur A, Kumar S (2012) Plants and plant products with potential antipsoriatic activity-a review. *Pharm Biol* 50: 1573-1591.
  20. Fuglie LJ (2001) Combating malnutrition with *Moringa*. In: Fuglie LJ (ed.) *The miracle tree: the multiple attributes of Moringa*. CTA Publication, Wageningen, The Netherlands p: 117.
  21. Bennett RN, Mellon FA, Foidl N, Pratt JH, Dupont MS, et al. (2003) Profiling glucosinolates and phenolics in vegetative and reproductive tissues of the multi-purpose trees *Moringa oleifera* L. (horseradish tree) and *Moringa stenopetala* L. *J Agric Food Chem* 51: 3546-3553.
  22. Sofowora A (1993) *Spectrum Books*, Ibadan p: 150.
  23. Trease GE, Vans WCE (1989) *Pharmacognosy* 13 (edn.), Bailliere Tindal, London pp: 176-180.
  24. Gupta A, Gautam MK, Singh RK, Kumar MV, Rao CHV, et al. (2010) Immunomodulatory effect of *Moringa oleifera* Lam. extract on cyclophosphamide induced toxicity in mice. *Indian J Exp Biol* 48: 1157-1160.
  25. Sudha P, Asdaq SM, Dhamingi SS, Chandrakala GK (2010) Immunomodulatory activity of methanolic leaf extract of *Moringa oleifera* in animals. *Indian J Physiol Pharmacol* 54: 133-140.
  26. Sulaiman MR, Zakaria ZA, Bujarimin AS, Somchit MN, Israf DA, et al. (2008) Evaluation of *Moringa oleifera* aqueous extract for antinociceptive and anti-inflammatory activities in animal models. *Pharmacol Biol* 46: 838-884.
  27. Mahajan S, Mehta A (2009) Curative effect of hydro alcoholic extract of leaves of *Moringa oleifera* lam against adjuvant induced established arthritis in rats. *Niger J Nat Prod Med* 13: 13-22.
  28. Cheenpracha S, Park EJ, Yoshida WY, Barit C, Wall M, et al. (2010) Potential anti-inflammatory phenolic glycosides from the medicinal plant *Moringa oleifera* fruits. *Bioorg Med Chem* 18: 6598-6602.
  29. Channarong MC, Pimjai PC, Phawachaya PP, Svasti S, Siriporn TS (2011) *Moringa oleifera* pod inhibits inflammatory mediator production by lipopolysaccharide-stimulated RAW 264.7 murine macrophage cell lines. *Inflammation* 2: 445-455.
  30. Anwar F, Latif S, Ashraf M, Gilani AH (2007) *Moringa oleifera*: a food plant with many medicinal uses. *Phytother Res* 21: 17-25.
  31. Thurber MD, Fahey JW (2009) Adoption of *Moringa oleifera* to combat under-nutrition viewed through the lens of the "Diffusion of Innovations" theory. *Ecol Food Nutr* 48: 212-225.
  32. Siddhuraju P, Becker K (2003) Comparative nutritional evaluation of differentially processed mucuna seeds [*Mucuna pruriens* (L.) DC var utilis (Wall ex Wight) Baker ex Burck] on growth performance, feed utilization and body composition in Nile tilapia (*Oreochromis niloticus* L.). *Aquacult Res* 34: 487-500.
  33. Palada MC, Chang LC (2003) Suggested cultural practices for moringa. AVRDC International Cooperators Guide. AVRDC Shanhua, Taiwan Pub 03-545.
  34. Alhakmani F, Kumar S, Khan SA (2013) Estimation of total phenolic content, *in-vitro* antioxidant and anti-inflammatory activity of flowers of *Moringa oleifera*. *Asian Pac J Trop Biomed* 3: 623-627.
  35. Amaglo NK, Bennett RN, LoCurto RB, Rosa EA, Lo Turco V, et al. (2010) Profiling selected phytochemicals and nutrients in different tissues of the multipurpose tree *Moringa oleifera* L. grown in Ghana. *Food Chem* 122: 1047-1054.
  36. Mbikay M (2012) Therapeutic potential of *Moringa oleifera* Leaves in chronic hyperglycemia and dyslipidemia: A review. *Front Pharmacol* 3: 24.
  37. Jain PG, Patil SD, Haswani NG, Girase MV, Surana SJ (2010) Hypolipidemic activity of *Moringa oleifera* Lam. Moringaceae, on high fat diet induced hyperlipidemia in albino rats. *Rev Bras Farmacogn* 20: 969-973.