

Ghrelin Attenuates the Effect of Acute Restraint Stress on the Liver

Shaimaa N. Amin^{1*}, Sarah M. Gamal², Rabab A. Rasheed³ and Laila A. Rashed³

¹Department of Medical Physiology-Faculty of Medicine-Cairo University, Egypt

²Department of Histology- Faculty of Medicine- Cairo University, Egypt

³Department of Histology-Faculty of Medicine-October 6 University, Egypt

Abstract

Background: Stress exposure has negative impact on different body systems including the liver. Acute restraint stress has clinical implications in both medical and surgical practice. Ghrelin is the gut hormone has been shown to provide protection to different organs under various pathological conditions. In this work we evaluated the effect of ghrelin in animal models exposed to acute restraint stress.

Methods: Thirty male albino rats divided into three groups; control group, group exposed to acute restraint stress and group treated with ghrelin in addition to exposure to acute restraint stress. Serum levels of cortisol, aspartate aminotransferase and alanine aminotransferase. Histological evaluation of the liver samples was done by Hematoxylin and eosin stain, Masson's trichrome stain and morphometric measurement of connective tissue area.

Results: The group treated with ghrelin and exposed to acute restraint stress showed less injury on microscopic evaluation and less fibrosis compared to acute restraint stress group. However; serum cortisol, aspartate aminotransferase and alanine aminotransferase showed no significant difference.

Conclusion: Ghrelin offered hepatoprotective effect on the liver in rats exposed to acute restraint stress as it improved the microscopic picture and decreased the fibrosis.

Keywords: Acute restraint stress; Liver; Ghrelin

Introduction

Stress impairs the physiological/psychological balance of the different body organs and activates the hypothalamic-pituitary-adrenal (HPA) axis and induces the release of glucocorticoid hormones that exert widespread effects [1]. Acute restraint stress (ARS) is an unavoidable stress situation that causes autonomic and behavioral effects [2].

Ghrelin is a gut hormone (28 amino acids) firstly discovered as a potent growth hormone secretagogue. Moreover, it plays a major role in the regulation of food intake [3]. The primary site of ghrelin synthesis is the stomach, but ghrelin transcripts have been detected in many other organs, including the liver, pancreas, kidneys, and lungs [4]. Most ghrelin actions are mediated by growth hormone secretagogue receptor (GHS-R), [3] which is mainly expressed in the pituitary gland but also in other organs, including the pancreas, spleen, and adrenal gland. [4]. Ghrelin has protective effects in different organs and cell types [5]. In the current work we investigated the effect of ghrelin treatment on rats exposed to acute restraint stress.

Materials and Methods

Experimental animals and study design

The experimental steps, animal handling, sampling and scarification were approved by the scientific and Ethical Committee of Physiology department, Faculty of Medicine, Cairo University.

30 adult male albino rats, 4–5 months old, obtained from Kasr Al Ainy animal house, weighting 150–200 g. Rats were housed in a constant temperature (22°C–24°C) and light-controlled room on an alternating 12:12 h light–dark cycle and had free access to a standard diet and water. Rats were divided into the following groups (10 rats/group):

Control: rats of this group were not exposed to any sort of stress and haven't been treated with ghrelin.

ARS group: rats were immobilized for 2.5 hours by fixing the four limbs to a grid for one stress session [6].

ARS+Ghrelin group: rats exposed to the same pattern of stress described in the previous group and treated with ghrelin (Sigma, St. Louis, MO, USA) as single dose of 20 µg/kg, intraperitoneal for three consecutive days [7].

Biochemical measurements

At the end of the experiments, rats were anesthetized by ether, blood samples were collected from retro-orbital venous sinus for measuring serum level of cortisol. Cortisol level was measured by enzyme-linked immunosorbent assay (ELISA) kit supplied by MyBioSource kit USA according to manufacturer's instruction. Activities of serum aspartate aminotransferase (AST) and serum alanine aminotransferase (ALT) were estimated by the method of Reitman and Frankel [8].

Histological evaluation

Rats were sacrificed by local anesthesia. Liver specimens were removed by a ventral midline incision and exposure of the liver. The

***Corresponding author:** Shaimaa N. Amin, Department of Medical Physiology, Faculty of Medicine, Cairo University, 11451, Egypt, Tel: +201111777956, +201142244442; E-mail: shaimaa599@yahoo.com

Received November 26, 2015; **Accepted** December 22, 2015; **Published** December 29, 2015

Citation: Amin SN, Gamal SM, Rasheed RA, Rashed LA (2016) Ghrelin Attenuates the Effect of Acute Restraint Stress on the Liver. *Anat Physiol* 6: 191. doi:10.4172/2161-0940.1000191

Copyright: © 2016 Amin SN, et al. This is an open-access article distributed under the terms of the Creative Commons Attribution License, which permits unrestricted use, distribution, and reproduction in any medium, provided the original author and source are credited.

removed liver specimens of the studied groups were fixed in 10% formaline for 48 hours. Paraffin blocks were prepared and 5 μ m thick sections were subjected to Hematoxylin and eosin stain [9] for demonstration of the structure of the liver and Masson's trichrome stain [10] for demonstration of the collagen content of the liver. Measurements of the connective tissue area in the histological sections were carried out using Leica Qwin 500 image analyzer computer system. The image analyzer consists of a colored video camera, colored monitor and a hard disc of IBM personal computer connected to the microscope and controlled by Leica Qwin 500 software. The image analyzer was first calibrated automatically to convert the measurement units (pixels) produced by the image analyzer program into actual micrometer units. Using the measuring field menu; the area, area % and standard measuring frame of a standard area were chosen. In each chosen field liver tissue was enclosed inside the standard measuring frame and then the connective tissue area was masked by a blue binary color to be measured. These measurements were done under magnification of 200 (Figure 1). The measurements were tabulated subjected for statistical analysis.

Statistical analysis

All statistical calculations were done using computer programs Microsoft Excel 2010 (Microsoft Corporation, NY, and USA) and SPSS 21(IBM SPSS Statistics 21; IBM Corporation, New York, USA) for Microsoft Windows. Data were analyzed and expressed as mean \pm standard deviation (Mean \pm SD). Comparison of quantitative variables between the studied groups was done using Kruskal–Wallis test with Wilcoxon signed-rank test. Correlations between the measured parameters have been calculated by Spearman's correlation Results were considered statistically significant at p value \leq 0.05 [11].

Results

The group exposed to ARS showed significant (p value <0.05) increase of serum cortisol, ALT and AST compared to control group. The group treated with ghrelin before ARS exposure didn't show any significant difference in serum cortisol, ALT and AST compared to group exposed to ARS (Figures 2-4).

Histologic examination by H& E and Masson trichrome (Figures 5-10) reveals normal liver tissue in control group showing liver lobules

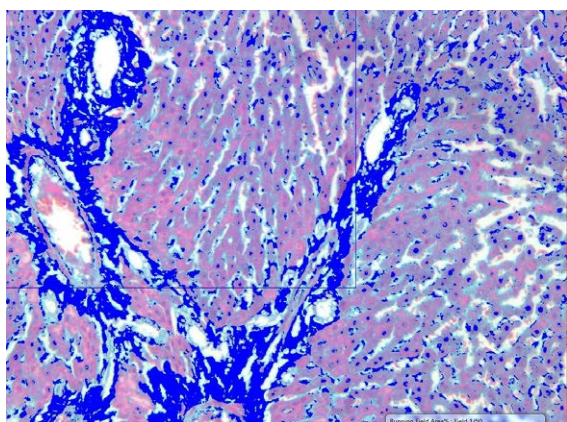


Figure 1: A copy of the image displayed on the monitor screen of a field of a section in the liver of a rat in control group showing the connective tissue areaX200. In each chosen field liver tissue was enclosed inside the standard measuring frame and then the connective tissue area was masked by a blue binary color to be measured.

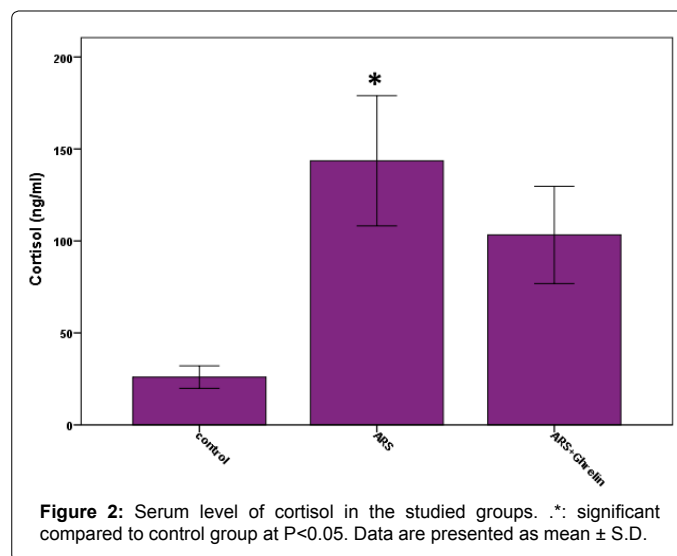


Figure 2: Serum level of cortisol in the studied groups. *: significant compared to control group at P<0.05. Data are presented as mean \pm S.D.

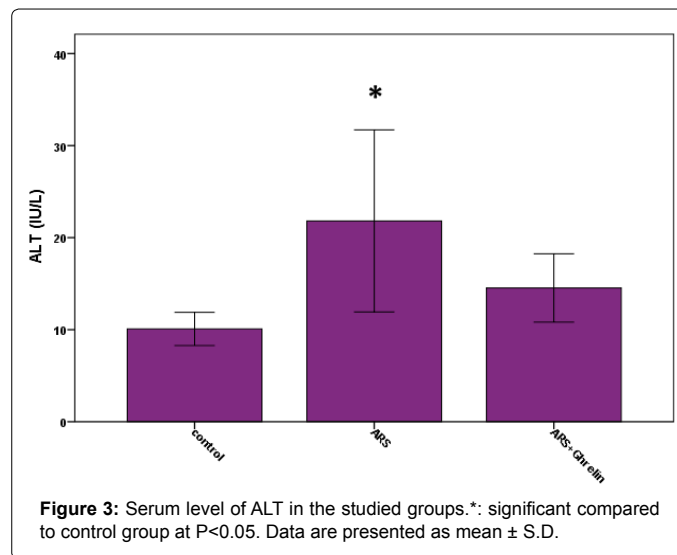


Figure 3: Serum level of ALT in the studied groups.*: significant compared to control group at P<0.05. Data are presented as mean \pm S.D.

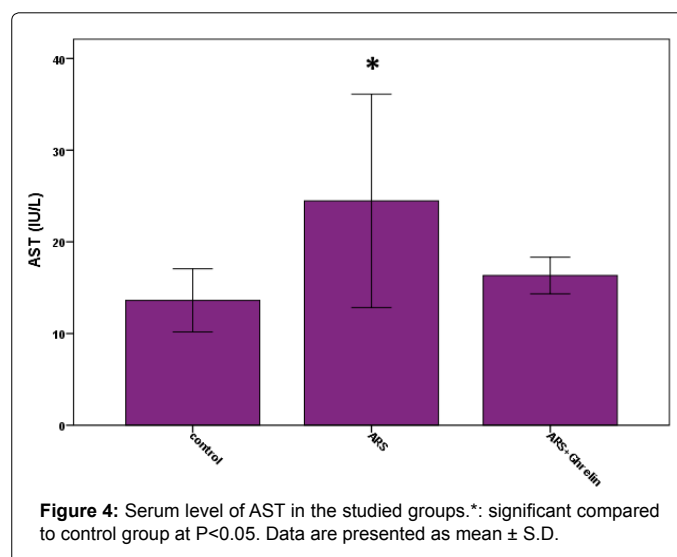


Figure 4: Serum level of AST in the studied groups.*: significant compared to control group at P<0.05. Data are presented as mean \pm S.D.

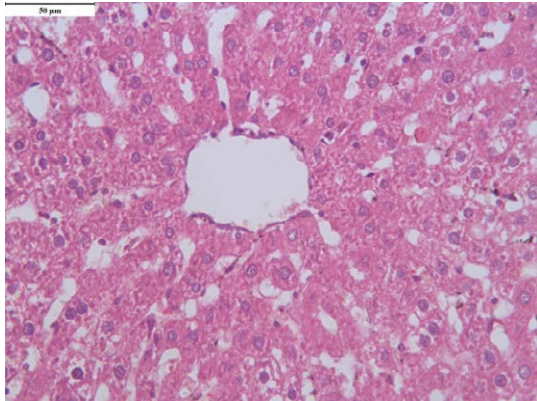


Figure 5: Hematoxylin and eosin stain in control group (X400). Normal liver tissue showing central vein, polyhedral hepatocytes with acidophilic vacuolated cytoplasm and vesicular nuclei.

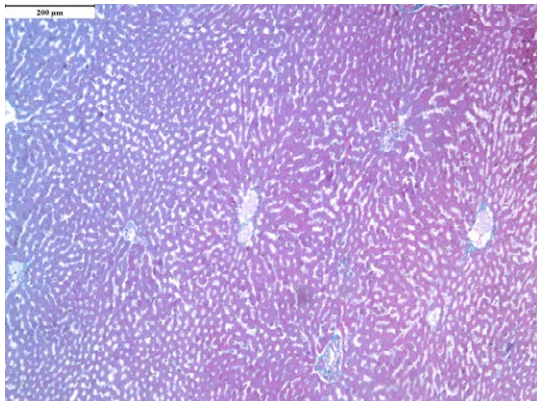


Figure 6: Masson's trichrome stain in control group (X100). Normal liver lobules showing central vein with cords of hepatocytes separated by blood sinusoids.

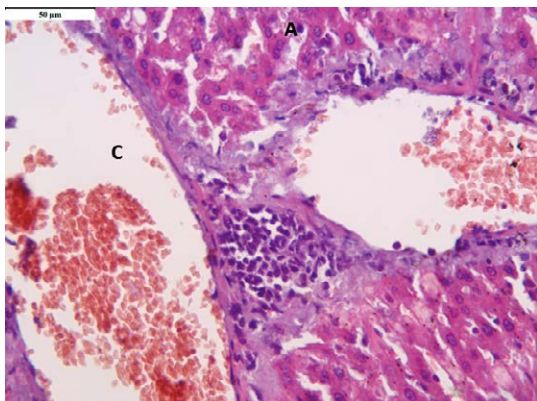


Figure 7: Hematoxylin and eosin stain in ARS group (X400). Marked congestion (C) of central vein and sinusoids. Some apoptotic cells (A) and mononuclear inflammatory cellular infiltrates were observed.

with central vein and hepatocytes arranged in cords separated by blood sinusoids. The hepatocytes are polyhedral cells with acidophilic vacuolated cytoplasm and vesicular nuclei.

Liver of rats exposed to acute restraint stress showed marked central vein congestion and centrizonal necrosis of hepatocytes. Apoptotic cells and mononuclear inflammatory cellular infiltrates were observed. Also, sections showed apparent vacuolization of hepatocytes. Examination of sections stained with Masson's trichrome revealed increased amount of collagen fibers in stroma.

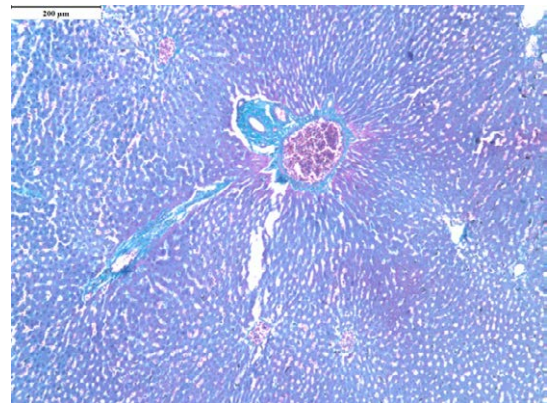


Figure 8: Masson's trichrome stain in ARS group (X100). There is increased amount of collagen fibers in stroma.

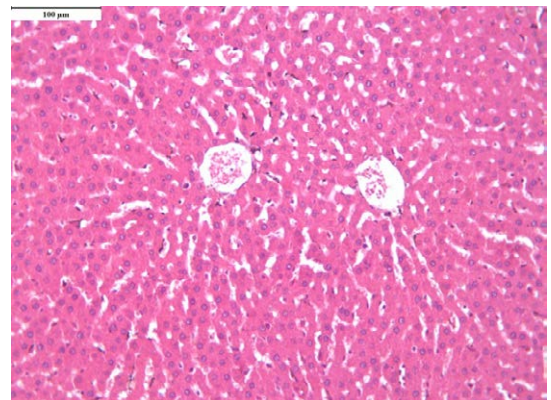


Figure 9: Hematoxylin and eosin stain in ARS+ ghrelin group (X 200). There is regularly arranged hepatocytes cords with fewer apoptotic changes.

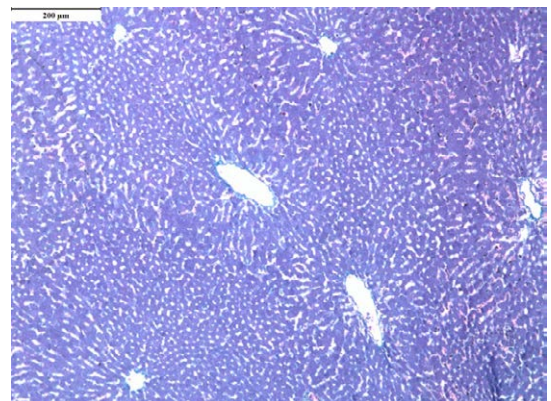
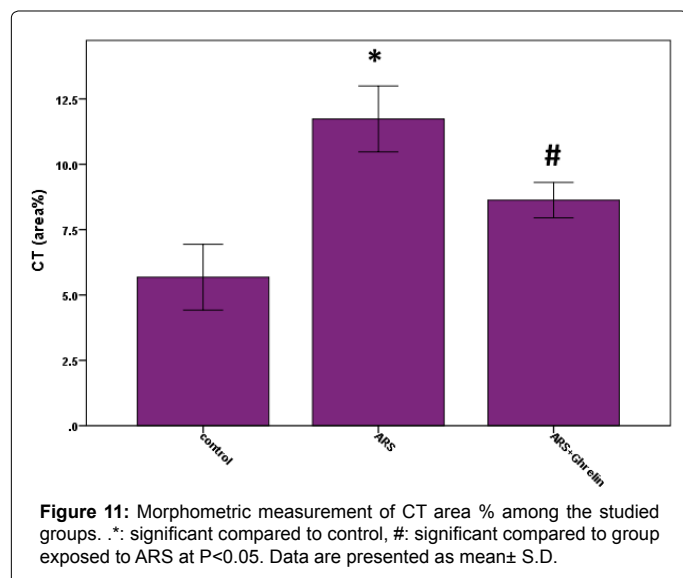


Figure 10: Masson's trichrome stain in ARS +ghrelin group (X100). Normal amount of liver stroma.



Examination of liver of rats treated with ghrelin showed marked improvement of liver histology with less vacuolization of hepatocytes and fewer apoptotic changes. Central vein and sinusoids showed less congestion. Examination of sections stained with Masson's trichrome showed normal amount of liver stroma. Morphometric study showed significant (p value <0.05) increase of CT area % in group exposed to ARS compared to control group and group treated with ghrelin prior to ARS exposure showed significant (p value <0.05) decrease compared to ARS group (Figure 11). Significant positive correlation ($r=0.72$; p value <0.05) was seen between serum cortisol and CT area %.

Discussion

As shown in our results ARS caused significant increase in serum cortisol, ALT, AST compared to control group. Restraint stress plays a role in increasing oxidative stress as demonstrated by Mugbil and Banu [12] that increases the risk of many diseases [13] due to oxidative damage of DNA, proteins, and lipids, which are catalyzed by reactive oxygen species [14]. Furthermore; Stress can cause liver injury due to misalignments in HPA axis and change in the glucocorticoid plasma level. Also; acute stress increase the degradation of hepatic glycogen with or without hyperglycemia depending on the particular characteristics of the stressor, disorganization of hepatic cord hepatocyte [15] and decrease in the level of triglycerides which is the most stored lipids in liver [16].

Ghrelin is as an acute-phase reactant [17], however; Otto et al. [18] found both endogenous and exogenous glucocorticoids decrease plasma ghrelin in humans. In the current work ghrelin administration didn't reveal any significant difference in serum levels of cortisol, ALT, AST. In contrast to our results; Leal-Cerro et al. [19] showed that ghrelin has stimulatory effect on ACTH and cortisol secretion.

The group exposed to stress developed liver fibrosis as indicated from significant increase of CT% in group exposed to ARS group compared to control. In liver fibrosis there is an increased deposition of collagen; specifically, the fibrillar collagens types I and III [20]. Insults on the liver including oxidative stress activates wound healing process, resulting in progressive accumulation of extracellular matrix (ECM) in the subendothelial space of Disse, and distortion of the parenchymal and vascular liver architecture by scar tissue [21].

The group treated with ghrelin showed less fibrosis and improvement of microscopic picture. Ghrelin has antifibrotic effects in the liver [22]. Iseri et al., [23] suggested protective effects of ghrelin in a model of chronic liver injury. Different mechanisms may explain the antifibrotic effects of ghrelin in the injured liver. First, ghrelin seems to protect hepatocytes from cell death, as indicated by decreased necroinflammatory injury in rats subjected to both acute and chronic liver injury. This effect was related to a reduction in the number of infiltrating inflammatory cells as well as decreased apoptosis in hepatocytes in the model of acute liver injury [24]. Furthermore; ghrelin administration increases hepatic expression of hepatoprotective signaling pathways such as phospho-Akt and phospho-extracellular signal-regulated kinase [25]. Also, ghrelin decreases the extent of oxidative stress in the liver [26].

Moreover; ghrelin reduces the accumulation of activated hepatic stellate cells (HSCs) in the liver and reduces collagen synthesis by cultured HSCs and decreases transforming growth factor- β 1 expression, a major profibrogenic cytokine in the liver [22].

Conclusion

Ghrelin offered hepatoprotective effect on the liver in rats exposed to acute restraint stress as it improved the microscopic picture and decreased the fibrosis. This may have clinical application in patients indicated for acute restraint in different clinical situations especially if there is risk of liver diseases.

Acknowledgments

We would like to thank Mr. Tarek Mamdoh, Mrs. Afaf Mohamed Afify and Mrs. Aza Kamal the technicians at Department of Medical Physiology for their kind help in this work.

Conflict of Interest

There is no conflict of interest.

References

1. McEwen BS (2008) Central effects of stress hormones in health and disease: Understanding the protective and damaging effects of stress and stress mediators. *Eur J Pharmacol* 583: 174-185.
2. Padovan CM, Guimaraes FS (2000) Restraint-induced hypoactivity in an elevated plus-maze. *Braz J Med Biol Res* 33: 79-83.
3. Kojima M, Kangawa K (2005) Ghrelin: structure and function. *Physiol Rev* 85: 495-522.
4. Gnanapavan S, Kola B, Bustin SA, Morris DG, McGee P, et al. (2002) The tissue distribution of the mRNA of ghrelin and subtypes of its receptor, GHS-R, in humans. *J Clin Endocrinol Metab* 87: 2988.
5. Granata R, Settanni F, Trovato L, Destefanis S, Gallo D, et al. (2006) Unacylated as well as acylated ghrelin promotes cell survival and inhibit apoptosis in HIT-T15 pancreatic beta-cells. *J Endocrinol Invest* 29: RC19-RC22.
6. Kumar A, Garg R, Prakash AK (2010) Effect of St. John's Wort (*Hypericum perforatum*) treatment on restraint stress-induced behavioral and biochemical alteration in mice. *BMC Complement Altern Med* 10: 18.
7. Tumer C, Bilgin HM, Obay BD, Diken H, Tasdemir E (2007) Effect of ghrelin administration on phagocytic activity in acute cold-restraint stress exposed rats. *Regul Pept* 138: 113-117.
8. Reitman S, Frankel S (1957) A colorimetric method for the determination of serum glutamic oxalacetic and glutamic pyruvic transaminases. *Am J Clin Pathol* 28: 56-63.
9. Kiernan JA (2001) *Histological and Histochemical methods: theory and practice*. 3rd ed., Arnold publisher, London, New York & New Delhi pp: 111-62.
10. Bancroft JD and Gamble M (2008) *Connective tissue stains*. In: *Theory and Practice of Histological Techniques*, sixth edition. Elsevier Health Sciences, Churchill Livingstone, Edinburgh, London, Oxford, New York, Philadelphia, St Louis, Sydney and Toronto 150.

11. Altman GD (2005) Comparing groups: Three or more independent groups of observations in practical statistics for medical research London: Chapman and Hall.
12. Muqbil I, Banu N (2006) Enhancement of pro-oxidant effect of 7,12-dimethylbenz (a) anthracene (DMBA) in rats by pre-exposure to restraint stress. *Cancer Lett* 240: 213-220.
13. Epel ES (2009) Psychological and metabolic stress: a recipe for accelerated cellular aging? *Hormones (Athens)* 8: 7-22.
14. Buijsse B, Feskens EJ, Moschandreas J, Jansen EH, Jacobs DR (2007) Oxidative stress, and iron and antioxidant status in elderly men: differences between the Mediterranean south (Crete) and northern Europe (Zutphen). *Eur J Cardiovasc Prev Rehabil* 14: 495-500.
15. Vasquez B, Sandoval C, Smith RL, del Sol M (2014) Effects of early and late adverse experiences on morphological characteristics of Sprague-Dawley rat liver subjected to stress during adulthood. *Int J Clin Exp Pathol* 7: 4627-35.
16. Czech B, Neumann ID, Müller M, Reber SO, Hellerbrand C (2013) Effect of chronic psychosocial stress on nonalcoholic steatohepatitis in mice. *Int J Clin Exp Pathol* 6: 1585-1593.
17. Maruna P, Gurlich R, Rosicka M (2008) Ghrelin as an acute-phase reactant during postoperative stress response. *Horm Metab Res* 40: 404-9.
18. Otto B, Tschop M, Heldwein W, Pfeiffer AF, Diederich S (2004) Endogenous and exogenous glucocorticoids decrease plasma ghrelin in humans. *Eur J Endocrinol* 151: 113-117.
19. Leal-Cerro A, Torres E, Soto A, Dios E, Deghenghi R (2002) Ghrelin is no longer able to stimulate growth hormone secretion in patients with Cushing's syndrome but instead induces exaggerated corticotropin and cortisol responses. *Neuroendocrinology* 76: 390-396.
20. Pinzani M, Rombouts K (2004) Liver fibrosis: from the bench to clinical targets. *Dig Liver Dis* 36: 231-242.
21. Pinzani M, Rombouts K, Colagrande S (2005) Fibrosis in chronic liver diseases: diagnosis and management. *J Hepatol* 42 Suppl: S22-36.
22. Moreno M, Chaves JF, Sancho-Bru P, Ramalho F, Ramalho LN, et al. (2010) Ghrelin attenuates hepatocellular injury and liver fibrogenesis in rodents and influences fibrosis progression in humans. *Hepatology* 51: 974-985.
23. Yeri SO, Sener G, Saglam B, Ercan F, Gedik N, et al. (2008) Ghrelin alleviates biliary obstruction-induced chronic hepatic injury in rats. *Regul Pept* 146: 73-79.
24. Chen J, Liu X, Shu Q, Li S, Luo F (2008) Ghrelin attenuates lipopolysaccharide-induced acute lung injury through NO pathway. *Med Sci Monit* 14: BR141-146.
25. Chung H, Kim E, Lee DH, Seo S, Ju S, et al. (2007) Ghrelin inhibits apoptosis in hypothalamic neuronal cells during oxygen-glucose deprivation. *Endocrinology* 148: 148-159.
26. Obay BD, Taaydemir E, Tamer C, Bilgin H, Atmaca M (2008) Dose dependent effects of ghrelin on pentylentetrazole-induced oxidative stress in a rat seizure model. *Peptides* 29: 448-455.