

Functional Assessments and Histopathology of Hepatic and Renal Tissues of Wistar Rats Fed with Cocoa Containing Diets

Chiedozi Onyejiaka Ibegbulem¹, Paul Chidoka Chikezie^{2*} and Ezeikel Chinemerem Dike²

¹Department of Biochemistry, Federal University of Technology, Owerri, Nigeria

²Department of Biochemistry, Imo State University, Owerri, Nigeria

Abstract

The liver and kidney are organs of homeostasis. The present study ascertained functional integrity of renal and hepatic tissues of Wistar rats fed with processed cocoa bean-based beverages (PCB-BB) and raw cocoa bean products (RCBP) containing diets using biochemical and histological methods. Thirty Wistar rats were designated on the basis of experimental diets received for 28 days. At the end of the feeding period, blood samples were drawn and renal and hepatic tissues were excised from the experimental rat groups for functional tests and histological examinations, respectively. Serum ALT activities of the experimental rat groups showed no significant difference ($p > 0.05$) and were within relatively narrow range of 32.17 ± 4.98 IU/L to 41.00 ± 10.85 IU/L whereas, serum AST activities gave wide variation within the range of 15.67 ± 2.13 IU/L to 34.83 ± 8.31 IU/L; $p < 0.05$. Serum bilirubin concentrations of experimental rat groups were < 1.0 mg/dL. Serum total protein and albumin concentrations varied within relatively narrow range. Serum creatinine concentration was significantly lower ($p < 0.05$) than serum urea concentration. Histology showed evidence of moderate disarrangement of hepatic tissues architecture and degenerated tubules and glomerular tufts. The pattern of activity of ALT > AST in serum appeared to correlate with the extent of disarrangement of hepatic tissue architecture. The experimental rat groups did not exhibit hyperbilirubinemia. Also, PCB-BB - and RCBP - containing diets did not substantially interfere with the capacity of the hepatocytes to biosynthesize plasma proteins and the functionality of renal tissues.

Keywords: Creatinine; Histopathology; Kidney; Serum; *Theobroma cacao*

Introduction

The cocoa bean tree-*Theobroma cacao* (Linnaeus); family Sterculiaceae, originated from Latin America about 500 years ago, from where it was domesticated in other parts of the world [1]. Harvested cocoa beans are usually fermented and dried prior to their processing into finished products [2,3]. Cocoa bean-beverages are processed products of the cocoa bean, sold under several brand names in Nigeria and worldwide [4-6]. The nutraceutical values of raw cocoa bean products (RCBP) [7-11] as well as the high acceptability of processed cocoa bean-based beverages (PCB-BB) [2], because of their attractive flavour and appearance, designate the cocoa tree as a highly prized international cash crop.

The quality parameters of PCB-BB in Nigeria markets have previously been reported elsewhere [5,6,12-14]. Previous studies have raised safety concerns about the consumption of RCBP- and industrial PCB-BB- containing diets. For the most part, the presence of anti-nutritional factors in RCBP is associated with the toxicological outcomes and poor nutritional score when used as feed substitutes for farm animals [15,16]. Likewise, the presence of Maillard reaction end-products/chemically modified by-products [2,17-21], heavy metal [22] and microbial contaminations [12,14,21-25] of PCB-BB- and RCBP-containing diets may provoke tissue lesion and organ damage.

The liver and kidney are organs of homeostasis. The hepatic tissues play a central role in the biotransformation of xenobiotics and endogenous molecules prior to their elimination from the body [26-28]. The biotransformation of xenobiotics in the hepatocytes may elicit the formation of noxious and highly reactive compounds or potentially toxic metabolites, which in the process of their metabolism predisposes the hepatocytes to injuries and dysfunction [29]. The renal tissues are highly specialized in ensuring delicate balance in selective excreting or retention of body biomolecules according to their physiologic renal

threshold indices [30]. The renal tissues are predisposed to chemical induced injuries because of their action to concentrate tubular fluid by removal of H₂O, organic compounds and inorganic salts from the vascular system. Liver (hepatic) function test (LFT) and renal function test (RFT) are diagnostic parameters for ascertaining organ integrity and functionality and level of recovery from pathologic injuries. Histopathological studies are precise methods for the identification and characterization of pathological changes associated with tissue lesion.

Chemical modifications of organic matters in cocoa bean occur through the processes of dextrinization, caramelization, pyrolysis, cyclization, oxidation and esterification reactions [19,20,31], which upon ingestion of the resultant organic derivatives may prompt tissue lesion in biologic systems. Additionally, studies have shown that farm and industrial PCB-BBs results in alterations of their physicochemical characteristics [2]. There is no available precise empirical information on the effect of PCB-BB - containing diets on internal organs integrity and functionality. Moreover, information on the effect of RCBP - containing diets on animal physiology is comparatively scanty and has been largely ignored and taken for granted. Accordingly, the present study ascertained functional integrity of renal and hepatic tissues of Wistar rats fed with PCB-BB - and RCBP - containing diets using biochemical and histological methods.

*Corresponding author: Paul C. Chikezie, Department of Biochemistry, Imo State University, Owerri, Nigeria, Tel: +2348038935327; E-mail: p_chikezie@yahoo.com

Received June 18, 2015; Accepted June 24, 2015; Published June 29, 2015

Citation: Ibegbulem CO, Chikezie PC, Dike EC (2015) Functional Assessments and Histopathology of Hepatic and Renal Tissues of Wistar Rats Fed with Cocoa Containing Diets. J Nutr Food Sci S11: 002. doi:10.4172/2155-9600.S11-002

Copyright: © 2015 Ibegbulem CO, et al. This is an open-access article distributed under the terms of the Creative Commons Attribution License, which permits unrestricted use, distribution, and reproduction in any medium, provided the original author and source are credited.

Materials and Methods

Collection and processing of raw cocoa-bean seeds

The cocoa-bean pods were randomly handpicked from small-holder cocoa farmers in Owerri, Imo State, Nigeria. The pods were harvested on the 24th September, 2014. The beans were evacuated from the pods and allowed to ferment for 5 days while shielded from sunlight. Fermentation of cocoa bean was done using the conventional heap fermentation method [32]. The wet beans were heaped on layers of plantain (*Musa paradisiaca*) leaves and covered with the same material to retain the heat generated during the fermentation process. On the third and fifth days, the beans were quickly and thoroughly re-mixed using a wooden spade and covered once again. Next, the fermented beans were sun-dried for ten days till constant weight was achieved. A 50 g sample of the beans were pulverized using Thomas-Willey milling machine (ASTM D-3182, INDIA), after which the ground samples were stored in air-tight plastic bottles with screw caps pending use to compound the rat diets.

Animal diets

The RCBP was mixed with sucrose (ratio 10:1 w/w) to sweeten it. The PCB-BBs were three (3) brands of cocoa beverages (OT = Cocoa beverage 1; BV = Cocoa beverage 2; MO = Cocoa beverage 3) commonly consumed in Nigeria, which were purchased from a grocery shop. Also, PCB-BB and RCBP were compounded separately with PSGF (ratio 10:1 w/w) to obtain the test diets, whereas the control diet was composed of pelletized standard guinea feed (PSGF) only. The PSGF (product of a subsidiary of UAC Nigeria Plc., Jos, Nigeria) was purchased at the Relief Market, Owerri, Imo State, Nigeria.

Animal handling

The present study was approved by the Ethical Committee on the use of animals for the research, Department of Biochemistry, Federal University of Technology, Owerri, Nigeria. The rats were obtained from the Animal House of the Department of Biochemistry, Federal University of Technology, and Owerri, Nigeria. Female albino (Wistar) rats were maintained at room temperatures of 28 ± 2 °C, 30–55% of relative humidity on a 12-h light/12-h dark cycle, with access to water and PSGF *ad libitum* for 2 weeks acclimatization period. Handling of the rats was in accordance with the standard principles of laboratory animal care of the United States National Institutes of Health.

Design of animal feed experiment

A total of 30 female Wistar rats (90 days old) of average weight of 106.0 ± 2.0 g were allotted into five (5) groups of six (6) rats each. The rats were deprived of food and water for additional 16 h before commencement of feeding as described elsewhere [33]. The rat groups were designated on the basis of experimental diets received for 28 days.

Group 1 (WR-PSGF): Wistar rats received PSGF + water *ad libitum*.

Group 2 (WR-RCBP): Wistar rats received RCBP + water *ad libitum*.

Group 3 (WR-OT): Wistar rats received OT + water *ad libitum*.

Group 4 (WR-BV): Wistar rats received BV + water *ad libitum*.

Group 5 (WR-MO): Wistar rats received MO + water *ad libitum*.

At the end of the feeding period, blood samples were drawn from the orbital sinus [34] of 12-hour post-fasted rat groups for renal and hepatic function tests. Also, renal and hepatic tissues were excised from the various rat groups for histological examinations.

Liver Function Test

Aspartate aminotransferase (AST) and alanine aminotransferase (ALT)

Measurement of serum AST and ALT activities were according to the methods of Reitman and Frankel, [35].

Bilirubin

Serum total bilirubin concentration (STBC) was measured using diazotized sulphanilic acid methods as previously described [36].

Total protein

Serum total protein concentration (STPC) was measured using the Biuret method as described by Gornall, [37].

Albumin

Measurement of serum albumin concentration (SAC) was by the method described by Doumas et al. [38].

Renal function test

Urea: Serum urea concentration (SUC) was measured using the rapid method as described by Fawcett and Scott, [39].

Creatinine: Measurement of serum creatinine concentration (SCC) was according to the methods as described by Bonsnes and Taussky [40].

Histopathological Examinations

Organ histology was according to the methods described by Bancroft [41]. Autopsy samples were taken from the renal and hepatic tissues of the different animal groups, fixed in 10% formolsaline (pH = 7.2) for 24 h and washed with continuous flow of distilled water. The specimens were cleared in xylene embedded in paraffin in hot air oven at 56 °C for 24 h. Paraffin bees wax tissue blocks were prepared for sectioning at 4-mm thickness using a semi-automated rotatory microtome. The obtained tissue sections were collected on glass slides, dehydrated by immersing in serial dilutions of ethyl alcohol-water mixture, cleaned in xylene and embedded in paraffin wax. Next, the specimens were deparaffinized and stained with hematoxylin and eosin (H&E) dye for histopathological examinations. Photomicrographs of the tissue sections were captured using charge-couple device (CCD) camera under light microscope (Olympus BX51TF; Olympus Corporation, Tokyo, Japan) at $\times 400$ magnification power.

Statistical analysis

The results were expressed as mean \pm SEM, and statistically analyzed by one way ANOVA followed by Dunnett test, with level of significance set at $p < 0.05$.

Results

An overview of Figure 1 showed that levels of serum activities of the two LFT enzymes were in the order: ALT > AST. However, serum ALT activities of WR-PSGF, WR-RCBP, WR-OT, WR-BV and WR-MO showed no significant difference ($p > 0.05$) and were within relatively narrow range of 32.17 ± 4.98 IU/L – 41.00 ± 10.85 IU/L.

Conversely, serum AST activities of WR-PSGF, WR-RCBP, WR-OT, WR-BV and WR-MO gave wide variation, which was within the range of 15.67 ± 2.13 IU/L – 34.83 ± 8.31 IU/L; $p < 0.05$. Specifically, WR-OT exhibited the lowest serum AST activity, whereas WR-RCBP gave the highest serum AST activity.

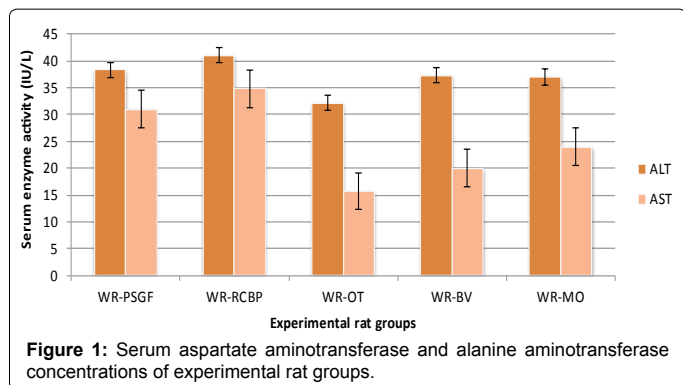


Figure 1: Serum aspartate aminotransferase and alanine aminotransferase concentrations of experimental rat groups.

Generally, STBC of WR-PSGF, WR-RCBP, WR-OT, WR-BV and WR-MO were <math>< 1.0\text{ mg/dL}</math>. WR-RCBP gave peak value of STBC = $0.85 \pm 0.18\text{ mg/dL}</math>, which was over 2 folds higher than that of WR-OT; STBC = $0.39 \pm 0.04\text{ mg/dL}</math> (Figure 2).$$

An overview of Figure 3 showed that STPC and SAC of WR-PSGF, WR-RCBP, WR-OT, WR-BV and WR-MO varied within relatively narrow range. Furthermore, STPC and SAC of WR-PSGF were not significantly different ($p > 0.05$) from that of WR-RCBP. Finally, STPC and SAC of WR-OT, WR-BV and WR-MO were comparatively higher than those of WR-PSGF and WR-RCBP.

Figure 4 showed that WR-RCBP gave the highest SUC, which was significantly different ($p < 0.05$) from that of other four experimental rat groups (WR-PSGF, WR-OT, WR-BV and WR-MO). Conversely, SUC of WR-PSGF, WR-OT, WR-BV and WR-MO showed no significant difference ($p > 0.05$). Additionally, SCC was significantly lower ($p < 0.05$) than SUC in WR-PSGF, WR-RCBP, WR-OT, WR-BV and WR-MO. Finally, SCCs in the five experimental rat groups were within relatively narrow range of $1.35 \pm 0.23\text{ mg/dL} - 0.72 \pm 0.03\text{ mg/dL}</math>; $p > 0.05$.$

Hepatic parenchyma of WR-PSGF showed several hepatic lobules separated from each other by delicate connective tissue septa that served as repositories to the portal triad. Additionally, the hepatic lobules were consisted of thin walled central vein surrounded by hepatic cords with irregular blood spaces lined by endothelial cells and Von Kupffer cells. The nuclei appeared densely stained (Figure 5A). Also, renal tissues of WR-PSGF showed normal histology of renal corpuscles and tubules. The renal corpuscles were consisted of tuft of blood capillaries surrounded by the Bowman's capsule (Figure 5B).

Hepatic parenchyma of WR-MO showed normal architecture with thin walled central vein surrounded by hepatic cords. Additionally, the nuclei appeared densely stained. Renal tissue of WR-MO showed evidence of loss of cellular architecture.

Discussion

Clinical surveys and animal model experiments have revealed that raised levels of ALT and AST activities are indicative of organ damage; specifically, in pathologic and toxicological events leading to cardiac and hepatic necrosis [29,42-44]. Precisely, earlier studies had associated raised serum ALT activity with non-diabetic non-alcoholic fatty liver disease and insulin resistance [45-50]. In the present study, the ratio of the two amino transferases activity in serum, whereby serum ALT > AST (Figure 1) was an indication that the two non-functional plasma enzymes were of hepatic origin rather than the cardiac tissues [48,51]. Accordingly, the pattern of activity of ALT > AST in serum appeared to correlate with the extent of disarrangement of hepatic

tissue architecture following the consumption PCB-BB - and RCBP - containing diets by corresponding experimental rat groups. It is worthwhile to note that the remarkable histologic alterations in hepatic tissue architecture of WR-RCBP, WR-OT, WR-BV and WR-MO (Figures 6A-9A) were reflections of the significant ($p < 0.05$) activity differentials between their ALT and AST values (Figure 1).

Previous reports have noted that human STBC > $1.0\text{ mg/dL} - 1.2\text{ mg/dL}</math> was diagnostic of hyperbilirubinemia [52,53]. The production of more bilirubin than the normal liver can excrete, failure of a damaged liver to excrete bilirubin produced in normal amounts and in the absence of hepatic damage, obstruction of the excretory ducts of the liver - by preventing the excretion of bilirubin are the underlying causative factors leading to the development of hyperbilirubinemia [52]. Studies have shown that ingestion of certain toxic food substances or compounds can provoke rapid erythrocyte haemolysis [54-57] and interfere with normal functions of the liver [57-60]. Accordingly, the peculiar proximate composition of RCBP as described elsewhere [2,7,8,61] may have caused the comparatively raised STBC in WR-$

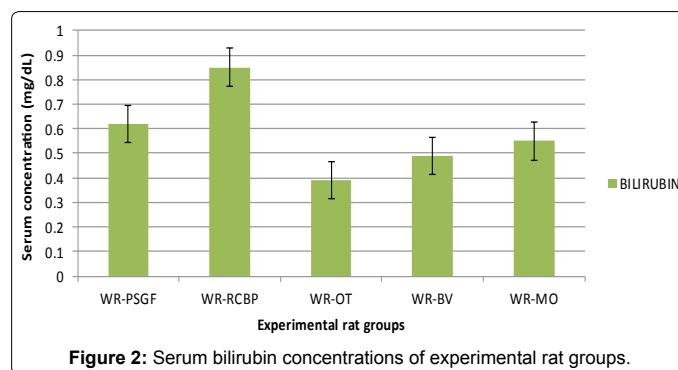


Figure 2: Serum bilirubin concentrations of experimental rat groups.

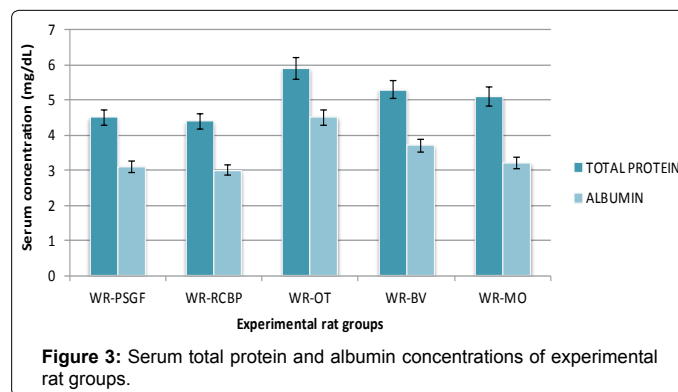


Figure 3: Serum total protein and albumin concentrations of experimental rat groups.

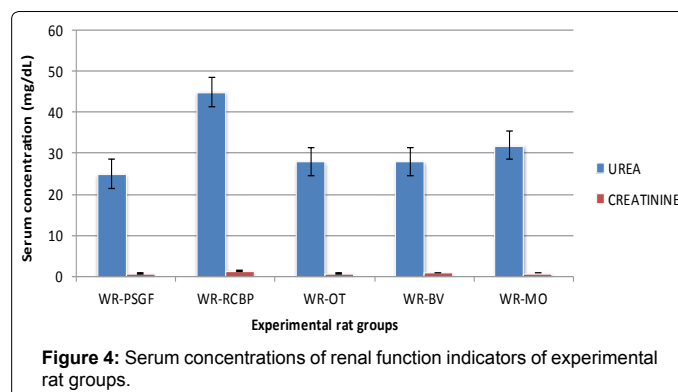


Figure 4: Serum concentrations of renal function indicators of experimental rat groups.

RCBP following the consumption of RCBP - containing diet by the corresponding experimental rat group. Nevertheless, the results of the present study appeared to suggest the absence of hyperbilirubinemia in WR-RCBP, WR-OT, WR-BV and WR-MO in spite of the moderate histological changes in their hepatic tissues (Figures 6A-8A). It is worthwhile to note that bilirubin and its derivative -biliverdin, by virtue of their anti-oxidant activity, protects mammals against nephropathy, stroke, atherosclerosis and vasculitis [53,62-64] and bilirubin at micro-molar concentrations efficiently scavenged peroxy radicals *in vitro* [53].

Although certain plasma proteins have their origin from the endothelial and plasma cells, most proteins biosynthesized in the hepatocytes eventually find their ways in plasma. Therefore, a compromised hepatic function engenders absence or low circulating levels of plasma proteins with attendant pathophysiological conditions. The plasma proteins have been studied extensively in both humans and animals and the relationship between STPC/SAC and the nutritional status of humans are well established, as typified in cases such as marasmus and kwashiorkor [65]. Comparative assessments of STPC and SAC (Figure 3) did not suggest incident of poor nutritional status in the various experimental rat groups. Specifically, experimental rat groups fed with PCB-BB - containing diets exhibited relatively higher STPC and SAC than those fed with RCBP - containing diet and PSGF. By implication, feeding experimental rats with PCB-BB - and RCBP - containing diets satisfied the minimum physiologic nutritional standards required by the rats. Additionally, the PCB-BB - and RCBP - containing diets - induced moderate changes in hepatic tissues histology of corresponding experimental rat groups did not substantially interfere with the capacity of the hepatocytes to biosynthesized plasma proteins.

Under normal physiologic conditions, urea is the primary vehicle for the excretion of metabolic nitrogen, whose sources are, for the most part, traceable to dietary constituents and body protein turnover [66,67]. Urea is a low threshold substance, which is why it is rapidly cleared from vascular system by the renal system. Therefore, raised level of blood urea nitrogen (BUN) concentration is diagnostic of renal dysfunction. The comparatively raised level of SUC in WR-RCBP (Figure 4) correlated with the structural alteration of the renal tissues as exemplified by the noticeable venous congestion of the tissue section (Figure 6B). However, the moderate degenerated tubules and glomerular tufts of WR-OT and WR-BV as well as moderate congestion of the glomerulus and interstitium of WR-MO did not profoundly affect the functionality of the renal tissues, since the SUC of the corresponding experimental rat groups were comparable with that of the WR-SGFP, whose renal tissue histology revealed normal glomerulus and renal tubules. Likewise, moderate disarrangement renal tissues of the various experimental rat groups did not adversely affect the capacity of their renal tissues to clear the blood of creatinine. Although the present study showed that SUC was greater than SCC in the experimental rat groups as described elsewhere [68-72], previous reports have shown that measurement of SCC offered a more reliable diagnostic parameter than SUC for confirmation of renal dysfunction [73,74]. Furthermore, Kang et al. [75] had earlier noted significant elevation of SUC as against marginal alterations of SCC in streptozotocin-induced diabetic rats that exhibited renal dysfunction, which conformed to the present findings (Figure 4). Creatinine is sourced from the muscle proteins turnover and urinary creatinine concentration is proportionate to muscle mass and remains relatively constant. Accordingly, the approximate equal body weights of the various experimental rat groups dictated the corresponding comparable SCCs of WR-PSGF, WR-RCBP, WR-OT, WR-BV and WR-MO. However, increase in SCC can result from increased ingestion of cooked meat [67].

Conclusion

The pattern of activity of ALT>AST in serum appeared to correlate with the extent of disarrangement of hepatic tissue architecture. The experimental rat groups did not exhibit hyperbilirubinemia. Also,

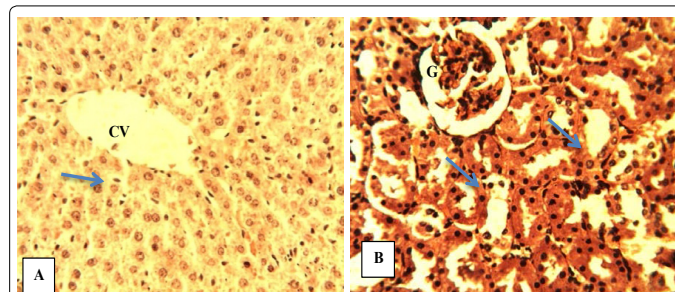


Figure 5: Photomicrograph of sections of organs from WR-PSGF. (A) Normal hepatic tissue with central vein (CV) and Kupffer cells along the sinusoids (blue arrow). (B) Renal tissue showing normal glomerulus (G) and renal tubules (blue arrows); H&E x400.

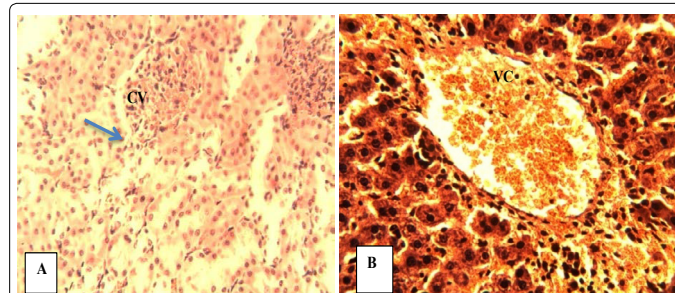


Figure 6: Photomicrograph of sections of organs from WR-RCBP. (A) Hepatic tissue with its central vein (CV) and Kupffer cells along the sinusoids (blue arrow). (B) Renal tissue showing venous congestion (VC); H&E x400.

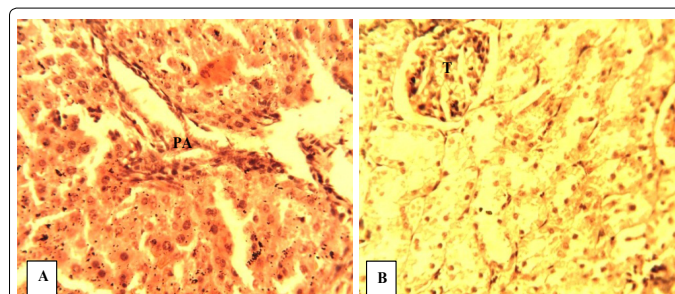


Figure 7: Photomicrograph of sections of organs from WR-OT. (A) Hepatic tissue showing the portal area (PA) with remarkable histologic change. (B) Renal tissue with moderate degenerated tubules and glomerular tufts (T); H&E x400.

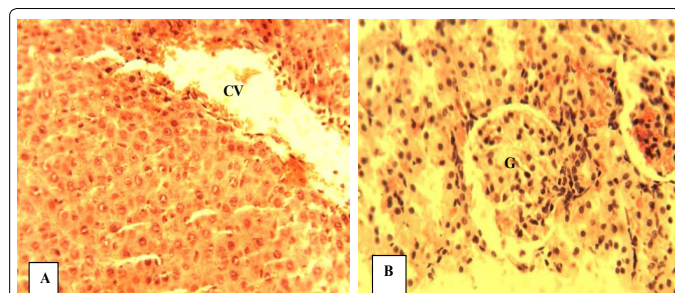


Figure 8: Photomicrograph of sections of organs from WR-BV. (A) Hepatic tissue showing central vein (CV) and moderate disarrangement of hepatocytes. (B) Renal tissue showing moderate hypercellularity of the glomerulus (G); H&E x400.

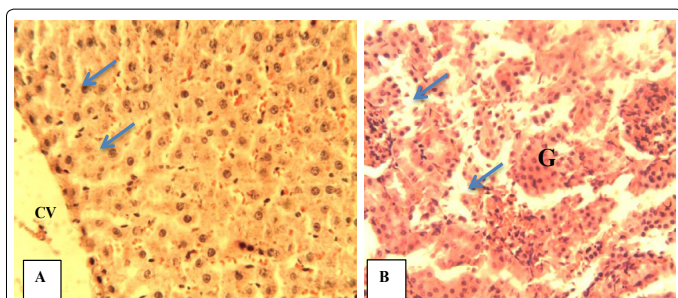


Figure 9: Photomicrograph of sections of organs from WR-MO. (A) Hepatic tissue showing the central vein (CV) and normal plates of hepatocytes (blue arrows), (B) Renal tissue showing moderate congestion of the glomerulus (G) and interstitium (blue arrows); H&E $\times 400$.

PCB-BB - and RCBP - containing diets did not substantially interfere with the capacity of the hepatocytes to biosynthesized plasma proteins and the functionality of renal tissues.

Acknowledgement

The author is grateful for the technical assistance offered by Mr. O.A.K. Emenyonu, Chief Laboratory Technologist, Department of Biochemistry, Imo State University Owerri, and Nigeria.

References

1. International Cocoa Organization (ICCO) (2000) - Annual Report 1997/1998. 1-4.
2. Adeyeye EI, Akinyeye RO, Ogunlade I, Olaofe O, Boluwade JO (2010) Effect of farm and industrial processing on the amino acid profile of cocoa beans. *Food Chem* 118: 357-363.
3. Chin E, Miller KB, Payne MJ, Hurst WJ, Stuart DA (2013) Comparison of antioxidant activity and flavonol content of cacao beans processed by modern and traditional Mesoamerican methods. *Herit Sci* 1: 9.
4. Olaofe O, Onajeta CC (1986) Quality assessment of some cocoa-based beverages in the Nigerian market. *Nig J Nutr Sci* 7: 81-85.
5. Olaofe O, Oladeji EO, Ayodeji OE (1987) Metal contents of some cocoa beans produced in Ondo State, Nigeria. *J Sci Food Agric* 41: 241-244.
6. Ogah CO, Obebe OT (2012) Caffeine content of cocoa and coffee beverages in Lagos, Nigeria. *J Innov Res Eng Sci* 3: 404-411.
7. Ruzaidi A, Amin I, Nawalyah AG, Hamid M, Faizul HA (2005) The effect of Malaysian cocoa extract on glucose levels and lipid profiles in diabetic rats. *J Ethnopharmacol* 98: 55-60.
8. Subhashini R, Rao USM, Sumathi P, Gunalan G (2010) A comparative phytochemical analysis of cocoa and green tea. *Indian J Sci Technol* 3: 188-192.
9. Molina-García L, Ruiz-Medina A, Fernández-de Córdoba ML (2011) Automatic optosensing device based on photo-induced fluorescence for determination of piceid in cocoa-containing products. *Anal Bioanal Chem* 399: 965-972.
10. Khan N, Monagas M, Andres-Lacueva C, Casas R, Urpi-Sardà M, et al. (2012) Regular consumption of cocoa powder with milk increases HDL cholesterol and reduces oxidized LDL levels in subjects at high-risk of cardiovascular disease. *Nutr Metab Cardiovasc Dis* 22: 1046-1053.
11. Ibero-Baraibar I, Abete I, Navas-Carretero S, Massis-Zaid A, Martinez JA, et al. (2014) Oxidised LDL levels decreases after the consumption of ready-to-eat meals supplemented with cocoa extract within a hypocaloric diet. *Nutr Metab Cardiovasc Dis* 24: 416-422.
12. Oluwafemi F, Ayanwande B (2008) Ochratoxin A in cocoa beans and cocoa based beverages in Nigeria: Traceability from farmgate to export outlet. *Nig Food J* 26.
13. Oke DO, Omotayo KF (2012) Effect of forced-air artificial intermittent drying on cocoa beans in South-Western Nigeria. *J Cereal Oil Seed* 3: 1-5.
14. Oyetunji TO (2013) Mycological evaluation of a ground cocoa-based beverage. *Afr J Microbiol* 1: 33-36.
15. Aremu CY, Agiang MA, Ayatse JO (1995) Nutrient and antinutrient profiles of raw and fermented cocoa beans. *Plant Foods Hum Nutr* 48: 217-223.
16. Olubaniwa O, Ikoy SM, Adebowale BA, Omojola AB, Hamzat RA (2006). Effect of boiling time on the utilization of cocoa bean shell in laying hen feeds. *Int J Poultry Sci* 5: 1137-1139.
17. Dauda WRW, Taliba MZM, Kyib TM (2007) Drying with chemical reaction in cocoa beans. *Drying Technol Int J* 25: 867-875.
18. Farah DMH, Zaibunnisa AH, Misnawi J, Zainal S (2012) Effect of roasting process on the concentration of acrylamide and pyridines in roasted cocoa beans from different origins. *APCBEE Procedia* 4: 204-208.
19. Jumnongporn R, Chaiseri S, Hongsprabhas P, Healy JP, Meade SJ et al (2012) Cocoa protein crosslinking using Maillard chemistry. *Food Chem* 134: 375-380.
20. Krysiak W, Adamski R, Zyzelewicz D (2013) Factors affecting the color of roasted cocoa bean. *J Food Qual* 36: 21-31.
21. Stadler RH, Hughes G, Guillaume-Gentil O (2014) Safety of food and beverages: Coffee, tea and herbals, cocoa and derived products. *Food Mater Technol Risk* 3: 371-383.
22. Rankin CW, Nriagu JO, Aggarwal JK, Arowolo TA, Adebayo K, et al. (2005) Lead contamination in cocoa and cocoa products: isotopic evidence of global contamination. *Environ Health Perspect* 113: 1344-1348.
23. Tortajada M, MartAnez-Culebras PV, Navarro V, Monzo H, Ramon D (2009) Evaluation of DNA extraction methods for PCR detection of fungal and bacterial contamination in cocoa extracts. *Eur Food Res Technol* 230: 79-87.
24. Jayeola CO, Oluwadun A, Yahaya LE, Dongo LN, Ajao AA, et al. (2011) Comparative analysis of detecting ochratoxin A in cocoa powder samples using high performance liquid chromatography (HPLC) and enzyme-linked immunosorbent assay (ELISA). *Afr J Food Sci* 5: 513-521.
25. Copetti MV, Iamanaka BT, Pereira JL, Lemes DP, Nakano F, et al. (2012) Determination of aflatoxins in by-products of industrial processing of cocoa beans. *Food Addit Contam Part A Chem Anal Control Expo Risk Assess* 29: 972-978.
26. Sugatani J, Wada T, Osabe M, Yamakawa K, Yoshinari K, et al. (2006) Dietary inulin alleviates hepatic steatosis and xenobiotics-induced liver injury in rats fed a high-fat and high-sucrose diet: association with the suppression of hepatic cytochrome P450 and hepatocyte nuclear factor 4alpha expression. *Drug Metab Dispos* 34: 1677-1687.
27. Shaker E, Mahmoud H, Mnaa S (2010) Silymarin, the antioxidant component and Silybum marianum extracts prevent liver damage. *Food Chem Toxicol* 48: 803-806.
28. Singh SN, Vats P, Suri S, Shyam R, Kumria MM, et al. (2001) Effect of an antidiabetic extract of *Catharanthus roseus* on enzymic activities in streptozotocin induced diabetic rats. *J Ethnopharmacol* 76: 269-277.
29. Adedara IA, Abolaji AO, Odion BE, Okwudi IJ, Omolaja AA, et al. (2014) Impairment of hepatic and renal functions by 2,5-hexanedione is accompanied by oxidative stress in rats. *J Toxicol* 2014: 239240.
30. Liu CM, Ma JQ, Sun YZ (2010) Quercetin protects the rat kidney against oxidative stress-mediated DNA damage and apoptosis induced by lead. *Environ Toxicol Pharmacol* 30: 264-271.
31. Bednarski W (1986) Principles of Food Technology, Ed. ART, Olsztyn, Poland. p. 175.
32. Fapohunda SO, Afolayan A (2012) Fermentation of cocoa beans and antimicrobial potentials of the pod husk phytochemicals. *J Phys Pharm Adv* 2: 158-164.
33. Ibegbulem CO, Chikezie PC (2013) Hypoglycemic properties of ethanolic extracts of *Gongronema latifolium*, *Aloe perryi*, *Viscum album* and *Allium sativum* administered to alloxan-induced diabetic albino rats (*Rattus norvegicus*). *Pharmacogn Commun* 3: 12-16.
34. Hoff N (2000) Methods of blood collection in the mouse. *Lab Ani* 29: 47-53.
35. Reitman S, Frankel S (1957) A colorimetric method for the determination of serum glutamic oxalacetic and glutamic pyruvic transaminases. *Am J Clin Pathol* 28: 56-63.
36. Pearlman FC, Lee RT (1974) Detection and measurement of total bilirubin in serum, with use of surfactants as solubilizing agents. *Clin Chem* 20: 447-453.

37. Gornall AG, Bardawill CJ, David MM (1949) Determination of serum proteins by means of the biuret reaction. *J Biol Chem* 177: 751-766.
38. Dourmas BT, ArdWatson W, Biggs HG (1971) Albumin standards and the measurement of serum albumin with bromocresol green. *Clinica Chimica Acta* 31: 87-96.
39. Fawcett JK, Scott JE (1960) A rapid and precise method for the determination of urea. *J Clin Pathol* 13: 156-159.
40. Bonsnes RW, Taussky HH (1945) On the colorimetric determination of creatinine by the Jaffe reaction. *J Biol Chem* 158: 581-591.
41. Bancroft JD, Stevens A, Turner DR (1996) Theory and practice of histological techniques, 4th Ed. Churchill Livingstone, New York, London, San Francisco, Tokyo.
42. Eidi A, Eidi M, Esmaili E (2006) Antidiabetic effect of garlic (*Allium sativum* L.) in normal and streptozotocin-induced diabetic rats. *Phytomedicine* 13: 624-629.
43. Cho BO, Ryu HW, Jin CH, Choi DS, Kang SY, et al. (2011) Blackberry extract attenuates oxidative stress through up-regulation of Nrf2-dependent antioxidant enzymes in carbon tetrachloride-treated rats. *J Agric Food Chem* 59: 11442-11448.
44. Suanarunawat T, Ayuthaya WD, Songsak T, Thirawarapan S, Pongshompoo S (2011) Lipid-lowering and antioxidative activities of aqueous extracts of *Ocimum sanctum* L. leaves in rats fed with a high-cholesterol diet. *Oxid Med Cell Longev* 2011: 962025.
45. Sattar N, Scherbakova O, Ford I, O'Reilly DJ, Stanley Adrian, Forrest E, et al. (2004) Elevated alanine aminotransferase predicts new-onset type 2 diabetes independently of classical risk factors, metabolic syndrome, and C-reactive protein in the West of Scotland coronary prevention study. *Diabetes* 53: 2855-2860.
46. Fraser A, Harris R, Sattar N, Ebrahim S, Davey Smith G, et al. (2009) Alanine aminotransferase, gamma-glutamyltransferase, and incident diabetes: the British Women's Heart and Health Study and meta-analysis. *Diabetes Care* 32: 741-750.
47. Kuzhandai velu V, Jyothirmayi B, Kumar JS (2011) Insulin resistance and alanine amino transaminase (ALT) levels in first degree relatives of type 2 diabetes mellitus. *Diabetes Metab Syndr* 5: 143-147.
48. Omagari K, Takamura R, Matsutake S, Ichimura M, Kato S, et al. (2011) Serum alanine aminotransferase concentration as a predictive factor for the development or regression of fatty liver. *J Clin Biochem Nutr* 49: 200-206.
49. Ghamar-Chehreh ME, Amini M, Khedmat H, Alavian SM, Daraei F et al. (2012) Elevated alanine aminotransferase activity is not associated with dyslipidemias, but related to insulin resistance and higher disease grades in non-diabetic non-alcoholic fatty liver disease. *Asian Pac J Trop Biomed* 2: 702-706.
50. de Luis DA, Aller R, Izaola O, Gonzalez Sagrado M, Conde R, et al. (2013) Role of insulin resistance and adipocytokines on serum alanine aminotransferase in obese patients with type 2 diabetes mellitus. *Eur Rev Med Pharmacol Sci* 17: 2059-2064.
51. Sherlock S, Dooley J (1997) Diseases of the liver and biliary system, (10th edn). Oxford: Blackwell Science 17-21.
52. Murray RK (2003) Porphyrins and bile pigments. In: Murray RK, Granner DK, Mayes PA, Rodwell VM. *Harper's Illustrated Biochemistry*. 26th Ed. Lange Medical Books/McGraw-Hill. NY. p. 270-287.
53. Toya K, Babazono T, Hanai K, Uchigata Y (2014) Association of serum bilirubin levels with development and progression of albuminuria, and decline in estimated glomerular filtration rate in patients with type 2 diabetes mellitus. *J Diabetes Investig* 5: 228-235.
54. D'Mello JPF (2000) Anti-nutritional factors and mycotoxins. In: *Farm animal metabolism and soybeans*. CAB International Wallingford, UK p. 383-403.
55. Frank JE (2005) Diagnosis and management of G6PD deficiency. *Am Fam Physician* 72: 1277-1282.
56. KovalkoviA ovA N, SutiakovA I, Pistl J, Sutiak V (2009) Some food toxic for pets. *Interdiscip Toxicol* 2: 169-176.
57. Tadele Y (2015) Important anti-nutritional substances and inherent toxicants of feeds. *Food Sci Qual Manage* 36: 40-47.
58. Wu F (2010) The global burden of disease caused by foodborne aflatoxin. WHO Commissioned Report, Foodborne Disease Burden Epidemiology Reference Group (FERG)?
59. Ashraf MW (2012) Determination of aflatoxin levels in some dairy food products and dry nuts consumed in Saudi Arabia. *Food Public Health* 2: 39-42.
60. Ruzaidi AM, Abbe MM, Amin I, Nawalyah AG, Muhajir H (2008) Protective effect of polyphenol-rich extract prepared from Malaysian cocoa (*Theobroma cacao*) on glucose levels and lipid profiles in streptozotocin-induced diabetic rats. *J Sci Food Agric* 88: 1442-1447.
61. Minife BW (1989) *Chocolate, cocoa and confectionary* (3rd Ed.). London: Chapman and Hall.
62. Stocker R, Yamamoto Y, McDonagh AF, Glazer AN, Ames BN (1987) Bilirubin is an antioxidant of possible physiological importance. *Science* 235: 1043-1046.
63. Fujii M, Inoguchi T, Sasaki S, Maeda Y, Zheng J, et al. (2010) Bilirubin and biliverdin protect rodents against diabetic nephropathy by downregulating NAD(P)H oxidase. *Kidney Int* 78: 905-919.
64. Cheryath P, Gorrepati VS, Peters I, Nookala V, Murphy ME, et al. (2010) High Total Bilirubin as a Protective Factor for Diabetes Mellitus: An Analysis of NHANES Data From 1999 - 2006. *J Clin Med Res* 2: 201-206.
65. Bender DA, Mayes PA (3003) Nutrition, digestion and absorption. In: Murray RK, Granner DK, Mayes PA, Rodwell VM. *Harper's Illustrated Biochemistry*. (26th edn) Lange Medical Books/McGraw-Hill, NY pp. 404-480.
66. Rodwell VW (2003) Catabolism of proteins and amino acids nitrogen. In: Murray RK, Granner DK, Mayes PA, Rodwell VM. *Harper's Illustrated Biochemistry*. (26th edn) Lange Medical Books/McGraw-Hill, NY pp. 242-248.
67. Samra M, Abcar AC (2012) False estimates of elevated creatinine. *Perm J* 16: 51-52.
68. El-Demerdash FM, Yousef MI, El-Naga NI (2005) Biochemical study on the hypoglycemic effects of onion and garlic in alloxan-induced diabetic rats. *Food Chem Toxicol* 43: 57-63.
69. Atangwho IJ, Ebong PE, Eteng MU, Eyong EU, Obi AU (2007) Effect of *Vernonia amygdalina* Del leaf on kidney function of diabetic rats. *Int J Pharmacol* 3: 143-148.
70. Shokeen P, Anand P, Murali YK, Tandon V (2008) Antidiabetic activity of 50% ethanolic extract of *Ricinus communis* and its purified fractions. *Food Chem Toxicol* 46: 3458-3466.
71. Etuk EU, Igboke V, Ajagbonna OP, Egua MO (2009) Toxicological studies of a Nigerian commercial polyherbal product in albino rats. *Res J Med Plant* 3: 52-60.
72. Meera KS, Vasudha KC, Sushmitha J (2011) The study of serum uric acid levels in non-insulin dependent diabetes mellitus (NIDDM). *Asian J Pharm Biol Res* 1: 260-266.
73. Shemesh O, Golbetz H, Kriss JP, Myers BD (1985) Limitations of creatinine as a filtration marker in glomerulopathic patients. *Kidney Int* 28: 830-838.
74. Orok UE, Eneji EG, Luke OU, Eyo RA, Sampson EV, et al. (2012) Effect of ethanolic root and twig extracts of *Gongronema latifolium* (utazi) on kidney function of streptozotocin induced hyperglycemic and normal wistar rats. *J Med Med Sci* 3: 291-296.
75. Kang KS, Kim HY, Yamabe N, Nagai R, Yokozawa T (2006) Protective effect of sun ginseng against diabetic renal damage. *Biol Pharm Bull* 29: 1678-1684.

This article was originally published in a special issue, [Let food be thy medicine and medicine be thy food](#) handled by Editor(s). Dr. Meena Shah, Texas Christian University, USA