

Erythromelalgic Thrombotic Thrombocytopenia (ETT) and Hemorrhagic Thrombocytopenia (HT) in Patients with Essential Thrombocythemia (ET) and Polycythemia Vera (PV)

Jan Jacques Michiels*

Academic Hospital Dijkzigt, Erasmus University Rotterdam (EUR 1974-1998), Department of Hematology, Antwerp University Hospital, Belgium, and Goodheart Institute, Bloodcoagulation and Vascular Medicine Center, Rotterdam, (1998-2014) The Netherlands

Abstract

We analysed between 1908 and 1985 of two hundred cases of thrombocytopenia from the literature between 1908 and 1985. Erythromelalgic, acrocyanotic ischemia and digital gangrene, cerebral or coronary ischemic events (erythromelalgic thrombotic thrombocytopenia: ETT) in 99 thrombocytopenia patients (essential thrombocytopenia: ET N=67 and polycythemia vera: PV N=32) occurred at platelet counts in excess of $400 \times 10^9/L$. Hemorrhagic complications at time of presentation of hemorrhagic thrombocytopenia (HT) in 100 HT patients included melana and/or hematemesis, skin bleedings (bruises, subcutaneous hematomas, painful hematomas after trauma, ecchymoses, but not petechiae, epistaxis and gum bleeding and secondary bleeding after trauma or surgery. ETT occurred at an early stage of thrombocytopenia with a mean platelet count of $1110+477 \times 10^9/L$, whereas HT occurred at significantly higher platelet counts in excess of $1000 \times 10^9/L$ with a mean platelet count of $2016+1070 \times 10^9/L$. HT patients frequently had a previous history of ETT or paradoxical occurrences of both thrombosis and bleeding (ETT/PHT). The degree of thrombocytopenia determined the sequential occurrence of ETT, HT in ET and PV patients. Hypersensitive thrombocytopenic platelets (sticky platelets) are involved in the etiology of platelet-mediated thrombosis at platelet counts above $400 \times 10^9/L$ whereas bleedings at high platelet count is related to an acquired von Willebrand syndrome processes on top of a blood clot retraction disturbance with erythrocyte fall out, that causes painful subcutaneous hematomas with a central swelling (clot) after a blow, trauma and secondary bleeding after surgery in thrombocytopenia patients.

Keywords:

Erythromelalgia and Arterial Thrombosis in ET and PV 1878-1980

Mitchell [1] reported on a rare vaso-motor neurosis of the extremities and labeled it as erythromelalgia (erythros=red, melos=extremity, and algos=pain) in the footnote of his article. Mitchell demonstrated that typical erythromelalgia in one or more toes may progress into unbearable intense burning, throbbing, and aching pain, complicated by neurologic ischemic attacks and visual disturbances in one and the same patient. The occurrence of erythromelalgia in polycythemia is very well known in the literature since 1908 [2-5], (Norman and Allen). Osler in 1908 noted that there has been cases of PV in which pain in the hands and feet with the extreme congestion is suggestive for the erythromelalgia of Weir Mitchell [1]. In 1929, Oppenheimer recognized that the erythromelalgic symptom complex was often the earliest symptom of PV and even may precede PV for more than 10 years. He distinguished two types of peripheral circulatory symptoms in PV: 1) the erythromelalgic syndrome, and 2) occlusion of peripheral arteries by thrombi (thromboangiitis obliterans) in later stages of the disease. Two of his patients suffered from erythromelalgia and recurrent attacks of dizziness and had platelet counts of 560 to $620 \times 10^9/L$. The peripheral microvascular symptoms at diagnosis of PV in 100 cases from the study of Brown and Griffin [4] were erythromelalgia in 6, acroparesthesias of burning type in 13, peripheral digital gangrene or ischemia in 8 (erythromelalgic ischemic complications 21%). Similar observations of erythromelalgic microvascular ischemia, amourosis fugax, and transient ischemic attacks and major arterial and venous thrombotic events were observed in the studies of Edwards and Cooley [6], and of Barabas et al. [7] (Table 1).

In 1940 Dameshek and Henstell described recurrent burning pain and cyanosis of several toes of the right foot with gangrene of the third

toe diagnosed as thrombo-angiitis obliterans in PV at platelet count above $1000 \times 10^9/L$ and erythrocyte count above $6 \times 10^{12}/L$ [8]. These observations prompted Dameshek in 1940 to suggest the possibility of "platelet thrombophilia" with multiple small peripheral vascular thromboses (thromboangiitis obliterans). In 1937 Nygaard and Brown [9] described a 47-year-old man with recurrent burning, painful, red toes during a 10-year follow-up ultimately complicated by blister formation and gangrene of the right fourth and fifth toes in a case with persistent increase of peripheral blood platelet count in myeloproliferative thrombocytopenia. Annets and Tracy [10] and Vreeken and van Aken [11] described microvascular painful ischemia of the toes as first manifestation of ET. Alarcon-Segovia et al. [12] recognized aspirin-sensitive erythromelalgia as a clue to the early diagnosis of ET and PV, but phlebotomy did not improve the erythromelalgic burning pain (cases 5, 6, 7 in Table 2).

Discovery of Aspirin-responsive Erythromelalgia in Thrombocytopenia

Between 1970 and 1973 we discovered that aspirin responsive burning red extremities (erythromelalgia) is causally related to thrombocytopenia in ET and PV patients (Figure 1). Acroparesthesias, for example tingling, "pins and needles" sensations, and numbness

*Corresponding author: Jan Jacques Michiels, Goodheart Institute, Bloodcoagulation and Vascular Medicine Center, Erasmus Tower, Veenmos 13, 3069 AT Rotterdam, The Netherlands, Tel: +81-22-717-7312; Fax: +81-22-717-7316; E-mail: goodheartcenter@upcmail.nl

Received September 15, 2014; Accepted October 09, 2014; Published October 17, 2014

Citation: Michiels JJ (2014) Erythromelalgic Thrombotic Thrombocytopenia (ETT) and Hemorrhagic Thrombocytopenia (HT) in Patients with Essential Thrombocythemia (ET) and Polycythemia Vera (PV). J Hematol Thromb Dis 2: 169. doi: [10.4172/2329-8790.1000169](https://doi.org/10.4172/2329-8790.1000169)

Copyright: © 2014 Michiels JJ. This is an open-access article distributed under the terms of the Creative Commons Attribution License, which permits unrestricted use, distribution, and reproduction in any medium, provided the original author and source are credited.

A. Vascular manifestations as the intial symptom of PV in 26 patients according to Edwards abd Cooley 1970	
Painful or unclean toes (good pulses in 6, fairly good pulses in 2)	8
Painful fingers and good pulses	2
Major ischemia of a lower limb (with arteriosclerosis in 2)	3
Cerebral vascular disease (not specified)	5
Coronary heart disease (not specified)	2
Total	20
B. Vascular Complications in 200 PV patients according to Barabas et al.	
Cerebrovascular accidents	
Transient ischemic attack, facial weakness, or aphasia (TIA)	26
Permanent neurologic loss (Preceded by TIA I 6)	13
Attack of transient blindness (amaurosis fugax)	4
Peripheral artery disease	
Sudden ischemia of toe or finger(amputation of 1 or more digits in 10)	15
Femoral artery occlusion and amputated toe in the past	3
Femoral artery occlusion without preceding ischemia of the toes	7
Coronary heart disease (not specified)	10
Total arterial thrombotic complications	78
	In 68 patients (34%)
Superficial thrombophlebitis	30
Deep venous thrombosis	26
Splanchnic vein thrombosis	5
Pulmonary embolism	4
Priapism	1
Total venous thrombotic complications	66 in 57 patients (28%)

Table 1: Vascular manifestations.

Case	Age year	Platelets x10 ⁹ /L	Hb g%	Ht	Erythrocytes		Aspirine sensitive erythromelalgia
					x10/L	Diagnosis	
1	62	352	17	0.61	6.1	PV	hands and feet since 6 years
2	62	-	13	0.50	6.0	PV	feet since 12 years
3	68	-	19	0.74	8.1	PV	feet since 2 years
4	43	373	17.3	0.61		PV	right foot since 5 years
5	70	1049	15.6	-	5.8	ET/PV	feet since 14 years, phleb no effect
6	62	-	14	0.51	5.1	ET	right foot phlebotomy no effect
7	61	837	17	0.62	6.3	PV	left hand foot, phleb no effect
8	57	-	12.4	-	-	MPD	foot big toe developed MMM

Table 2: Erythromelalgia as a clue to early diagnosis of myeloproliferative disorders (MPD), Alarcon-Segovia et al 1966.

in the toes or fingers, usually precede the disabling and burning distress, and aspirin promptly relieves pain for approximately three days [13-15]. A few cases of erythromelalgia associated with primary (essential) thrombocytopenia has been recognized in the 1970s [16-20]. Between 1974 and 1977 Weatherley-Mein clearly documented that erythromelalgia was the presenting feature of primary (essential) thrombocytopenia. Preston et al. [21] interpreted the burning painful and ischemic digital circulation disturbances as thrombotic thrombocytopenia. Between 1975 and 1981 we demonstrated that aspirin responsive erythromelalgia is a pathognomonic manifestation of thrombocytopenia in ET and PV patients is caused by platelet-mediated inflammation and thrombosis in the end-arterial circulation (Figure 1). Aspirin relieves the peripheral, cerebral and ocular ischemic disturbances by irreversible inhibition of platelet cyclooxygenase (COX) activity and aggregation ex vivo and vitamin K antagonist (Warfarin), dipiridamol, ticlopedine, sulfinpyrazone and sofiom salicytlate have no effect on platelet COX activity and are ineffective in the treatment thrombocytopenia-specific manifestations of erythromelalgia and migraine-like ischemic attacks (MIAs) (Figure 2), [13-15]. Aspirin responsive erythromelalgia in thrombocytopenia appeared to be utterly dissimilar from aspirin resistent incurable primary erythromelalgia and secondary erythromelalgia in SLE or RA patients [22-24]. Erythromelalgia disappeared by correction of platelet

counts to normal (<350 × 10⁹/L) in ET and PV, but not by correction of hemoglobin to normal by bloodletting in PV patients [13,15].

Delineation of HT in Various Myeloproliferative Disorders 1923-1980

Minot and Buckmann recognized in 1923 [25] a bleeding tendency of ecchymosis, nose bleeds, and secondary bleedings but absence of pectechiae in association with persistent increased platelet count in a case of polycythemia vera. Rosenthal [26] recognized a group of post-splenectomy patients with persistent increase of platelet counts in excess of 1000 × 10⁹/L associated with hemorrhagic or thrombotic complications. Thrombocytopenia may be associated with both a hemorrhagic diathesis as well as thrombotic complications in one and the same patient [27,28]. Epstein and Goedel [29] introduced the term hemorrhagic thrombocytopenia (HT) for a disease entity featured by recurrent gums and nose bleeds associated with very high platelet count of 1735 × 10⁹/L and atrophic spleen in a 56 year old man This case was previously described as a case with “hochgradigen Thrombocytenvermehrung=high grade platelet increase” by Epstein and Kretz [30]. Similar case histories are described in the literature under a diversity of terms including hemorrhagic thrombocytopenia (Uotila, Reid, Mortensen, Woodrow and Lope, Hardisty and Wolf,

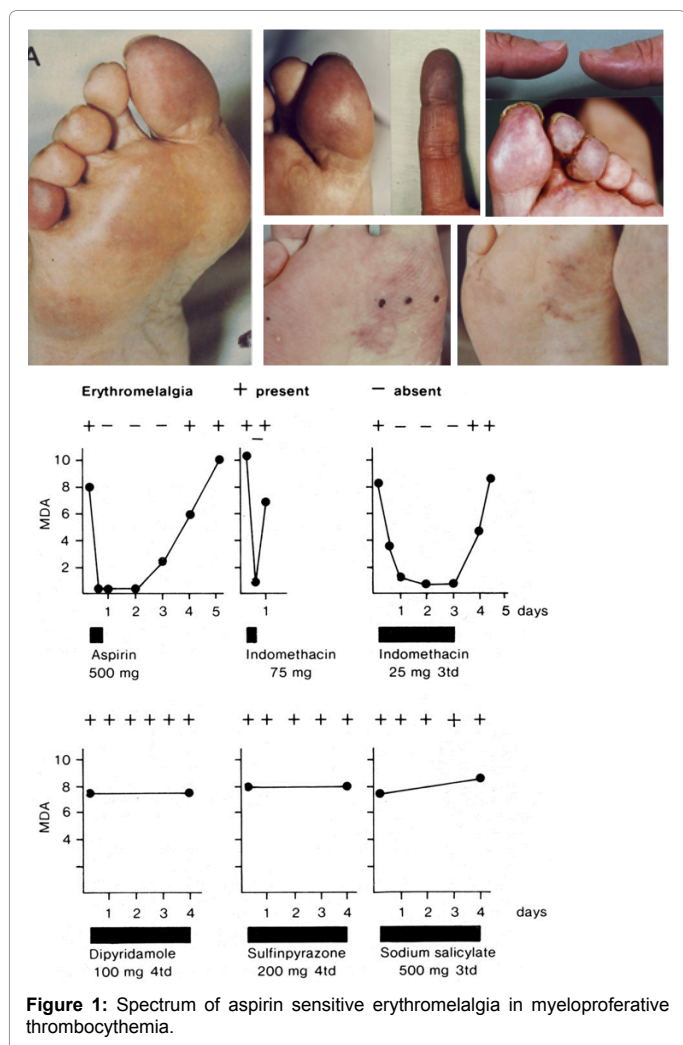


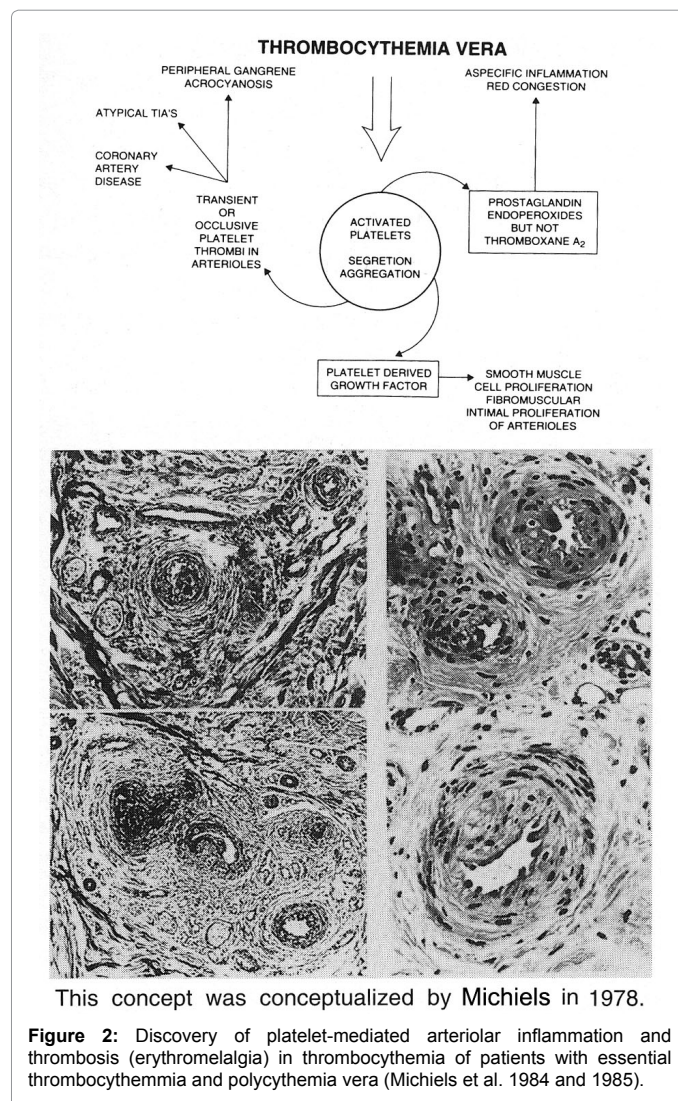
Figure 1: Spectrum of aspirin sensitive erythromelalgia in myeloproliferative thrombocythemia.

Binswanger et al., Koller and Bounameaux, Spaet and Bauer, Fountain, Gunz, Shaw, Fountain and Losowsky, Webb et al., Cronberg et al., Hall, Ohler et al., Bensiger et al., and the Polycythemia Vera study Group, PVSG [31-45]) primary hemorrhagic thrombocythemia, [28,46-48] primary thrombocythemia [49], essential thrombocythemia [50-53], persistent thrombocythemia [54], thrombocythemia [55-57], postsplenectomy thrombocythemia [58], thrombocytosis [59], hemorrhagic thrombocytosis [60,61], myelose hyperthrombocytairie [62] and hyperplaquetose [63].

According to Reid [34], Fanger et al. [55], Ozer et al. [28] and Silverstein [48] HT may be part of or clearly associated with polycythemia vera, chronic myeloid leukemia, or myelofibrotic myeloid metaplasia. Others labeled HT as a distinct disease even when associated with other myeloproliferative diseases like polycythemia vera and myelofibrotic myeloid metaplasia [31]. According to Dameshek in 1950 [64], the cause of the hemorrhagic diathesis of polycythemia is obscure. Bleedings do not ordinarily occur spontaneously but only in response to trauma as with a blow or following operative procedures. Extreme degrees of postoperative hematomas are common, and excessive bleeding occurs after dental extractions, tonsillectomy, polypectomy and similar procedures. Based on the analysis of 50 cases from the literature and 5 of his own, Gunz [42] defined hemorrhagic thrombocythemia (HT) as clinical syndrome of recurrent spontaneous hemorrhages often

preceded by thromboses, extremely high platelet count in excess of $1000 \times 10^9/L$, frequently splenomegaly, and hypochromic anemia with a tendency towards polycythemia between hemorrhages. Inclusion and exclusion

Bleeds from nose gums and gastrointestinal tract were most frequent followed by bruises and bleedings after trauma or surgery, whereas "thrombocytopenic purpura" were never seen. HT is obviously related to cases of primary or essential thrombocythemia, polycythemia vera, and agnogenic myeloid metaplasia (AMM). About half of the patients diagnosed as HT first come to medical attention via an emergency episode of acute bleeding or impending vascular occlusion. Spontaneous hemorrhages in HT typically develop at superficial cutaneous and mucosal surfaces, manifesting primarily as epistaxis, bruising, painful hematomas, ecchymoses, and bleeding from the gastrointestinal tract. Life threatening hemorrhage is infrequent and usually follows accidental or surgical trauma. When death occur, it was usually due to major thrombosis and much less frequent to hemorrhages. Deep tissue bleeding like joints bleeds seen in hemophilia, muscles hematomas, and intracerebral hemorrhage is very rare. Petechiae specific for thrombocytopathia of Glanzmann or Bernard Soulier or severe thrombocytopenia are never seen.



This concept was conceptualized by Michiels in 1978.

Figure 2: Discovery of platelet-mediated arteriolar inflammation and thrombosis (erythromelalgia) in thrombocythemia of patients with essential thrombocythemia and polycythemia vera (Michiels et al. 1984 and 1985).

Diagnosis	ET	PV	ETT
Number of patients			
Erythromelalgia without peripheral gangrene	24	15	49
Erythromelalgia → peripheral digital gangrene	23	8	31
Peripheral gangrene (thromboangiitis obliterans)	6	4	10
Erythromelalgia and/or digital gangrene	53	27	80
Treatment for digital ischemia			
Sympathectomy	4	1	5
Amputation toe	6	2	8
Sympathectomy and toe amputation	5	-	5
Sympathectomy and/or amputation toe total	15	3	18
Angina pectoris	6	-	6
Myocardial infarction	3	3	6
Angina pectoris and/or myocardial infarction	9	3	12
Transient cerebral ischemic attack TIA	3	3	6
Amaurosis fugax	1		1
TIA → hemiparesis	2	2	4
Hemiparesis	6	2	8
TIA and/or hemiparesis	12	7	19
Deep venous thrombosis	3	-	3
Pulmonary embolism	2	-	3
Superficial thrombophlebitis	3	-	3
Localisation of erythromelalgia and/or digital ischemia (thromboangiitis obliterans) in 80 cases with ETT (Michiels 1981)			
Diagnosis	ET	PV	ETT
Toes	35	17	51
Toes/sole of the foot	9	6	15
Ankles	3		3
Fingers	3	1	4
Toes and fingers	4	4	8
Total	52	27	80

Table 3: Erythromelalgia and peripheral ischemic circulation disturbances in 99 cases with erythromelalgic thrombotic thrombocythemia (ETT) subdivided 67 cases with ET and 32 cases with PV from Tables 3 and 4.

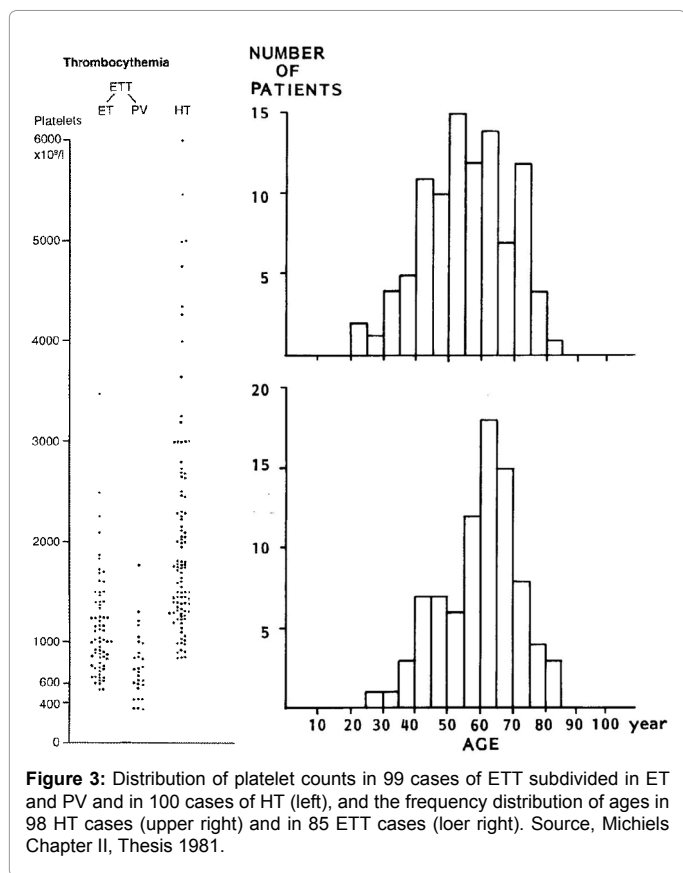
Delineation of Erythromelalgic Thrombotic Thrombocythemia (ETT) in ET and PV

Vreeken and van Aken [11] described a patient with aspirin-responsive recurrent painful toes and fingers (erythromelalgia) in ET. Peripheral gangrene [21], microvascular ischemic or occlusive disease [18,65], and peripheral arterial thrombosis has been recognized as presenting symptoms of ET. Bernstein et al. [66] found ischemic signs on the electrocardiograms (ECG) in two ET patients with angina pectoris and “Prinz Metal” angina pectoris with transient increased of ST-segment on ECG but a normal coronary angiogram has been observed in a 40-year-old man with ET [67]. Weber [68] reported a case of PV (hemoglobin 117%, erythrocytes $8.2 \times 10^{12}/L$, and platelets $700 \times 10^9/L$) who had frequent attacks of ophthalmic migraine, which was associated with transient diplopia. Sometime there had been luminous visual phenomena, and at times he had transient attacks of giddiness. Neurologic manifestations in ET patients varied from recurrent attacks of transient ischemic attacks (TIA) to persistence of neurological deficits. Unilateral migraine-like headache, amaurosis fugax preceded by scotomas trigeminus neuralgia, aphasia, dysarthria, central facialis paresis, transient paresis of one arm, leg or hemiparesis, persistent hemiparesis and organic vascular dementia have been frequently noted in ET patients [69-75]. Two ET patient became blind caused by thrombotic occlusion of the arteria centralis retinae. Singer [73] and Mundall et al. [75] observed attack of amaurosis vasospasm followed by white-yellow particle flowing from central to peripheral retina on funduscopy, which disappeared together with complete recovery of the visus.

Smith and Allen first discovered that a single dose of acetyl salicylic acid (aspirin) produced marked relief of the burning erythromelalgic distress that persisted for a few days. Bab et al. [76] distinguished primary from secondary erythromelalgia associated with PV, systemic lupus erythematodes (SLE) or rheumatoid arthritis (RA) and stated that the response to aspirin is characteristic enough to constitute a valuable diagnostic clue for the diagnosis of erythromelalgia. Alarcon-Segovia et al. documented that aspirin-responsive erythromelalgia was a clue to early diagnosis in 8 PV patients associated thrombocythemia in 4 (Table 2). The spectrum of microvascular manifestations, cerebrovascular accidents, acute coronary artery syndromes superficial thrombophlebitis deep vein thrombosis and splanchnic vein thrombosis at time of diagnosis in the 1970s of 226 PV patients are shown in Table 3. Post-splenectomy thrombocytosis in MPD patients is typically persistent and complicated by bleeding and thrombotic complications [77-79]. Reactive thrombocytosis is not associated with thrombotic or bleeding complications (McClure et al., Zucker and Mielke, Ginsburg, Coons et al.) [80]. The incidence of venous thrombosis is low in transient reactive post-splenectomy thrombocytosis [78,81,82]. Bleeding and thrombosis are rare in Ph+CML associated with persistent thrombocytosis [83].

Objective of the ETT vs. HT Literature Study Anno 1980 (Michiels Thesis 1981)

Between 1975 and 1980, the author of this monography discovered that erythromelalgic thrombotic complications in thrombocythemia (ETT) occurred at slightly increased platelet counts ($>400 \times 10^9/L$) in ET and PV patients, whereas hemorrhagic complications in thrombocythemia (HT) in myeloproliferative disorders tend to occur



the age distribution of 85 case histories of ETT is shown in Figure 3. Burning painful red or blue extremities, in retrospect very suggestive of erythromelalgia, were reported in 80 ETT cases. Peripheral (digital) gangrene developed in 31 cases. Eleven patients presented with peripheral gangrene without a record on burning. In 51 of the 62 evaluable cases, the peripheral arterial pulses were reported to be normal indicating the absence of significant atherosclerotic disease. Sympathectomy in 10 cases with digital gangrene (thromboangiitis obliterans) never induced improvement of the peripheral vascular insufficiency. Transient ischemic or thrombotic complications of the cerebral or coronary circulation were recorded in 12% and 19% of the cases, respectively. Deep vein thrombosis, pulmonary embolism and superficial thrombophlebitis of one or both leg rarely occurred (3% each).

The hemorrhagic symptoms of 100 case histories from the literature between 1933 to 1978 are shown in Table 4. The age distribution of 98 HT patients is shown in Figure 3. Gastrointestinal blood loss usually occurred as melena and/or hematemesis. A bleeding source could not be detected, neither roentgenologically in 19 out of 24, nor gastroscopically in 8 out of 9 patients investigated. In a few cases, the bleeding source could not be localized even at laparotomy. Nose bleeds in 33 patients were generally profuse and relapsed frequently. The typical gingival bleeding in 15 patients usually occurred after tooth extraction. Skin bleedings were either recorded as bruises in 18 as subcutaneous hematomas in 15, and as ecchymoses or sugillations in 10 out of 34 patients. In some cases painful subcutaneous hematomas started with or had a central nodule (very likely a thrombotic clot), which extended to large hemorrhagic effusions. Petechiae characteristic for severe thrombocytopenia or congenital thrombasthenia of Glanzmann were never seen.

Cutaneous Bleedings		34 PHT patients
Bruises, bruising	18	
Subcutaneous hematomas	10	
Ecchymoses	15	
Nose bleeds	33	33 HT patients
Gum bleeds	15	15 HT patients
Secondary bleeds, trauma surgery	29	29 HT patients
Gastrointestinal (GI) blood loss	50	50 HT patients
Melena and hematemesis	12	
Melena	17	
Hematemesis	6	
Occult blood loss	4	
No details of GI blood loss	11	
Total type of bleeds in 100 PHT	161	1.6 main type of bleeds per PHT patient

Table 4: Main Type of Bleeding Manifestations in 100 reports of hemorrhagic thrombocytopenia (HT).

at platelet counts in excess of $1000 \times 10^9/L$. In order to document a relationship between platelet count and clinical complication of thrombosis or hemorrhages I reviewed in 1980 the spectrum erythromelalgic, thrombotic and hemorrhagic manifestations and hematological findings in 200 consecutive thrombocytopenia cases published in the literature between 1929 and 1980. The 99 ETT cases histories from the literature could be diagnosed as ET (N=67) and PV (N=32) and the 100 HT cases in thrombocytopenia of various MPDs were reported in the literature between 1908-1980 and published in my thesis [13].

Results in 99 ETT and 100 HT patients

The platelet number in ETT patients subdivided in ET and PV and

Arterial and/or venous thrombosis preceded or followed the hemorrhagic periods in 15 out of 100 HT cases (15%) (Table 5). One HT case developed recurrent gangrene of the toes 4 years following the hemorrhagic manifestations [29,30]. The thrombotic manifestations preceding the hemorrhagic diathesis were described as painful acrocyanosis in 3, gangrene of toes in 5, transient neurologic ischemic attacks in 3 and hemiparesis in 2, superficial thrombophlebitis in 3, priapism in 3 and deep vein leg thrombosis in one case only (Table 5). In 7 of 99 ETT cases (7%) hemorrhagic complications are recorded; subcutaneous hematomas in 2, ecchymosis in 1, melena in 1 and secondary bleeding after surgery in 3 cases (Table 5).

Post-splenectomy HT

The spleen in 64 evaluable ETT patients was not palpable in 27, slightly to moderately enlarged in 36 and greatly enlarged to below the costal margin in only 3. The spleen in 67 evaluable HT patients was not palpable in 17, slightly to moderately enlarged in 26 and greatly enlarged to below the umbilical level in 21 cases. In 2 ETT patients a splenectomy had been performed. In 20 HT patients, splenectomy was performed (spleen weight in excess of 1 kilogram) had induced a post-splenectomy thrombocytopenia complicated by bleedings (see section post-splenectomy HT) (Table 6). At time of splenectomy portal vein thrombosis was diagnosed in 2 and thrombosis of vena lienalis in 4 patients. Platelet counts in these 6 patients with splanchnic vein thrombosis was normal in 4 and strongly increased in 2. The majority of post-splenectomy HT patients (90%) had no bleeding manifestations at time of splenectomy. Platelet count at time of splenectomy was normal in 8, increased between $400-1000 \times 10^9/L$ in 3, increased above $1000 \times 10^9/L$ in 3, and not stated in 6 cases (Table 6). In the 3 cases with platelet counts of $>1000 \times 10^9/L$ had bleeding manifestation during or

A. Preceding arterial or venous thrombosis in 15 out of 100 case histories (15%) of hemorrhagic thrombocytopenia (HT)			
HT case	Author	Year	Type of thrombotic complication
1	Epstein	1933	Recurrent gangrene of toes followed by toe amputation
2	Uotila	1938	Transient hemiparesis, superficial thrombophlebitis left leg
3	Mortensen	1948	Painful cyanosis of first and fifth right toes
4	McGabe	1955	Painful cyanosis of fingers of the right hand
5	Shaw	1955	Hemiparesis, peripheral circulation disturbances of one foot
6	Hardisty	1955	Venous thrombosis left leg
7	Hardisty	1955	Painful foot sole and ischemic ulcerations fifth right toe
8	Hardisty	1955	Cerebral thrombosis, priapism
9	Baikie	1958	Transient hemiparesis
10	Gunz	1960	Superficial thrombophlebitis both legs
11	Gunz	1960	Gangrene in fourth and fifth right toes
12	Ozer	1960	Gangrene of the toes, priapism
13	Ozer	1960	Burning pain in feet and finger, transient attacks of dysarthria
14	Fountain	1962	Superficial thrombophlebitis of one leg
15	Ougier	1964	Priapism

B. The occurrence of bleeding complications in 7 of 99 reports of Erythromelalgic Thrombotic Thrombocytopenia (ETT).			
EET case	Author	Year	Type of bleeding complication
1	Moolten	1949	Subcutaneous hematoma
2	Fanger	1954	Subcutaneous hematoma
3	Shaw	1961	Ecchymoses
4	Champion	1963	Melena
5	Singh and Weitherley-Mein	1977	Secondary bleeding after surgery in 3 ETT cases
6	Hussein	1978	Secondary bleeding after surgery in 3 ETT cases

Table 5: Bleeding Complications.

Before Splenectomy		After Splenectomy				
Author /Year	Bleeding symptoms	Platelets×10 ⁹	Bleeding symptoms	Months*	Platelets×10 ⁹	Splen weight
Brughs 1933	-	228	+	24	1735	n.s
Moolten 1949	-	580	+	3	2800	1100
Revol 1950	-	720	+	1	3655	600
Fanger 1954	-	n.s	+	36	4353	n.s
Hardisty 1955	-	Normal	+	1	1750	>1000
	-	n.s	+	3	2735	>1000
Binswanger/Koller 1955/56	-	246	+	6	4050	800
Gunz 1960	-	normal	+	22	4000	>1000
Ozer 1960	-	n.s	+	0	n.s	1000
Pederson 1961	-	n.s	+	n.s	2150	n.s
Fleisher 1962	-	normal	+	38	1289	n.s
Fountain 1962	-	145	+	n.s	1310	568
Ougier 1964	-	1470	+	0	1395	>1000
Cronberg 1965	+	1920	+	0	1433	2200
Silverstein 1968	-	n.s	+	26	1312	280
	+	1000	+	0	1750	1030
	-	normal	+	1	3000	850
	-	n.s	+	3	2000	>1000
	-	510	+	12	2300	1000
Dube 1971	-	270	+	3	1300	>1000

-:absent, +:Present, n.s:not stated, *Time lapse in months between Splenectomy and onset of Bleeding

Table 6: Post-splenectomy hemorrhagic thrombocytopenia (HT) in 20 patients from the literature.

immediately after splenectomy (Table 6). In 17 post-splenectomy cases hemorrhagic manifestation became evident after 1 month in 4, after 3 months in 4, after 6 months in 1 and after one or a few years in 6 cases. At time of HT the platelet counts were far above $1000 \times 10^9/L$ (range 1289-4353, Table 6). The weight of splenectomized spleen was significantly increased except in 1 and not stated in 4 (Table 6). One case of post-splenectomy HT in a 43-years old case was complicated by angina pectoris, myocardial infarction, and transient hemiparesis at platelet count of $1700 \times 10^9/L$ [84], and by erythromelalgia (painful red swollen toes) at platelet count of $900 \times 10^9/L$ in another case [85].

Platelet and leukocyte counts, and bone marrow findings in ETT and HT patients

Platelet counts ranged from 735 to $5000 \times 10^9/L$ in HT and from 352 to $3500 \times 10^9/L$ in ETT (Figure 3). The frequency distribution of the platelet and leukocyte counts in ETT and HT is shown in Table 7. The platelet count of $1059+507 \times 10^9/L$ (mean+SD) in 96 ETT patients was significantly lower ($P<0.001$, Mann-Whitney-U test) than the platelet count of $2050+1107 \times 10^9/L$ in 100 PHT patients. The mean leukocyte count of $25+17 \times 10^9/L$ in 86 PHT patients was significantly higher

Plateletsx10 ⁹ /L	PHT	ETT	Leukocytes x10 ⁹ /L	PHT	ETT
<500	0%	4%	10-Apr	10%	23%
500-1000	7%	47%	15-Oct	21%	46%
1000-1500	32%	31%	15-20	14%	19%
1500-2000	21%	14%	20-90	55%	12%
2000-6000	40%	4%	-	-	-
Mean x10 ⁹ /L	2050	1059	Mean x10 ⁹ /L	25	14
SD	1107	507	SD	17	6
Man-Whitney test	p<0.001		p<0.001		

Table 7: Frequency distribution of platelet and leukocyte counts in 100 cases of hemorrhagic thrombocytopenia (HT) and in 96 cases of erythromelalgic thrombotic thrombocytopenia (ETT). Source Michiels 1981.

A. The 1980 RCP major (A) and confirmative (B) criteria for ET	
A1	Persistent platelet count in excess of 400x10 ⁹ /L.
A2	Increase and clustering of enlarged megakaryocytes in bone marrow biopsy.
A3	No or slight increase of reticulin fibers (RF 0 or RF 1)
B1	Presence of large platelets in a peripheral blood smear
B2	Absence of any underlying disease for reactive thrombocytosis and normal ESR.
B3	No splenomegaly (<12 cm) or slight splenomegaly on palpation or scan (<15 cm)
B4	Increase of LAP-score and no signs of fever or inflammation
Exclusion criterion	
Ph+ chromosome and any other cytogenetic abnormality in blood or bone marrow cells	
B. The 1980 RCP major (A) and minor (B) criteria for PV	
A1	Increased erythrocyte count above 6x10 ¹² /L: Dameshek 1940 [42].
A2	Raised red cell mass. Male >36 ml/kg, female >32 ml/kg: PVSG 1971-1975
A3	Increase in bone marrow biopsy of clustered, large pleomorphic megakaryocytes with hyperlobulated nuclei and increased cellularity due to increased megakaryopoiesis erythropoiesis or typically trilinear mega-erythro-granulopoiesis. typical PV bone marrow excludes erythrocytosis.
B1	Thrombocytopenia, persistent increase of platelet >400x10 ⁹ /L
B2	Leukocytosis, leucocyte count >10 ⁹ /L and low erythrocyte sedimentation rate (ESR)
B3	Raised leukocyte alkaline phosphatase (LAP) score >100, absence of fever or infection
B4	Splenomegaly on palpation or on isotope/ultrasound scanning
A1 or A2 plus A3 and none of B establishes erythrocythemic PV	
A1 or A2 plus A3 plus one of B establishes PV and excludes erythrocytosis	

Table 8: The Rotterdam Clinical and Pathological (RCP) criteria for Essential Thrombocytopenia (ET) and Polycythemia Vera (PV) 1975-1980.

than 14+6 × 10⁹/L in 65 ETT patients (P<0.001). This leukocytosis in thrombocytopenia is due to increased mature granulocytes. Half of HT cases had leukocytosis between 20 and 90 × 10⁹/L. In some cases of HT the white blood cell differential count was left-shifted indicative for more advanced MPD disease [19,31,40,54,59,61,63].

The individual platelet in ETT and HT patients is shown in Figure 3. About half of 67 ETT patients had thrombotic complications at platelet counts between 400-1000 × 10⁹/l (Table 8). The majority of symptomatic PV patients had similar microvascular thrombotic complications (ETT) at platelet counts between 375 and 1000 × 10⁹/L (Figure 2). ETT usually persisted when the PV was brought into remission by phlebotomy simple because thrombocytopenia persisted. There was no correlation between increased number of platelets and leukocytes in each of the categories of HT (r=0.07) and ETT (r=0.24).

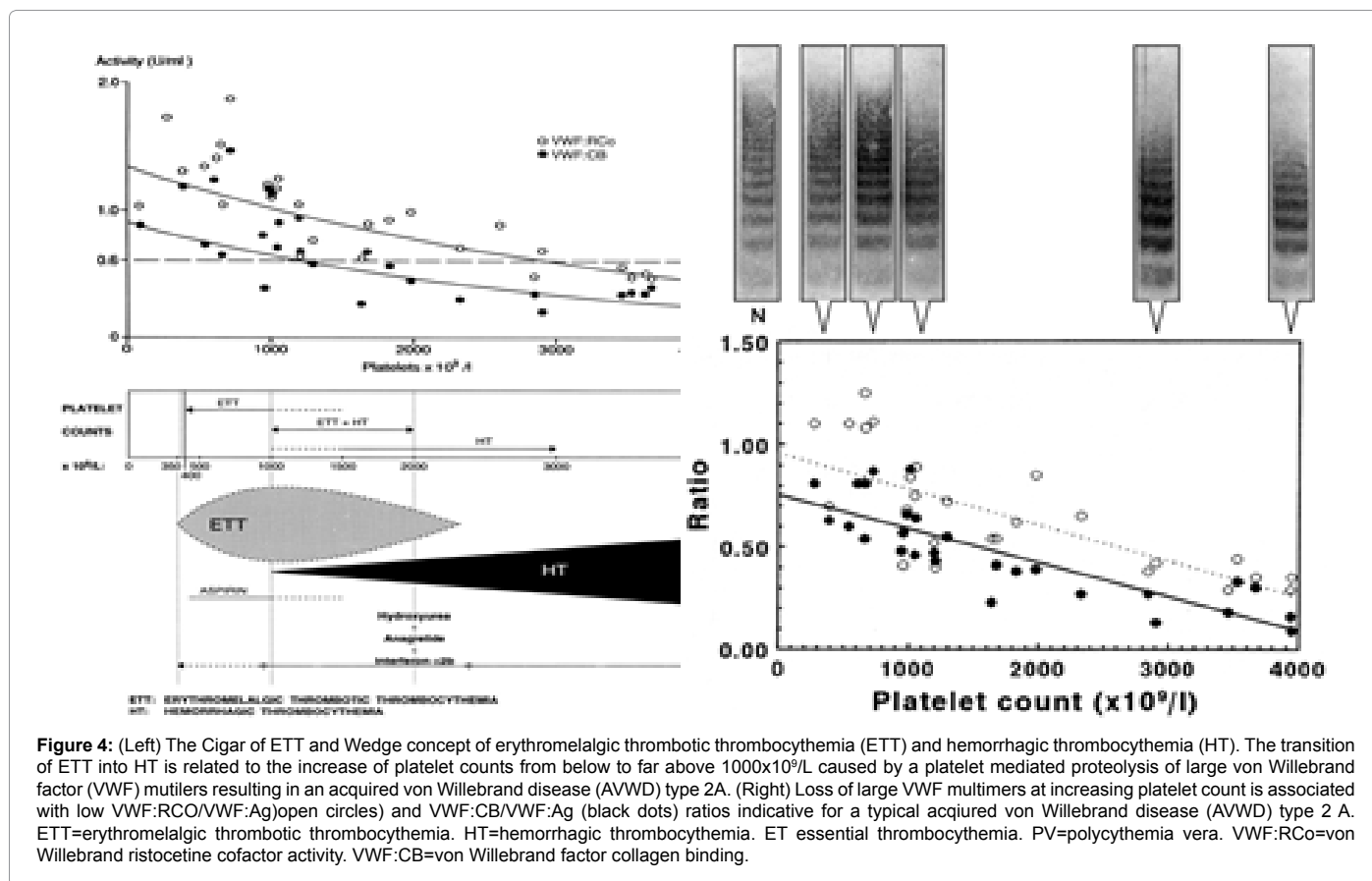
Bone marrow findings, mainly aspirates, in 36 HT and 31 ETT patients showed major increase of mature megakaryocytes and platelet clumps, normoblastic erythropoiesis and normal myelopoiesis thereby excluding erythroleukemia, preleukemia and MDS. In addition peripheral blood and bone marrow findings were consistent with chronic myeloid leukemia in 5 PHT and agnogenic myeloid metaplasia in 4 PHT patients. Between 1960 and 1970, Silverstein observed 47 HT patients in whom the thrombocytopenia was associated with chronic granulocytic leukemia, myeloid metaplasia, or polycythemia vera in eight patients each.

At platelet counts in excess of 800 × 10⁹/L, serum potassium concentrations are always significantly elevated in the presence of normal renal function and normal plasma potassium levels [86-89]. This pseudohyperkalemia in thrombocytopenia of various

myeloproliferative disorders is explained by release of potassium from the platelets during coagulation and clot retraction [23,90].

Discussion

The PVSG criteria in 1975 for the diagnosis of hemorrhagic thrombocytopenia were and crude and required a minimal platelet count in excess of 1000 × 10⁹/L [91] thereby overlooking symptomatic ET patients who presented with ETT at platelet counts above 400 × 10⁹/L (Michiels et al. [15]). Focusing on the causal relation between erythromelalgia and thrombocytopenia in ET and PV patients, we were able to document since 1975 the very early stage of ET by the use of the Rotterdam Clinical and Pathological (RCP) criteria for ET and PV [92,93]. The 1980 RCP criteria of ET and PV were determined by careful prospective documentation of peripheral blood and bone marrow smears and bone marrow biopsy material [93]. Platelets in excess of 400 × 10⁹/L, and an increase of clustered enlarged megakaryocytes in a bone marrow biopsy material was found to be diagnostic for ET and excluded reactive thrombocytosis. On top of the clinical PVSG criteria for PV [46] we introduced in 1980 bone marrow histopathology and erythrocyte count above 6 × 10¹²/L proposed by Dameshek in 1940 [94] as specific clues to the diagnosis of PV to clearly differentiate PV from all variant of primary and secondary erythrocytosis. The 1980 RCP modifications of the 1975 PVSG criteria for PV include 4 main changes [13]. First, the major criterion O₂-saturation of >92% is replaced by absence of primary or secondary erythrocytosis by clinical and laboratory tests. Second; splenomegaly is replaced by bone marrow histology as a major criterion (A3). Third, the 1980 RCP diagnostic set used splenomegaly as a minor criterion. Fourth, we skipped raised B12 (>900 ng/L) or raised B12 binding capacity (>2200 ng/L) as completely irrelevant for the diagnosis of early and overt stage PV.



The follow-up of the Rotterdam MPD Working Group (1975-1995) on the efficacy and safety for the prevention and treatment of thrombotic complications in 68 ET patients seen in the Academic Hospital Rotterdam has been critically evaluated by Perry van Genderen et al. [95,96]. The therapeutic implications from the prospective Rotterdam ET studies are completely in line with the concept that microcirculatory thrombotic complications in thrombocytopenia already occur at platelet counts in excess of 400 × 10⁹/L, which are relieved by reduction of platelet counts to normal (<400 × 10⁹/L) or by control of platelet function with low dose aspirin. At time of presentation 54 patients had ET related microvascular thrombotic complications at platelet counts between 575 and 1031, mean 750 × 10⁹/L and treated with low-dose aspirin. In patients receiving platelet lowering agents either busulfan or hydroxyurea and no aspirin, thrombotic complications occurred frequently during follow-up at platelet counts above 400 × 10⁹/L (624 ± 255 × 10⁹/L), indicating that inadequate control of platelet number in thrombocytopenia of ET and PV patients is associated with a persistent high incidence of microvascular disturbances including MIAs when not on aspirin at platelet counts above 350 to 400 × 10⁹/L. One low dose aspirin reduces the risk of microvascular ischemic or thrombotic complications from above 50% to less than 5% during 6.2 years of follow-up, and thereby prevented the progression from low thrombotic risk to high risk thrombotic in ET and PV (Van Genderen et al. [95,96]). Aspirin in ET at platelet counts above 1000 × 10⁹/l in general daily practices is not safe enough in terms of bleedings elicited by aspirin indicating the need to add non-leukemogenic platelet lowering agents. Thrombocytopenia with platelet counts in excess of 1000+250 × 10⁹/L is frequently associated with the paradoxical occurrence of thrombosis and bleeding. Mucocutaneous bleedings spontaneously

occur at platelet count in excess of 1000+250 × 10⁹/L due to an acquired type II-like von Willebrand syndrome (AVWS, absence of high and intermediate von Willebrand factor (VWF) multimers) increasing in severity at increasing platelet counts to high levels above 1000 to 1500 × 10⁹/L (Figure 4, Van Genderen et al. [95]. Reduction of platelet count by anagrelide, interferon (or hydroxyurea if anagrelide and interferon fail) to less than 1000 × 10⁹/L will result in the persistence of microvascular thrombotic events and the disappearance of the bleeding symptoms and AVWS (Figure 4). Correction of the platelet counts to normal is associated with no recurrences of microvascular events and complete correction of the VWF-multimeric pattern and correction of all VWF-parameters to complete normal values.

References

1. Mitchel SW (1878) On a rare vaso-motor neurosis of extremities and on the maladies with which it may be confounded. *Amer J Med Sc* 76: 2-36.
2. Osler W (1908) A clinical lecture on erythraemia. *Polycythemia vera with cyanosis. Maladie du Vasques. Lancet* 1: 143-145.
3. Oppenheimer BS (1929) Vascular occlusion in polycythemia vera. *Tr Am Physicians* 44: 338-344.
4. Brown GF, Giffin HZ (1930) Peripheral arterial disease in polycythemia vera. *Arch Int Med* 46: 705-717.
5. Brown GF (1932) Erythromelalgia and other disturbances of the extremities accompanied by vasodilatation and burning. *Amer J M Sc* 183: 468-485.
6. Edwards EA, Cooley MH (1970) Peripheral vascular symptoms as the initial manifestation of polycythemia vera. *JAMA* 214: 1463-1467.
7. Barabas AP, Offen DN, Meinhard EA (1973) The arterial complications of polycythaemia vera. *Br J Surg* 60: 183-187.
8. Dameshek W, Henstell HH (1940) The diagnosis of polycythemia. *Ann Intern Med* 13: 1360-1387.

9. Nygaard KK, Brown GE (1937) Essential thrombophilia. *Arch Int Med* 59: 82-106.
10. Annetts DL, Tracy GD (1966) Idiopathic thrombocythemia presenting with ischaemia of the toes: report of three cases. *Med J Aust* 2: 180-183.
11. Vreeken J, van Aken WG (1971) Spontaneous aggregation of blood platelets as a cause of idiopathic thrombosis and recurrent painful toes and fingers. *Lancet* 2: 1395-1397.
12. Alarcon-Segovia D (1973) Erythromelalgia in systemic lupus erythematoses. *Am J Science* 226: 149-151.
13. Michiels JJ (1981) Erythromelalgia and thrombocytopenia. Thesis, Erasmus University Rotterdam.
14. Michiels JJ, Ten Kate FW, Vuzevski VD, Abels J (1984) Histopathology of erythromelalgia in thrombocythemia. *Histopathology* 8: 669-678.
15. Michiels JJ, Abels J, Steketeer J, van Vliet HH, Vuzevski VD (1985) Erythromelalgia caused by platelet-mediated arteriolar inflammation and thrombosis in thrombocytopenia. *Ann Intern Med* 102: 466-471.
16. Bierme R, Boneu B, Guiraud B, Pris J (1972) Aspirin and recurrent painful toes and fingers in thrombocythemia. *Lancet* 1: 432.
17. Redding KG (1977) Thrombocytopenia as a cause of erythromelalgia. *Arch Dermatol* 113: 468-471.
18. Singh AK, Wetherley-Mein G (1977) Microvascular occlusive lesions in primary thrombocythemia. *Br J Haematol* 36: 553-564.
19. Hardisty RM, Wolff HH (1955) Haemorrhagic Thrombocythemia: A Clinical And Laboratory Study. *Br J Haematol* 1: 390-405.
20. Vera JC (1979) Antiplatelet agents in the treatment of thrombotic complications of primary thrombocytopenia. *Can Med Assoc J* 120: 60-61.
21. Preston FE, Emmanuel IG, Winfield DA, Malia RG (1974) Essential thrombocythemia and peripheral gangrene. *Br Med J* 3: 548-552.
22. Michiels JJ, van Joost T (1990) Erythromelalgia and thrombocytopenia: a causal relation. *J Am Acad Dermatol* 22: 107-111.
23. Michiels JJ, van Genderen PJ, Lindemans J, van Vliet HH (1996) Erythromelalgic, thrombotic and hemorrhagic manifestations in 50 cases of thrombocytopenia. *Leuk Lymphoma* 22 Suppl 1: 47-56.
24. Van Genderen PJ, Michiels JJ (1995) Hydroxyurea in essential thrombocytopenia. *N Engl J Med* 333: 802-803.
25. Minot GR, Buckman ThE (1923) Erythema (polycythemia rubra vera). *Amer J Med Sci* 166: 469-489.
26. Rosenthal RL (1949) Blood Coagulation In Leucemia And Polycythemia; Value of the Heparin Clotting Time and Clot Retraction Rate. *J Lab Clin Med* 34: 1321-1335.
27. Wasserman LR, Vroman L, Gelin G (1958) [Hemorrhages & thromboses in the course of essential thrombocytopenia; concerning 3 personal observations]. *Sang* 29: 560-571.
28. Ozer FL, Traux WE, Miesch DC, Levin WC (1960) Primary hemorrhagic thrombocytopenia. *Am J Med* 28: 807-823.
29. Epstein E, Goedel A (1934) Haemorrhagische Thrombocythemia bei vasculärer Schrumpfmilz. *Virch Arch* 293: 233-247.
30. Epstein E, Hretz J (1930) Ueber einen Fall von hochgradiger Thrombocytenvermehrung. *Klin Wchschr* 25: 1177-1178.
31. McCabe WR, Bird RM, McLaughlin RA (1955) Is primary hemorrhagic thrombocytopenia a clinical myth? *Ann Intern Med* 43: 182-190.
32. Shaw S, Oliver RA (1958) primary hemorrhagic thrombocythemia. *Proc r soc med* 51: 768-772.
33. Uotila U (1938) On hemorrhagic thrombocytopenia. *Acta Med SWcand* XCV: 136-150.
34. Reid J (1940) Haemorrhagic thrombocytopenia. *Lancet* II: 584-587.
35. Mortensen O (1948) Thrombocytopenia Hemorrhagica. *Acta Med Scand* 129: 547-559.
36. Woodrow JC, Cope S (1955) Haemorrhagic thrombocythemia treated with radioactive phosphorus. *Br Med J* 2: 1069.
37. Binswanger D, Schaub F, Scheitlin W (1955) [Hemorrhagic Diathesis Caused By Excessive Production of Blood Platelets (Thrombocytopenia Hemorrhagica)]. *Acta Haematol* 14: 383-386.
38. Bounameaux Y, Koller F (1956) [Hemorrhagic Diathesis After Splenectomy (Hemorrhagic Thrombocytopenia)]. *Bull Schweiz Akad Med Wiss* 12: 248-260.
39. Spaet TH, Gaynor E, Goldstein ML (1969) Defective platelets in essential thrombocytopenia. *Arch Intern Med* 124: 135-141.
40. Fountain JR, Losowsky MS (1962) Haemorrhagic Thrombocythemia and Its Treatment with Radioactive Phosphorus. *Q J Med* 31: 207-220.
41. Fountain JR (1958) Haemorrhagic Thrombocythemia; Report of Two Cases Treated With Radioactive Phosphorus. *Br Med J* 2: 126-130.
42. Gunz FW (1960) Hemorrhagic Thrombocytopenia: A Critical Review. *Blood* 15: 706-723.
43. Cronberg S, Nilsson IM, Gydell K (1965) Haemorrhagic thrombocythemia due to defect platelet adhesiveness. *Scand J Haematol* 2: 208-219.
44. Hall WJ 3rd (1965) Hemorrhagic Thrombocytopenia: Report of a Case. *Jama* 192: 912-914.
45. Ohler WG, Friederici L, Castenholz A (1965) [Contribution To The Clinical Picture Of Hemorrhagic Thrombocytopenia]. *Med Welt* 19: 1034-1037.
46. Bensing TA, Logue GL, Rundles RW (1970) Hemorrhagic thrombocytopenia; control of postsplenectomy thrombocytopenia with melphalan. *Blood* 36: 61-69.
47. Murphy S, Iland H, Rosenthal D, Laszlo J (1986) Essential thrombocytopenia: an interim report from the Polycythemia Vera Study Group. *Semin Hematol* 23: 177-182.
48. Silverstein MN (1968) Primary or hemorrhagic thrombocytopenia. *Arch Intern Med* 122: 18-22.
49. Rowlands RA, Vairey JM (1938) Primary thrombocytopenia. *Lancet*: 1217-1222.
50. Owren PA (1934) Essential Thrombocythemia. *Gastroenterology* 68: 148-153.
51. Goudsmit R (1956) [Essential Thrombocytopenia, Chronic Myeloid Leukemia or Polycythemia Vera]. *Ned Tijdschr Geneesk* 100: 1236-1239.
52. Kupfer HG, Ebbels BJ, Miller JN, Thoma GW, Russi S (1958) Essential Thrombocytopenia. *Ann Intern Med* 48: 685-697.
53. Wasserman LR, Bassen F (1959) Polycythemia. *J Mt Sinai Hosp N Y* 26: 1-49.
54. Brugsch H (1933) Persistierende Thrombocythemia und Leukaemie nach Milzentfernung. *Folia Haematol* 1933 Leipzig 49: 454-465.
55. Fanger H, Cella LJ Jr, Litchman H (1954) Thrombocytopenia; Report of Three Cases And Review of Literature. *N Engl J Med* 250: 456-461.
56. Baikie AG, Cunningham TA, McAlpine SG (1958) Thrombocythemia and Thrombocytopenia in the Myeloproliferative Syndromes. *Scott Med J* 3: 26-30.
57. Robertson JH (1970) Uric acid in the treatment of thrombocytopenia. *Blood* 35: 288-297.
58. Dube B, Bajpai HS, Chawla SC, Gupta YN (1971) Platelet defects in post-splenectomy thrombocythemia. *Acta Haematol* 46: 221-227.
59. Hermann RE (1957) Thrombocytopenia, Its Occurrence and Association with Abnormal Bleeding; Report of a Case. *Ann Surg* 145: 238-243.
60. Pedersen B, Videbaek A (1961) A Case Of Haemorrhagic Thrombocytopenia Treated with Cytotoxics. *Acta Haematol* 26: 372-377.
61. Fleischer J (1962) [Persistent Leukemoid Reactions and Hemorrhagic Thrombocytopenia after Exstirpation of The Spleen. Primary Myeloproliferative Syndrome?]. *Folia Haematol (Frankf)* 6: 409-423.
62. Revol L (1950) La myelose hyperplaquettaire. *Thrombocytemie hemorrhagique*. *Sang* 21: 409-423.
63. Ougier J, Page G, Mengus C (1964) [High Platelet Level Discovered after Splenectomy and Treated with Myleran]. *Presse Med* 72: 1959-1961.
64. Dameshek W (1950) Physiopathology and Course of Polycythemia Vera as Related to Therapy. *J Am Med Assoc* 142: 790-797.
65. Rhyner K, Blättler W, Bauer W, Bollinger A (1979) [Primary thrombocytopenia: clinical, pathophysiology and therapeutic possibilities]. *Schweiz Med Wochenschr* 109: 467-471.

66. Bernstein A (1965) Primary thrombocytosis and angina syndrome. *Am J Cardiol* 16: 159-164.
67. Barr I, Cohen P, Berken A, Lown B (1974) Thrombocytopenia and myocardial ischemia with normal coronary angiogram. *Arch Intern Med* 134: 528-533.
68. Weber FP (1934) Erythraemia with migraine, gout and intracardiac thrombosis. *Lancet* 2: 808-809.
69. de Olivarius BF (1957) Cerebral manifestations in thrombocytopenia. *Acta Psychiatr Neurol Scand* 32: 77-82.
70. Kissel P, Faivre G, Craus B, Debry G, Schmitt J, et al. (1957) [Essential Thrombocytopenia]. *Bull Mem Soc Med Hop Paris* 73: 447-453.
71. Alajouanine T, Castaigne P, Fournier E, Cambier J, Auzepy (1958) [Polyneuritis with Ischemic Gangrene of the Fingers in a Woman with Thrombocytopenia; Recovery Following Administration of Radiophosphorus]. *Rev Neurol (Paris)* 98: 772-777.
72. Levine J, Swanson PD (1968) Idiopathic thrombocytopenia. A treatable cause of transient ischemic attacks. *Neurology* 18: 711-713.
73. Singer G (1969) Migrating emboli of retinal arteries in thrombocythemia. *Br J Ophthalmol* 53: 279-281.
74. Korenman G (1969) Neurologic syndromes associated with primary thrombocytopenia. *J Mt Sinai Hosp N Y* 36: 317-323.
75. Mundall J, Quintero P, Von Kaulla KN, Harmon R, Austin J (1972) Transient monocular blindness and increased platelet aggregability treated with aspirin. A case report. *Neurology* 22: 280-285.
76. Babb RR, Alarcon-Segovia d, Fairbairn JF 2nd (1964) Erythromelalgia. Review of 51 cases. *Circulation* 29: 136-141.
77. Rosenthal M (1925) Clinical and hematological studies on Banti's disease. *JAMA* 84: 1887-1891.
78. Hayes DM, Spurr CL, Hutaff LW, Sheets JA (1963) Post-Splenectomy Thrombocytosis. *Ann Intern Med* 58: 259-267.
79. Gordon DH, Schaffner D, Bennett JM, Schwartz SI (1978) Postsplenectomy thrombocytosis: its association with mesenteric, portal, and/or renal vein thrombosis in patients with myeloproliferative disorders. *Arch Surg* 113: 713-715.
80. Ginsburg AD (1975) Platelet function in patients with high platelet counts. *Ann Intern Med* 82: 506-511.
81. Coon WW, Penner J, Clagett P, Eos N (1978) Deep venous thrombosis and postsplenectomy thrombocytosis. *Arch Surg* 113: 429-431.
82. Starksen NF, Day AT, Gazzaniga AB (1978) Does splenectomy result in a higher incidence of limb deep venous thrombosis? *Am J Surg* 135: 202-206.
83. Mason JE Jr, DeVita VT, Canellos GP (1974) Thrombocytosis in chronic granulocytic leukemia: incidence and clinical significance. *Blood* 44: 483-487.
84. Kissel P, Dureux JB, Schmitt J, Tridon P (1958) [Not Available]. *Rev Neurol (Paris)* 98: 766-772.
85. Meilleur PA, Meyers MC (1961) Thrombocytosis: A Postsplenectomy Complication In Agnogenic Myeloid Metaplasia. *Am J Med Sci* 241: 68-82.
86. Hartmann RC, Auditore JV, Jackson DP (1958) Studies on Thrombocytosis. I. Hyperkalemia Due to Release of Potassium From Platelets During Coagulation. *J Clin Invest* 37: 699-707.
87. Frick PG (1960) [Pseudohyperkalemia in Thrombocytosis]. *Schweiz Med Wochenschr* 90: 433-435.
88. Myerson RM, Frumin AM (1969) Hyperkalemia associated with the myeloproliferative disorders. *Arch Int Med* 106: 406.
89. Fink M, Hiller E, Huhn D, Brunswicker F (1979) [Pseudo-hyperkalemia in myeloproliferative diseases (author's transl)]. *Dtsch Med Wochenschr* 104: 1639-1641.
90. Wulkan RW, Michiels JJ (1990) Pseudohyperkalemia in thrombocythemia. *J Clin Chem Clin Biochem* 28: 489-491.
91. Laszlo J (1975) Myeloproliferative disorders (MPD): myelofibrosis, myelosclerosis, extramedullary hematopoiesis, undifferentiated MPD, and hemorrhagic thrombocytopenia. *Sem Hematol* 12: 409-432.
92. Dameshek W(1951) Some speculations on the myeloproliferative syndromes. *Blood* 6: 372-375.
93. Ghosh ML (1972) Primary haemorrhagic thrombocythemia with Philadelphia chromosome. *Postgrad Med J* 48: 686-688.
94. Georgii A, Vykoupil KF, Buhr T, Choritz H, Döhler U, et al. (1990) Chronic myeloproliferative disorders in bone marrow biopsies. *Pathol Res Pract* 186: 3-27.
95. van Genderen PJ, Michiels JJ, van der Poel-van de Luytgaarde SC, van Vliet HH (1994) Acquired von Willebrand disease as a cause of recurrent mucocutaneous bleeding in primary thrombocytopenia: relationship with platelet count. *Ann Hematol* 69: 81-84.
96. van Genderen PJ, Mulder PG, Waleboer M, van de Moesdijk D, Michiels JJ (1997) Prevention and treatment of thrombotic complications in essential thrombocythemia: efficacy and safety of aspirin. *Br J Haematol* 97: 179-184.