

Erythema Multiforme-Like Bullous Pemphigoid Associated with Furosemide

Stefanie A. Hirano*, Ashley R. Mason, Valerie M. Harvey and Antoinette F. Hood

Eastern Virginia Medical School, Department of Dermatology, Norfolk, VA 23507, USA

Abstract

The clinical diagnosis of bullous pemphigoid (BP) can be challenging given the polymorphic nature of the disease. We present a case of erythema multiforme (EM)-like BP in an 80-year-old woman with celiac disease. Skin biopsies showed intraepidermal and subepidermal bullae with direct immunofluorescence (DIF) demonstrating IgG and C3 linear deposition at the basement membrane. The etiology of our patient's BP is unclear but may be associated with furosemide usage and is temporally associated with a flare of celiac sprue. To our knowledge, only four other published cases document EM-like lesions in BP. Atypical presentations of BP should be confirmed with histology and direct immunofluorescence.

Report of a Case

An 80-year-old woman with celiac sprue presented with an acute bullous eruption on the bilateral flexural forearms. She had coincident onset of diarrhea and vomiting which led to dehydration, renal failure,

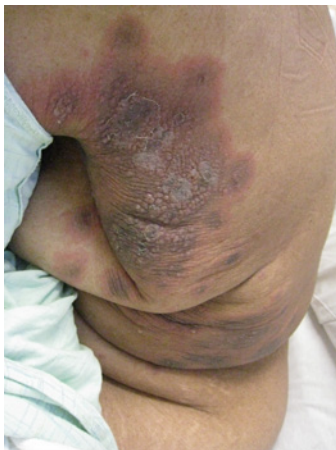

Figure 1: Left flank with erythematous targetoid plaques with dusky centers; forming areas of confluent erythema and coalesced tense vesicles.

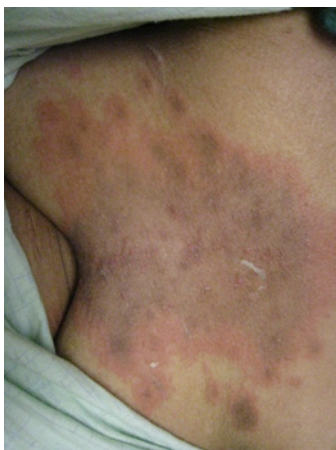

Figure 2: Central chest with erythematous targetoid plaques with dusky centers; forming areas of confluent erythema.

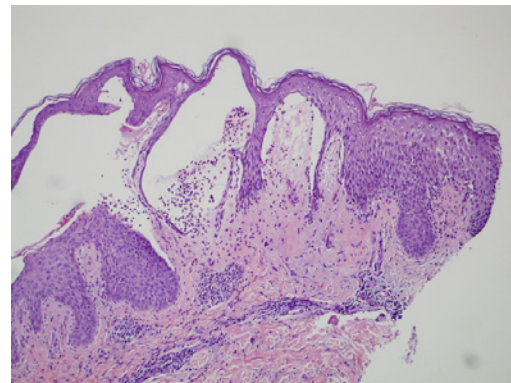


Figure 3: Biopsy of vesicle from flexoral surface of right arm showing intraepidermal and subepidermal bullae, spongiosis with microvesicular formation (hematoxylin and eosin stain; original magnification 100X).

and hospitalization. She denied a history of similar eruptions. Pre-hospitalization medications were unchanged over the past year and included clonidine, olmesartan, simvastatin, diphenoxylate/atropine, omeprazole, and furosemide.

Cutaneous examination revealed erythematous targetoid plaques with dusky centers symmetrically distributed on the chin, neck, flexural forearms, central chest, breasts, flanks, inner thighs, and anterior legs (Figure 1 and Figure 2). In addition, there were numerous tense vesicles and bullae in the same distribution (Figure 1). Palms, soles, and mucous membranes were spared. Laboratory studies revealed a mild leukocytosis and findings consistent with acute renal failure.

***Corresponding author:** Stefanie A. Hirano, MD, Eastern Virginia Medical School, Department of Dermatology, Norfolk, VA 23507, USA. Virginia Clinical Research Incorporated, Dermatology, 601 Medical Tower, Norfolk, VA 23507, USA, Tel: (757) 625-0151; Fax: (757) 625-6212; E-mail: shirano@gmail.com

Received May 02, 2011; Accepted July 14, 2011; Published July 20, 2011

Citation: Hirano SA, Mason AR, Harvey VM, Hood AF (2011) Erythema Multiforme-Like Bullous Pemphigoid Associated with Furosemide. J Clin Exp Dermatol Res 2:123. doi:10.4172/2155-9554.1000123

Copyright: © 2011 Hirano SA, et al. This is an open-access article distributed under the terms of the Creative Commons Attribution License, which permits unrestricted use, distribution, and reproduction in any medium, provided the original author and source are credited.

Histologic examination demonstrated intraepidermal and subepidermal bullae, spongiosis with microvesicular formation, and focal subepidermal vesiculation (Figure 3). Within the bullae, proteinaceous material and an eosinophil-predominant infiltrate were present. In the upper dermis, an intense perivascular infiltrate was composed of neutrophils and numerous eosinophils. Direct immunofluorescence (DIF) demonstrated linear deposits of IgG and C3 at the basement membrane zone. Treatment with the following resulted in clinical improvement: oral prednisone taper starting at 60mg/dL daily, mycophenolate mofetil 1000mg BID, and cessation of furosemide. At 21-month follow-up the patient remained asymptomatic.

Discussion

The clinical diagnosis of bullous pemphigoid (BP) can be challenging in the setting of erythema multiforme (EM)-like lesions. To our knowledge, only four case reports describe EM-like BP [1,2]. In one report, multiple medications—citalopram, thioridazine, and flupenthixol—were suspected, none of which had previously been associated with BP [2]. Three additional cases of EM-like BP describe patients who developed severe bullous eruptions after receiving various penicillins—amoxicillin, penicillin G, and phenoxymethyl penicillin [1]. Of interest, bullous disease with clinical and histological features of both EM and BP has been reported [3].

The diagnosis of BP is based on clinical suspicion but is sometimes difficult as the disease is polymorphic. Therefore, the diagnosis should be confirmed by histology and DIF [4]. In the present case, the clinical diagnosis of bullous EM was initially suspected. However, review of the biopsy specimens suggested BP.

BP is usually idiopathic but may be associated with malignancy, medications, and rarely autoimmune disorders [4]. It is unclear if the presentation of BP in our patient was causally related to her underlying celiac sprue. The onset of diarrhea, presumed to be a flare of celiac sprue, was in fact temporally correlated with the onset of her bullous disease. One documented case exists of BP developing in a child with untreated celiac sprue, however the case lacked sufficient evidence to support a causal relationship between the two conditions [5]. Of note, antigliadin antibody, an autoantibody associated with celiac sprue, can also be found in 40-80% of BP and pemphigus vulgaris patients. However, the presence of antigliadin antibody may be age-related.⁶

Unlike the weak association of BP with autoimmune disorders, furosemide-associated BP has been supported in the literature [4,7,8]. The first report of furosemide-associated BP by Ebringer et al in 1969 described remission upon discontinuation of the medication [7]. Another similar case documented recurrence of BP upon rechallenge with furosemide [8]. Additionally, at least another 8 cases have been reported linking furosemide use with onset of BP [4,9-13]. These cases all involve elderly patients with cardiac disease, renal disease, or both. It does not appear that development of BP while on furosemide is dose or duration dependent [4,7,13]. The authenticity of furosemide-induced BP has been debated; a prospective multi-centered trial failed to demonstrate an association between BP and furosemide [14].

The exact mechanism for furosemide-induced and medication-induced BP is not known, however several immunological mechanisms have been proposed. One theory suggests that the offending medication possibly behaves as an antigenic hapten inducing antibodies to the basement membrane zone via binding to a protein in the lamina lucida and somehow uncovering a hidden antigenic site and altering

its antigenic properties [15-17]. Alternatively, another mechanism proposed that medication-induced antibody production alters T suppressor cell function which then no longer represses certain B cell clones [15]. A third possibility is that sulfur-containing medications, including furosemide, may cause a biochemical dermal-epidermal splitting which occurs independent of immunologic mechanisms [15,18]. There has also been a “two-step” theory for medication-induced BP in which 2 separate medication work together to initiate and exacerbate the disease, suggesting a multi-factorial etiology of medication-induced BP [19].

Our experience emphasizes the need to consider BP in the differential diagnosis of bullous lesions even when morphology is atypical. Moreover, while the pathogenesis of BP remains unclear, the discontinuation of any medication known to be associated with BP induction is prudent when clinically feasible. Furosemide associated BP is rare, yet clinically relevant especially given the widespread use of this medication in the elderly population. Timely discontinuation of furosemide generally leads to resolution of BP.

References

1. Alcalay J, David M, Ingber A, Hazaz B, Sandbank M (1988) Bullous pemphigoid mimicking erythema multiforme: an untoward side effect of penicillins. *J Am Acad Dermatol* 18: 345-349.
2. Mehravaran M, Gyulai R, Husz S, Dobozy A (1999) Drug-induced erythema multiforme-like bullous pemphigoid. *Acta Derm Venereol* 79: 233.
3. Hayakawa K, Shiohara T (2002) Atypical bullous disease showing features of both erythema multiforme and bullous pemphigoid. *Acta Derm Venereol* 82: 196-199.
4. Koch CA, Mazzaferri EL, Larry JA, Fanning TS (1996) Bullous pemphigoid after treatment with furosemide. *Cutis* 58: 340-344.
5. Meenan FO, Cahalane SF (1969) Bullous pemphigoid of childhood and coeliac disease. Report of a case *Br J Dermatol* 81: 777-779.
6. Kumar V, Jain N, Beutner EH, Chorzelski TP (1987) Detection of antigliadin antibodies in bullous diseases and their recognition of similar antigenic polypeptides. *Int Arch Allergy Appl Immunol* 83:155-159.
7. Ebringer A, Adam WR, Parkin JD (1969) Bullous haemorrhagic eruption associated with frusemide. *Med J Aust* 1: 768-771.
8. Fellner MJ, Katz JM (1976) Occurrence of bullous pemphigoid after furosemide therapy. *Arch Dermatol* 112: 75-77.
9. Castel T, Gratacos R, Castro J, Bergada E, Lecha M, et al. (1981) Bullous pemphigoid induced by frusemide. *Clin Exp Dermatol* 6: 635-638.
10. Ingber A, David M, Feuerman EJ (1986) An unusual case: hemorrhagic bullous pemphigoid following furosemide treatment. *Z Hautkr* 61: 1554-1556.
11. Siddiqui MA, Zaman MN (1995) Recurrent and chronic leg ulcers secondary to furosemide-induced bullous pemphigoid. *J Am Geriatr Soc* 43:1183-1184.
12. Baz K, Ikizoglu G, Kaya TI, Koca A (2002) Furosemide-induced bullous pemphigoid. *J Eur Acad Dermatol Venereol* 16: 81-82.
13. Panayiotou BN, Prasad MV, Zaman MN (1997) Frusemide-induced bullous pemphigoid. *Br J Clin Pract* 51: 49-50.
14. Bastuji-Garin S, Joly P, Picard-Dahan C, Bernard P, Vaillant L, et al. (1996) Drugs associated with bullous pemphigoid. A case-control study. *Arch Dermatol* 132: 272-276.
15. Ruocco V, Sacerdoti G (1991) Pemphigus and bullous pemphigoid due to drugs. *Int J Dermatol* 30: 307-312.
16. Bean SF, Good RA, Windhorst DB (1970) Bullous pemphigoid in an 11-year-old boy. *Arch Dermatol* 102: 205-208.
17. Kashihara M, Danno K, Miyachi Y, Horiguchi Y, Imamura S (1984) Bullous pemphigoid-like lesions induced by phenacetin. Report of a case and an immunopathologic study. *Arch Dermatol* 120: 1196-1199.

18. Ruocco V, de Luca M, Pisani M, de Angelis E, Vitale O, et al. (1982) Pemphigus provoked by D(-)penicillamine. An experimental approach using in vitro tissue cultures. *Dermatologica* 164: 236-248.
19. Shachar E, Bialy-Golan A, Srebrnik A, Brenner S (1998) "Two-step" drug-induced bullous pemphigoid. *Int J Dermatol* 37: 938-989.