

## Effects of Nutritional Supplement with $\alpha$ -Lipoic Acid in Patients with Recurrent Pterygium

Jorge Guillermo Hurtado Godinez<sup>1</sup>, Leonel Garcia Benavides<sup>1\*</sup>, Sara Pascoe Gonzalez<sup>1</sup>, Ivan Isidro Hernandez Cañaveral<sup>1</sup>, Francisco Javier Galvez Gastelum<sup>1</sup> and Irinea Yañez Sanchez<sup>2</sup>

<sup>1</sup>INTEC, Departamento de Fisiología, Centro Universitario de Ciencias de la Salud, Universidad de Guadalajara, Jalisco, México

<sup>2</sup>Centro de Investigación en Nanociencia y Nanotecnología, Centro Universitario de los Valles, Universidad de Guadalajara, Jalisco, México

\*Corresponding author: Leonel García Benavides M.D., PhD., Instituto de Terapéutica Experimental y Clínica Departamento de Fisiología, CUCS, U de G, Sierra Mojada 950, edificio P, 1° piso, Colonia Independencia, CP 44340, Guadalajara, Jalisco, México, Tel (52) (33) 10585200 ext. 33659, 33660; Fax (52) (33) 36173499; E-mail: drleonelgb@hotmail.com

Received date: Feb 13, 2014, Accepted date: May 13, 2014, Published date: May 20, 2014

Copyright: © 2014 Godinez JGH, et al. This is an open-access article distributed under the terms of the Creative Commons Attribution License, which permits unrestricted use, distribution, and reproduction in any medium, provided the original author and source are credited.

### Abstract

**Background:** Pterygium is an ocular disease characterized by fibro-proliferative disarray of the corneal surface. Control of oxidative stress with effective antioxidant supplementation, like  $\alpha$ -lipoic acid, could prevent recurrence following surgical resection.

**Materials and methods:** This study was a randomized placebo-controlled, double-blind trial. Seventy patients with recurrent pterygium participated. Oral therapy with  $\alpha$ -lipoic acid or placebo was administered. Pterygium tissue was collected for histological and immunohistochemical analysis.

**Results:** Pterygium recurrence was similar in both groups. A significant increment of fibroelastic tissue was observed in the placebo compared with the  $\alpha$ -lipoic acid group. Number and caliber of blood vessels, extracellular matrix content and presence of inflammatory infiltrated cells decreased in the  $\alpha$ -lipoic acid group. Myofibroblasts were also localized and smaller.

**Conclusions:** Treatment with  $\alpha$ -lipoic acid improved clinical appearances through decreased fibroelastic tissue size. Recurrence was similar. Blood vessels, extracellular matrix content and inflammatory infiltrated cells reduced with  $\alpha$ -lipoic acid.

**Keywords:** Pterygium; Angiogenesis; Extracellular matrix; Antioxidant

### Introduction

Pterygium is an ocular disease that can display aggressive clinical behavior and threaten the vision. Chronic ultraviolet-B radiation (UV-B) exposure has been attributed as a causal agent. Clinically, pterygium can be described as a fibro-proliferative disease of the corneal surface, sometimes bilateral, and usually originating from the nasal bulbar conjunctiva, but also occasionally from the temporal conjunctiva [1,2]. Symptoms associated with pterygium include chronic ocular surface inflammation, tearing, astigmatism and blurred vision due to optical axis involvement on the corneal surface [2].

At the molecular level, pterygium has been reported as an overexpression of several growth factors related with cellular proliferation, such as vascular endothelial growth factor (VEGF), platelet-derived growth factor, transforming growth factor- $\beta$ 1 [3] tumor necrosis factor- $\alpha$ , and basic fibroblast growth factor, all involved in the pathophysiology of pterygium [4,5]. The underlying fibrovascular tissue usually presents a chronic inflammatory cellular infiltrate and rich vasculature. VEGF is involved in angiogenesis and is produced by corneal fibroblasts in response to inflammation or other noxious stimuli, such as ultraviolet (UV) radiation. VEGF has been detected in increased amounts in pterygium epithelium compared

with normal conjunctiva in studies employing immunohistochemistry or RT-PCR [1,2,4,6]. Histologically, pterygium exhibits both degenerative and hyperplastic changes as well as proliferative and inflammatory disorders [4]. Degenerated type I and type IV collagen fibers and immature elastin fibers (elastin dysplasia) or degenerated elastin fibers (elastin dystrophy) have been described. Epithelial changes are variable and include hyperkeratosis, parakeratosis or acanthosis. Fibroblasts at the anterior corneal stroma (underneath Bowman's membrane) may become activated by UV radiation and may cause the Bowman's membrane to rupture, resulting in the firm adherence of pterygium to the under-lying corneal stroma [7]. Fibroblasts isolated from pterygium in a serum-free conditioned medium can induce growth and proliferation, suggesting that pterygium fibroblasts may release proliferative factors [5].

There are several treatment options available, including surgical excision or pharmacological treatments, but postoperative recurrence is common and can be very aggressive, worse than in the beginning [2].

Oxidative stress is considered one of the most important factors involved in the genesis of certain eye diseases, including pterygium, and can lead to the induction of proteins, like 8-hydroxydeoxyguanosine, which has been correlated with DNA oxidation [1,2,8]. Nitrosamine stress has been observed to act as a protective antioxidant agent at physiologic doses, and when administered in large amounts it has oxidizing and apoptotic

properties and enhances VEGF production [9,10]. It is also known that UV radiation increases nitric oxide release by non-enzymatic mechanisms [10]. Epidemiological evidence suggests that UV radiation plays the most important role in the development of oxidative stress [8].

As free radicals are involved in the development of pterygium, effective antioxidant supplementation could have a beneficial effect [2]. Among the antioxidants,  $\alpha$ -lipoic acid has been found in the ocular anterior chamber. It is a powerful antioxidant that is active in both the lipophilic and hydrophilic environments without deleterious consequences.  $\alpha$ -lipoic acid's activity comes from it acting as a scavenger of hydroxyl radicals, hypochlorous acid, peroxynitrite and singlet oxygen.  $\alpha$ -lipoic acid can neutralize reactive oxygen species (ROS) and is indispensable for the regeneration of other antioxidants, such as vitamin E, vitamin C and glutathione [11]. Furthermore, it can also chelate pro-oxidant metals, such as iron and, in some cases, it can repair proteins damaged by ROS [12]. Demir et al. investigated the protective effects of  $\alpha$ -lipoic acid against oxidative damage in rabbit conjunctiva exposed to UV radiation and demonstrated that it induces an increase in superoxide dismutase and glutathione peroxidase enzymes [13]. It has recently been reported in a study using experimental models that  $\alpha$ -lipoic acid could prevent UV-B-induced corneal damage [14].

The aim of this study was to determine the therapeutic effect of oral  $\alpha$ -lipoic acid administration at preventing the recurrence, and to improve the histological and clinical appearance, of pterygium after surgical resection.

## Materials and Methods

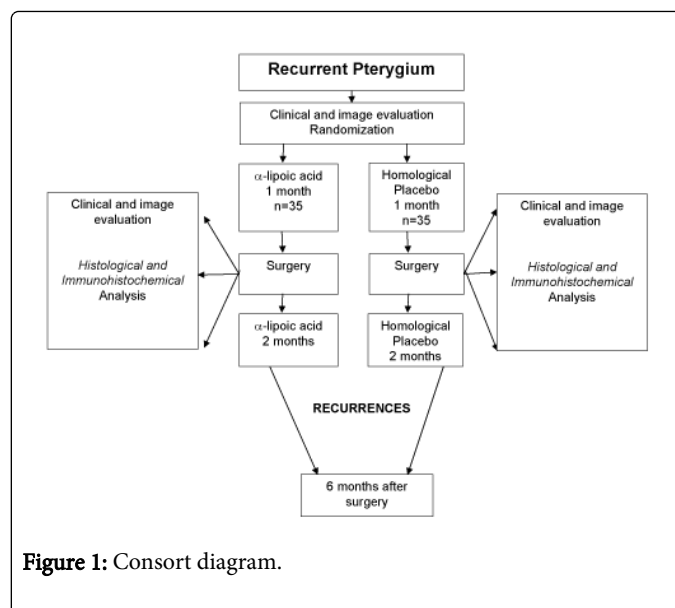
### Patients and treatment

A randomized placebo-controlled, double-blind trial was designed which included 70 patients of both sexes, aged around forty years old, with recurrent pterygium recruited from the Civil Hospital of Guadalajara "Fray Antonio Alcalde" or from the Reconstructive Plastic Surgery Institute, Jalisco, México. The study began in August 2011 after ethical local committee approval (registration code: 01.04.2011); all participants gave written informed consent prior to any medical procedure for screening.

Patients with primary pterygium, co-morbidities (diabetes mellitus, hepatopathy, heart disease, and collagen disease), alcohol consumption, anti-inflammatory/antioxidant or pharmacological drug ingestion, history of allergy to  $\alpha$ -lipoic acid, other ocular diseases, infections or concomitant ocular medication were not included in the study. Patients failing to observe the study guidelines, non-attendance of two consecutive appointments, or ingestion of alcohol, drugs or vitamins with antioxidant properties during the study were excluded.

The allocation was concealed and done by simple randomization with closed envelopes that contained either the letter A or B. Investigators were unaware of the code of the pharmacological assignment during the study.

Either  $\alpha$ -lipoic acid (Thioctacid, Bayer® of Mexico) or homologated placebos were administrated orally (600 mg/day) 1 month before surgery and were continued for 2 months after surgery (total time received: 3 months) (Figure 1).



**Figure 1:** Consort diagram.

### Clinical and histological analysis

The pterygium area was localized and measured monthly in all patients. The biological tissue of the pterygium was removed and either placed in an Eppendorf tube for molecular analysis or immersed in paraformaldehyde (4%, pH 7.4) before being embedded in paraffin and sectioned (5- $\mu$ m thick) and stained with Masson's trichrome and hematoxylin-eosin (H&E). Histological evaluation was performed in 15 random fields to measure connective tissue in both groups. Blood vessels, extracellular matrix deposits, and inflammatory infiltrated and epithelioid cell presence were also determined. Myofibroblasts were detected by immunohistochemical analysis using mouse IgG for  $\alpha$ -SMA (Abcam, Cambridge, MA, USA). The angiogenic process was determined by the presence of VEGF using an antibody (anti-VEGF, Abcam, Cambridge, MA, USA). Positive cells or vessels with a visibly stained lumen for  $\alpha$ -SMA and VEGF were analyzed.

### Surgery

All patients were treated similarly with resection and simple closure. The surgeon and the physician who evaluated the clinical appearances and conducted histological analysis were blinded to the study protocol.

### Statistical analysis

Parametric and non-parametric statistical tests using student *t* tests and  $\chi^2$  tests were performed to evaluate differences between groups. A *p*-value of <0.05 was considered statistically significant.

### Results

Seventy patients were included in the study, of which 71% were men and 29% women, and were distributed into two groups. Patient characteristics are shown in Table 1. The initial dimension of pterygium was similar in both groups;  $3.82 \pm 0.05$  in the  $\alpha$ -lipoic acid group and  $3.42 \pm 0.7$  for placebo group. The pterygium had a slight reduction in  $\alpha$ -lipoic acid group before the surgery ( $3.4 \pm 0.6$ ) compared with the initial, differing with placebo which had a slight

increase ( $3.82 \pm 0.7$ ). These changes were statistically significant ( $p < 0.05$ ). The patients that had a recurrence during the 6 months after surgery were 25 (13 for the  $\alpha$ -lipoic acid group and 12 for the placebo group). Although the number of patients with recurrence of pterygium was similar in both groups (Table 2), six months after surgery a significant increment (2.46 mm) of fibroblastic tissue was observed in patients that received the placebo compared with patients that received  $\alpha$ -lipoic acid, which also had a recurrence but only of 1 mm (Figure 2).

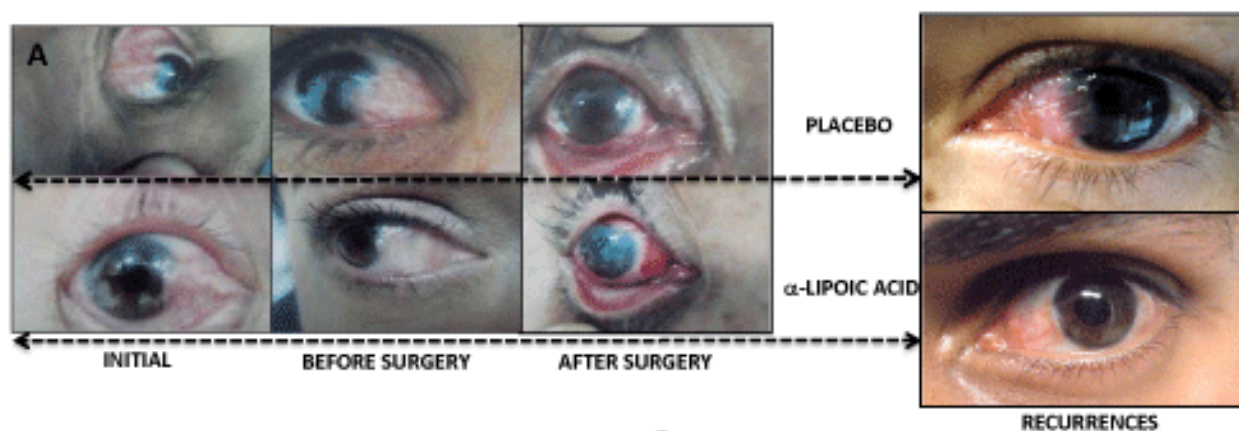
Characteristic	$\alpha$ -lipoic acid	Placebo	p
Sexes F / M	26 / 9	24 / 11	0.59
Age	$43 \pm 7.6$	$48 \pm 11.4$	0.02
Sun glasses	5	10	0.14
One Eye Affected	29	29	1
Both eyes	6	6	
Left eye	15	19	
Right eye	14	10	0.28
Residence			
Urban	24	19	0.34
Suburban	24	19	0.34

Localization			
Nasal	33	31	0.39
Temporal	2	4	0.39

**Table 1:** Patient Characteristics.

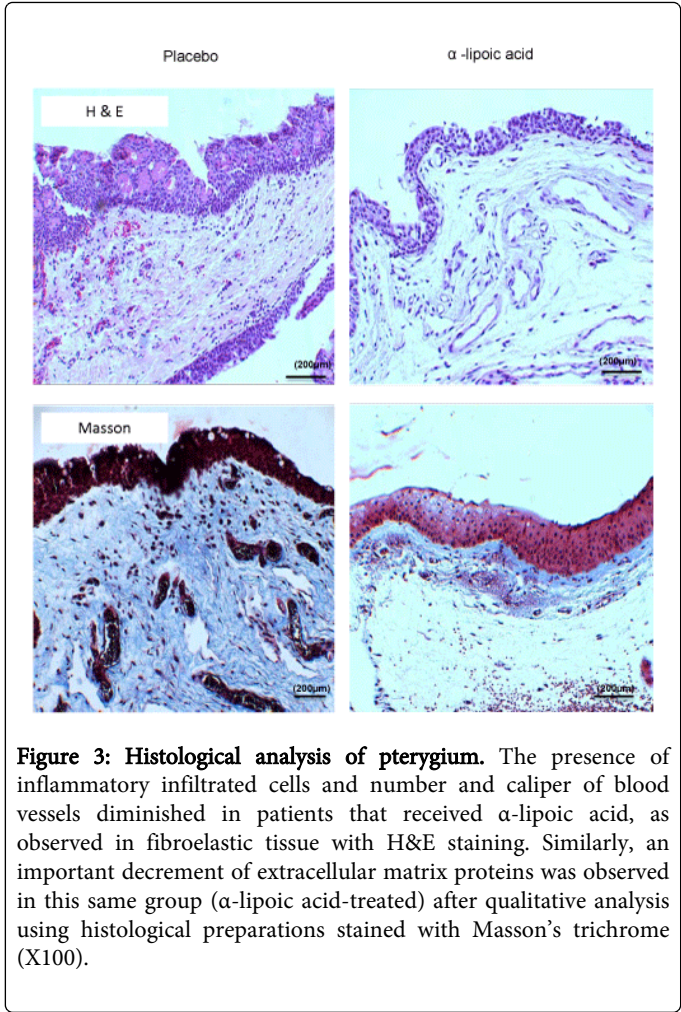
Months	$\alpha$ -lipoic acid n=35	Placebo n=35	p
1	3	5	0.45
2	4	3	0.75
3	3	1	0.29
4	1	2	0.57
5	1	1	1
6	1	0	0.3
Total	13	12	0.80

**Table 2:** Number of Recurrences and time post-surgery.



**Figure 2:** Size of pterygium recurring tissue after surgery. (A) The photograph shows the presence of pterygium; initial, before and after surgery in patients treated with  $\alpha$ -lipoic acid or placebo. (B) Six months after surgery the results showed an important reduction of tissue content in recurrences, which was statistically significant ( $p < 0.05$ ) in patients that received  $\alpha$ -lipoic acid.





**Figure 3: Histological analysis of pterygium.** The presence of inflammatory infiltrated cells and number and caliber of blood vessels diminished in patients that received  $\alpha$ -lipoic acid, as observed in fibroelastic tissue with H&E staining. Similarly, an important decrement of extracellular matrix proteins was observed in this same group ( $\alpha$ -lipoic acid-treated) after qualitative analysis using histological preparations stained with Masson's trichrome (X100).

$\alpha$ -SMA			
	Placebo n=35	$\alpha$ -lipoic acid n=35	p
Low	7	13	0.11
Moderate	15	17	0.63
Intense	13	5	0.02
VEGF			
Low	11	15	0.32
Moderate	19	17	0.63
Intense	5	3	0.45

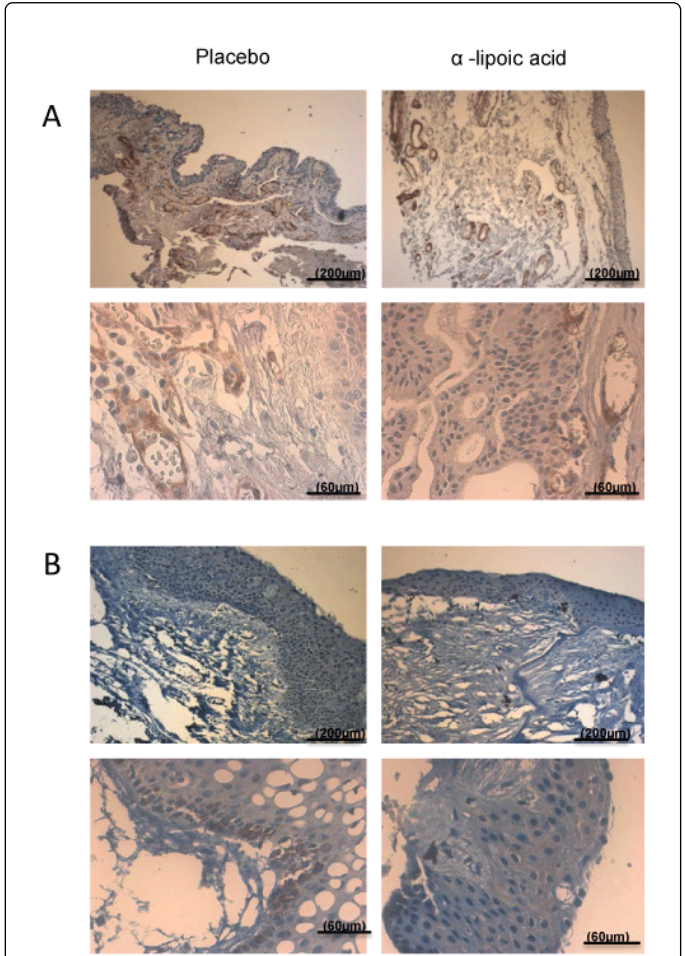
**Table 3:** Immunohistochemical analysis.

Histological analysis showed significant changes in both groups. The number and caliber of blood vessels, extracellular matrix content and inflammatory infiltrated cells decreased in patients treated with  $\alpha$ -lipoic acid (Figure 3). Stroma of fibrovascular tissue in patients that received the placebo showed the most striking results with H&E staining compared with the  $\alpha$ -lipoic acid group; in these patients, eosinophilic bundles of dense fibrous tissues showed a marked

reduction. Similarly, the excessive extracellular matrix stained with Masson's trichrome showed an important reduction in patients treated with  $\alpha$ -lipoic acid.

Immunohistochemical analysis of myofibroblast (presence of  $\alpha$ -SMA<sup>+</sup>) cells, and other fibroblastic and inflammatory stromal cells in pterygium tissue of patients treated with  $\alpha$ -lipoic acid revealed an important decrement of immunoreactivity compared with the placebo group, although VEGF<sup>+</sup> cells only showed a slight decrease post-treatment in the  $\alpha$ -lipoic acid group (Figure 4; Table 3).

Alpha lipoic acid and placebo were tolerated in a good way by all the patients, no adverse events were observed during the pharmacological intervention.



**Figure 4: Immunohistochemical analysis of  $\alpha$ -SMA, desmin and VEGF.** (A) Representative micrograph showing the abundant presence of cells  $\alpha$ -SMA<sup>+</sup> in patients treated with the placebo. The number of cells decreased in patients that received  $\alpha$ -lipoic acid. (B) No significant difference in VEGF<sup>+</sup> was observed in patients that received oral  $\alpha$ -lipoic acid 1 month prior to surgery (X100 and X400).

## Discussion

Pterygium, a wing-shaped (pterygos is “wing” in Greek) fibrovascular growth of conjunctiva extending into the superficial cornea, may cause irritation, redness, and tearing. Clinically, the condition involves invasive centripetal growth with associated inflammation and neovascularization. Several factors have been proposed to play a role in the pathogenesis of pterygium, such as anti-apoptosis, pro-inflammatory cytokines, growth factors, immunological responses, viral infections, extracellular matrix remodeling, and genetic factors [15].

Pterygium is common in the so-called “pterygium zone”, which is defined by a geographical latitude of 40° north and south of the equator. In countries within this area as our country, the prevalence is up to 22% in the general population. In countries outside this area, the prevalence rates usually do not exceed 2% [16,17].

The lesion mostly affects patients with an increased exposure to solar UV radiation, such as people working outdoors. A slightly higher incidence in males is reported, which may be attributed to lifestyle differences between genders (with males spending more time outdoors) in many countries [2]. Nevertheless, in the current study, the majority of patients were female. This may be because, in México, males rarely go to the doctor for this kind of problem.

Pterygium has been documented as a fibrovascular membrane advancing on the corneal surface, often triangular in shape, sometimes bilateral and usually originating from the nasal bulbar conjunctiva, but also occasionally from the temporal conjunctiva. A study by Efsthios et al. reported that the majority of patients showed fibrovascular tissue in the nasal region [2].

The pathogenesis of pterygium remains to be elucidated, and little is known about the differences between primary and recurrent pterygium. The few studies that have made a distinction between primary and recurrent pterygium determined that p53 is likely to play a role [15]; levels of VEGF, basic fibroblast growth factor, and substance P were significantly higher in recurrent pterygium [1,18], but the opposite relationship was seen by others [19]. Similar results have been obtained with other proteins, such as L-3-phosphoserine phosphatase homolog, increases in periostin, metalloproteinase inhibitor 2 (TIMP-2), mastering eye morphogenesis and eye evolution (PAX-6), human papillomavirus and herpes simplex virus [1].

Although the detailed molecular mechanism remains unclear, it has been widely accepted that chronic UV exposure is a major etiological factor, which is supported by epidemiological evidence and histological features. The noxious effects of UV radiation are either caused by direct UV radiation or by indirect stress via reactive oxygen species (ROS). Excess ROS can overwhelm the antioxidant system and cause oxidative damage to a variety of biological molecules, such as lipids, proteins and DNA [20].

UV-B exposure causes oxidative stress, leading to upregulation of many potential mediators of pterygium growth. 8-hydroxydeoxyguanosine (a marker commonly used to identify oxidative damage to DNA) and human 8-oxoguanine glycosylase 1 (the enzyme that metabolizes 8-hydroxydeoxyguanosine) have been found in pterygium tissue in several studies [8,20].

Several treatment options are available; including surgical excision techniques [21], but postoperative recurrence is common and sometimes results in even more aggressive clinical behavior. The surgical technique used in the current study was simple closure, which

has been associated with a high risk for postoperative recurrence compared with other surgical modalities [21,22]. In the current study, the decision fell to the surgeon managing the patient because the aim of the study was to evaluate the effects of a complementary treatment using  $\alpha$ -lipoic acid, not the surgical technique; although, published literature suggests that the surgical technique could probably be the single most important factor influencing recurrence, recurrent pterygium is more common in younger patients and is sometimes associated with a family history of pterygium. Its treatment often requires sophisticated surgery [21].

Several studies [22-24], have indicated that the oral administration of alpha lipoic acid can be useful and safe in treating human diseases, it exhibits high tissue capacity of penetration and it has been safe even being administrated for several weeks. Topical formulation of alpha-lipoic acid in eye drops (1%) has been used and has exhibited good penetration [11]. Although this way of administration is very interesting, only a single dose has been used, so other studies should be performed in order to test efficiency and safety using repeated doses for several weeks in order to be determined on humans.

Di Geronimo et al. [23] used alpha lipoic acid for three months at 600 mg by day and had good tolerance and safety; we decided to use this dosage and began this treatment previous to the surgery as Pajardi et al. [24], to inhibit the process of synthesis of fibroelastic tissue responsible of the recurrence, enhanced after surgery.

In this study, all patients were treated similarly in both groups and our results indicate that recurrence was similar but with a significant decrement in size of fibroelastic tissue recurring for the  $\alpha$ -lipoic acid group.

Another therapeutic strategy is anti-metabolite treatment, such as mitomycin C, which is often combined as an adjuvant with pterygium surgery (the recurrence rate is reported as <10%). Other agents include the alkylating agent thiopeta, and a pyrimidine analogue, 5-fluorouracil. Although very effective in reducing recurrence rates, anti-metabolite use is, nevertheless, associated with serious and potentially sight-threatening complications, such as delayed healing or even scleral melt [2].

Oxidative stress caused by UV exposure may be the principal cause of pterygium development, and several protocols have been established in animals exposed to UV-B radiation to evaluate the effects of antioxidants. For example, Suh et al. [25] demonstrated the protective effect of ascorbic acid in damaged cornea, and Demir et al. [13] with the use of  $\alpha$ -lipoic acid, determined the protective effect of conjunctival and corneal damage against oxidative stress in rabbits exposed to UV radiation.

Several studies, for example Golu et al. [26] indicated an abundance of subepithelial connective tissue in pterygium tissue, a rich basic substance with numerous fibroblasts, round mononuclear cells of lymphocyte and macrophage type, and a rich network of blood vessels and numerous goblet cells. Goblet cells are observed in classical stains, having the appearance of a cup or goblet, with a dilated apical pole and a foamy cytoplasm slightly stained from synthesis and accumulation of substances rich in glycosaminoglycans. The emergence of an increased number of goblet cells in the epithelium of pterygium may be the consequence of the exposure of the anterior segment of the eye to irritant pollutants. Similarly, our results are congruent with a report by Golu in the patients treated with placebo; however, the characteristics observed diminished after treatment with  $\alpha$ -lipoic acid, suggesting a prominent blockade of pterygium tissue recruitment.



The fibroelastic tissue demonstrated abundant extracellular matrix, with abundant fibroblastic cells present in bundle areas. The phenotype of cells within these bundles was positively stained for  $\alpha$ -SMA, indicating “foci” of myofibroblasts that decreased with  $\alpha$ -lipoic acid treatment. Touhami et al. [27] reported similar results in pterygium tissue (primary and recurrent) and demonstrated the presence of contractile myofibroblast bundles in pterygium and in periorbital fibroadipose tissue.

The process of angiogenesis is governed by a complex balance of positive and negative regulatory factors. One of the most potent and specific angiogenic factors is VEGF. This growth factor is considered to be the most selective mitogen for endothelial cells (angiogenesis). Livezeanu et al. [28] reported a strong reaction to VEGF in the pterygium for epithelial cells, except goblet cells, vascular endothelial cells, fibroblasts and stromal inflammatory cells with a granular pattern of expression and diffuse cytoplasmic disposition. Similarly, Aspiotis et al. [4] and Marcovich et al. [5] demonstrated an overexpression of VEGF in pterygium tissue and indicated that angiogenesis may play a role in the formation of pterygium. In the current study, we observed that  $\alpha$ -lipoic acid treatment did not significantly inhibit the presence of VEGF in pterygium. This observation aligns with a report by Rocamonde et al. [29] who reported that  $\alpha$ -lipoic acid increased the VEGF content in experimental brain injury animals.

The clinical appearance definitely changed with  $\alpha$ -lipoic acid, decreasing the excess of fibro-elastic tissue, adopting a less aggressive phenotype. However  $\alpha$ -lipoic acid as a treatment itself couldn't replace the surgery but it could be useful as a complementary therapy with a surgery in pterygium to avoid persistent inflammation, especially after a primary resection to avoid recurrences.

Our results indicated that the number of patients with recurrence during the 6 months following surgery was 25 (35.7%), and recurrence appeared principally within 3 months after resection. Patients that received  $\alpha$ -lipoic acid showed no differences in recurrence; perhaps further studies with a longer period of treatment using  $\alpha$ -lipoic acid prior the surgery will diminish these early recurrences.

## References

- Bradley JC, Yang W, Bradley RH, Reid TW, Schwab IR (2010) The science of pterygia. *Br J Ophthalmol* 94: 815-820.
- Detorakis ET, Spandidos DA (2009) Pathogenetic mechanisms and treatment options for ophthalmic pterygium: trends and perspectives (Review). *Int J Mol Med* 23: 439-447.
- Di Girolamo N, Chui J, Coroneo MT, Wakefield D (2004) Pathogenesis of pterygia: role of cytokines, growth factors, and matrix metalloproteinases. *Prog Retin Eye Res* 23: 195-228.
- Aspiotis M, Tsanou E, Gorezis S, Ioachim E, Skyras A, et al. (2007) Angiogenesis in pterygium: study of microvessel density, vascular endothelial growth factor, and thrombospondin-1. *Eye (Lond)* 21: 1095-1101.
- Marcovich AL, Morad Y, Sandbank J, Huszar M, Rosner M, et al. (2002) Angiogenesis in pterygium: morphometric and immunohistochemical study. *Curr Eye Res* 25: 17-22.
- Detorakis ET, Zaravinos A, Spandidos DA (2010) Growth factor expression in ophthalmic pterygia and normal conjunctiva. *Int J Mol Med* 25: 513-516.
- Dushku N, Molykutty HJ, Schultz GS, Reid T (2002) Pterygia Pathogenesis: corneal invasion by matrix metalloproteinase expressing altered limbal epithelial basal cells. *Arch Ophthalmol* 120: 234-237.
- Tsai YY, Cheng YW, Lee H, Tsai FJ, Tseng SH, et al. (2005) Oxidative DNA damage in pterygium. *Mol Vis* 11: 71-75.
- Papapetropoulos A, García-Cardena G, Madri JA, Sessa WC (1997) Nitric oxide production contributes to the angiogenic properties of VEGF in human endothelial cells. *J Clin Invest* 100: 3131-3139.
- Balci M, Sahin S, Mutlu FM, Yaqi R, Karanci P, et al. (2011) Investigation of oxidative stress in pterygium tissue. *Mol Vis* 17: 443-447.
- Cagini C, Leontiadis A, Ricci MA, Bartolini A, Dragoni A, et al. (2010) Study of alpha-lipoic acid penetration in the human aqueous after topical administration. *Clin Experiment Ophthalmol* 38: 572-576.
- Biewenga GP, Haenen GR, Bast A (1997) The pharmacology of the antioxidant lipoic acid. *Gen Pharmacol* 29: 315-331.
- Demir U, Demir T and İlhan N (2005) The protective effect of alpha-lipoic acid against oxidative damage in rabbit conjunctiva and cornea exposed to ultraviolet radiation. *Ophthalmologica* 219: 49-53.
- Chen BY, Lin DP, Chang LS, Huang TP, Liu HJ, et al. (2013) Dietary alpha-lipoic acid prevents UVB-induced corneal and conjunctival degeneration through multiple effects. *Invest Ophthalmol Vis Sci* 54: 6757-6766.
- Cimpean AM, Sava MP, Raica M (2013) DNA damage in human pterygium: one-shot multiple targets. *Mol Vis* 19: 348-356.
- Martins Ribeiro LA, Martins Ribeiro LFG, de Azevedo Castro PR, Lima da Silva FD, Wey VM, et al. (2011) Characteristics and prevalence of pterygium in small communities along the Solimões and Japurá rivers of the Brazilian Amazon Rainforest. *Rev bras oftalmol*.
- Liu L, Wu J, Geng J, Yuan Z, Huang D (2013) Geographical prevalence and risk factors for pterygium: a systematic review and meta-analysis. *BMJ Open* 3: e003787.
- Gebhardt M, Mentlein R, Schaudig U, Pufe T, Recker K, et al. (2005) Differential expression of vascular endothelial growth factor implies the limbal origin of pterygia. *Ophthalmology* 112: 1023-1030.
- Kau HC, Tsai CC, Lee CF, Kao SC, Hsu WM, et al. (2006) Increased oxidative DNA damage, 8-hydroxydeoxyguanosine, in human pterygium. *Eye (Lond)* 20: 826-831.
- Sánchez-Thorin JC, Rocha G, Yelin JB (1998) Meta-analysis on the recurrence rates after bare sclera resection with and without mitomycin C use and conjunctival autograft placement in surgery for primary pterygium. *Br J Ophthalmol* 82: 661-665.
- Al Fayed MF (2002) Limbal versus conjunctival autograft transplantation for advanced and recurrent pterygium. *Ophthalmology* 109: 1752-1755.
- Bertolotto F, Massone A (2012) Combination of alpha lipoic acid and superoxide dismutase leads to physiological and symptomatic improvements in diabetic neuropathy. *Drugs R D* 12: 29-34.
- Di Geronimo G, Caccese AF, Caruso L, Soldati A, Passaretti U (2009) Treatment of carpal tunnel syndrome with alpha-lipoic acid. *Eur Rev Med Pharmacol Sci* 13: 133-139.
- Pajardi G, Bortot P, Ponti V, et al. (2014) Clinical Usefulness of Oral Supplementation with Alpha-Lipoic Acid, Curcumin Phytosome, and B-Group Vitamins in Patients with Carpal Tunnel Syndrome Undergoing Surgical Treatment. *Evid Based Complement Alternat Med* 891310.
- Suh MH, Kwon JW, Wee WR, Han YK, Kim JH, et al. (2008) Protective effect of ascorbic Acid against corneal damage by ultraviolet B irradiation: a pilot study. *Cornea* 27: 916-922.
- Golu T, Mogoanta L, Streba CT, Pirici DN, Malaescu D, et al. (2011) Pterygium: histological and immunohistochemical aspects. *Rom J Morphol Embryol* 52: 153-158.
- Touhami A, Di Pascuale MA, Kawatika T, Del Valle M, Rosa RH Jr, et al. (2005) Characterisation of myofibroblasts in fibrovascular tissues of primary and recurrent pterygia. *Br J Ophthalmol* 89: 269-274.
- Livezeanu C, Craitoiu MM, Manescu R, Mocanu C, Craitoiu S (2011) Angiogenesis in the pathogenesis of pterygium. *Rom J Morphol Embryol* 52: 837-844.
- Rocamonde B, Paradells S, Barcia JM, Barcia C, García Verdugo JM, et al. (2012) Neuroprotection of lipoic acid treatment promotes angiogenesis

and reduces the glial scar formation after brain injury. Neuroscience 224: 102-115.