

Dynamic Soft Tissue Reconstructive Procedure for Correction of Severe Flexible Flat Foot

Mohamed Abd El Aziz Mohamed Ali*

Faculty of Human Medicine, Zagazig University, Zagazig, Sharkya, Egypt

*Corresponding author: Faculty of Human Medicine, Zagazig University, Zagazig, Sharkya, Egypt, Tel: 00201005624590; E-mail: ahmedghith646@gmail.com

Received date: August 03, 2016; Accepted date: August 26, 2016; Published date: August 31, 2016

Copyright: © 2016 Ali MAEAM. This is an open-access article distributed under the terms of the Creative Commons Attribution License, which permits unrestricted use, distribution and reproduction in any medium, provided the original author and source are credited.

Abstract

Background: We studied results of a soft tissue reconstructive procedure (Yahia procedure) for correction of symptomatic severe Flexible Flat Foot (FFF). The idea of the procedure was open reduction of the midtarsal joints with dynamic elevation of the talus by split transfer of the tibialis anterior tendon to reconstruct the medial longitudinal arch with rerouting of the other half of the tendon to act as a supportive planter ligament. The aim of this work is to assess Dynamic Soft Tissue Reconstructive (DSTR) procedure for correction of severe flexible flat foot.

Patients and Methods: We operated 17 patients (30 feet), (13 bilateral-4 unilateral), 12 males and 5 females, at a mean age of 6 (4-8) years corrected by Dynamic Soft Tissue Reconstructive (DSTR) technique with a mean of 30 months (12-48) of follow up period.

Result: At a mean of 2.5 years after surgery, 96.7% of the studied feet had satisfactory results.

Conclusion: We concluded that this soft tissue reconstructive procedure is useful for achieving accepted and maintained correction of severe Flexible Flat Foot (FFF).

Keywords: Flat foot; Flexible; Correction; Surgical

Introduction

The human foot is a highly complex structure. It has two major functions: the first is to support the body in standing and progression and the second is to lever it forwards in walking, running and jumping. Although their importance, the ligaments are unable to maintain the arch entirely on their own. The most important structure is the plantar aponeurosis. Deltoid, plantar and talocalcaneal interosseous ligaments, together with the capsule of the talo-navicular and navicula-cuneiform joints play important role in maintaining the medial longitudinal arch. The posterior tibial muscle, flexor digitorum longus, flexor hallucis longus and the intrinsic muscles of the foot also help in supporting the arch [1].

Flat foot is a very common orthopedic problem and can be divided according to arch mobility into mobile or rigid flat foot [2,3]. Flexible flat foot refers to collapse of the medial longitudinal arch on weight bearing, while it appears relatively normal in the non-weight-bearing position. The deformity has three components: heel valgus, forefoot abduction in addition to collapse of the medial longitudinal arch. Cases with mild degrees of deformity (only collapse of the medial longitudinal arch) are usually asymptomatic, although some patients may have shoe wear that can be relieved by the use of orthoses. The disorder is usually identified when parents notice the problem in wearing shoes, skin ulcerations, and serious walking problem, and the most important is moderate to severe pain and fatigue on long standing and walking. The goal of treatment of this disorder is to relieve the skin ulcer and pain, overcome difficulties in shoe and brace wearing and to restore the normal alignment of the foot.

The muscles that dynamically support the arches are divided into intrinsic and extrinsic muscles of the foot. The intrinsic muscles originate from and insert onto bones within the foot. The extrinsic muscles originate from the lower leg and insert onto the bones of the foot. The three extrinsic foot muscles (peroneus longus and brevis and the tibialis posterior) can be used to strengthen and deepen the longitudinal arch of the foot [4].

Correction of severe deformity is indicated even if still asymptomatic to avoid the occurrence of secondary osteoarthritis and fixed deformities. The surgical treatment comes for cases with severe FFF deformity that consists of collapse of medial longitudinal arch, heel valgus, forefoot abduction, prominent talar head and tight Achilles tendon [4]. Surgical Options vary from simple soft tissue procedures to calcaneal osteotomy subtalar extra articular arthrodesis and triple arthrodesis because of the problems associated with limited arthrodesis common opinion is to correct children's foot deformities without arthrodesis [3]. A new soft tissue procedure to reconstruct the medial longitudinal arch in severe FFF was conducted and reported satisfactory results in 90% of cases with correction of all components of the deformity [5]. The idea of soft tissue reconstruction technique was reduction of the midtarsal joints with dynamic elevation of the talus by split transfer of the tibialis anterior tendon and rerouting of the other half of the tendon to act as strong planter ligament pulling the created arch in increasing its curvature [1].

Patients and Methods

We made study of 17 patients (30 feet) who had undergone soft tissue reconstructive procedure for correction of severe FFF using Yahia procedures [6] between 2011 and 2015.

Indications of surgery

All patients had chronically symptomatic severe FFF with heel valgus, fore foot abduction in addition to collapse of the medial longitudinal arch. The complaints included foot strain especially in long standing and walking, difficulty of walking and running unsightly appearance of the foot which was an important complaint in girls and excessive shoe distortion and wear, all cases had a failure of at least 2 years of conservative treatment by orthotics (Figure 1). This procedure must not be done in rigid type of flat foot, presence of any underlying neurological disease as myelomeningocele, cerebral palsy or spina bifida, obese.

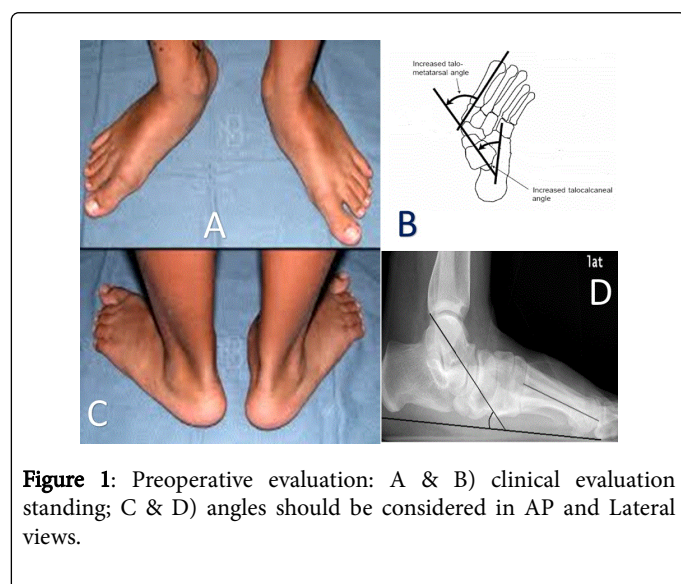


Figure 1: Preoperative evaluation: A & B) clinical evaluation standing; C & D) angles should be considered in AP and Lateral views.

Clinical assessment

Complaints: If there is any recurrence of the pre-operative complaints as foot strain, easy fatigability and shoe wear. Foot examination was done postoperatively, comparing the foot appearance as regard arch state, fore foot and hind foot alignment, talar head prominence and mobility of ankle, subtalar and midtarsal joints with the foot condition at the end of first follow up visit.

Radiological assessment: Each patient was assessed by preoperative and postoperative anteroposterior and lateral weight-bearing radiographs of the foot. From these films the same angles used for assessment Talohorizontal (TH), Talometatarsal (TMT), Calcaneal Pich (CP) and Talocalcaneal (TC) angles in lateral view and TMT and TC angles in anteroposterior view.

Operative procedure: All the cases were operated upon under general anesthesia, in the supine position, with application of a pneumatic tourniquet and complete aseptic technique (Figure 2c and 2d).

Skin incision beginning at the calcaneocuboid joint, passing under the tip of the lateral malleolus, the skin is incised, preserving if possible the veins on the lateral side and protecting the sural nerve. Capsulotomy of the calcaneocuboid joint: Releasing the capsule superiorly, laterally and inferiorly.

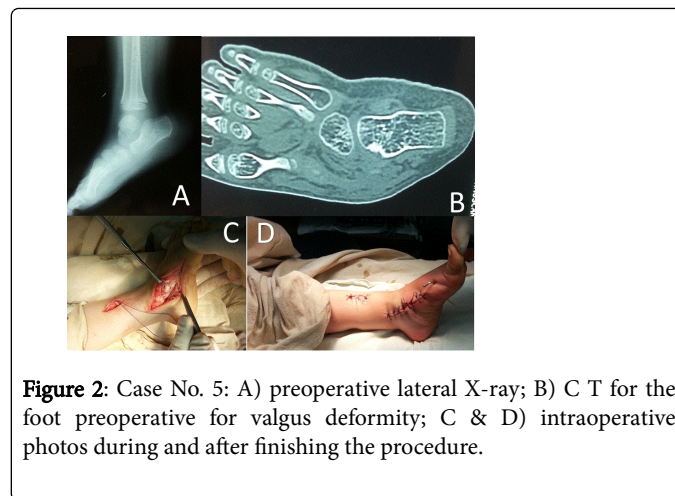


Figure 2: Case No. 5: A) preoperative lateral X-ray; B) C T for the foot preoperative for valgus deformity; C & D) intraoperative photos during and after finishing the procedure.

Z-Plasty elongation of the tight peroneal tendons. Z-plasty elongation of the tight Achilles tendon, leaving the distal slip attached medially to the os calcis to exert an inverting effect on the os calcis. Sullivan preferred method for pes planus in an otherwise normal person is to perform a triple cut through 2 to 3 cm incisions while tendon sheath is left intact or nearly so. The Achilles tendon spirals from the musculoskeletal junction to its insertion. Gastrocnemius tendon recession when there is only gastrocnemius equinus (limitation of dorsiflexion of the foot at the ankle with the knee extended but not with the knee flexed), a lengthening procedure of the gastrocnemius portion of the Achilles tendon may be performed. Posterior capsulotomy of the ankle and subtalar joints was done with division of the calcaneofibular ligament posteriorly in severe cases. Skin incision from the medial malleolus and down the medial side of the foot to the first metatarsal, division of the tibialis anterior tendon longitudinally leaving on half attached to same insertion and releasing the other half from the insertion. Complete release of the talonavicular joint capsule superiorly, medially and inferiorly was done followed by reduction of the subluxated talonavicular joint. The released longitudinal half of the tibialis anterior tendon is passed through a hole done in the talar neck and pulled to be sutured in it, so acting as a sling to the created arch. The distal part of the other half of the tibialis anterior tendon which is still attached to the original insertion is rerouted and pulled down to be sutured to the soft tissues on the medial aspect of the talus below the talar head. The tibialis anterior is transferred through the talus from dorsal lateral to plantar medial for direct talar control. The remaining tendon end was sutured to the plantar medial foot to form a strong ligament, which also helps to control plantar talar subluxation acting as a strong planter ligament pulling the created arch and increasing its curvature. In the severe medial column deformity, significant elongation of the plantar talonavicular joint capsule, spring ligament, and tibialis posterior tendon are noted. These must also be addressed. Plication of the tibialis posterior tendon and the spring ligament, tibialis anterior transfer into talus. The use of tibialis anterior tendon transfer through the talus for severe flexible pes planus has been derived and modified from its use for the congenital convex pen valgus. It has been utilized in selected symptomatic patients with severe talar declination and subluxation. Imbrication of the talonavicular capsule. A K-wire (2 mm) is pinned from the medial cuneiform through the navicular to the talus to stabilize the created arch and the reduced talonavicular joint and another k-wire pinned through the calcaneocuboid joint to decrease stress on the first wire.

Release of the tourniquet. Adequate closure of the subcutaneous tissue and skin after good hemostasis. A well-padded below knee non weight bearing plaster cast is applied with the ankle in neutral position.

Post-operative: After two weeks, post-operatively the cast was changed with the removal of stiches. One month later the cast was removed for the removal of the k-wires and another below knee, well molded non-weight bearing cast was maintained for another 4-6 weeks. After removal of plaster, a medical shoe was used on which the medial part of the sole is elevated to maintain the correction produced and prevent recurrence, for at least eight months after surgery during the follow up period assessment of the patient was repeated clinically and radiologically every 2 month for at least 8 months.

Methods of assessment of results

We used the modified point scoring system to assess patients. This scoring system incorporated 32 points for clinical parameters, 4 points for radiological parameters making a total of 36 points (Table 1). The resulting total score of every case reflected the quality of the result and was classified as:

Excellent: 30-36 points, Good: 25-29 points, Fair: 20-24 points, Poor: 19 points or less cases showing excellent and good results were classified as satisfactory and cases showing fair and poor results were classified as unsatisfactory.

Parameters	4 points	3 points	2 points	1 points
I. Clinical				
A. Subjectively				
1. Pain	No pain	Occasional pain	Pain with sternous activity.	Pain
2. Activity	Normal	mild reduction	Unable to do heavy work	difficulty of walking
B. Objectively				
1. Medial Arch	Normal	Decreased	abcent	convex
2. Heal Posture	Normal	Mild valgus or varus	Moderate valgus or varus	Severe valgus or varus
3. Forefoot	Normal	Mild abduction or adduction	Moderate abduction or adduction	Severe abduction or adduction
4. Prominence of Talar Head	None	Mild	Moderate	severe
5. Range of Motion	Good range of motion	Slight limitation	Stiff In neutral position limitation of the subtalar and midtarsal joints	Deformity in equinus or dorsiflexion stiffness of the whole tarsus
a- Ankle Joint	Good range of motion	Limited sutalar and mobil idtarsal joints		
b-Subtalar and Mlid Tarsal Joints				
II. Radiological	5 angles or more fell within normal range	Only 4 angles fell within normal range	3 angles fell within normal range	Less than 3 angles fell within normal range

Table 1: The point scoring system.

Results

Dynamic Soft Tissue Reconstructive (DSTR) procedure for correction of severe flexible flat foot operation was performed in 30 feet of 17 patients (11 boys, 6 girls, mean age at the end of follow – up 9 years, range 5 years to 13 years) with flexible FFF all of the bilateral deformities were operated at the same time except for one in which the second operation was performed 4 months later the first one. Mean age during the time of the surgery was 2.5 years (range 4 years-8 years), the mean postoperative follow up period was 2.5 years (range 1-4 years). Etiology was idiopathic in all cases. All of the patient were treated conservatively for a long time before surgery. Postoperative clinical and radiological evaluation scales were formed for all patients. Clinical evaluation was made over 8 parameter and 36 points using the modified points scoring system. The results of follow up were satisfactory in 29 feet (96.7%) and unsatisfactory in one foot (3.3%) of the studied feet.

Clinically: None of the studied feet developed deterioration as regards pain, 21 feet (70%) were asymptomatic and 9 feet (30%) had only occasional pain. Collapse of the medial arch follow up in 4 feet (13%). Heel posture in 7 feet (23%) mild varus, one feet moderate valgus (3.3). Talar head prominence 9 feet mild (30%), range of motion of ankle joint one feet slight limitation (3%). 2 feet limited dorsiflexion in neutral position (3%), 28 feet good range of motion of ankle (93%). Fore foot abduction 8 feet mild abduction (26.6%). Range of motion of subtalar joints 7 feet slight limitation (23%), 2 feet limitation of subtalar joints (6%) (Table 2).

Clinical evaluation of tibialis anterior tendon at follow up by dorsiflexion and inversion of the first ray against resistance did not show any mechanical insufficiency of the tendon in any of the feet studied.

Radiologically: Normal angles used in radiological assessment had in 3 feet (1%), 24 feet were radiological angles were 4 angel normal

values from 6 angles were normal and take score 3 (80%) and 3 feet were radiological angles were 3 felt in normal range (10%) their mean fell within the normal range except cp angle witch is slightly lower (Tables 2 and 3).

Discussion

On reviewing the literatures, most authors prefer to use a combined bony and soft tissue interference procedure to correct the components of FFF deformity, for the belief that relying only on soft tissue reconstruction is ineffective and may fail due to high possibility of recurrence [7,8]. There is an agreement that the use of joint fusion in correction of flexible flat foot deformity is not preferred because arthrodesis of joint or joints in the foot of a child leads to early degenerative changes of adjacent joints, because of the shift of stress to still mobile joints [9,10].

Our study demonstrates that a high incidence of satisfactory clinical results can be achieved after soft tissue reconstructive technique

(Yahiya procedure). This technique does not use bony osteotomy or joint fusion, thus can be used safely in children and adolescents. It is well known that flat foot deformity is easily corrected in younger children because the older the patient the less predictable is the results [11]. The mean period of follow up in this study is 2.5 years (1-4 years) with satisfactory results in 96.6% (29/30) of the studied feet.

The key of success of this procedure is the use of all needs for maintaining reduction by doing soft tissue tightening, dynamic transfer and k- wire fixation in addition to absence of any bony osteotomy or joint fusion. Miller procedure that had been reassessed after a mean of 12 years (3-27 years) after surgery had only 84% satisfactory clinical results and symptoms persisted in 16% (6/38) of the feet for no apparent clinical or radiological reasons, the persistence of symptoms after miller procedure can be explained by the shift of stresses to other foot joints due to arthrodesis of naviculo-cuneiform joint in all his cases and a second arthrodesis of metatarso-cuneiform joint in 18% (7/38) of feet [2].

Foot no.	Subjective		Objective						Total Clinical score	Radiological score	Total score
	Pain	Activity	Medial arch	Heel posture	Fore foot	Prominence	Range of motion				
							Ankle joints	Subtalar			
1	4	3	4	4	3	4	4	3	28	3	31
2	3	4	4	4	4	4	4	3	30	3	33
3	4	3	4	3	4	4	4	4	30	3	33
4	4	4	4	4	4	4	4	4	32	3	35
5	4	4	4	4	4	4	4	3	31	3	34
6	3	3	3	4	4	4	4	4	30	3	33
7	4	4	4	4	4	4	4	4	32	3	35
8	4	4	4	4	3	4	4	3	29	3	32
9	4	4	4	4	4	3	4	4	32	3	35
10	4	4	4	4	4	4	4	3	31	3	34
11	4	4	4	4	4	4	4	4	32	3	35
12	3	3	3	3	3	4	4	4	26	2	28
13	4	4	4	4	4	3	4	4	32	3	35
14	4	4	4	4	4	4	4	4	32	3	35
15	4	4	4	4	4	4	4	4	32	3	35
16	4	3	3	3	4	4	4	4	29	3	32
17	4	4	4	4	3	3	4	4	30	3	33
18	3	3	4	4	4	4	4	4	31	3	34
19	4	4	4	4	4	4	4	4	32	4	36
20	4	4	4	4	4	3	4	4	30	3	33

21	4	4	4	4	4	4	4	3	32	4	36
22	4	4	4	4	4	4	4	4	32	4	36
23	3	3	3	2	3	3	2	3	22	2	24
24	3	3	4	4	4	4	4	4	32	3	33
25	4	4	3	3	4	4	4	4	33	3	34
26	3	3	4	4	4	4	4	4	33	3	33
27	3	3	3	3	3	3	2	2	23	2	23
28	4	4	3	3	4	4	4	4	33	3	33
29	3	3	3	3	3	3	3	2	27	3	27
30	4	4	4	3	3	3	3	3	30	3	30

Table 2: The clinical point system for all feet.

Similar long-term results have been achieved with the Durham plasty, Caldwell and Coleman reported satisfactory results in 95% of feet followed for up to 6 and 26 years respectively [12,13].

The Hoke procedure alone is inadequate since after 2 to 9 years, satisfactory clinical and radiological results were reported in only 67% of feet [8], and by 16 to 19 years there was osteoarthritis of the talonavicular and subtalar joints in 69% of feet [14]. In this study, the reexamined feet did not complain of any recurrence of pain or restricted activity that were present pre-operatively, they were all highly satisfied with the functional outcome and foot appearance.

Angle	Normal range	Preoperative angles			Postoperative angles		
		Range	Mean	SD	Range	Mean	SD
Lateral view							
TMT	(-4)-(4)	25-50	37.5		(-5)-(10)	2.5	
TH	15-37	30-65	47.5		May-30	17.5	
CP	15-30	(-6)-(16)	10		Oct-25	17.5	
TC	25-55	35-65	50		Oct-40	25	
AP view							
TMT	(-15)-(10)	15-30	22.5		(-10)-(10)	0	
TC	15-35	20-50	35		Oct-50	30	

Table 3: The preoperative and postoperative angles of the foot after surgical correction compared to normal range.

TMT: Tarsometatarsal Angle, TH: Telo Horizontal Angle, CB: Calcaneal Pitch Angle, TC: Telocalcaneal Angle

Objectively, the shape of the foot was considered satisfactory if the reconstructed medial arch did not collapse, the achieved correction of heel valgus and forefoot abduction was maintained and talar head prominence did not recur. Absence of shoe wear and planter skin callosity till this follow up is a practical proof of the maintained significant foot correction. Two feet (6.7%) (One patient) showed

equinus deformity due to shortening of the tendoachillis without apparent cause and without affection of the corrected arch. We managed this by lengthening of the Achilles tendon. Plantigrade position with good range of ankle motion was achieved for two feet.

The mean of all radiological angles used for assessment of the studied feet fell within the normal range except for CP angle; its mean was lower than the lower limit of normal by 0.1. The late review of miller operation showed mild degenerative changes in the talonavicular and calcaneocuboid joints of one foot (2.6%).

Transferring the tibialis anterior, the tendon provides a strong plantar "ligament" to maintain osseous alignment from inferior to the talar neck distally. The addition of spring ligament and talonavicular joint capsular plication, as well as tibialis posterior tendon advancement, completes the securing of the subluxed medial column. The tibialis anterior in the chosen tendon to transfer for two reasons. Since it primarily a swing phase muscle, it can continue to act as an ankle joint dorsiflexor after its transfer to the talus. Releasing the tibialis anterior from its normal insertion also removes a potential deforming force, in a longstanding flatfoot, tibialis anterior assists in producing the forefoot supination deformity. When transferred, it allows the peroneus longus to aid in maintaining medial column stability during weight bearing [15-17]. Contracture of the Achilles tendon often accompanies the symptomatic flatfoot, it prevents normal dorsiflexion of the ankle during the midstance phase of the gait cycle. The dorsiflexion stress is shifted to the talonavicular joint, subjecting the underlying soft tissues to excessive direct axial loading and shear forces [18,19].

Conclusion

This soft tissue reconstructive procedure is useful for achieving accepted and maintained correction of severe FFF in children and adolescents without recurrence. The adopted technique revealed satisfactory results after a period of follow up. The idea held by many authors that a soft tissue reconstructive technique only is ineffective for correction of FFF deformity is incorrect provided the technique is done meticulously. Lack of bony interference (osteotomy or arthrodesis) in this technique is an advantage because this allows the technique to be used in children and avoids the occurrence of arthritis or bony deformity after long term follows up. The excellent results of

this study compared to Miller technique may owe to relatively short period of follow up and we recommend further follow up of long term to report if these results changed or not.

References

1. Eid Am (1979) Diseases of the ankle and foot. In: a concise text book on orthopedic diseases (1st ed) Qatar. Ali bin Ali printing press: 312-347.
2. Fraser RK, Menelaus MB, Williams Pf, Cole GW (1995) The miller procedure for mobile flat feet. *J Bone Joint Surg (br)* 77: 396-399.
3. Ahmet D, Mehmet AY (2006) The result of calcaneal lengthening osteotomy for the treatment of flexible pes planovalgus and evaluation of alignment of the foot. *Acta Orthop Traumatol Turc* 40: 356-366.
4. Dockery GI (1995) Symptomatic juvenile flat foot condition: surgical treatment. *J Foot Ankle Surg* 34: 135-145.
5. Giorgini R, Giorgini T, Calderaro M, Japour C, Cortes J, et al. (2010) The modified Kidner-Cobb procedure for symptomatic flexible pes planovalgus and posterior tibial tendon dysfunction stage II: review of 50 feet in 39 patients. *The Journal of Foot & Ankle Surgery* 49: 411-416.
6. Mohamed Y, Abd El Razzak, Maher Elk (2011) Late assessment of a soft tissue reconstructive procedure for correction of severe flexible flat foot. *The Egyptian orthopedic journal* 46: 405-424.
7. Veigas Gv (2003) Reconstruction of the pediatric flexible planovalgus foot by using an Evans calcaneal osteotomy and augmentative medial split tibialis anterior tendon transfer. *J Foot and Ankle Surg* 42: 199-207.
8. Duncan J, Lovell W (1983) Modified Hoke-Miller. Flat foot procedure. *Clin Orthop* 181: 24-27.
9. Vanderwilde R, Staheli Lt, Chew De, Malagon V (1988) Measurements on radiographs of the foot in normal infants and children. *J Bone Joint Surg* 70: 407-415.
10. Wright DG, Desai SM, Henderson WH (1964) Action of the subtalar and ankle joint complex during the stance phase of walking. *J Bone Joint Surg* 46: 361-382.
11. Sobel EC, Giorgini R, Velez Z (1995) Combined technique for surgical correction of pediatric severe flexible flat foot. *J Foot Ankle Surg* 34: 183-194.
12. Cald Well G (1953) Surgical correction of flat foot by Durham flat foot plasty. *Clin Orthop* 2: 221-226.
13. Collemannss (1983) Complex flat foot deformities in children. Philadelphia, lea and febigar.
14. Elkamhawy MMM (2006) Surgical management of symptomatic severe flexible flat foot. *Drch Orth Thesis. University of Alexandria*.
15. Chen MJL, Chen CPC (2010) Flexible flatfoot 100: 842-846.
16. Murphy Ga (2003) Pes planus, In: Canale St (edt.) *Campbelle operative orthopedics st. louis: Mosby: 4025-4027*.
17. El-Tayeby Hm (1999) The severe flexible flat foot: rerouting of the tibialis anterior tendon. *J Foot Ankle Surg* 38: 41-49.
18. Seymour N (1967) The late results of naviculo-cuneiform fusion. *J Bone Joint Surg (br)* 49: 558-559.
19. Kissel CG, Blacklidge DK (1995) Tibialis anterior transfer into talus for control of the severe planus pediatric foot: A preliminary. *J foot Ankle Surg* 34: 195-199.