

DRESS syndrome with atypical cholecystitis in a female child: Review of literature

F. Chahed¹, N. Ben Fadhel¹, H. Ben Romdhane¹, Z. Chadli¹, H. Besbes², N.A. Boughattas¹, N. Ben Fredj¹, K. Aouam¹

¹Department of Clinical Pharmacology. University Hospital of Fattouma Bourguiba Monastir, Tunisia.

²Department of Pediatrics. University Hospital of Fattouma Bourguiba Monastir, Tunisia.

ABSTRACT

Drug rash with eosinophilia and systemic symptoms (DRESS) is a severe drug-hypersensitivity reaction involving several organs but rarely gallbladder. We describe an original pediatric case of sulfasalazine-induced DRESS complicated by an acute acalculous cholecystitis. A 12-year-old child was presented with fever, generalized and pruritic skin eruption and abdominal pain 25 days after sulfasalazine intake for a Crohn's disease.

Physical examination revealed fever, cervical lymphadenopathy, facial edema, diffuse maculopapular eruption with splenomegaly and right side abdominal tenderness. Laboratory findings revealed eosinophilia, atypical lymphocytes, thrombocytopenia, hepatic cytolysis, hypertriglyceridemia and hyperferritinemia. Abdominal ultrasound showed an acute acalculous cholecystitis. A DRESS syndrome was suspected, sulfasalazine was withdrawn and regimen of corticosteroid therapy was started. The total recovery was obtained over four months.

We report the first case of DRESS complicating by acalculous cholecystitis occurring in a child. Although low, the risk of cholecystitis occurrence in the course of DRESS incites to consider abdominal ultrasonography in the initial workup.

Keywords: DRESS, sulfasalazine, Acalculous cholecystitis, pediatric

INTRODUCTION

Drug rash with eosinophilia and systemic symptoms (DRESS) syndrome is a rare and severe drug-induced hypersensitivity reaction (1). The overall mortality of DRESS can be as high as 10% and occurs in patients with severe multi-organ involvement (2). Adults are more prone to be affected than children and the exact incidence of the drug reaction has not yet been determined in the pediatric patients (3). The most commonly offending drugs are aromatic anticonvulsants, allopurinol, anti-inflammatory drugs and sulfonamides such as, sulfasalazine and sulfamethoxazole (4). In patients with DRESS, visceral organ involvement typically manifests as hepatic dysfunction, nephritis, but may include acute interstitial pneumonitis, myocarditis,

colitis etc... (5). Acalculous cholecystitis has been very rarely described as an organ involvement in DRESS (2).

Hereby, we add to the literature an original pediatric case of sulfasalazine-induced DRESS complicated by an acute acalculous cholecystitis.

CASE PRESENTATION

A 12-year-old child with no history of drug hypersensitivity, was diagnosed with Crohn's disease and treated with sulfasalazine. Twenty-five days later, she was presented with fever, abdominal pain, a generalized and pruritic skin eruption over the anterior trunk.

* **Corresponding to:** Dr Ferdaous CHAHED, University Hospital of Fattouma Bourguiba Monastir, Tunisia; E-mail: dr.ferdaws.chahed@gmail.com


Received date: December 24, 2020; **Accepted date:** August 26, 2021, 2021; **Published date:** September 06, 2021

Citation: Chahed F (2021) DRESS syndrome with atypical cholecystitis in a female child: Review of literature. J Pharma Reports. 5:p175

Copyright: © 2021 Chahed F. This is an open-access article distributed under the terms of the Creative Commons Attribution License, which permits unrestricted use, distribution, and reproduction in any medium, provided the original author and source are credited.

Physical examination revealed a body temperature of 38.6°C, cervical lymphadenopathy, facial edema, diffuse maculopapular and purpuric eruption, predominantly on her face, anterior chest and back (Figure 1). The abdominal examination, revealed palpable splenomegaly and right upper quadrant abdominal tenderness.

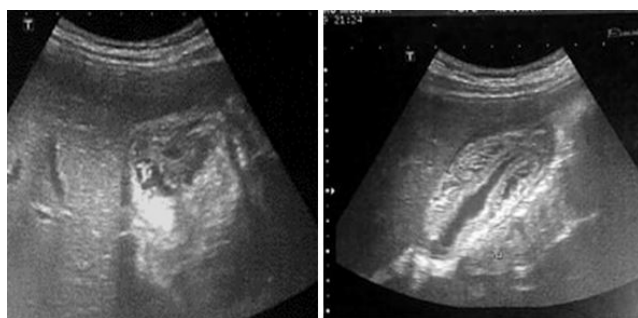
Figure 1: Maculopapular rash over face and neck.



Blood tests showed leukocytosis (leucocytes count 13620/mm³), eosinophilia 900/ mm³, lymphocytosis 8308/ mm³, atypical lymphocytes and thrombocytopenia (platelet count 120000/ mm³). Liver tests revealed cytolysis, (aspartate aminotransferase of 547 U/L, alanine aminotransferase of 591 U/L) and elevated gamma-glutamyl transferase of 352 U/L. Lipid profile showed hypertriglyceridemia (4.5 mmol/l). A ferritinemia of 500 ng/ml and a mild increase of C-reactive protein of 15 mg/L were also noted. Serology for mycoplasma, chlamydia trachomatis was negative. Similarly, viral serologies for hepatitis A, B, C, and D as well as cytomegalovirus, and Epstein-Barr virus showed negative results. Abdominal ultrasound revealed a thickened gallbladder wall with absence of gallstones, evoking an acute acalculous cholecystitis.

Figure 2 (A): Ultrasound cross section of the gallbladder, showing a diffuse (circumferential) thickening of the gallbladder wall.

(B): Longitudinal section of the gallbladder, demonstrating diffuse gallbladder wall thickening.



The Chest X-ray and echocardiogram showed no abnormalities. Skin biopsy demonstrated epidermal keratinocytes and dermal inflammatory perivascular infiltrate involving lymphocytes, histiocytes and eosinophils in line with the diagnosis of a DRESS. Serum lipase and C-reactive protein were both normal. Based on history, physical examination and laboratory results, DRESS was suspected. Sulfasalazine was withdrawn and betamethasone therapy was started. Two weeks later, she began

to improve gradually with the disappearance of the skin rash and resolution of facial and lymph node swelling. Laboratory findings and abdominal ultrasound were without abnormality four weeks later and the patient was discharged without any medication. A patch test with sulfasalazine performed six weeks later (20%) was negative.

Two months later, the child developed fever (40 °C), generalized maculopapular skin eruption accompanied with cervical lymphadenopathy as well as odynophagia. Blood tests revealed a normal white blood cell and eosinophils count of 7750 and /mL and 800/mm³, respectively. A flare-up reaction to sulfasalazine was suspected and the patient has received corticosteroid for six days. One week later, the symptoms began to improve gradually to disappear over three weeks.

DISCUSSION

We describe in this work an original clinical observation of sulfasalazine- induced DRESS complicated by acalculous cholecystitis occurring in a child. Indeed, cholecystitis is a very rare complication of DRESS and described only in adults so far. In our case, the clinical, biologic, and histological data are in accordance with the diagnostic criteria of DRESS published by Kardaun et al (6). Our case deserves a score of 8, qualifying the diagnosis of DRESS to be definite. The culprit drug was thought to be sulfasalazine in view of a suggestive temporal relationship between drug intake and the reaction onset, the remission of symptoms after drug withdrawal and the lack of other etiologies. According to Naranjo adverse drug reaction probability scale, our case is labeled “probable” (score of 6) (7). The symptoms relapse two month after the episode of DRESS despite the discontinuation of sulfasalazine intake and appropriate treatment may fit , with the flare-up phenomenon that could occur within days to several weeks after the initial manifestations of DRESS (8).

Moreover, we believe that patch-test to sulfasalazine performed in our patient was falsely negative as it has been shown that skin tests to sulfasalazine have a very weak sensitivity and revealed usually negative result (9,10).

Sulfasalazine is an anti-inflammatory drug commonly used in the treatment of chronic inflammatory bowel disease including ulcerative colitis and Crohn’s disease but also in many rheumatic conditions (10). Various adverse effects have been reported related to sulfasalazine and were generally dose-dependent and mild in severity (11). Whereas, sulfasalazine has an arylamine sulfonamide structure that is known to be related to severe fatal hypersensitivity reactions. Amos et al. have reported that only 5% (37/774) of children treated by sulfasalazine have developed hypersensitivity reaction (12). Unlike in adults, severe hypersensitivity reaction such as DRESS related to sulfasalazine has been rarely published (8,13,14). For instance, Kim et al. have described only five cases of DRESS induced by sulfasalazine in pediatric population (15). This may be explained by the fact that sulfasalazine is rarely prescribed in children. In DRESS the most commonly internal organ involved is the liver followed by the kidney and the lung (14). Although sulfasalazine is known to cause DRESS involving numerous

organs, it has never been associated with gallbladder damage. Interestingly, we described in our patient an acalculous cholecystitis as part of DRESS, confirmed by abdominal ultrasonography. The latter condition represents a life-threatening disorder with a high risk of perforation and necrosis of the gallbladder compared with typical calculous disease (2). It is estimated to represent at least 50 to 70% of all cases of acute cholecystitis during childhood (16). However, it has been rarely described as a drug side effect and even less so in the pediatric population. To date, DRESS with gallbladder involvement has been reported in four isolated adult cases. An et al. were the first to report the case of a 22-year-old male patient who had developed DRESS complicated by acalculous cholecystitis induced by antibiotic cefotaxime and/or oseltamivir treatment for hepatitis A (17). Subsequently, Haddad et al. have described a clinical observation of a 63-year-old male who had DRESS complicated with a gallbladder granulomatous vasculitis seven weeks after carbamazepine intake (5). The third case of acalculous cholecystitis as part of a DRESS was described by Waseem et al. in a 71-year-old woman, four weeks after starting a treatment with allopurinol (2). Finally, in 2019, Singh et al. has reported the case of a 36-year-old woman patient who had DRESS with an acute acalculous cholecystitis four weeks after starting levetiracetam for seizures related to astrocytoma (18). To our knowledge, no pediatric case of DRESS involving gallbladder was published in the literature so far.

Therefore, our case presents two originalities: the offending drug and the target population in DRESS with gallbladder involvement.

In summary we report the first case of DRESS complicating by acalculous cholecystitis occurring in a child. Although low, the risk of cholecystitis occurrence in the course of DRESS incites to consider abdominal ultrasonography in the initial workup. Early withdrawal of the culprit medication leads to quicker recovery. We also add sulfasalazine to the list of drugs that could elicit DRESS with acalculous cholecystitis.

REFERENCES

1. Fernando SL. Drug-reaction eosinophilia and systemic symptoms and drug-induced hypersensitivity syndrome. *Australas J Dermatol.* févr 2014;55:15-23.
2. Waseem H, Inayat F, Abduraimova M, Kamholz S. Allopurinol-Induced Drug Reaction with Eosinophilia and Systemic Symptoms Syndrome: A Cause of Acalculous Cholecystitis? *Cureus.* 16 août 2017;9:e1569.
3. Criado PR, Criado RFJ, Avancini J de M, Santi CG. Drug reaction with Eosinophilia and Systemic Symptoms (DRESS) / Drug-induced Hypersensitivity Syndrome (DIHS): a review of current concepts. *An Bras Dermatol.* juin 2012;87:435-49.
4. Bourgeois GP, Cafardi JA, Groysman V, Hughey LC. A review of DRESS-associated myocarditis. *J Am Acad Dermatol.* juin 2012;66:e229-236.
5. Haddad R, O'Brien B, Evans J, Orr C. Novel finding of carbamazepine induced gall bladder granulomatous vasculitis. *Intern Med J.* juill 2014;44:700-3.
6. Kardaun SH, Sidoroff A, Valeyrie-Allanore L, Halevy S, Davidovici BB, Mockenhaupt M, et al. Variability in the clinical pattern of cutaneous side-effects of drugs with systemic symptoms: does a DRESS syndrome really exist? *Br J Dermatol.* mars 2007;156:609-11.
7. Adverse Drug Reaction Probability Scale (Naranjo) in Drug Induced Liver Injury. In: *LiverTox: Clinical and Research Information on Drug-Induced Liver Injury* [Internet]. Bethesda (MD): National Institute of Diabetes and Digestive and Kidney Diseases; 2012 [cité 6 mai 2020]. Disponible sur
8. Lian BS, Busmanis I, Lee HY. Relapsing Course of Sulfasalazine-Induced Drug Reaction with Eosinophilia and Systemic Symptoms (DRESS) Complicated by Alopecia Universalis and Vitiligo. *Ann Acad Med Singap.* nov 2018;47:492-3.
9. Gerberick GF, Vassallo JD, Foertsch LM, Price BB, Chaney JG, Lepoittevin J-P. Quantification of Chemical Peptide Reactivity for Screening Contact Allergens: A Classification Tree Model Approach. *Toxicological Sciences.* 18 janv 2007;97:417-27.
10. Sulfasalazine-Induced Dress: A Report of Five Cases - Clinical Therapeutics [Internet]. [cité 5 juin 2020]. Disponible sur:
11. Fathallah N, Slim R, Rached S, Hachfi W, Letaief A, Ben Salem C. Sulfasalazine-induced DRESS and severe agranulocytosis successfully treated by granulocyte colony-stimulating factor. *Int J Clin Pharm.* août 2015;37:563-5.
12. Amos RS, Pullar T, Bax DE, Situnayake D, Capell HA, McConkey B. Sulphasalazine for rheumatoid arthritis: toxicity in 774 patients monitored for one to 11 years. *Br Med J (Clin Res Ed).* 16 août 1986;293:420-3.
13. Liang J, Qu H, Wang X, Wang A, Liu L, Tu P, et al. Drug Reaction with Eosinophilia and Systemic Symptoms Associated with Reactivation of Epstein-Barr Virus and/or Cytomegalovirus Leading to Hemophagocytic Syndrome in One of Two Patients. *Ann Dermatol.* févr 2018;30:71-4.
14. Augusto J-F, Sayegh J, Simon A, Croue A, Chennebault J-M, Cousin M, et al. A case of sulphasalazine-induced DRESS syndrome with delayed acute interstitial nephritis. *Nephrol Dial Transplant.* sept 2009;24:2940-2.
15. Kim GY, Anderson KR, Davis DMR, Hand JL, Tollefson MM. Drug reaction with eosinophilia and systemic symptoms (DRESS) in the pediatric population: A systematic review of the literature. *J Am Acad Dermatol.* 2 avr 2020;
16. Poddighe D, Sazonov V. Acute acalculous cholecystitis in children. *World J Gastroenterol.* 21 nov 2018;24(43):4870-9.
17. An J, Lee JH, Lee H, Yu E, Lee DB, Shim JH, et al. Drug rash with eosinophilia and systemic symptoms syndrome following cholestatic hepatitis A: a case report. *Korean J Hepatol.* mars 2012;18:84-8.
18. Singh T, Niazi M, Karri K, Rudikoff D, Gonzalez E. A Rare Case of DRESS (Drug Reaction with Eosinophilia and Systemic Symptoms) Syndrome with Cholecystitis in a Patient on Levetiracetam. *Cureus.* 13 mars 2019;11:e4245.