

Diffuse Juvenile Xanthogranuloma: A Case Report

B. Hasam¹, N. Elmakrini, N. Ismaili, L. Benzekri, K. Senouci and B. Hassam

Department of Dermatology, Venereology, CHU Ibn Sina, Mohamed V University, Rabat, Morocco

***Corresponding author:** B. Hasam, Department of Dermatology, Venereology, CHU Ibn Sina, Mohamed V University, Rabat, Morocco, Tel: + 00212661223823; E-mail: hasnaazaouri@yahoo.fr

Received date: June 12, 2017; **Accepted date:** September 06, 2017; **Published date:** September 09, 2017

Copyright: © 2017 Zaouri H, et al. This is an open-access article distributed under the terms of the Creative Commons Attribution License, which permits unrestricted use, distribution, and reproduction in any medium, provided the original author and source are credited.

Abstract

Juvenile xanthogranuloma (JXG) is a benign Non-langerhansian histiocytic proliferation. Herein, we report the case of a 17-month-old infant, who presented with two months history of a diffuse asymptomatic papular eruption, made of orange papules on the face, trunk and limbs. A skin biopsy performed, showed a Non-langerhansian histiocytosis type juvenile xanthogranuloma. Through this case report, we highlight the importance of knowing this rare entity that may be diagnosed easily in typical cases, but may be more difficult to diagnose in unusual variants.

Keywords: Juvenile xanthogranuloma; Non-langerhansian histiocytosis

Introduction

Juvenile xanthogranuloma (JXG) is a benign Non-langerhansian histiocytic proliferation of uncertain histogenesis which usually resolves spontaneously. Herein, we report a new case of diffuse juvenile xanthogranuloma.

Clinical Case

A 17-month-old infant was presented with two months history of a diffuse asymptomatic papular eruption. The dermatological examination found orange papules well limited, firm, infiltrated, rounded to oval, 0.5 to 2 cm diameter, located in the face, trunk, upper and lower limbs (Figures 1 and 2). The immuno-histological study showed a Non-langerhansian histiocytosis type juvenile xanthogranuloma CD68+, PS100+, CD1a- (Figure 3). Biological and morphological explorations did not reveal a systemic localization. No treatment was administered because of the spontaneously resolving nature of this dermatosis. The evolution was marked by the disappearance of skin lesions after 3 years of follow-up.

Comments

JXG is the most frequent Non-langerhansian histiocytosis (NLH). It usually occurs in infants and children in 80% of cases before the age of 2 years [1]. The lesions preferentially sit at the level of the upper part of the body but may also appear at the limbs. It is characterized by a single papule or a single yellow-orange nodule [2]. The JXG is rarely multiple which makes the originality of our observation. We should distinguish between the micro-nodular form which is the most frequent, and the macro nodular form that could have a particular risk of systemic involvement (lung, bones, kidneys, testicles, pericardium, eye, etc.).

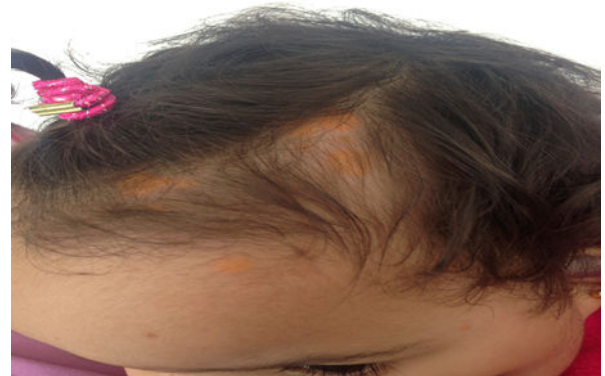

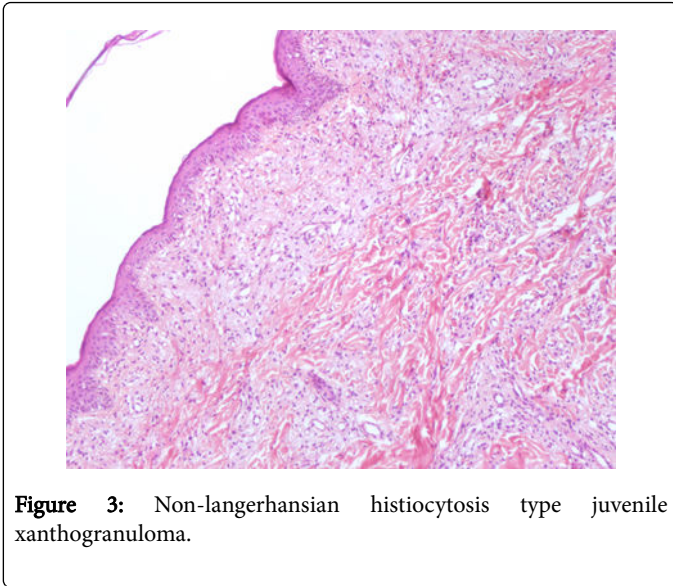
Figure 1: Orange papules in the face.

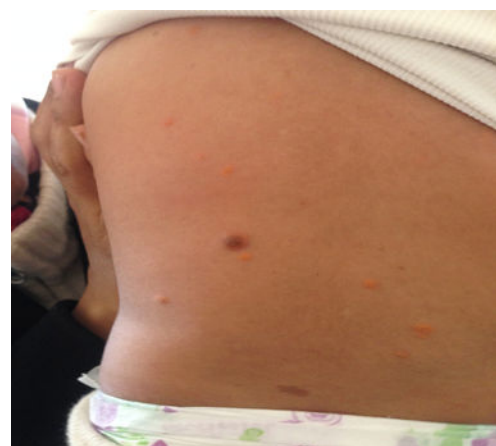

Figure 2: Orange papules well limited, firm, infiltrated, rounded to oval.

The diagnosis is histological, showing a dense dermal infiltration of epithelioid cells with vacuolated and foamy histiocytes S100-, CD1-, CD68+ and touton cells [3]. The JXG prognosis is generally benign with self-regression in a few months to a few years [4]. Therapeutic abstention may be proposed. For non-regressive forms, treatment is not well codified due to the scarcity of the different entities.

In summary, our observation illustrates a clinically atypical observation of JXG by the multi-lesional and multifocal nature of lesions. It illustrates also the difficulties of classifying benign forms of NLH, because of the existence of forms of passage between different entities.



Conflict of Interests

None.

References

1. Kupfer-Bessaguet F, Staroz P, Plantin (2008) Xanthogranulome juvénile. *Ann Dermatol Venerol* 136: 70-73.
2. Castilla EA, Ormsby A (2002) Adult xanthogranuloma of the vulva: case report and review. *Pathology* 34: 86-87.
3. Battistella M (2011) Les xanthogranulomes. *Ann Dermatol Venerol* 138:156-158.
4. Boudhir H, Bouhllab J, Mael-Ainin M, Senouci K, Hassam B (2013) Adult xanthogranuloma. *Annales de dermatologie et de vénéréologie* 140: 574-575.