

## Corneal Evaluation in Healthy Brazilian Children Using a Scheimpflug Topography System

Vieira Matheus IS<sup>\*</sup>, Germano Arnaldo MF, Zangalli Camila, Ferreira Bruna G, Castro Rosane S, Okanobo Andre, Alves Monica and Vasconcellos JPC

Department of Ophthalmology and Otorhinolaryngology, University of Campinas, UNICAMP, Brazil

<sup>\*</sup>Corresponding author: Vieira Matheus, Department of Ophthalmology and Otorhinolaryngology, School of Medical Sciences, University of Campinas (UNICAMP), Brazil, Tel: +55 (19) 3521-7396; E-mail: matheusivan@gmail.com

Received date: March 28, 2017; Accepted date: April 25, 2017; Published date: April 28, 2017

Copyright: ©2017 Matheus V, et al. This is an open-access article distributed under the terms of the Creative Commons Attribution License, which permits unrestricted use, distribution, and reproduction in any medium, provided the original author and source are credited.

### Abstract

**Purpose:** To identify the distribution and variation in corneal topography, thickness, and elevation in healthy Brazilian children as measured by the Pentacam Scheimpflug system (Oculus Optikgeräte GmbH, Wetzlar, Germany).

**Methods:** Healthy children between 7 and 11 years of age were scanned using the Pentacam Scheimpflug corneal topography system (Oculus Optikgeräte GmbH, Wetzlar, Germany). The exclusion criteria were inability to undergo the ocular exam, history of any ocular diseases (including strabismus, amblyopia, cataracts, retinal disorders, and allergic conjunctivitis), and topographic diagnosis of corneal ectasia based on the modified Rabinowitz/McDonnell criteria for keratoconus. The right eye of each subject was selected for analysis. The parameters evaluated were central corneal thickness (CCT), thinnest pachymetry (TP), average pachymetric progression index (PPlave), anterior and posterior elevation (AE and PE), anterior and posterior best fit sphere (ABFS and PBFS), pachymetric difference between the apex and the thinnest point (PDAT), Ambrosio's relational thickness (ARTMax), overall Belin/Ambrósio Enhanced Ectasia display score (BAD-D), simulated keratometry (SimK), astigmatism in SimK (SimK astig), maximum keratometry (K max), asphericity (Q value), and anterior chamber depth (ACD).

**Results:** A total of 160 children (69 male, 91 female) were included in this study. The mean age of the children was  $8.82 \pm 1.23$  years (ranging from 7 to 11 years). The mean CCT was  $553.81 \pm 32 \mu\text{m}$ , and mean TP was  $547.95 \pm 32.06 \mu\text{m}$ . The TP was most commonly located in the inferotemporal quadrant in 93.125% (149) eyes. The mean PPlave was  $1.00 \pm 0.14$ , similar to that of normal adults. The mean ABFS and PBFS values were  $7.49 \pm 3.26$  and  $10.54 \pm 6.25$ , respectively. ART Max and D averaged  $446.57 \pm 81.20$  and  $0.78 \pm 0.65$ , respectively. Mean  $\pm$  SD values for SimK, SimK astig, and K max were  $43.35 \pm 1.31$  D,  $0.92 \pm 0.66$  D, and  $44.40 \pm 1.45$  D respectively. The K max and SimK astig values were close to those reported by other topographic systems for children. Q value and ACD averaged  $-0.39 \pm 0.12$  and  $3.065 \pm 0.2745$  mm.

**Conclusion:** This study provides normative values for corneal topography, thickness, and elevation in healthy Brazilian children. These results may provide helpful information for diagnosis of corneal diseases in children. Further studies are needed to evaluate the role of tomography in identifying early forms of ectasia in this age group.

**Keywords:** Cornea; Children; Topography; Healthy; Pentacam; Scheimpflug

### Introduction

In clinical practice and research involving the use of keratometric readings of the anterior surface of the eye, the study of the posterior aspects of the cornea and its pachymetric distribution are very important for understanding how the cornea behaves structurally. These parameters are needed to identify abnormal corneas and to predict how they will behave in the future and after surgical procedures. Until techniques such as slit-scanning and Scheimpflug imaging were developed, the field of corneal imaging was restricted to the analysis of the shape and optical quality of the cornea's anterior surface with Placido disc-based topography systems [1]. These are still the most commonly used technologies for cornea imaging, though they lack the ability to diagnose subclinical keratoconus, contact lens corneal warpage, and corneas that are not suitable for refractive

surgeries. These new anterior segment imaging technologies are capable of reconstructing the three-dimensional structure of the cornea from two-dimensional optical cross-sections, greatly enhancing our ability to investigate the properties of the cornea. There are currently five devices on the market that are based on these technologies: Orbscan IIz (Bausch & Lomb Surgical, Inc), Pentacam (Oculus, Inc), the Galilei (Ziemer Ophthalmic Systems AG), the Preciso (Ligi Technologie Medicali), and the Sirius (CSO Ophthalmic). The Orbscan IIz is the only slit-scanning-based technology; the others involve Scheimpflug-based technology [2].

The Pentacam corneal tomographer (Oculus Optikgeräte GmbH, Wetzlar, Germany) is a Scheimpflug-based topographer that can provide readings and analyses of the anterior and posterior surfaces of the cornea, as well as measurements of corneal thickness. Since its launch in 2004, it has become a popular device for evaluating the anterior segment of the eye. Previous studies have demonstrated excellent reproducibility of the automated measurements of the

anterior segment structures [3-6]. The Pentacam system may be used to diagnose keratoconus, to screen corneas for refractive surgery, to monitor post-surgical corneas, to calculate the keratometric index and intraocular lens power, and to assess intraocular lens implants. Studies have provided normative data on the anterior segments of adults [7], as well as on changes in posterior corneal elevation following the use of an excimer laser [8]. In order to avoid undetectable keratoconus, new-generation devices now offer features and algorithms that help to differentiate keratoconus from normal corneas [9,10]. It is important to recognize the influences of aging on the shape of the anterior and posterior surfaces of the cornea [11], especially in patients who have cataracts and who have undergone corneal refractive surgery—in other words, patients who are in most need for accurate keratometric parameters in the selection of the correct intraocular lens [12].

Despite the vast amount of data on these corneal parameters in adults, similar information on children is still scarce [13], which can limit the use of the Pentacam for identifying abnormal corneas. Some studies have shown that the onset of keratoconus typically occurs during puberty [14]. However, when this condition develops sooner (as in cases of pediatric keratoconus), it seems to progress faster and to be more advanced at the time of diagnosis than keratoconus in adults [15]. Due to its advanced stage at diagnosis, pediatric keratoconus bears a higher risk of corneal scarring than adult cases, an issue which reflects a greater need for penetrating keratoplasty [16]. All of this information justifies the importance of obtaining keratometric, pachymetric, and elevation data from pediatric patients in order to diagnose corneal abnormalities earlier and, ideally, to avoid progression to such advanced stages and subsequent losses in quality of life.

The purpose of this study was to establish a database of normative corneal topography measurements from healthy children between 7 and 11 years of age using the Pentacam corneal topography system.

## Patients and Methods

The present study was reviewed and approved by the Research Ethics Committee of the University of Campinas (UNICAMP) in Campinas, São Paulo, Brazil under CAAE Registry number 54921916.9.0000.5404, and the tenets of the Declaration of Helsinki were followed. The study was based on a retrospective review of the ophthalmological medical records of healthy children enrolled in second to fifth grade of the State of São Paulo public school system in 2011. As it was a retrospective review of the ophthalmological medical records of patients that were examined in the past, the informed consent was dispensed with no harm to the patients. The Honorato Faustino State School was chosen randomly for these exams as part of a partnership with the state government, and children from 7 to 11 years of age who agreed to participate of the study and whose parents and guardians agreed to their participation were included. The exclusion criteria were inability to undergo the ocular exam, history of any ocular diseases (including strabismus, amblyopia, cataracts, retinal disorders, and allergic conjunctivitis), and topographic diagnosis of corneal ectasia based on the modified Rabinowitz/McDonnell criteria for keratoconus [17]. The ocular tomographic exam was performed using the OCULUS-Pentacam Scheimpflug Topography System.

During the examinations, the patients were comfortably positioned at the instrument with proper placement on the chin rest and forehead strap. The patients were asked to blink a few times and to open both eyes and stare at the fixation target. The system, which was in automatic release mode, started the scan after proper alignment was obtained. Twenty-five single Scheimpflug images within captured for each eye within 2 seconds. Two experienced ophthalmologists and corneal specialists in a dimly lit room performed all of the tomographic exams, and the tomography was repeated until acceptable image quality was obtained (image quality defined as “OK” according to the built-in Examination Quality Specifications). Details are shown in Figure 1. The analysis of the captured images considered the topographic, pachymetric, and elevation parameters, and maps, graphs, and indices have been created.

Central corneal thickness (CCT) was recorded at the apex of the cornea when the patient fixated on the target of the topographer. The thinnest point (TP) and its distance to the CCT in micrometers ( $\mu\text{m}$ ) were recorded. All of these calculations are exemplified in Figure 2.

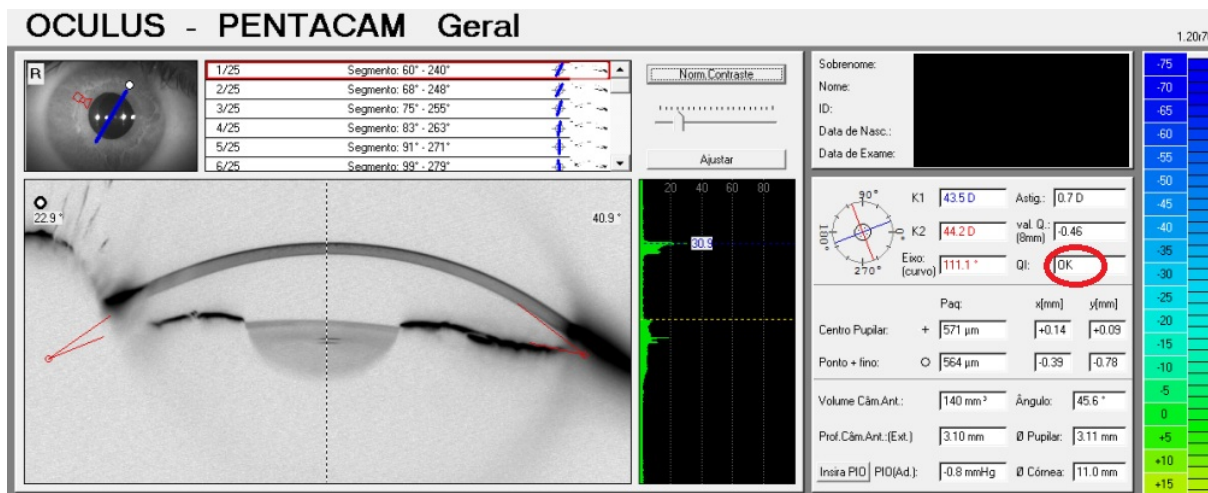
Anterior and posterior maps were used in the calculations of the anterior and posterior elevations at the thinnest point (AETP and PETP), as well as anterior and posterior elevation in the best fit sphere (ABFS and PBFS) using a fixed optical zone of 8.0 mm, as seen in Figure 3.

The mean value of the pachymetric progression index (PPIave) was recorded, as were the anterior elevation (AE) and posterior elevation (PE). The relational thickness parameter was calculated as the ratio of the PPI value to Ambrosio’s relational thickness (ART), which refers to the relational thickness of the TP with PPIMax (ARTMax). Using the Belin/Ambrosio Enhanced Ectasia display, a calculation was made based on the anterior and posterior elevations and on the distribution of thickness and the overall value, which was referred to as BAD-D. The BAD-D was recorded and used in the description of how the thickness of the cornea changed between the thinnest area and the periphery. Another parameter recorded was the asphericity of the cornea, which is measured by a Q value in which an oblate cornea has a positive value and a prolate cornea has a negative value. To avoid redundancy of the data, we included only the right eye. The data was manually transferred to Microsoft Excel (Microsoft, Redmond, Washington).

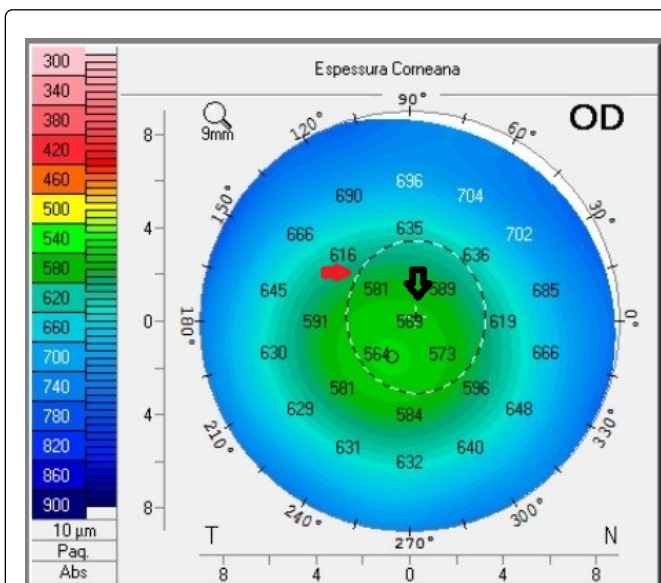
Statistical analyses were performed using the R Project software, version 3.0 (R Foundation for Statistical Computing Platform, Vienna, Austria). The mean, standard deviation, range, and confidence interval (95% CI) were calculated for each parameter in question. The probability of distribution was calculated using the skewness and kurtosis descriptors.

## Results

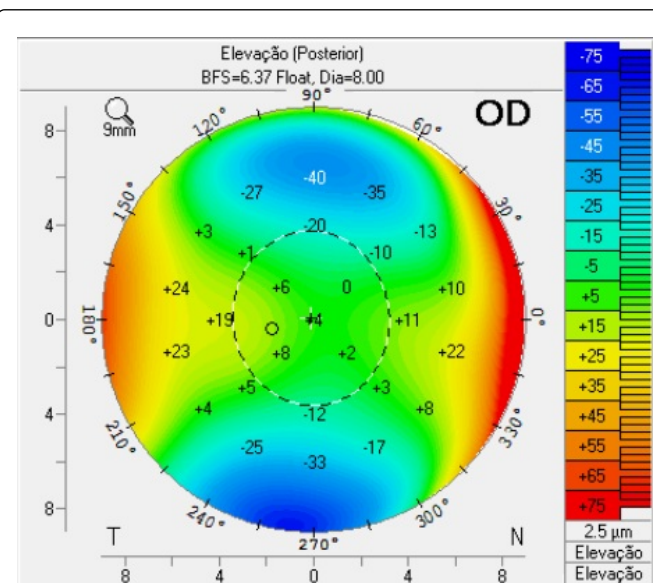
A total of 160 healthy children from 7 to 10 years of age were included in this study. Of these subjects, 69 were male and 91 were female (43.1% and 56.9%, respectively). The average patient age was  $8.82 \pm 1.23$  years. Table 1 summarizes the results.



**Figure 1:** Overview screen on the Pentacam showing the camera images, the optical density of the ocular tissues, the keratometric, pachymetric, and volumetric data of the anterior segment of the eye, and the reliability of the images as highlighted by the red circle.



**Figure 2:** Corneal thickness map showing the anatomical relations of the pupil edge (red arrow) and its center (black arrow); the thinnest point and the center of the map represent the corneal apex.



**Figure 3:** Posterior elevation map and the values based on the best fit sphere; note the anatomical relations between the pupil edge and its center, the thinnest point and the center of the map representing the corneal apex.

Simulated flat keratometry (flat SimK), simulated steep keratometry (steep SimK), and maximum keratometry (K max) in diopters (D) were  $42.95 \pm 1.32$  (range: 39.10 to 46.70),  $43.86 \pm 1.40$  (range: 40.20 to 48.00), and  $44.40 \pm 1.45$  (range: 40.50 to 48.50), respectively. SimK and SimK astigmatism (SimK astig) values were  $43.35 \pm 1.31$  (range: 39.65 to 47.00) and  $0.92 \pm 0.66$  (range: 4.80 to 0), respectively, and they were also measured in diopters (D).

In the analysis of corneal thickness, the mean CCT was found to be  $553.81 \pm 32$  μm (range: 481 to 640), and mean TP was  $547.95 \pm 32.06$  μm (range: 469 to 629). The TP was most commonly located in the inferotemporal quadrant in 93.125% (149) eyes. The distribution of thickness was represented in PPlave and ARTMax, which were  $1.00 \pm 0.14$  (range: 0.64 to 1.45) and  $446.57 \pm 81.20$  (range: 223 to 745), respectively.



	Mean ± SD	Range	Skew	Kurtosis
Age (y)	8.819 ± 1.233	7 to 11	-0.06	-1.13
CCT (µm)	553.81 ± 32	481 to 640	0.06	-0.67
TP (µm)	547.95 ± 32.06	469 to 629	0.05	-0.64
PPlave	1.00 ± 0.14	0.64 to 1.45	0.31	0.29
AE (µm)	3.20 ± 1.91	1 to 13	1.15	4.88
PE (µm)	5.09 ± 3.43	2 to 20	0.92	2.2
ABFS	7.49 ± 3.26	4 to 26	1.05	6.33
PBFS	10.54 ± 6.25	3 to 30	0.44	0.26
PDAT (µm)	5.86 ± 4.90	0 to 32	2.69	8.84
ART Max	446.57 ± 81.20	223 to 745	0.54	0.83
BAD-D	0.78 ± 0.65	1.14 to 2.42	0.13	0.15
SimK	43.35 ± 1.31	39.65 to 47.00	0.058	0.112
Flat SimK	42.95 ± 1.32	39.10 to 46.70	0.04	-0.23
Steep SimK	43.86 ± 1.40	40.20 to 48.00	0.21	-0.07
SimK Astig	0.92 ± 0.66	4.80 to 0	-1.7	10.95
K max	44.40 ± 1.45	40.50 to 48.50	0.15	-0.02
Q Value	-0.39 ± 0.12	-0.77 to -0.05	-0.2034	0.07598
ACD	3.065 ± 0.2745	2.28 to 3.97	-0.2948	0.8669

SD: Standard deviation; 95% CI: Confidence Interval; CCT: Central Corneal Thickness; TP: Thinnest Pachymetry; P Plave: Average Pachymetric Progression Index; AE: Anterior Elevation; PE: Posterior Elevation; K: Keratometry; ARTMax: Maximum Ambrósio Relational Thickness; SimK: Simulated Keratometry; ABFS: Anterior Best Fit Sphere; PBFS: Posterior Best Fit Sphere; PDAT: Pachymetric Difference Between the Apex and the Thinnest Point; Kmax: Maximum Keratometry; BAD-D: Overall Belin/Ambrósio Enhanced Ectasia Display Score; ACD: Anterior Chamber Depth. The Pentacam Scheimpflug Corneal Topography (Oculus Optikgerate GmbH, Wetzlar, Germany).

**Table 1:** Measurements from 160 children's eyes evaluated using the OCULUS-Pentacam Scheimpflug topography system.

Using the anterior and posterior maps, the data on AE, PE, ABFS, and PBFS in µm was  $3.20 \pm 1.91$  (range: -1 to +13),  $5.09 \pm 3.43$  (range: -2 to +20),  $7.49 \pm 3.26$  (range: -4 to +26), and  $10.54 \pm 6.25$  (range: -3 to +30), respectively.

The overall Belin/Ambrósio's Enhanced Ectasia display score (BAD-D) was calculated using elevation, thickness, and the distribution of the aforementioned thickness data, and the result was  $0.78 \pm 0.65$  (range: 1.14 to 2.42). The shape of the cornea was analyzed based on its asphericity, which was a Q value of  $-0.39 \pm 0.12$  (range: -0.77 to -0.05).

## Discussion

Before the advent of Scheimpflug technology, Placido disk-based computer assisted videokeratometry was the best way to clinically evaluate corneal topography. It detected the curvature and corneal power of the anterior surface of the cornea, and its application is well known, including among pediatric patients. Before Scheimpflug technology, most classification criteria for keratoconus were based on

anterior corneal curvature data derived from corneal topography [18,19]. With the introduction of corneal tomographers such as the Orbscan IIz (Bausch & Lomb Surgical, Inc), the Pentacam (Oculus, Inc), and the Galilei (Ziemer Ophthalmic Systems AG,), both the anterior and posterior corneal surfaces came to be measured along with the pachymetry at each point, and elevation maps are now produced. These advancements provide information that was previously lacking with the Placido disk-based keratometry, and this information helps in the diagnosis of diseases by identifying different patterns of anterior and posterior topographies. This new data also aids in disease monitoring by providing additional parameters and more detailed information. These Pentacam measurements are currently being used in the formulation of new algorithms for the diagnosis of keratoconus and in the creation of built-in software that is capable of categorizing corneas as normal or as having cases of subclinical keratoconus [20]. An example of this is the new software adaptation to the Pentacam Scheimpflug Tomography (Oculus, Wetzlar, Germany) called the Belin/Ambrósio Enhanced Ectasia Display (BAD). The BAD software combines anterior and posterior elevation data with pachymetric data to provide a three-dimensional tomographic representation of the cornea's shape. A previous study showed that the thickness profile provided by the Pentacam and the BAD software can detect early keratoconus with a sensitivity and specificity of 98% [9]. The details provided by the Pentacam are reliable because the equipment has a high level of reliability and repeatability for keratometric and pachymetric readings [21,22]. The measurement of corneal thickness is essential in the diagnosis and evaluation of multiple ocular and corneal diseases, for establishing surgical indication, and for monitoring certain pathologies. Corneal thickness is considered an important indicator of corneal health, and it can be evaluated through the use of several methods, including ultrasonic pachymetry, optical slit-lamp pachymetry, confocal microscopy, specular microscopy, and partial coherence interferometry. Several reports have found corneal thickness measurements performed by the Pentacam and its pachymetric map to be reliable and reproducible [5,23-26].

With reports that the onset of keratoconus typically occurs during puberty [14] and that vision-related quality of life is worse among these patients [27], the detection of abnormal corneas in children has gained significant importance. It may be difficult to distinguish subclinical keratoconus from regular myopic astigmatism during a routine eye exam. Proper and prompt diagnosis of keratoconus is crucial for a better understanding of disease progression, for early treatment, and to avoid decreases in young patients' BCVA and the subsequent impact on productivity and quality of life [28]. While advanced keratoconus is easily diagnosed by slit-lamp biomicroscopy and corneal curvature readings, diagnosing subclinical keratoconus remains a challenge. Another benefit of topography evaluation is greater sensitivity to the subtle changes in topographic parameters in children with subclinical expressions of keratoconus and suspicious topographic corneal patterns. In patients who have already been diagnosed with keratoconus, topography exams are important for analyzing progression and establishing surgical indication.

Previous studies have provided substantial information and many normative values for corneal power, astigmatism, corneal thickness and pachymetric progression indices in adults. However, these parameters have not been studied in children using current tomographers such as the OCULUS-Pentacam Scheimpflug topography system. Our study provides normative data resulting from the use of Pentacam Scheimpflug corneal topography in children from

7 to 11 years of age. This data may be useful for distinguishing between normal and abnormal corneas. It has the potential to aid in the early diagnosis of corneal abnormalities, in the evaluation and monitoring corneal ectasia, and in the understanding of changes in corneal curvatures in healthy patients, in cases of ocular diseases, and in children who have undergone eye surgeries. Along with other topographic and tomographic systems, the Pentacam is one of the best technologies for scanning corneas in children. It provides data on topography, corneal thickness, and elevations with a single, rapid scan. In this study, topographic and pachymetric parameters of healthy children's corneas were studied using the Pentacam Scheimpflug topography system, as well as pachymetric progression indices and Ambrosio's relational thickness. As stated previously, precise knowledge on corneal topography in children is important for corneal ectasia diagnoses, contact lens fitting, and ocular surgery assessments [29].

This study on healthy children between 7 and 11 years of age found a relative similarity between children's mean CCT, TP, PPlave and BAD-D values and those of normal adults. The results also reflected a relative difference between children's values and the values in subclinical and keratoconus patients found by Ambrósio et al. [9], that studied 113 normal and 44 eyes with keratoconus from Brazilian patients aged between 11.7 to 78 years (mean 38.7 ± 17.9 years), and Vazquez et al. [30], that studied 189 normal and 44 eyes with keratoconus and their fellow eyes from Argentine patients aged between 14 and 71 years (mean 32.3 ± 8.1 years), as seen in Table 2. It seems that children's corneas become thinner from the periphery to the center the same way and as fast as adult corneas do, a finding that suggests that this parameter could be used to identify pediatric corneas that differ from healthy parameters. More studies are needed to significantly distinguish between normal and abnormal corneas based on these parameters.

	Current Study	Vázquez et al. - 2014		KC	Cutoff	Ambrósio et al. - 2011		Cutoff
	Mean ± SD	Normal	SC KC			Normal	KC	
		Mean ± SD	Mean ± SD	Mean ± SD		Mean ± SD	Mean ± SD	
CCT (µm)	553.81 ± 32	532 ± 33	502 ± 37	491 ± 39		550.53 ± 0.35	483.34 ± 41.88	529
TP (µm)	547.95 ± 32.06	528 ± 32	489 ± 37	474 ± 43		545.20 ± 34.27	448.70 ± 52.96	504
PPlave	1.00 ± 0.14	0.97 ± 0.14	1.42 ± 0.48	1.79 ± 0.77	1.09	0.87 ± 0.21	2.42 ± 1.74	1.06
ART MAX	446.57 ± 81.20	445 ± 87	269 ± 101	223 ± 109	349	507.36 ± 128.56	180.78 ± 78.21	339
BAD-D	0.78 ± 0.65	1.03 ± 0.7	4.26 ± 3.03	6.08 ± 3.98	1.61			

SD: Standard Deviation; 95% CI: Confidence Interval; SC: Sub Clinical; CCT: Central Corneal Thickness; KC: Kerato Conus; TP: Thinnest Pachymetry; PPlave: Average Pachymetric Progression Index; ARTMax: Maximum Ambrósio Relational Thickness; BAD-D: Overall Belin/Ambrosio Enhanced Ectasia Display score; The Pentacam Scheimpflug corneal topography system (Oculus Optikgerate GmbH, Wetzlar, Germany).

**Table 2:** Measurements of 160 children's eyes and cutoff values in the current study and as reported in other studies.

K max (42.95 ± 1.32) and SimK astig (0.92 ± 0.66) values were found to be similar to those found through the use of other topographic systems with older technologies (computerized videokeratoscopy) and newer technologies (slit-scanning and

Scheimpflug) among healthy children and adults [29,31]. These values represent a low overall level of corneal astigmatism in the pediatric population of this study. These indices were also found to be similar to those of other studies (Table 3).

	Method	No. of eyes	SimK max (D)	SimK min (D)	SimK Astig (D)
Current Study	Pentacam	160	43.86	42.95	0.92
Ortiz-Toquero et al.	Galilei G4	56	44.22	43.22	0.97
Ortiz-Toquero et al.	Allegro-Topolyzer	56	44.07	43.12	0.95
Reddy et al.	Orbscan II z	100	44.26	43.56	0.69
Liu et al.	Orbscan	94	44.24	43.31	0.9
Bogan et al.	CMS	216	43.39		0.8
Rabinowitz et al.	TMS-1	390	43.7		

**Table 3:** Simulated keratometry (SimK) findings in different studies.

As Table 4 shows, we also compared the parameters between males and females and found the values to be similar. The mean Q value was -0.39 ± 0.12, a finding which suggests that children's corneas are more prolate than those of African-American adults (-0.26 ± 0.19) and of

Caucasian adults (-0.20 ± 0.12) in studies that used the Pentacam [32]. Younger corneas seem to be more prolate than those of older patients (7 years -0.3919 ± 0.02438; 11 years -0.3309 ± 0.03195; p=0.1428), but

further studies on more subjects are needed to prove this information with statistical significance.

	Males (n: 69)		Females (n: 91)		P-value
	Mean	SD	Mean	SD	
CCT	549.1	33.78	557.4	30.3	<0.0001
TP	543.7	34.21	551.2	30.12	<0.0001
PPlave	0.986	0.1369	1.002	0.1351	<0.0001
PE	4.406	3.663	5.604	3.169	<0.0001
ABFS	7.406	2.83	7.549	3.572	<0.0001
PBFS	8.739	6.416	11.9	5.795	<0.0001
PDAT (µm)	5.478	4.661	6.154	5.084	<0.0001
ART MAX	445.4	86.61	447.5	77.32	<0.0001
BAD-D	0.709	0.6337	0.8358	0.6637	<0.0001
SimK	43.13	1.557	43.61	1.303	<0.0001
Flat SimK	42.68	1.432	43.15	1.197	<0.0001
Steep Sim K	43.58	1.556	44.08	1.244	<0.0001
SimK Astig	-0.901	0.6993	-0.9282	0.624	<0.0001
K max	44.06	1.595	44.66	1.271	<0.0001
Q Value	-0.381	0.1673	-0.3756	0.1338	<0.0001
ACD	3.12	0.2664	3.023	0.2745	<0.0001

SD: Standard Deviation; CCT: Central Corneal Thickness; TP: Thinnest Pachymetry; PPlave: Average Pachymetric Progression Index; AE: Anterior Elevation; PE: Posterior Elevation; K: Keratometry; SimK: Simulated Keratometry; ABFS: Anterior Best Fit Sphere; PBFS: Posterior Best Fit Sphere; PDAT: Pachymetric Difference Between the Apex and the Thinnest Point; Kmax: Maximum Keratometry; BAD-D: Overall Belin/Ambrósio Enhanced Ectasia Display score; The Pentacam Scheimpflug corneal topography (Oculus Optikgeräte GmbH, Wetzlar, Germany)

**Table 4:** Comparison of Pentacam parameters between male and female pediatric patients.

This study is the first to report on the corneal parameters of healthy Brazilian children. Some limitations must be noted, however: though the parameters are similar to those found in the general population, the age range of our study was between 7 and 11 years, and it is not known how the corneas of younger and older children behaves and whether these same parameters can be applied to other pediatric age groups. Because the current study is descriptive in nature, its statistical significance cannot be compared to that of other populations (such as adults and patients with keratoconus corneas). Therefore, it is difficult to determine similarities and differences between these findings and others. It is also important to note that, while the tomographic exam requires only two seconds capturing all of the images, the patient to remain immobile and fixate on the target, which could be difficult to achieve among younger patients.

This is the first study in the literature to provide normalized values for keratometry, pachymetry, and relational data from Brazilian children's corneas using the Pentacam Scheimpflug topography system. It can provide a good foundation for the comparison of abnormal

pediatric corneal topography to normal cases. This data may prove useful in the field to help distinguish between normal and abnormal corneas, as well as in future comparative studies that consider different corneal diseases in children. Further studies are needed to evaluate the role of tomography in identifying early forms of ectasia in children.

## References

- Klyce SD (2000) Corneal topography and the new wave. *Cornea* 19: 723-729.
- Oliveira CM, Ribeiro C, Franco S (2011) Corneal imaging with slit-scanning and Scheimpflug imaging techniques. *Clin Exp Optom* 94: 33-42.
- Pinero DP, Saenz Gonzalez C, Alio JL (2009) Intraobserver and interobserver repeatability of curvature and aberrometric measurements of the posterior corneal surface in normal eyes using Scheimpflug photography. *J Cataract Refract Surg* 35: 113-120.
- Chen D, Lam AK (2007) Intrasection and intersession repeatability of the Pentacam system on posterior corneal assessment in the normal human eye. *J Cataract Refract Surg* 33: 448-454.
- Shankar H, Taranath D, Santhirathelagan CT, Pesudovs K (2008) Anterior segment biometry with the Pentacam: comprehensive assessment of repeatability of automated measurements. *J Cataract Refract Surg* 34: 103-113.
- Chen D, Lam AK (2009) Reliability and repeatability of the Pentacam on corneal curvatures. *Clin Exp Optom* 92: 110-118.
- Feng MT, Belin MW, Ambrosio R, Grewal SP, Yan W, et al. (2011) International values of corneal elevation in normal subjects by rotating Scheimpflug camera. *J Cataract Refract Surg* 37: 1817-21.
- Ciolino JB, Belin MW (2006) Changes in the posterior cornea after laser in situ keratomileusis and photorefractive keratectomy. *J Cataract Refract Surg* 32: 1426-1431.
- Ambrosio R, Alonso RS, Luz A, Coca Velarde LG (2006) Corneal-thickness spatial profile and corneal-volume distribution: tomographic indices to detect keratoconus. *J Cataract Refract Surg* 32: 1851-1859.
- Hashemi H, Mehravaran S (2010) Day to Day Clinically Relevant Corneal Elevation, Thickness, and Curvature Parameters Using the Orbscan II Scanning Slit Topographer and the Pentacam Scheimpflug Imaging Device. *Middle East Afr J Ophthalmol* 17: 44-55.
- Dubbelman M, Sicam VA, Van der Heijde GL (2006) The shape of the anterior and posterior surface of the aging human cornea. *Vision Res* 46: 993-1001.
- Borasio E, Stevens J, Smith GT (2006) Estimation of true corneal power after keratorefractive surgery in eyes requiring cataract surgery: BESSt formula. *J Cataract Refract Surg* 32: 2004-2014.
- Zheng Y, Huang G, Huang W, He M (2008) Distribution of central and peripheral corneal thickness in Chinese children and adults: the Guangzhou twin eye study. *Cornea* 27: 776-781.
- Sahin A, Yildirim N, Basmak H (2008) Two-year interval changes in Orbscan II topography in eyes with keratoconus. *J Cataract Refract Surg* 34: 1295-1299.
- Léoni-Mesplé S, Mortemousque B, Touboul D, Malet F, Praud D, et al. (2012) Scalability and severity of keratoconus in children. *Am J Ophthalmol* 154: 56-62.
- El-Khoury S, Abdelmassih Y, Hamade A, Slim E, Cherfan CG, et al. (2016) Pediatric Keratoconus in a Tertiary Referral Center: Incidence, Presentation, Risk Factors, and Treatment. *J Refract Surg* 32: 534-541.
- Cavas-Martinez F, De la Cruz Sanchez E, Nieto Martinez J, Fernandez Canavate FJ, Fernandez-Pacheco DG (2016) Corneal topography in keratoconus: state of the art. *Eye Vis* 3: 5.
- Quisling S, Sjöberg S, Zimmerman B, Goins K, Sutphin J (2006) Comparison of Pentacam and Orbscan IIz on posterior curvature topography measurements in keratoconus eyes. *Ophthalmology* 113: 1629-1632.

19. de Sanctis U, Loiacono C, Richiardi L, Turco D, Mutani B, et al. (2008) Sensitivity and specificity of posterior corneal elevation measured by Pentacam in discriminating keratoconus/subclinical keratoconus. *Ophthalmology* 115: 1534-1539.
20. Arbelaez MC, Sekito MB (2013) Screening for subclinical keratoconus. *Oman J Ophthalmol* 6: 1-2.
21. Hamer CA, Buckhurst H, Purslow C, Shum GL, Habib NE, et al. (2016) Comparison of reliability and repeatability of corneal curvature assessment with six keratometers. *Clin Exp Optom* 99: 583-589.
22. Modis L, Szalai E, Nemeth G, Berta A (2011) Reliability of the corneal thickness measurements with the Pentacam HR imaging system and ultrasound pachymetry. *Cornea* 30: 561-566.
23. Mueller A, Thomas BC, Auffarth GU, Holzer MP (2016) Comparison of a new image-guided system versus partial coherence interferometry, Scheimpflug imaging, and optical low-coherence reflectometry devices: Keratometry and repeatability. *J Cataract Refract Surg* 42: 672-678.
24. Chen S, Huang J, Wen D, Chen W, Huang D, et al. (2012) Measurement of central corneal thickness by high-resolution Scheimpflug imaging, Fourier-domain optical coherence tomography and ultrasound pachymetry. *Acta Ophthalmol* 90: 449-455.
25. de Sanctis U, Missolungi A, Mutani B, Richiardi L, Grignolo FM (2007) Reproducibility and repeatability of central corneal thickness measurement in keratoconus using the rotating Scheimpflug camera and ultrasound pachymetry. *Am J Ophthalmol* 144: 712-718.
26. Jahadi Hosseini HR, Katbab A, Khalili MR, Abtahi MB (2010) Comparison of corneal thickness measurements using Galilei, HR Pentacam, and ultrasound. *Cornea* 29: 1091-1095.
27. Aydin Kurna S, Altun A, Gencaga T, Akkaya S, Sengor T (2014) Vision related quality of life in patients with keratoconus. *J Ophthalmol* 2014: 694542.
28. Kymes SM, Walline JJ, Zadnik K, Gordon MO, Collaborative Longitudinal Evaluation of Keratoconus study group (2004) Quality of life in keratoconus. *Am J Ophthalmol* 138: 527-535.
29. Reddy SP, Bansal R, Vaddavalli PK (2013) Corneal topography and corneal thickness in children. *J Pediatr Ophthalmol Strabismus* 50: 304-310.
30. Ruisenor Vazquez PR, Galletti JD, Minguez N, Delrivo M, Fuentes Bonthoux F, et al. (2014) Pentacam Scheimpflug tomography findings in topographically normal patients and subclinical keratoconus cases. *Am J Ophthalmol* 158: 32-40 e2.
31. Ortiz-Toquero S, Zuniga V, Rodriguez G, de Juan V, Martin R (2016) Agreement of corneal measurements between dual rotating Scheimpflug-Placido system and Placido-based topography device in normal and keratoconus eyes. *J Cataract Refract Surg* 42: 1198-1206.
32. Fuller DG, Alperin D (2013) Variations in corneal asphericity (Q value) between African-Americans and whites. *Optom Vis Sci* 90: 667-673.