

## Contralateral Prophylactic Reinforcement in Case of First Low-Energy Hip Fracture: First-in-Man Clinical Data of a New Percutaneous Internal Fixation Device

Szpalski M<sup>1\*</sup>, Le Huec JC<sup>2</sup>, Jayankura M<sup>3</sup>, Reynders P<sup>4</sup> and Maas C<sup>5</sup>

<sup>1</sup>Hôpitaux Iris Sud, Department of Orthopedic and Trauma Surgery, Belgium

<sup>2</sup>Pellegrin Hospital, University Hospital of Bordeaux, France

<sup>3</sup>Erasmus Hospital, Belgium

<sup>4</sup>University Hospital of Brugmann, Belgium

<sup>5</sup>Clinical Research, Hyprevention, France

### Abstract

A prevention dedicated osteosynthesis device (Y-STRUT<sup>®</sup>, Hyprevention) was developed to reinforce the proximal femur on patients with high risk of fragility hip fracture. A multicentre pilot study was initiated to evaluate the feasibility, safety and tolerance of this device and the related operative procedure.

This clinical study is an on-going prospective series of 15 patients. Between February 2013 and December 2016, 10 patients were implanted. Patients were recruited when arriving to emergencies following a low-energy trauma leading to a pertrochanteric hip fracture. The device was implanted in combination with bone cement into the contralateral hip during the same anaesthesia as the fractured hip fixation. Clinical evaluation includes pain evaluation, functional status, and osteointegration of the device.

Mean age of patients was  $82 \pm 7$  years. Mean duration of implantation was  $56 \pm 19$  min for Y-STRUT<sup>®</sup> implantation and  $37 \pm 24$  for fracture fixation in the opposite side. Mean cement quantity injected was  $8 \pm 1.6$  ml. At 3 months, WOMAC scores for pain and functionality were 5 and 24, respectively and 4 and 18 at 12 months. Mean follow-up is  $16 \pm 12$  months. No patient died during the follow-up. No osteolysis nor post-operative fracture were observed.

Preliminary results of this prospective study showed the feasibility, safety and tolerance of the implantation of this new device. Further patients are required to confirm this experience and confirm efficacy of the device to reduce the risk of contralateral hip fracture during the first year after the first fracture when elderly patients are at the highest risk of fracture and mortality and the anti-osteoporosis medication prescribed at fracture is not yet efficient.

**Keywords:** Femur; Fracture; Osteoporosis; Orthopaedic; Pain

### Introduction

More than 2 million hip fractures are reported annually worldwide [1]. The occurrence is expected to increase with growing and aging of the population, aggravating this public health issue [2]. A hip fracture, even with a surgical treatment well managed with high success rate, remains a traumatic event for the elderly. This event often initiates a radical worsening of their quality of life, including functional and vital consequences, leading to dependency. Besides, the mortality rate after a first hip fracture is between 15 and 33% at 1 year [3,4].

In the elderly population, hip fracture is often the result of a low-energy fall linked to a daily life activity, and it is associated with a change in the bone structure naturally linked to age: Osteoporosis. Around 9% of patients treated for a hip fracture are victims of a second fracture of the opposite side during the year following the first fracture, and this rate increase to 20% at 5 years, leading to a dramatic increase of the mortality risk reaching 64% within 5 years [5].

To date, existing preventive solutions are weakly convincing; first, efficiency of hip protectors has not been proved and they are rarely used because of a low compliance [6]. Secondly, the efficiency of the medication treatments for osteoporosis is limited, especially because the patient's compliance is very low [7,8]. The adverse side effects of these treatments are often an obstacle to a long-term intake: Jaw necrosis, oesophageal and gastric complications, atypical fractures [9-13]. On the other hand some drug treatments are efficient to reduce the hip fracture rate only after 12 to 36 months of use [7]. Another study showed that the effectiveness of these treatments were limited (risk fracture reduction of

only 34%) [14]. The authors also turned out that the decrease was not significant for patients 80 and older, whereas the age is a major risk factor for hip fracture [5,15,16]. In comparison to these medicinal methods, surgical prevention has the advantage to be immediately effective, without regular intake and several surgical techniques, including femoroplasty, injection of silicone, and metallic spiral augmentation, have been the object of biomechanical investigations [17-20]. But despite their potential ability to reinforce strongly the proximal femur, they have not been tested through clinical trials owing to their major drawbacks (use of an important amount of cement inducing necrosis, leading to atypical fractures and making the revision complex if need be) [17,18]. One device - consisting in a titanium tubular screw with a coated hydroxyapatite thread, inserted in the axis of the femoral neck by minimally invasive surgery - was evaluated during a clinical trial, showing the feasibility and safety of a prophylactic surgery in case of a first fracture in the opposite hip [21]. However patient disability has not permitted to demonstrate the whole benefit of the device since

\*Corresponding author: Szpalski Marek, Hôpitaux Iris Sud, Department of Orthopedic and Trauma Surgery, Brussels, Belgium, Tel: 32475230516; E-mail: [mszp@skynet.be](mailto:mszp@skynet.be)

Received April 20, 2017; Accepted June 14, 2017; Published June 21, 2017

Citation: Szpalski M, Le Huec JC, Jayankura M, Reynders P, Maas C (2017) Contralateral Prophylactic Reinforcement in Case of First Low-Energy Hip Fracture: First-in-Man Clinical Data of a New Percutaneous Internal Fixation Device. J Osteopor Phys Act 5: 202. doi: [10.4172/2329-9509.1000202](https://doi.org/10.4172/2329-9509.1000202)

Copyright: © 2017 Szpalski M, et al. This is an open-access article distributed under the terms of the Creative Commons Attribution License, which permits unrestricted use, distribution, and reproduction in any medium, provided the original author and source are credited.

only 31% of included patients returned to their pre-injury walking ability. To address the issue of hip fragility fracture prevention, a new medical device, Y-STRUT<sup>®</sup> (Hyprevention, France), was developed to be implemented in the proximal femur by minimally invasive surgery [22,23]. Biomechanical tests on human osteoporotic femurs showed that the implantable medical device, placed in the proximal femur, increases the bone fracture load and energy to fracture in case of fall without modifying or worsening the nature of the fracture [24]. Its performance in biomechanical reinforcement has also been shown in case of multiple falls through cyclic testing.

Besides, this device has already been studied in patients with impending pathological fractures due to lytic tumorous lesions located on the proximal femur [25]. This article reports an analysis of preoperative and postoperative (short-term and mid-term) preliminary data from the first 10 patients implanted with Y-STRUT<sup>®</sup> device in osteoporotic patients with a first hip fracture and at high risk of contralateral fracture. It should be noted that another article has already been published to present the initial results of this study [26].

## Materials and Methods

A multicentre, single-arm, prospective and international study was initiated in order to assess Y-STRUT<sup>®</sup> medical device in an orthopaedics-traumatology indication-prevention of contralateral hip fracture [25,26]. A cohort of 15 patients with a 5 year follow-up is planned.

The study was performed according to the Declaration of Helsinki and with the approval of the Human Ethics Committees and the Competent Authorities of France (ANSM-“Agence Nationale de Sécurité du Médicament et des produits de santé”) and Belgium (AFMPS-“Agence Fédérale des Médicaments et des Produits de Santé”). All investigation variables were collected using electronic Case Report Forms (CS Online, Clinsight).

## Population

The patients included in the study were older than 60 years old with suspected or known osteoporosis (defined by a T-Score inferior or equal to -2.5), suffering from a pertrochanteric fracture further to a low-energy trauma, and having a risk of new fall (falls history, ocular diseases, use of walking aids, dizziness, important walking ability) [27-31]. In addition, the 10-year probability of hip fracture, given by the Fracture Risk Assessment Tool-FRAX was estimated for each patient [32]. Patients who agreed to participate by signing the informed consent underwent the surgical procedure within 24 to 72 h following their admission.

## Studied device and surgical technique

Y-STRUT<sup>®</sup> device (Hyprevention, France) is an implantable medical device composed of two implants assembled *in situ*. The implants are made of radio-transparent polymer PEEK and include visualizing markers made of tantalum. It is combined with PMMA bone cement, radio-opaque and with a low viscosity in order to allow smooth injection through the peripheral perforations of the implants, to ensure the bone anchoring of the device and increase the surface contact between the implants and the weak/osteoporotic bone (Figures 1a and 1b).

The surgical procedure is a percutaneous internal fixation of the proximal femur. All procedures were performed under general anaesthesia due to the simultaneous hip fracture fixation. Patients were in supine position on an orthopaedic traction table. The device was implanted contra laterally, after surgical treatment of the hip fracture and under the same anaesthesia (Figure 2). It was inserted through a

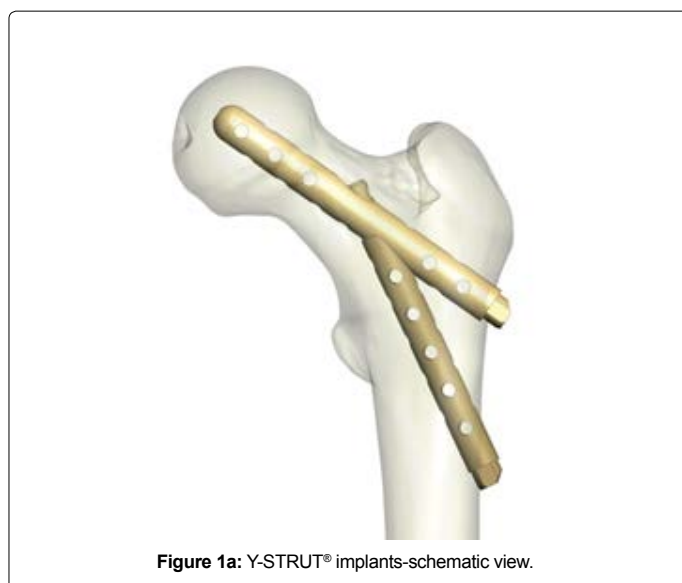


Figure 1a: Y-STRUT<sup>®</sup> implants-schematic view.

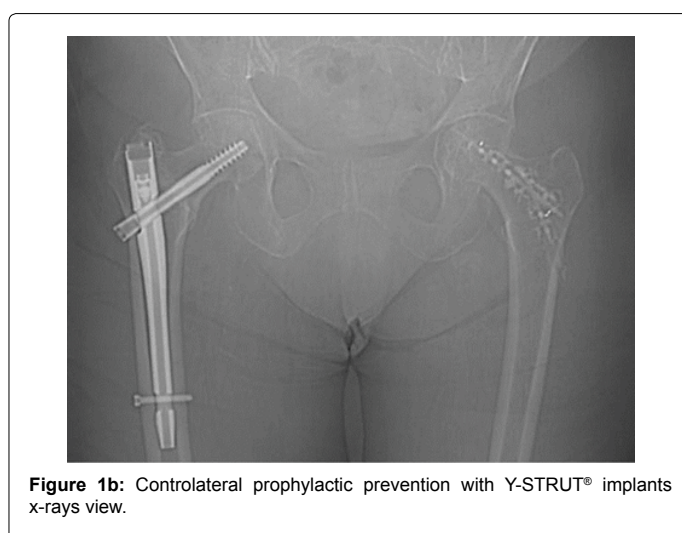


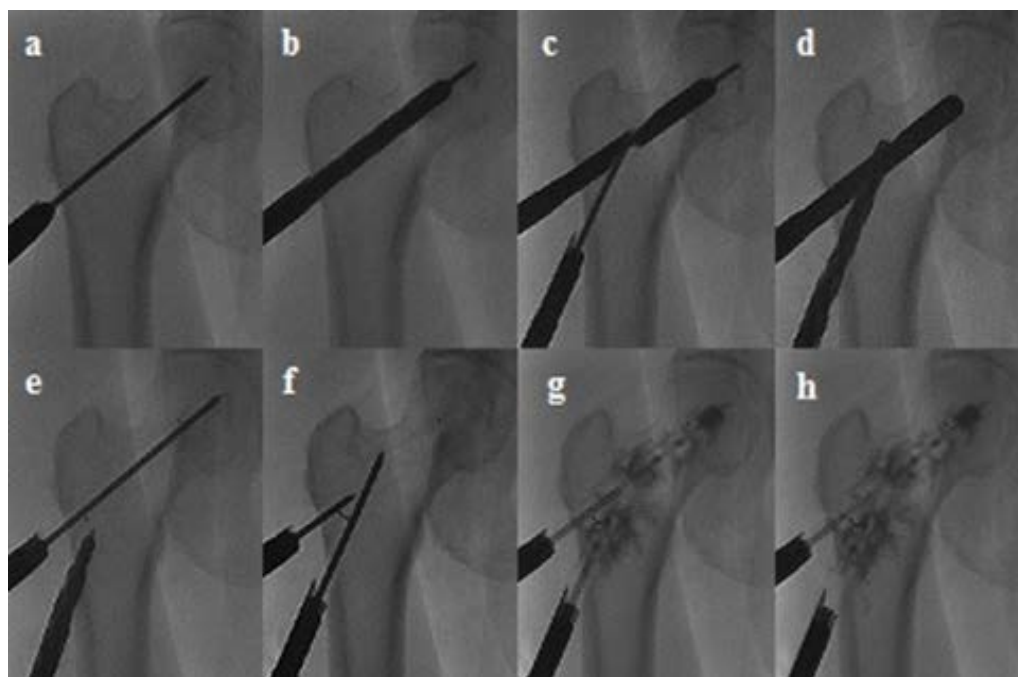
Figure 1b: Contralateral prophylactic prevention with Y-STRUT<sup>®</sup> implants x-rays view.

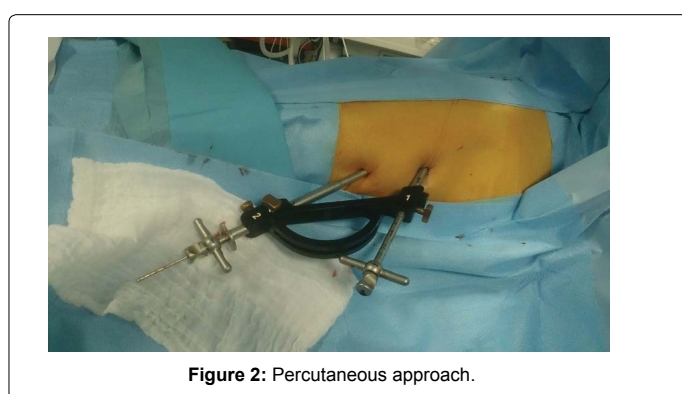

Figure 2: Percutaneous approach.

minimally invasive procedure with only 2 small incisions of 1 to 2 cm in the thigh, by means of a specific instrumentation kit (Hyprevention, France) and under imaging control (Figure 3).

First, a guide wire was inserted parallel to the axis of the femoral neck, in the upper third part of the proximal femur. After drilling of the



**Figure 3:** Radiographs showing the consecutive steps of the operative technique: (a) Positioning of the guide wire, (b) Drilling implant 1 location site, (c) positioning the template and the guide wire 2, (d) Drilling implant 2 location site, (e) Positioning of implant 1 (visualizing marker on the head side over the guide wire), (f) Positioning of implant 2 and control of implants positioning (the 2 distal markers form a V shape), (g, h) Cement injection on both sides.

Follow-up	3 weeks	3 months	6 months	12 months	24 months	36 months
Number of patients	10	10	9	4	2	1
Missing patient	0	1	3	1	0	0
Mean pain in the fractured hip (VAS)	1.8 ± 1.1	2.7 ± 3.6	1.3 ± 1.4	2.3 ± 1.2	3 ± 2	2
Mean pain in the Y-STRUT hip (VAS)	0.9 ± 1.2	2.2 ± 2.6	2.7 ± 2.9	3.4 ± 2.6	3 ± 2	0
Mean WOMAC pain	Not evaluated	5 ± 5	3 ± 6	4 ± 2	Not evaluated	Not evaluated
Mean WOMAC function	Not evaluated	24 ± 17	17 ± 14	18 ± 8	Not evaluated	Not evaluated

NB: Two patients were lost to follow-up at 10 and 18 months, respectively

**Table 1:** Data collected during follow-up.

first implant bed, a template was used during the second phase, where a second guide wire and drill were used for the second implant bed. A pilot instrument allowed directing the second drilling to assemble safely the 2 implants *in situ*, with an angle of 30° between both implants. At the end of the procedure, PMMA bone cement is injected through catheters directly inserted in the cannulated implants. Progressive cement injection into the implants is controlled by imagery to avoid cement leakages.

After the intervention, patients followed the rehabilitation protocol prescribed for their fracture, without additional rehabilitation with respect to the contralateral device.

Patients were followed by medical consultations and radiographic exams at short-term (3 weeks, 3 months and 6 months), mid-term (12 months), and long term (follow-up on-going to 5 years).

### Endpoints

The objectives of this investigation were to assess the procedure feasibility and safety as well as the short-term and mid-term device tolerance. We analysed the technical data of the procedure, its duration and per-operative adverse events. Tolerance of the device was evaluated by analysing the device stability and osteointegration on imagery, by

using pain assessment by visual analog scale (VAS). WOMAC scores for pain and functionality were also assessed. All related adverse events were collected.

### Results

We analysed the results for the 10 first patients (9 female, 1 male) included between February 2013 and December 2016. Mean follow-up duration was 16 months (range 5 to 47 months).

Mean age and BMI of patients were 82 ± 7 years and 25 ± 6 kg/m<sup>2</sup>, respectively. Bone mineral density of patients was measured at 3-month follow-up; Osteoporosis was confirmed at 3 months with a mean T-Score of -3.20 ± 1.2. Mean FRAX was 34% (range 5 to 74).

Six different orthopaedic surgeons performed the 10 procedures (1 to 3 cases by surgeon), with a mean intervention duration of 56 ± 19 min for device implantation and 37 ± 24 for hip fracture fixation in the opposite side. Mean cement quantity injected was 8 ± 1.6 ml.

Mean duration of hospitalisation was 14 days (range 5 to 29 days) and was always related to the hip fracture treatment on the opposite side. No additional rehabilitation was needed with respect to the one set up for the fracture. Walking recovery was not delayed by the device implantation. All patients could resume walking at hospital discharge.



Two cases of non-device related serious adverse events were reported in this cohort (thromboembolic event and anaemic episodes) and may rather be related to the treatment of the fractured hip done under the same anaesthesia. There was no case of wound infection nor bleeding; all patients achieved a complete wound healing at 3 month follow-up.

One case of cement leakage was reported: a patient experienced a high pain and was quickly hospitalized to remove an excess of cement located in soft tissues, which immediately resolved the pain. Median pain at the device implanted hip was 1 (range 0 to 4) at 3 week follow-up, indicating a very good short-term tolerance of the device. At 3 months, WOMAC scores for pain and functionality were 5 and 24, respectively, and 4 and 18 at 12 months.

Radiographic exams showed that the device remains in place in the bone and was stable 3 months after the intervention. None post-operative fracture was reported during the follow-up (Table 1).

## Discussion

Y-STRUT<sup>®</sup> was developed to offer a reinforcement solution for the prevention of fragility hip fractures in osteoporotic elderly patients with the advantage of being efficient immediately and constantly from implantation, contrary to non-surgical strategies such as osteoporosis drugs needing a difficult patient compliance to a long-term treatment and achieving efficacy after several years of administering or hip protectors not worn all day [8].

Otherwise, the technique of cementoplasty studied in several articles has major disadvantages due to the use of a gross amount of cement to achieve reinforcement leading to the risk of difficult revision and subtrochanteric fracture [17,18]. In this new technique, cement is needed to improve the contact surface and fix the implants into the bone and a very low amount of cement is used ( $8 \pm 1.6$  ml) comparing to Heini and Sutter (36 ml and 47 ml, respectively) [17,18].

One of the issues of preventing a second hip fracture is to identify the right patients who could fully benefit from the prevention, that is to say patients with the highest risk of new fracture. As shown on the study, FRAX assessment is a good tool to identify these specific patients. In addition, physicians, who could be the orthopaedic surgeon, the orthogeriatrician or geriatrician, the rheumatologists, have to evaluate the patients who are likely to have a second fracture by taking into account the activity of the patients before their first fracture and their medical history (ocular disease, dizziness, etc.).

Patients were recruited at the emergencies, thus the fixation of the fracture is planned quickly and the preventive act as to be decided simultaneously to be performed during the same intervention. Prophylaxis implied to not make patients running important risks with respect to the benefits. Indeed, operating the 2 hips leads to a unique anaesthesia and hospitalisation and mostly limits the risk of second fracture that will require a new surgery and hospitalisation and will lead to dependency and comorbidity in most of the cases [3]. Besides, in the study, longer anaesthesia ( $56 \pm 19$  min) was not related to any complications. Operation duration was longer than the additional 20 min reported by Giannini in his cohort of 34 patients [21]. These first 10 cases were performed by 6 different surgeons (1 to 3 cases by clinical center) and a learning curve should significantly reduce this additional operative time.

Besides, the mean hospitalization duration was not lengthened by the device implantation, as well as the rehabilitation protocol for the hip fracture fixation which was not modified by this second intervention. In

this first cohort of patients, the results have shown the feasibility and safety of the operative technique. Imaging control at 3 months has shown a good stability and osteointegration of the medical device and a good tolerance by the patients with a median pain of 1 at 3 week follow-up.

Finally, no fracture was reported after an average follow-up of 16 months (range 5 to 47 months)-and no patient died during the follow-up. All patients recovered full walking ability not achieved in the other similar technique-suggesting the potential of this new technique [21].

## Conclusion

Preliminary results from this first-in-man study showed the feasibility and safety of this new mini-invasive surgical approach to limit the risk of contralateral fragility hip fracture during the first year following the first fracture when the patients are at the highest risk of contralateral fracture and death. Besides tolerance was also demonstrated, making Y-STRUT<sup>®</sup> an encouraging solution for the osteoporotic elderly. Thus, more data (longer follow-up and a larger cohort of patients) are expected to confirm the clinical efficacy of the studied device.

## References

1. Sambrook P, Cooper C (2006) Osteoporosis. *Lancet* 367: 2010-2018.
2. Cooper C, Campion G, Melton LJ (1992) Hip fractures in the elderly: A worldwide projection. *Osteoporos Int* 2: 285-289.
3. Ekman EF (2010) The role of the orthopaedic surgeon in minimizing mortality and morbidity associated with fragility fractures. *J Am Acad Orthop Surg* 18: 278-285.
4. Schnell S, Friedman SM, Mendelson DA, Bingham KW, Kates SL (2010) The 1-year mortality of patients treated in a hip fracture program for elders. *Geriatr Orthop Surg Rehabil* 1: 6-14.
5. Ryg J, Rejnmark L, Overgaard S, Brixen K, Vestergaard P (2009) Hip fracture patients at risk of second hip fracture: A nationwide population-based cohort study of 1,69,145 cases during 1977-2001. *J Bone Miner Res* 24: 1299-1307.
6. Cameron ID et al. (2011) Improving Adherence With the Use of Hip Protectors Among Older People Living in Nursing Care Facilities: A Cluster Randomized Trial. *J Am Med Dir Assoc* 12: 50-57.
7. Inderjeeth CA, Foo ACH, Lai MMY, Glendenning P (2009) Efficacy and safety of pharmacological agents in managing osteoporosis in the old old: Review of the evidence. *Bone* 44: 744-751.
8. Rabenda V, Mertens R, Fabri V, Vanoverloop J, Sumkay F, et al. (2008) Adherence to bisphosphonates therapy and hip fracture risk in osteoporotic women. *Osteoporos Int* 19: 811-818.
9. Pazianas M, Miller P, Blumentals WA, Bernal M, Kothawala P (2007) A Review of the Literature on Osteonecrosis of the Jaw in Patients with Osteoporosis Treated with Oral Bisphosphonates: Prevalence, Risk Factors, and Clinical Characteristics. *Clin Ther* 29: 1548-1558.
10. De Groen PC, Lubbe DF, Hirsch LJ, Daifotis A, Stephenson W, et al. (1996) Esophagitis associated with the use of alendronate. *N Engl J Med* 335: 1016-1021.
11. Zografos GN, Georgiadou D, Thomas D, Kaltsas G, and Digalakis M (2009) Drug-induced esophagitis. *Dis esophagus Off J Int Soc Dis Esophagus* 22: 633-637.
12. Vestergaard P, Schwartz K, Pinholt EM, Rejnmark L, Mosekilde L (2010) Gastric and esophagus events before and during treatment of osteoporosis. *Calcif Tissue Int* 86: 110-115.
13. Sellmeyer DE (2010) Atypical fractures as a potential complication of long-term bisphosphonate therapy. *JAMA* 304: 1480-1484.
14. Bawa HS, Weick J, Dirschl DR (2015) Anti-Osteoporotic Therapy After Fragility Fracture Lowers Rate of Subsequent Fracture. *J Bone Jt Surgery-American* 97: 1555-1562.
15. Berry SD, Samelson EJ, Hannan MT, McLean RR, Lu M, et al. (2008) Second Hip Fracture in older men and women: The Framingham Study 1971-1976.

16. Dretakis EK, Steriopoulos KA, Kontakis GM, Giaourakis G, Economakis G, et al. (1998) Cervical hip fractures do not occur in arthrotic joints. A clinicoradiographic study of 256 patients. *Acta Orthop Scand* 69: 384-386.
17. Heini PF, Franz T, Fankhauser C, Gasser B, Ganz R (2004) Femoroplasty-augmentation of mechanical properties in the osteoporotic proximal femur: A biomechanical investigation of PMMA reinforcement in cadaver bones. *Clin Biomech* 19: 506-512.
18. Sutter EG, Wall SJ, Mears SC, Belkoff SM (2010) The effect of cement placement on augmentation of the osteoporotic proximal femur. *Geriatr Orthop Surg Rehabil* 1: 22-26.
19. Steenhoven VDTJ, Schaasberg W, De-vries AC, Valstar ER, Nelissen RGHH (2009) Augmentation with silicone stabilizes proximal femur fractures: An in vitro biomechanical study. *Clin Biomech* 24: 286-290.
20. Springorum HR, Gebauer M, Mehrl A, Stark O, Craiovan B, et al. (2014) Fracture prevention by prophylactic femoroplasty of the proximal femur-metallic compared with cemented augmentation. *J Orthop Trauma* 28: 403-409.
21. Giannini S, Luciani D, Chiarello E, Cadossi M, Tedesco G, et al. (2011) Osteosynthetic improvement of osteoporotic bone: Prevention surgery. *Clin Cases Miner Bone Metab* 8: 51-54.
22. Ferrari S, Reginster JY, Brandi ML, Kanis JA, Devogelaer JP, et al. (2016) Unmet needs and current and future approaches for osteoporotic patients at high risk of hip fracture. *Arch Osteoporos*. 11: 37.
23. Varga P, Hofmann-Fliri L, Blauth M, Windolf M (2016) Prophylactic augmentation of the osteoporotic proximal femur-mission impossible? *Bone key Rep* 5: 1-9.
24. Szpalski M, Gunzburg R, Aebi M, Delimoge C, Graf N, et al. (2015) A new approach to prevent contralateral hip fracture: Evaluation of the effectiveness of a fracture preventing implant. *Clin Biomech* 30: 713-719.
25. Cornelis FH, Tselikas L, Carteret T, Lapuyade B, Baere TD, et al. (2017) A Novel Implant for the Prophylactic Treatment of Impending Pathological Fractures of the Proximal Femur: Results from a Prospective, First-in-Man Study. *Cardiovasc Intervent Radiol* 40: 1070-1076.
26. Cornelis FH, Tselikas L, Carteret T, Lapuyade B, Baere TD, et al. (2017) Percutaneous internal fixation with Y-STRUT® device to prevent both osteoporotic and pathological hip fractures: a prospective pilot study. *J Orthop Surg Res* 12: 27.
27. Briot K (2012) Actualisation 2012 des recommandations françaises du traitement médicamenteux de l'ostéoporose postménopausique. *Rev Geriatr* 37: 469-479.
28. Angthong C, Suntharapa T, Harnroongroj T (2009) Major risk factors for the second contralateral hip fracture in the elderly. *Acta Orthop Traumatol Turc* 43: 193-198.
29. Delisle J (2006) Predicting factors of contralateral hip fractures among patients above 55 Years of Age.
30. Wolinsky FD, Fitzgerald JF (1994) Subsequent hip fracture among older adults. *Am J Public Health*. 84: 1316-1318.
31. Chapurlat RD, Bauer DC, Nevitt M, Stone K, Cummings SR (2003) Incidence and risk factors for a second hip fracture in elderly women. *The Study of Osteoporotic Fractures*. *Osteoporos Int* 14: 130-136.
32. Kanis JA, McCloskey EV, Johansson H, Cooper C, Rizzoli R, et al. (2013) European guidance for the diagnosis and management of osteoporosis in postmenopausal women. *Osteoporos Int* 24: 23-57.