

# Continuous Erector Spinae Plane Block for Anesthesia Management of Congenital Diaphragmatic Hernia in a Preterm Neonate

Pierre Goffin\*, Mathieu Georges

Department of Anesthesia and Intensive Care, MontLegia Hospital, Groupe Santé CHC, Liège, Belgium

## ABSTRACT

We describe the first reported use of a continuous Erector Spinae Plane Block for perioperative analgesia of a thoracoscopic surgery in a preterm neonate. We observed a high clinical efficacy and no secondary effect. Informed consent was obtained from parents for this publication.

**Keywords:** Pediatric anesthesia; Regional anesthesia; Erector block; Local anesthetics; Chest X-ray; Pulsoximetry

## INTRODUCTION

Congenital Diaphragmatic Hernia (CDH) is a developmental defect of the diaphragm presents in about 1:3000 live births that allows abdominal viscera to herniate into the chest [1]. Most often locates in left side. Pulmonary hypertension and lung hypoplasia are responsible of neonatal morbidity and mortality. The successful management of congenital diaphragmatic hernia is truly a multidisciplinary team. Surgical repair is not urgent but is the key treatment. We described the use of a continuous Erector Spinae Plane Block (ESPB) for perioperative analgesia of thoracoscopy surgery for CDH repair. Informed consent was obtained from parents for this publication.

## CASE PRESENTATION

A 9 days year-old, 2450 gr, former 34 weeks premature boy was postnatal diagnosed with Congenital Diaphragmatic Hernia. The prenatal obstetrical follow-up did not identify any abnormalities. A chest X-ray for respiratory distress at birth conducted to CDH diagnose. He was secondary transferred to our hospital for care. Diaphragmatic defect was left side located and 15 mm wide. No other malformation was associated. The echocardiography demonstrated a light left to right shunt but no pulmonary hypertension. The clinical condition is stable with limited oxygen supplementation.

Surgical correction was scheduled. Induction of anesthesia was performed with sevoflurane and fentanyl in spontaneous ventilation. After intubation, patient was turned into right lateral decubitus position.

For regional anesthesia procedure, T7 level was determined by palpation of the inferior angle of scapula. Under aseptic condition, the probe was placed in a transverse orientation to determine vertebra level of T5 (Logiq P9 GE Healthcare, with Hockey stick probe, 15 MHz). Then, the probe was turned to longitudinal orientation and moved laterally up to the identification of transverse process. The needle was inserted with an in-plane technique from cranial to caudal orientation up to contact with bone process. Two and half milliliter of ropivacaine 0.1% were injected deep to the erector spinae muscles to create a virtual hydro-dissected space. A catheter was inserted on 10 mm and skin fixed (Perifix® ONE Paed, B Braun, Melsungen, Germany. Tuohy needle 20 G and 24 G catheter).

The fourth surgical trocars levels were located from the mid-axillary to mid clavicular line, from T5 to T8 sensitive level. Standard anesthesia parameter (pulsoximetry, non-invasive blood pressure and ECG), invasive blood pressure and near-infrared spectroscopy were monitored throughout the procedure. The surgical thoracoscopy procedure was performed without any complication, intraoperative hemodynamic measurements remained stable. No other bolus of fentanyl was injected during surgery. At the end of surgery, the patient was transferred to neonatal intensive care unit and was extubated a few hours after. Breastfeeding was resumed four and half hours after awakening and the chest drain tube were removed on the first postoperative day.

Postoperatively ESPB catheter was infused at a rate of 2 ml/hour with ropivacaine 0.025%, to administrate a maximum of ropivacaine 0.2 mg/kg/h. Multimodal analgesia was ensuring with complementary dose of paracetamol (7.5 mg/kg/6h). Patient was

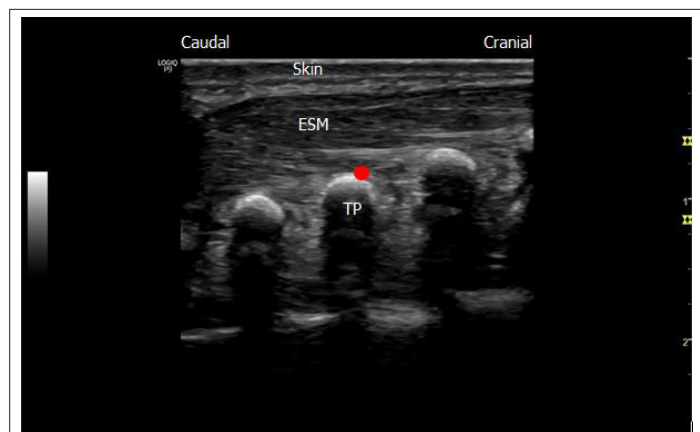
**Correspondence to:** Dr. Pierre Goffin, Department of Anesthesia and Intensive Care, MontLegia Hospital, Groupe Santé CHC, Liège, Belgium, Tel: 0032499738866; E-mail: pierre.goffin@chc.be.

**Received:** October 05, 2020; **Accepted:** October 21, 2020; **Published:** October 27, 2020

**Citation:** Goffin P, Georges M (2020) Continuous Erector Spinae Plane Block for Anesthesia Management of Congenital Diaphragmatic Hernia in a Preterm Neonate. J Anesth Clin Res. 11: 972. DOI: 10.35248/2155-6148.20.11.972.

**Copyright:** © 2020 Goffin P, et al. This is an open-access article distributed under the terms of the Creative Commons Attribution License, which permits unrestricted use, distribution, and reproduction in any medium, provided the original author and source are credited.

very comfortable according to pain score measure (Leuven Neonatal Pain Scale [2]). No morphine rescue was need for postoperative analgesia. Catheter was removed postoperatively at 48 hours with no reported complications. Patient was discharge 8 days after surgery without complication (Figure 1).



**Figure 1:** Image of our continuous Erector Spinae Plane Block technique (ESPB) (TP: Transverse Process; ESM: Erector Spinae Muscles; Red point: Needle target for ESP block at the transverse process and ESM meeting point).

## DISCUSSION

Previous cases report ESPB in neonate and this block is experimented in adult for analgesia in thoracic surgery [3]. Case report successful ESPB in neonate without use of catheter, providing enough analgesia through the perioperative period [4]. We have considered benefit to prolonged analgesia through catheter infusion. This is the first case in relating a continuous infusion for postoperative analgesia in a preterm neonate. ESPB is performed with LA deposition deep to the erector spinae muscle, superficial to the tip of the transverse process. The mechanism of analgesia is still controversial but seem to result from blockade of the ventral and dorsal rami of spinal nerve [5].

The volume of injected LA was 1ml/kg, adapted from Govender [5]. We used this volume to achieve four vertebral level, according the same author. It is markedly more than previous cases in neonate which injected 0.45-0.6 ml/kg approximately [4]. Possibly, LA spread to the paravertebral, epidural and intercostal spaces [6]. But we don't observe any hypotension or upper or lower limbs paresis.

LA dosage in neonate is still difficult to appreciate because of lack of evidence. We adapted volume infusion to ensure enough spread effect (ESPB is a diffusion block) and concentration to maintain low dilution and limited LA toxicity [7].

ESPB seems interesting compared to paravertebral or epidural block. Because it is easy to perform, particularly in this age group (very good echogenicity), and reduces the risk associated with central block and of pneumothorax [8].

## CONCLUSION

In conclusion, we have used the Erector Spinae Plane Block as part of a multimodal perioperative analgesic strategy in a preterm neonate. Our patient is the youngest to receive continuous ESPB in the current literature. Regional anesthesia technique has enhanced recovery after this thoracoscopic surgery with very comfortable

patient and without observed any clinical complication, supporting the effectiveness of Erector Spinae Plane Block in a premature neonate to ensure continuous analgesia in thoracic surgery. Further studies will be needed to define the maximum safe dose of LA, the optimal volume and infusion rate for continuous Erector Spinae Plane Block in infants.

## CONFLICTS OF INTEREST

The authors declare that there is no conflict of interest regarding the publication of this article.

## FUNDING

The authors have no sources of funding to declare for this manuscript.

## REFERENCES

1. Dingeldein M. Congenital diaphragmatic hernia: Management and outcomes. *Adv Pediatr.* 2018;65(1): 241-247.
2. Allegaert K, Tibboel D, Naulaers G, Tison D, De Jonge A, Van Dijk M, et al. Systematic evaluation of pain in neonates: Effect on the number of intravenous analgesics prescribed. *Eur J Clin Pharmacol.* 2003;59(2): 87-90.
3. Cassai ADE, Bonvicini D, Correale C, Sandei L, Tulgar S, Tonetti T. Erector spinae plane block: A systematic qualitative review. *Minerva Anesthesiol.* 2019;85(3): 308-319.
4. Basaran B, Akkoyun I. Erector spinae plane block for management of major abdominal surgery in a low birth weight preterm neonate. *J Clin Anesth.* 2020;61(9): 109641.
5. Govender S, Bosenberg A, Mohr D, Schoor AN Van. The extent of cranio-caudal spread within the erector spinae fascial plane space using computed tomography scanning in a neonatal cadaver. *Pediatr Anesth.* 2020;30: 667-670.
6. Govender S, Mohr D, Bosenberg A, Schoor AN Van. A cadaveric study of the erector spinae plane block in a neonatal sample. *Reg Anesth Pain Med.* 2020;45: 386-388.
7. Patel D. Epidural analgesia for children. *BJA Educ.* 2006;6(2): 63-66.
8. Aksu C, Gurkan Y. Defining the Indications and Levels of Erector Spinae Plane Block in Pediatric Patients: A Retrospective Study of Our Current Experience. *Cureus.* 2019;11(8).