

## Comparison of Direct and Video Assisted Views of the Larynx during Routine Intubation in Infants and Children

Ashwani K Chhibber<sup>1\*</sup>, Dawn Sweeney<sup>2</sup>, Kenneth Cheng<sup>3</sup> and Amie Hoefnagel<sup>4</sup>

<sup>1</sup>Professor of Anesthesiology and Pediatrics, University of Rochester Medical Center Anesthesiology, USA

<sup>2</sup>Associate Professor of Anesthesiology and Pediatrics, University of Rochester Medical Center Anesthesiology, USA

<sup>3</sup>Associate Professor of Anesthesiology, University of Rochester Medical Center Anesthesiology, USA

<sup>4</sup>Assistant professor of Anesthesiology, University of Rochester Medical Center Anesthesiology, USA

### Abstract

**Purpose:** Video assisted laryngoscopy has been rapidly incorporated into the anesthesiologist's arsenal for challenging adult airway management. The development of pediatric video airway equipment presents an opportunity to expand upon the previous reliance on direct laryngoscopy alone. This study utilized the Storz DCI® Video Laryngoscope which consists of a standard straight 0 and 1 blade combined with a 2.8 mm fiberoptic light bundle built into the left side of the blade.

**Method:** The ease of use, best direct and video-assisted glottic view was documented for 50 infants and children less than 2 years of age. Direct laryngoscopy was performed with the naked eye (direct view). The best views obtained with and without external laryngeal manipulation were graded by the laryngoscopist without looking at the video monitor. The views on the video monitor, located in front of the intubator and to the right of the patient, were simultaneously graded independently by another pediatric anesthesiologist.

**Results:** Fifty infants and children, ages ranging from one day to 22 months, were enrolled in the study. There were 37 males, and 13 females. The average age was 10.5 months. ASA physical status ranged from I to III, with the vast majority of patients being either class I or II. The grade of laryngeal view on the video monitor was significantly improved when compared with that of direct laryngoscopy ( $p < 0.05$ ).

**Conclusion:** In our study the view on the monitor screen was, on average, one grade better than the direct view. In only one instance was the view obtained with the video laryngoscope worse than that obtained under direct vision. The magnified view provided by the video laryngoscope allows for better visualization of airway structures in difficult airways and further help in facilitating securing the airway.

**Keywords:** Pediatric airway management, Video laryngoscope, Difficult pediatric airway, Laryngoscope

### Introduction

Direct laryngoscopy blades revolutionized airway management due to direct glottic visualization at their inception [1,2]. Such laryngoscopes are traditionally powered by a battery in the handle, which is connected to a small light bulb at the distal end of the blade, allowing illumination of the airway. Further advances improved the illumination and view by incorporating a fiber-optic light guide into the blade [3]. Video assisted laryngoscopy combines the capabilities of direct laryngoscopy, and simultaneously provides video screen assisted magnified views of the larynx and immediate adjacent structures. This has been widely used in adults and shown to provide an improved view of the larynx, as compared with direct visualization in patients undergoing general anesthesia [4,5].

Prior studies have tried to mimic difficult airway conditions in the pediatric patient to compare direct vs. video laryngoscopy [6]. Additional studies have compared devices across difficult airway situations [7] however there remains mixed data regarding the difficult pediatric airway, and studies in children less than 2 years of age are lacking. This study compares the visualization of the larynx obtained by direct laryngoscopy in contrast to that seen with video laryngoscopy during endotracheal intubation in infants and children less than 2 years of age.

### Materials and Methods

After approval from the Institutional Review Board, 50 ASA status I-III children up to the age of two years, who were scheduled to

receive general anesthesia requiring tracheal intubation for an elective procedure, were enrolled in this study. Exclusion criteria included: patients with an acute abdomen, high risk of aspiration, oropharyngeal pathology, and limited mouth opening.

Laryngoscopy and intubation in each patient was accomplished with a Storz DCI® Video Laryngoscope. This consists of a standard straight 0 and 1 blade combined with a 2.8 mm fiberoptic light bundle built into the left side of the blade. This scope has a small video camera incorporated with the image sensor and fiberoptic light, together that is used as a handle, which is attached to the blade (Figure 1).

All practitioners were experienced pediatric anesthesiologists with extensive experience in the performance of conventional direct laryngoscopy in children and video laryngoscopic tracheal intubation in adults. A representative of Karl Storz then trained each of them in the use of the pediatric video laryngoscope on a manikin. Additionally,

**\*Corresponding author:** Ashwani K Chhibber, Department of Anesthesiology and Pediatrics, University of Rochester Medical Center Anesthesiology, 601 Elmwood Ave, Box 604, Rochester, New York 14642, USA, Tel: 1-585-275-1386; Fax: 1-585-244-7271; E-mail: [Ashwani\\_chhibber@URMC.Rochester.edu](mailto:Ashwani_chhibber@URMC.Rochester.edu)

**Received** October 17, 2014; **Accepted** December 03, 2014; **Published** December 10, 2014

**Citation:** Chhibber AK, Sweeney D, Cheng K, Hoefnagel A (2014) Comparison of Direct and Video Assisted Views of the Larynx during Routine Intubation in Infants and Children. J Anesth Clin Res 5: 481. doi:10.4172/2155-6148.1000481

**Copyright:** © 2014 Chhibber AK. This is an open-access article distributed under the terms of the Creative Commons Attribution License, which permits unrestricted use, distribution, and reproduction in any medium, provided the original author and source are credited.



**Figure 1:** Video Handle containing a small TV camera incorporating the image sensor and fiber light together attached to the blade and a suction cannula with rounded tip.

each anesthesiologist performed 2 to 5 intubations in children using the video laryngoscope before the inception of the study. All children received general anesthesia, which was not standardized but left to the usual practice of the anesthesiologist.

Patient enrollment was not randomized. A data sheet in the form of a questionnaire was provided for the uniform recording of data by each participating anesthesiologist.

The view of the glottis was rated using five grades according to the Cormack-Lehane scoring system as modified by Yentis and Lee [8]: 1=full view of the glottis; 2a=partial view of the glottis; 2b=arytenoids or posterior portion of cords only visible; 3=only the epiglottis visible; 4=neither epiglottis nor glottis visible [5].

All participating anesthesiologists were trained in the use of this rating system until they were proficient. Direct laryngoscopy was performed with the naked eye (direct view). The best views obtained with and without external laryngeal manipulation were graded by the laryngoscopist without looking at the video monitor. The views on the video monitor, located in front of the intubator and to the right of the patient, were simultaneously graded independently by another pediatric anesthesiologist. External manipulation required to obtain a view of the glottic opening were not scored or standardized. These maneuvers were utilized and then the airway visualization grade was obtained for both the direct visualization and the video laryngoscopy.

Subjective assessments regarding the views obtained with the pediatric video laryngoscope were made, comparing these views with the traditional laryngoscope blade views (better, same, or worse). Difficult laryngoscopy was defined as the inability to visualize the vocal cords, which included grades 3 and 4 on the scoring system described above. One grade difference in the view between direct and video laryngoscopy was considered significant. In case of a difficult airway the laryngoscopist was allowed to look at the screen view to assist in directing endotracheal tube (ETT) into the trachea.

All data were collected on standardized forms. The data was aggregated as a chi square table, and analyzed using McNemar's test to compare the paired proportions. Statistical analysis was performed using the STATA statistical package (STATA Corporation, College Station, Texas.) A p value <0.05 was considered significant.

## Results

Fifty infants and children, ages ranging from one day to 22 months, were enrolled in the study. There were 37 males, and 13 females. The average age was 10.5 months. ASA physical status ranged from I to III, with the vast majority of patients being either class I or II. The average weight was 7.8 kg.

In all cases the best view obtained by direct and videoscopic laryngoscopy was grade 3 or lower and grade 2 or lower respectively. The grade of laryngeal view on the video monitor was significantly improved when compared with that of direct laryngoscopy ( $p < 0.05$ ).

One child's video view was one grade lower than that obtained from direct laryngoscopy. Thirteen patients had grade 2b view and two had grade 3 views with direct laryngoscopy (Figure 2). On the video monitor out of two patients with a grade 3 view one was graded as 2a and other as grade 2b view. Out of 13 patients with grade 2b view with direct laryngoscopy 6 patients had grade 2a and 7 patients had grade 1 view on the monitor. All 15 patients were intubated by directing the ETT while looking at the video monitor. Tracheal manipulation significantly improved the view in both direct and video monitored views (Figures 2-4).

## Discussion

There are various video laryngoscopic devices such as Malleable video-optical intubation stylet (VOIS) [9,10], Glidescope® video laryngoscope, [11,12] AIRTRAQ® Disposable Optical Laryngoscope, Truview PCD™, [12] and Storz's pediatric video laryngoscope (Figure 1). We studied the latter because of the extensive use of a straight blade laryngoscope in intubating infants and children. Unlike the wide curved blade of the pediatric/neonatal Glidescope®, it was the most similar to the blade used in our routine pediatric anesthesia practice. We observed that with this device the larynx could be visualized directly along with enlarged live video image of larynx and immediate surrounding structures on the screen (Figure 5). To deal with secretions, the instrument has a miniature 3 mm ball tip stainless steel suction with side holes (Figure 1).

There may be potential advantages in the use of pediatric video laryngoscopy.

Management of airway in infants and children, especially those with a difficult airway, can be challenging and stressful. A relatively large tongue, anteriorly slanted vocal cords, large floppy epiglottis, and small oral cavity are the major factors involved in making tracheal intubation more challenging in infants and young children as compared with adults [13]. In our study, two patients with modified Cormack-Lehane score of 3 on direct view were intubated with a grade 2 view as seen on the video screen. By utilizing the video blade to visualize the larynx and immediate surrounding structures the endotracheal tube (with a stylet) was able to be advanced into the trachea.

Similar to a study by Weiss et al. [14] we see a role for the pediatric video laryngoscope in the education of residents and medical students. To start, the learner can begin to identify airway structures while an experienced laryngoscopist is performing tracheal intubation. As the novice begins performing laryngoscopy the attending anesthesiologist can see the technical skills and provide guidance in real time. This may be even more important in the management of the emergency or difficult airway or in clinical situations where there is increased risk of aspiration of gastric contents. During these situations the student can perform the technical management while the attending anesthesiologist

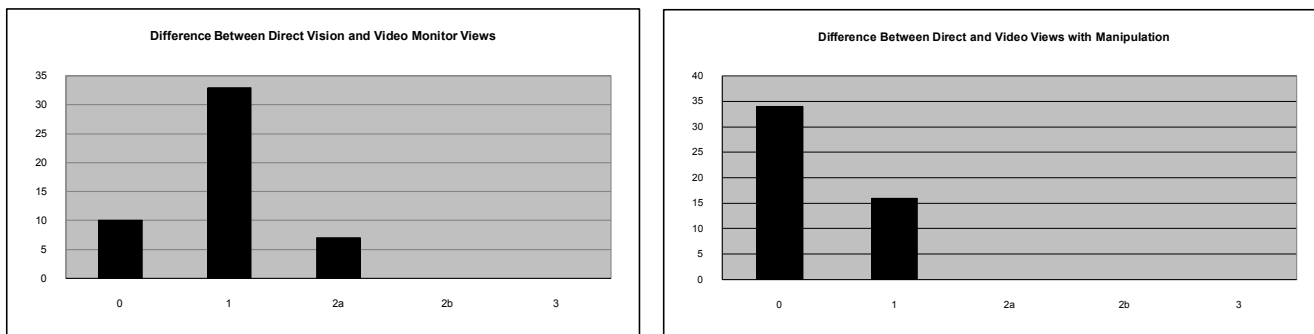


Figure 2: Shows the difference in views obtained between direct vision and use of the video laryngoscope, with and without tracheal manipulation. The view obtained with the video laryngoscope was the same or superior to the view obtained by direct vision.

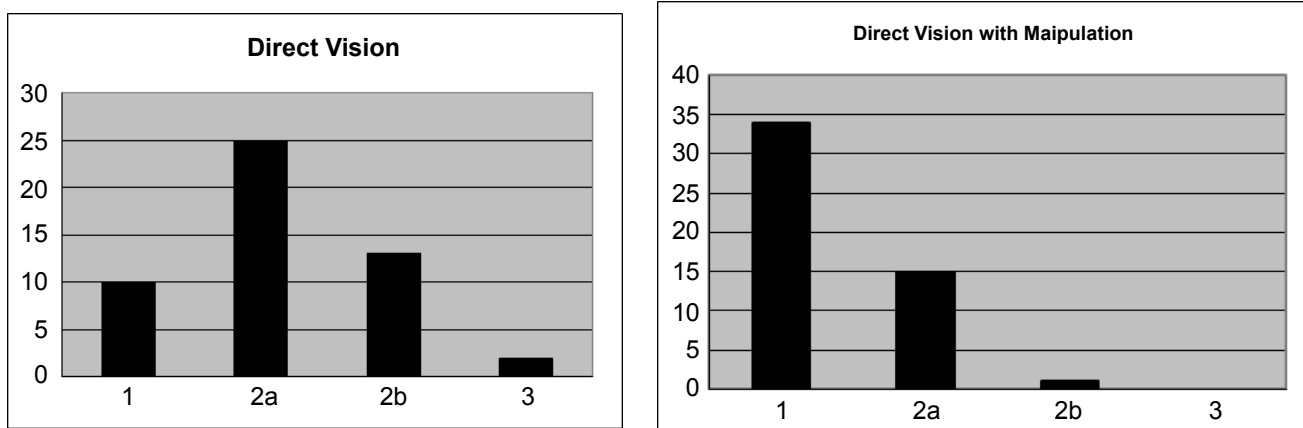


Figure 3: Shows the best grade view obtained under direct vision with and without tracheal manipulation.

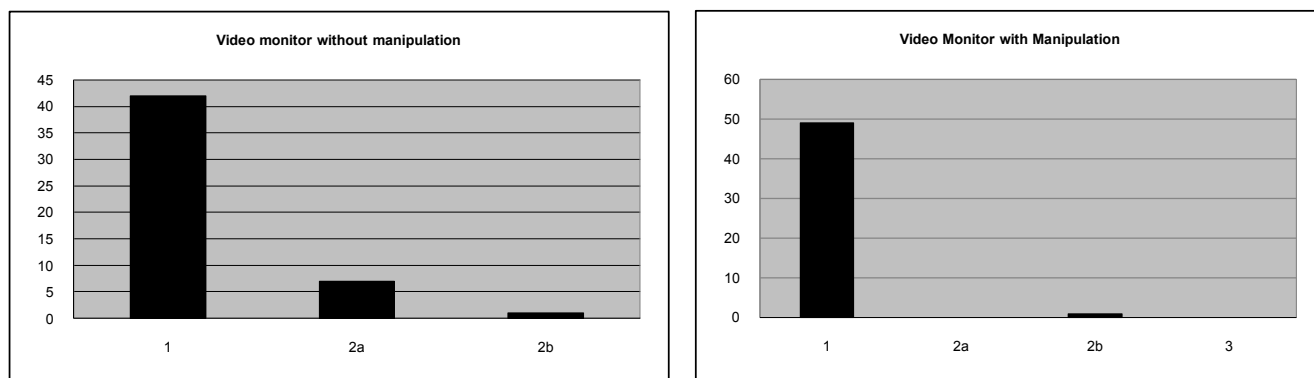
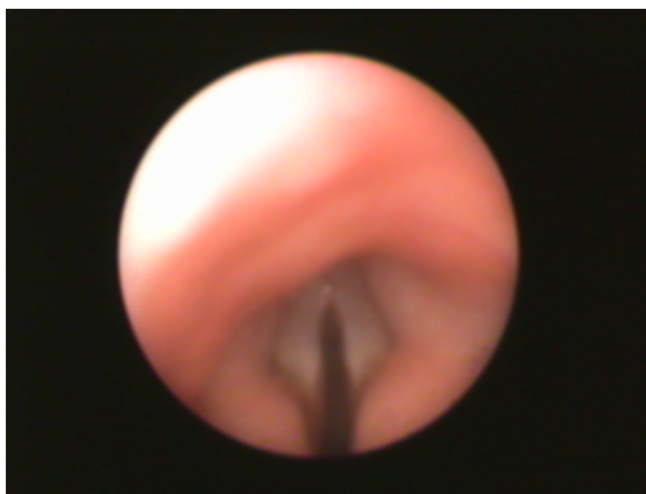


Figure 4: Shows the best grade view obtained using the video laryngoscope with and without tracheal manipulation.

maintains visualization and can provide instruction, facilitating timely intubation by the resident. Further, images obtained with the pediatric video laryngoscope can be easily recorded for teaching, documentation purposes, or further review. Video laryngoscopy as a teaching tool should not be limited to the operating theatre, but extended to the Neonatal Intensive Care Units, and Pediatric Emergency Departments.

Observer bias cannot be completely eliminated in this study. We tried to avoid bias by having fully trained pediatric anesthesiologists

who also had extensive experience with use of a videoscope in adults. In our experience with the Storz Video Laryngoscope we found the built-in suction device easy to use in a traumatic manner, but we observed that the bore of the cannula is too narrow and is not useful in suctioning copious secretions. We did encounter in some patients, difficulty in keeping the mouth wide open with this narrow laryngoscope blade. This is in contrast to a regular straight blade, which has an elevated ridge that prevents the mouth from closing. We overcame this by assistance of a finger to hold open the mouth by the laryngoscopist.



**Figure 5:** View of Pediatric airway obtained with video laryngoscope without lifting epiglottis.

## Conclusion

We found the Storz pediatric video laryngoscope to be easy to use in infants and children utilizing both direct and video assisted views. In our study the view on the monitor screen was, on average, one grade better than the direct view. The magnified view provided can allow for better visualization of airway structures in difficult airways and further help in facilitating securing the airway. In only one instance was the view obtained with the video laryngoscope worse than that obtained under direct vision, and that was when laryngeal manipulation was used under direct vision and not during visualization with the video laryngoscope. Improving design of the blade by adding ridge/lip of traditional straight blade may further improve process of intubation by its ability in keeping mouth opening possible in all cases especially in neonates.

## Acknowledgement

We would like to thank Karl Storz for providing the video laryngoscope that was used in this study.

## References

1. Macintosh RR (1932) A new laryngoscope blade. *Lancet* 1: 205.
2. Miller RA (1941) A new laryngoscope. *Anesthesiology* 2: 317.
3. Marks RR, Hancock R, Charters P (1993) An analysis of laryngoscope blade shape and design: new criteria for laryngoscope evaluation. *Can J Anaesth* 40: 262-270.
4. Kaplan MB, Hagberg CA, Ward DS, Brambrink A, Chhibber AK, et al. (2006) Comparison of direct and video-assisted views of the larynx during routine intubation. *J Clin Anesth* 18: 357-362.
5. Kim HJ, Kim JT, Kim HS (2001) A comparison of GlideScope® video laryngoscopy and direct laryngoscopy for nasotracheal intubation in children. *Pediatr Anesth* 21: 417-421.
6. Vlaten A, Litz S, MacManus B, Launcelott S, Soder C (2012) A comparison of the GlideScope video laryngoscope and standard direct laryngoscopy in children with immobilized cervical spine. *Pediatr Emerg Care* 28: 1317-1320.
7. Armstrong J, John J, Karsli C (2010) A comparison between the GlideScope Video Laryngoscope and direct laryngoscope in paediatric patients with difficult airways - a pilot study. *Anaesthesia* 65: 353-357.
8. Yentis SM, Lee DJ (1998) Evaluation of an improved scoring system for the grading of direct laryngoscopy. *Anaesthesia* 53: 1041-1044.
9. Weiss M, Hartmann K, Fischer J, Gerber AC (2001) Video-intuboscopic assistance is a useful aid to tracheal intubation in pediatric patients. *Can J Anaesth* 48: 691-696.
10. Biro P, Weiss M (2001) Comparison of two video-assisted techniques for the difficult intubation. *Acta Anaesthesiol Scand* 45: 761-765.
11. Kim HJ, Chung SP, Park IC, Cho J, Lee HS, et al. (2008) Comparison of the GlideScope video laryngoscope and Macintosh laryngoscope in simulated tracheal intubation scenarios. *Emerg Med J* 25: 279-282.
12. Holm-Knudsen R (2011) The difficult pediatric airway--a review of new devices for indirect laryngoscopy in children younger than two years of age. *Paediatr Anaesth* 21: 98-103.
13. Wetzell R (2008) Evaluation of Children. In Longnecker DE, editor: *Anesthesiology*, McGraw Hill, New York: pp: 310-340.
14. Weiss M, Schwarz U, Dillier CM, Gerber AC (2001) Teaching and supervising tracheal intubation in paediatric patients using videolaryngoscopy. *Paediatr Anaesth* 11: 343-348.