

Communications of Transverse Cervical Cutaneous Nerve with the Cervical Branch of Facial Nerve and its Variant Nerve Endings Deep in the Parotid Gland

Srinivasa Rao Sirasanagandla*, Swamy Ravindra S, Sapna Marpalli and Satheesha Nayak B

Department of Anatomy, Melaka Manipal Medical College, Manipal University, Madhav Nagar, Manipal, Karnataka, India

Abstract

Anastomoses between the transverse cervical cutaneous nerve and the cervical branch of facial nerve are regularly present. The anatomic locations of these anastomoses were poorly documented in the literature. During regular dissection, we came across two of such anastomoses: one of the two anastomoses was identified posterior to submandibular gland, and the other was noted within the parenchyma of the parotid gland. Prior knowledge of anatomic locations of these anastomoses is clinically important as it allows a method for identification and preservation of the cervical branch of the facial nerve as well as a starting point for retrograde facial nerve dissections. In addition, few terminal nerve endings of transverse cervical cutaneous nerve were seen along the retromandibular vein, ducts and some were penetrating the interlobular septa of parotid gland. The functional significance of anatomic variations of its nerve terminal ends deep in the gland is yet to be evaluated.

Keywords: Anastomoses; Transverse cervical cutaneous nerve; Cervical branch of facial nerve; Parotid gland; Submandibular gland

Introduction

Cervical plexus is formed by the ventral rami of upper four cervical spinal nerves and supply some of the areas of skin on the head, neck and chest through its cutaneous branches. It lies deep to the prevertebral fascia, and its superficial cutaneous branches, the lesser occipital nerve, great auricular nerve (GAN), transverse cervical cutaneous nerve

(TCCN) and supraclavicular nerves pierce the fascia to supply the skin. Transverse cutaneous nerve arises from the second and third cervical ventral rami and then curves around the midpoint of posterior border of sternocleidomastoid muscle and runs obliquely forwards passing deep to the external jugular vein. It crosses the anterior border of the muscle and perforates the deep cervical fascia before dividing into ascending and descending branches. The ascending branch supplies the skin of upper anterior areas of neck after piercing the platysma while the descending branch supplies anterolaterally to the skin of neck till the level of sternum [1]. Anastomoses between the TCCN and the cervical branch [CB] of facial nerve are regularly present [2]. The anatomic locations of these anastomoses are poorly documented in the medical literature [2]. Herein, we report the anatomic location of anastomoses between the TCCN and CB of facial nerve and discuss its clinical significance.

Case Report

During routine dissection classes to first year medical students, we came across an anatomical variation of superior division of TCCN, in the Department of Anatomy, Melaka Manipal Medical College, Manipal University, Manipal. The variation was observed in an adult male cadaver. The terminal branches of TCCN and CB of facial nerve were traced carefully. The appropriate photograph was taken (Figure 1).

Results

***Corresponding author:** Srinivasa Rao Sirasanagandla, Department of Anatomy, Melaka Manipal Medical College, Manipal University, Madhav Nagar, Manipal, Karnataka, India, Tel: +91-820-2922644; Fax: +91-820-2571905; E-mail: seenaih.anat@gmail.com

Received December 26, 2012; **Accepted** January 22, 2013; **Published** January 24, 2013

Citation: Srinivasa Rao S, Swamy Ravindra S, Sapna Marpalli, Satheesha Nayak B (2013) Communications of Transverse Cervical Cutaneous Nerve with the Cervical Branch of Facial Nerve and its Variant Nerve Endings Deep in the Parotid Gland. *Anatom Physiol* 3: 114. doi:10.4172/2161-0940.1000114

Copyright: © 2013 Srinivasa Rao S, et al. This is an open-access article distributed under the terms of the Creative Commons Attribution License, which permits unrestricted use, distribution, and reproduction in any medium, provided the original author and source are credited.

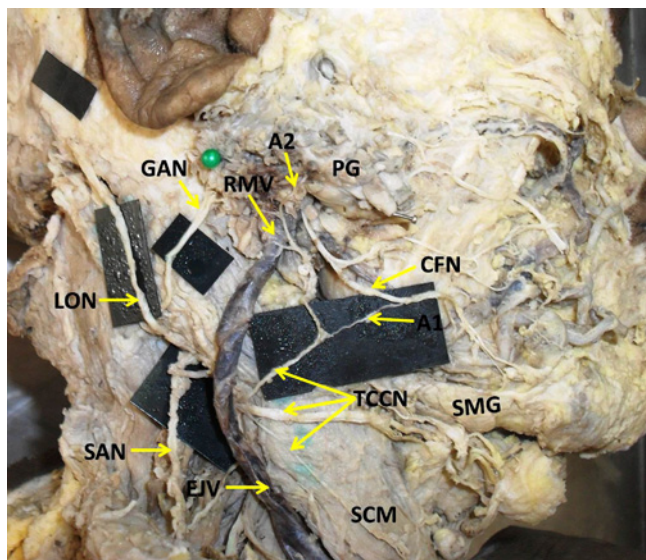


Figure 1: Close view of dissected right side of the neck and parotid region showing the anastomoses (A1 and A2) between ascending branch of TCCN and CFN. The terminal nerve endings of TCCN passing along the RMV and penetrating into the substance of parotid gland are also shown.

TCCN: Transverse Cervical Cutaneous Nerve; A1 and A2: Anastomoses between the transverse cervical cutaneous nerve and cervical branch of facial nerve; CFN: Cervical Branch of Facial Nerve; SMG: Submandibular Gland; PG: Parotid Gland; EJV: External Jugular Vein; SCM: Sternocleidomastoid Muscle; GAN: Great Auricular Nerve; LON: Lesser Occipital Nerve; SAN: Spinal Accessory Nerve; RMV: Retromandibular Vein

The TCCN arose from the loop of ventral rami of C2 and C3 spinal nerves and divided into superior, middle and inferior branches. The superior branch ran obliquely upwards towards the parotid gland along with the external jugular vein. On the way, it gave a communicating branch to CB of facial nerve posterior to the submandibular gland [SMG]. (Figure 1). Upon careful dissection of the main branch in the parenchyma of the gland, it was further divided into many small branches. One of its branches was noted to be communicated with the cervical branch of facial nerve with in the parenchyma of the parotid gland. Rest of the nerve endings were seen along the retromandibular vein, ducts and some were penetrating the interlobular septa of the gland (Figure 1).

Discussion

Communications between TCCN and the GAN as well as some cranial nerves usually exist and are reported in the past [1,3,4]. Biglioli et al. [5] have been reported an anastomosis between the TCCN and anterior branch of GAN. Kim et al. have been identified an anatomical variation of close relation between the TCCN and GAN as they were emerging from the paravertebral fascia [6]. TCCN and GAN commonly communicate with the CB of facial nerve [1,4]. TCCN usually divides into ascending and descending branches, the ascending branch forms plexus with the cervical branch, deep to platysma muscle in the submandibular region [1]. Domet et al. [7] have demonstrated the presence of anastomoses between the CB of facial nerve and TCCN in 22 adult neck halves (11 cadavers). In their study, a total of 33 anastomoses were identified, with at least one anastomosis per hemineck and two anastomoses in 11 heminecks. Anastomoses were observed posterior to the SMG (12 specimens) or along the inferior border of the sSMG (20 specimens). In the present case one of the two anastomoses was identified posterior to SMG and other was noted within the parenchyma of the parotid gland. Knowledge of anatomical positions of these anastomoses is clinically important as it allows a method for identification and preservation of the CB of the facial nerve as well as a starting point for retrograde facial nerve dissections [7]. The stimulation of communicating branch of TCCN during neck surgeries

might results the contraction of platysma, and could potentially cause the operating surgeon to think that it was a branch of the facial nerve. The knowledge of anatomic variations of TCCN may also help the anesthesiologists and the surgeons to prevent iatrogenic injury to TCCN during anesthesia blocks, surgical procedures, treatment of pain and abnormalities relating to TCCN.

The termination of anterior branch of GAN along the ducts and vessels deep in the parotid gland has been considered as an anatomical variation. In a study by Zohar et al. nerve bundles of GAN were found to penetrate the interlobular septa in 13% cases and nerve bundles were seen deep in the gland close to small ducts and thin-walled blood vessels in 30 % cases [2]. In the present case, we noted the terminal ends of TCCN deep in the parotid gland. Few branches of TCCN were penetrating the interlobular septa and few of them were thin walled blood vessels (retromandibular vein). The functional significance of anatomic variations of TCCN deep in the parotid gland, in relation to ducts and vessels are yet to be evaluated.

References

1. Standring S (2008) Neck. In: Standring S ed. *Gray's Anatomy*. Edinburgh: Churchill Livingstone, 435-436.
2. Zohar Y, Siegal A, Siegal G, Halpern M, Levy B (2002) The great auricular nerve; does it penetrate the parotid gland? An anatomical and microscopical study. *J Craniomaxillofac Surg* 30: 318-321.
3. Kierner AC, Zelenka I, Heller S, Burian M (2000) Surgical anatomy of the spinal accessory nerve and the trapezius branches of the cervical plexus. *Arch Surg* 135: 1428-1431.
4. Sinnatamby CS (2006) Head and neck and spine. In: Sinnatamby CS ed. *Last's Anatomy*. Edinburgh, Churchill Livingstone, 345-347.
5. Biglioli F, D'Orto O, Bozzetti A, Brusati R (2002) Function of the great auricular nerve following surgery for benign parotid disorders. *J Craniomaxillofac Surg* 30: 308-317.
6. Kim HJ, Koh KS, Oh CS, Hu KS, Kang JW, et al. (2002) Emerging patterns of the cervical cutaneous nerves in Asians. *Int J Oral Maxillofac Surg* 31: 53-56.
7. Domet MA, Connor NP, Heisey DM, Hartig GK (2005) Anastomoses between the cervical branch of the facial nerve and the transverse cervical cutaneous nerve. *Am J Otolaryngol* 26: 168-171.