

# Cataract Surgery during Anti-TNF- $\alpha$ Therapy (Infliximab) for Behçet's Disease

Shigenari Suzuki\*

Department of Ophthalmology, Dokkyo Medical University, 880 Kitakobayashi Mibumachi, Shimotsugagunn, Tochigi 321-0293, Japan

## Abstract

**Background:** In cases of complicated cataract due to Behçet's disease, flare-ups of attacks of ocular inflammation tend to occur after cataract surgery. Because these flare-ups may often result in loss of vision in Behçet's disease, attention is now being paid to complicated cataract surgery with the administration of infliximab, which provides powerful long-term suppression of attacks of ocular inflammation.

**Case Report:** Surgery was performed for complicated cataract due to Behçet's disease with highly active uveitis in a patient who was being treated with infliximab. The patient was a 25-year-old man. Cataract surgery had been postponed due to highly active uveitis, but surgery was eventually performed while infliximab was being administered after the ocular inflammation had subsided as a result of this medication. The patient's course was uneventful, with no postoperative flare-ups of ocular inflammation or infection.

**Conclusion:** Concomitant use of infliximab enables the safe performance of surgery for complicated cataract due to Behçet's disease even in patients with highly active uveitis. And cataract surgery can be performed at any point during infliximab administration (5mg/kg) other than the induction period.

**Keywords:** Behçet's disease; Complicated cataract; Anti-TNF- $\alpha$  therapy; Infliximab (Remicade®); Intra-ocular surgery; Uveitis

**Abbreviations:** TNF: Anti Human Tumor Necrosis Factor; INF: Interferon; EULAR: The European League Against Rheumatism

## Introduction

Uveitis in Behçet's disease may be accompanied by complications such as cataract, glaucoma, vitreous hemorrhage, and retinal detachment. In these complications, cataracts are often needed to be treated surgically [1].

In 2007, the antihuman tumor necrosis factor- $\alpha$  agent infliximab was approved for use in Japan to treat refractory chorio-retinitis due to Behçet's disease. It was discovered that complicated cataract surgery could be performed safely even in patients with highly active uveitis. Surgery for complicated cataract due to Behçet's disease during infliximab therapy has since become a topic of discussion. This new finding was disseminated from Japan [2-6]. In this paper, the latest developments in surgery for complicated cataract due to Behçet's disease are described.

## Cataract Surgery in Behçet's Disease

### Surgical procedure

In Japan, colchicines and cyclosporine A are commonly used to treat panuveitis due to Behçet's disease. In 2007, Japan became the first country to approve the use of infliximab (Remicade®, Mitsubishi Tanabe Pharma Corporation, Japan) for this condition. It has since been used to treat refractory chorio-retinitis due to Behçet's disease, with good therapeutic results.

The EULAR recommendations for the management of Behçet's disease state (2008) that azathioprine and systemic corticosteroids should be used for eye involvement, while for refractory eye involvement, either cyclosporine A (2-5mg/kg/day) or infliximab should be used in combination with azathioprine and corticosteroids; alternatively IFN ( $\alpha$ ) with or without corticosteroids can be used [7].

The surgical technique used for complicated cataract due to Behçet's disease has evolved from intracapsular cataract extraction to extracapsular cataract extraction and from planned extracapsular extraction to phacoemulsification, in the same way as age-related cataract surgery. This evolution of the surgical procedure has reduced the invasiveness of the surgery, resulting in increased opportunities for intraocular lens implantation and improved postoperative outcomes [8-11]. On the other hand, it is known that surgery may contribute to post-operative flare-ups of attacks of ocular inflammation in some patients [9-11].

### Cataract surgery with concomitant use of colchicine or cyclosporine A

Before the advent of infliximab, there was a high incidence of postoperative attacks of ocular inflammation (33.3-51.8%) [8,10,11], which carried the risk of blindness. Hiraoka and Fujino reported that the frequency of attacks of ocular inflammation after surgery for complicated cataract due to Behçet's disease increased to 7 of 19 patients (36.8%) compared with before surgery, and that such attacks were more common in patients using cyclosporine A (an immunosuppressant) with a shorter disease duration [10]. Goda et al. [11] reported that attacks of ocular inflammation occurred in 29 of 56 eyes (51.8%) following surgery for complicated cataract due to Behçet's

\*Corresponding author: Shigenari Suzuki, Department of Ophthalmology, Dokkyo Medical University, 880 Kitakobayashi Mibumachi, Shimotsugagunn, Tochigi 321-0293, Japan, Tel: +81 282 86 1111 / 2675; Fax: +81 282 86 0630; E-mail: s-suzuki@dokkyomed.ac.jp

Received December 02, 2011; Accepted February 05, 2012; Published February 12, 2012

Citation: Suzuki S (2012) Cataract Surgery during Anti-TNF- $\alpha$  Therapy (Infliximab) for Behçet's Disease. J Clin Exp Ophthalmol S1:004. doi:10.4172/2155-9570.S1-004

Copyright: © 2012 Suzuki S. This is an open-access article distributed under the terms of the Creative Commons Attribution License, which permits unrestricted use, distribution, and reproduction in any medium, provided the original author and source are credited.

disease, with flare-ups of attacks of ocular inflammation occurring in all six eyes of the six patients who underwent surgery within 3-months of the last attack, but patients who underwent surgery  $\geq 7$  months after the last attack had good outcomes.

Before the advent of infliximab, it was therefore considered that, in patients with short uveitis disease duration or in those in whom it was sufficiently active to warrant the use of the immunosuppressant cyclosporine A, surgery for complicated cataract due to Behçet's disease should be performed from at least 6 to 12 months after the inflammation had subsided [11].

In a few patients, however, surgery could not be performed because the inflammation failed to subside, or surgery resulted in flare-ups of attacks of ocular inflammation even though the inflammation had subsided within 6 months [10].

### 5.3 Cataract surgery with concomitant use of infliximab

**Post-operative infection of infliximab was regarded as dose-dependent:** Infliximab has three known mechanisms of action: (i) it binds to and neutralizes soluble TNF- $\alpha$ ; (ii) it blocks TNF- $\alpha$  producer cells by binding to membrane-bound TNF- $\alpha$  on the surface of the cell membrane; and (iii) it dissociates receptor-bound TNF- $\alpha$ . Infliximab resolves inflammation following cataract surgery or due to Behçet's disease, in which TNF- $\alpha$  is involved, within a short period (24 h to 1 week) [12], and suppresses it over the long term [13]. Its pharmacological action led to the discussion of surgery for complicated cataract due to Behçet's disease during concomitant use of infliximab, and there have been reports of its efficacy [2-6]. However, infliximab also damages TNF- $\alpha$ -producing macrophages, raising concerns about postoperative infection [14]. Soon after infliximab was launched, a drug holiday prior to surgery was recommended to deal with the perioperative period, and as the half-life of infliximab is 9.5 days, it was believed that surgery should ideally be performed after a drug holiday of two to three times this period (2-4 weeks) [15]. As coming off the drug worsened the primary disease in some patients, however, the possibility of performing surgery while continuing infliximab administration was explored.

As a result, the recommended timing for surgery is now during a gap of around 8 weeks after a break of at least 2 weeks after the last dose, in a regimen comprising administration every 8 weeks following a three-dose induction regimen (administered on a schedule of 0, 2, 4, and every 8 weeks), in order to avoid the early period of administration when the blood concentration is high (Figure 1).

**Post-operative infection of infliximab is not dose-dependent:** To date, there have fortunately been no reports of postoperative infection following surgery for complicated cataract due to Behçet's disease.

In rheumatoid arthritis, increasing the dosage of medication is being tried as one way of dealing with patients who do not respond to infliximab. The results of the RISING study and other trials of increased dosage [16-18] have shown that the frequency of infection due to infliximab is almost the same at doses of 3 mg/kg, 5 mg/kg, 6 mg/kg, and 10 mg/kg, indicating that side effects are not dose-dependent.

This suggests that, in terms of timing, surgery can be performed at any point during infliximab administration (5mg/kg) other than the induction period.

**Questions regarding cataract surgery with concomitant use of infliximab:** A number of questions remain to be resolved when performing surgery for complicated cataract due to Behçet's disease, including whether or not to administer infliximab prior to surgery in patients who are not already using it, whether infliximab can be

administered immediately should a flare-up occur even if it has not been given preoperatively, and if infliximab has already been administered, how long to continue its administration postoperatively.

## Case Report

### Case: 25-year-old man

**Previous medical and family history:** Nothing of note.

**History of current condition:** The patient was examined by a local physician on May 9, 2005, complaining of decreased visual acuity in the right eye for 1 week, and he was identified as suffering from uveitis. On May 10, 2005, he was referred to our hospital for investigation of the cause and treatment.

**Findings on initial examination:** Right visual acuity 0.08 (n.c.), left visual acuity 0.9 p ( $1.2 \times +0.75^D = \text{cyl} -1.0^D \times 600$ ), right intraocular pressure 9 mmHg, and left intraocular pressure 8 mmHg. Uveitis with hypopyon was evident in the right eye (Figure 2). Retinal hemorrhage and exudative lesions were also present in the right ocular fundus (Figure 3). There were no abnormalities in his left eye. In terms of extraocular symptoms, oral aphthous ulcers and erythema nodosum were present.

**Test findings:** Positive tuberculin test 13 mm x 10 mm ( $<10 \times 10$ ), elevated sedimentation rate 32 mm/1 h (1-7), peripheral leukocytosis  $9.9 \times 10^9/l$  ( $4-9 \times 10^9$ ), CRP positive 2.5 mg/dl ( $\leq 0.3$ ), HLA-A2601/02, HLA-A3101/02, HLA-B5101, and HLA-Cw1402/04/05. (Values in parentheses are normal values).

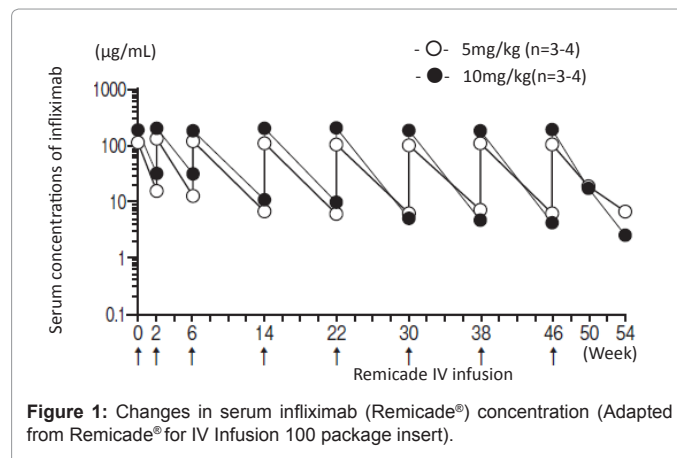
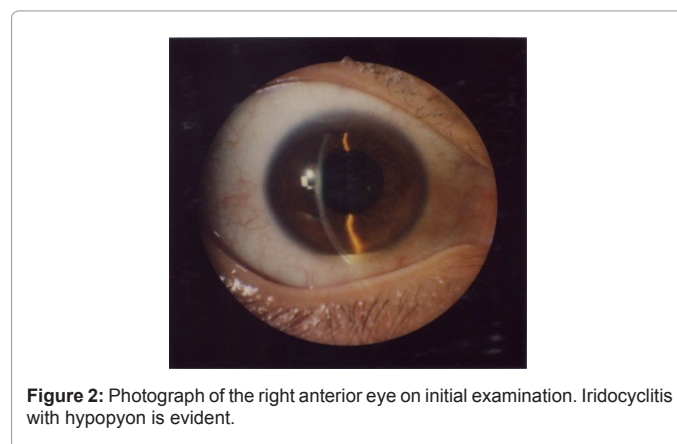


Figure 1: Changes in serum infliximab (Remicade®) concentration (Adapted from Remicade® for IV Infusion 100 package insert).



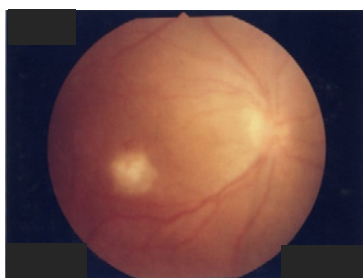## Course

The patient was diagnosed with panuveitis due to Behçet's disease, and colchicines therapy was initiated. Repeated attacks of ocular inflammation continued after colchicines administration, and liver dysfunction regarded as being due to colchicines was observed after 6 months. Cyclosporine A administration was withheld due to the decline in liver function, and the patient was switched to systemic corticosteroid administration Predonine® (Predonisorone Shionogi & CO, LTD, Japan; starting at 30 mg/day). As the steroid dosage was reduced, however, attacks of ocular inflammation occurred. The cataract in the right eye deteriorated, but cataract surgery was postponed due to the high uveitis activity (Figure 4). The patient was started on infliximab on March 28, 2007. Because the ocular inflammation had subsided, full informed consent for surgery was obtained, and the patient was admitted to hospital on July 18, 2007. On admission, right visual acuity was 0.06x +0.75<sup>D</sup> = cyl-0.75<sup>D</sup>A x 154° and flare was 29.8 ± 4.4 photon counts/ms. Cataract surgery (phacoemulsification and intraocular lens implantation) was performed on the right eye on July 19. The patient was discharged on July 23, and his condition was monitored as an outpatient. Right visual acuity 1week postoperatively had improved to 0.3x IOL (0.6x IOL = -1.25<sup>D</sup> = cyl-1.75<sup>D</sup>A x 1500). Flare was 38.8 ± 3.1 photon counts/ms. Right visual acuity 1year postoperatively was 0.1x IOL (0.7x IOL = -1.0<sup>D</sup> = cyl-1.75<sup>D</sup>A x 1500) and flare was 27.9 ± 1.5 photon counts/ms, with no flare-ups of ocular inflammation during follow-up (Figure 5, 6).

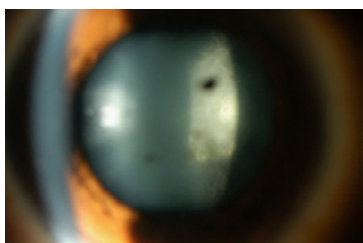
## Possible alternatives to infliximab

Steroids are sometimes administered systemically during the perioperative period, but their value has not been demonstrated [19].

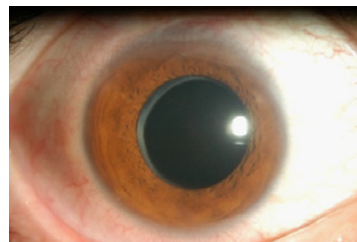
Although we ourselves have no experience of its use, it has been reported that concomitant use of IFN- $\alpha$  may enable the safe



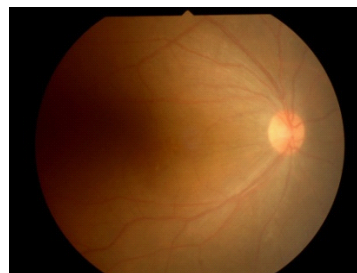
**Figure 3:** Photograph of the right ocular fundus on initial examination. Opacity of the vitreous body is evident, and hemorrhage and exudate are present in the fundus.



**Figure 4:** Preoperative photograph of the right anterior eye. The cataract has worsened, but surgery was postponed due to high uveitis activity.



**Figure 5:** Postoperative photograph of the right anterior eye. There is no flare-up.



**Figure 6:** Postoperative photograph of the right ocular fundus. There is no flare-up.

performance of surgery for complicated cataract due to Behçet's disease [20], and there are hopes for its future use as a new concomitant drug.

## Conclusion

In this paper, new developments in surgery for complicated cataract due to Behçet's disease have been described. Recently many people have been administrated for refractory chorio-retinitis due to Behçet's disease in Japan [21]. Infliximab is exceptionally effective, and opportunities for performing ocular surgery during its use are increased. Infliximab's mechanism of action, however, has led to concerns being raised about infections, such as postoperative endophthalmitis, and further investigation involving a greater number of patients is required. But we consider that the frequency of the side effects due to infliximab is as same as other immunosuppressants.

## References

1. Okinami S (2001) Surgical Treatments for complication of uveitis. *Folia Ophthalmol Jap* 52: 361-376.
2. Suzuki S, Senoo T (2008) A case of the patient who was undergone secondary cataract surgery while anti TNF- $\alpha$  therapy for Behçet's disease. *Folia Japonica Ophthalmologica Clinica* 1: 1168-1171.
3. Noda E, Yamanishi S, Shiraishi A, Ohashi Y (2009) Cataract surgery under infliximab therapy in a patient with Behçet's disease. *J Ocul Pharmacol Ther* 25: 467-470.
4. Sakai T, Kanetaka A, Noro T, Tsuneoka H (2010) Intraocular surgery in patients receiving infliximab therapy for Behçet's disease. *Jpn J Ophthalmol* 54: 360-361.
5. Handa T, Tsunekawa H, Zako M (2011) Cataract surgery in Behçet's disease patients one week after infliximab administration. *Case Report Ophthalmol* 2: 176-178.
6. Nishida T, Shibuya E, Asukata Y, Nakamura S, Ishihara M, et al. (2011) Clinical Course before and after Cataract and Glaucoma Surgery under Systemic Infliximab Therapy in Patient with Behçet's Disease. *Case Report Ophthalmol* 2: 189-192.
7. Hatemi G, Silman A, Bang D, Bodaghi B, Chamberlain AM, et al. (2008)

- EULAR recommendations for the management of Behçet disease. *Ann Rheum Dis* 67: 1656-1662.
8. Chung YM, Yeh TS (1990) Intraocular lens implantation following extracapsular cataract extraction in uveitis. *Ophthalmic Surg* 21: 272-276.
  9. Tanaka T, Minoda H, Kezuka T, Usui M (2000) Outcome of surgery for complicated cataract in Behçet's disease. *Jpn J Clin Ophthalmol* 54: 577-580.
  10. Hiraoka M, Fujino Y (1999) Cataract surgery and intraocular lens implantation in patients with Behçet's disease. *Nippon Ganka Gakkai Zasshi* 103: 119-123.
  11. Goda C, Kotake S, Sasamoto Y, Terayama A, Matsuda H (2000) Outcome of surgery for complicated cataract in Behçet's Disease. *Jpn J Clin Ophthalmol* 54: 1272-1276.
  12. Sfikakis PP, Theodossiadis PG, Katsiari CG, Kaklamanis P, Markomichelakis NN (2001) Effect of infliximab on sight-threatening panuveitis in Behçet's Disease. *Lancet* 358: 295-296.
  13. Accorinti M, Pirraglia MP, Paroli MP, Priori R, Conti F, et al. (2007) Infliximab treatment for ocular and extraocular manifestations of Behçet's disease. *Jpn J Ophthalmol* 51: 191-196.
  14. Giles JT, Bartlett SJ, Gelber AC, Nanda S, Fontaine K, et al. (2006) Tumor necrosis factor inhibitor therapy and risk of serious postoperative orthopedic infection in rheumatoid arthritis. *Arthritis Rheum* 55: 333-337.
  15. Ledingham J, Deighton C, British Society for Rheumatology Standards, Guidelines and Audit Working Group (2005) Update on the British Society for Rheumatology guidelines for prescribing TNF $\alpha$  blockers in adults with rheumatoid arthritis (update of previous guidelines of April 2001). *Rheumatology (Oxford)* 44: 157-163.
  16. Takeuchi T, Miyasaka N, Inoue K, Abe T, Koike T (2009) Impact of trough serum level on radiographic and clinical response to infliximab plus methotrexate in patients with rheumatoid arthritis: result from the RISING study. *Mod Rheumatol* 19: 478-487.
  17. Rahman MU, Strusberg I, Geusens P, Berman A, Yocum D, et al. (2007) Double-blinded infliximab dose escalation in patients with rheumatoid arthritis. *Ann Rheum Dis* 66: 1233-1238.
  18. Hanauer SB, Feagan BG, Lichtenstein GR, Mayer LF, Schreiber S, et al. (2002) Maintenance infliximab for Crohn's Disease: the ACCENT 1 randomised Trial. *Lancet* 359: 1541-1549.
  19. Mimura Y (1982) Treatment of ocular lesions in Behçet's Disease. University of Tokyo Press, Tokyo, 499-512.
  20. Krause L, Altenburg A, Bechrakis NE, Willerding G, Zouboulis CC, et al. (2007) Intraocular surgery under systemic interferon-alpha therapy in ocular Adamantiades-Behçet's disease. *Graefes Arch Clin Exp Ophthalmol* 245: 1617-1621.
  21. Ohno S, Nakamura S, Hori S, Shimakawa M, Kawashima H, et al. (2004) Efficacy, Safety, and Pharmacokinetics of Multiple Administration of Infliximab in Behçet's disease with Refractory Uveoretinitis. *J Rheumatol* 31: 1362-1368.

This article was originally published in a special issue, **Cataract** handled by Editor(s). Dr. Line Kessel, University of Copenhagen, Denmark