

Case Study: Inverted Diverticulum. Colonoscopy Evaluation Prior to Intervention

Mahmoud Elkaramany*

Hull Royal Infirmary, Hull, England, United Kingdom

*Corresponding author: Mahmood Elkaramany, Consultant Gastroenterology, Hull Royal Infirmary, 10 Pelham close, Hu178pn, Hull, England, United Kingdom, Tel: 7840469910; E-mail: mahmoud_aramany@yahoo.com

Received date: April 22, 2017; Accepted date: May 02, 2017; Published date: May 05, 2017

Copyright: © 2017 Elkaramany M. This is an open access article distributed under the terms of the Creative Commons Attribution License, which permits unrestricted use, distribution, and reproduction in any medium, provided the original author and source are credited.

Abstract

In spite of the rare incidence, inverted colon diverticulum can be misinterpreted and may result in perforation when biopsied or endoscopically removed. Such iatrogenic perforation can be avoided by simple maneuvers. Endoscopic air in insufflation can simply detect inverted colon diverticulum and save the risk of perforation. Our case study represents an old lady scheduled for colonoscopy for advanced evaluation of ambiguous abdominal pain and constipation. A polyp was discovered in the sigmoid colon. By air insufflation, the inverted colon diverticulum was detected and further procedures were ceased.

Keywords: Diverticulum; Diverticulitis; Colon; Endoscopy; Colonoscopy

Introduction

Diverticular disease (DD) is a very common colon disorder in the Western community [1]. When colonoscopy is necessary for evaluation of abdominal symptoms, it may show adenomatous polyps associated with diverticular disease. Endoscopic polypectomy has been estimated to be responsible for around 50% of perforation during the procedure [2]. The estimated incidence has been less than 0.05% [3] of the total cases of perforation. The latter percentage is subject to increase in case of inverted colon diverticulum (ICD) that can be mistaken for the colon polyp lesion [4].

Hereafter, a case presentation of an old woman who was scheduled for colonoscopy for evaluation of abdominal symptoms. A pedunculated polyp had been discovered and proved to be ICD. Therefore, the procedure had been held short of polypectomy.

Case Presentation

Subjective data

A 67-years-old lady was presented to internal medicine clinic with abdominal pain, mostly on the left side accompanied by constipation. She received medications for two months with no significant response. The patient was referred to the gastroenterology clinic for evaluation and consideration of endoscopic evaluation when appropriate.

Objective data

Thorough physical examination and routine laboratory tests showed no significant abnormality. Echocardiogram study revealed concentric hypertrophy of the left ventricle consistent with essential hypertension.

Colonoscopy procedure

Colonoscopy evaluation of the colon was scheduled. The patient bowel was prepared by lavage with four liters of polyethylene glycol [1]. The colon was examined fully. Examination visualized a 0.6 cm polypoid lesion in the sigmoid colon. The external appearance showed shiny pink mucosa covering like that of the colon. So trying endoscopic air insufflation was attempted near the lesion for about 2 min to 3 min and the response of the polyp was registered. It was noted that the polyp reduced in size with the effect of air insufflation and the reduction was proportionate to the degree of air insufflation (Figures 1 and 2). These criteria were in favour of ICD. Therefore, attempts to perform polypectomy were cancelled.

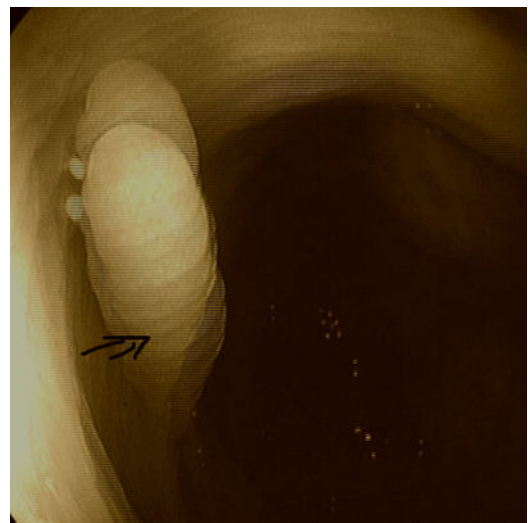


Figure 1: Inverted colon diverticulum before air insufflation.

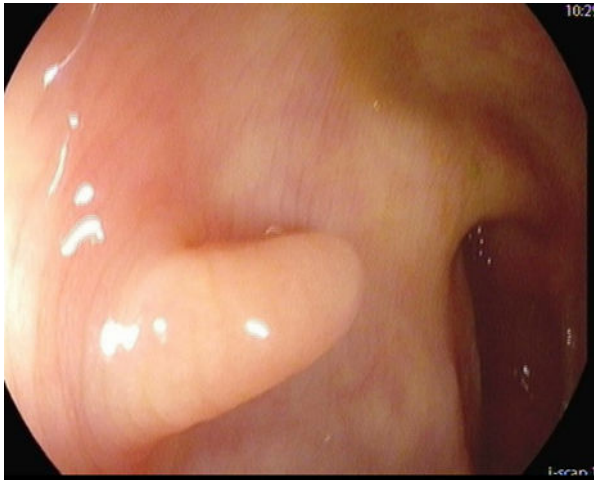


Figure 2: The diverticulum after gradual air insufflation.

Discussion

Diagnosis of ICD implies considerable difficulty and serious adversity. The rarity of the condition participates in the awkwardness of the condition. The literature reported nearly twenty cases; six of which were radiologically diagnosed, five were endoscopically diagnosed, and eight were histopathologically diagnosed following either surgery or endoscopic polypectomy [5]. The problem becomes more complicated when the polyp is large resembling a pedunculated polyp. Bowel perforation is the serious adversity that is elicited when endoscopic polypectomy is attempted with the electrosurgical snare. That is why awareness of the problem should be in mind before performing an endoscopic intervention.

Conclusion

Diagnosis of ICD can be successfully achieved by several methods. It is of value to attempt to induce eversion of ICD using endoscopic air

insufflation [5]; as we performed in our case or during radiological evaluation [6]. It is suggested to probe the lesion gently with biopsy forceps and attempt to push it outside the colon [7]. However, large polyps give false results necessitating considering biopsy specimens to diagnose the lesion histopathologically. Biopsy of such ambiguous polyps should be performed with caution to avoid viscous preformation [4]. Recently, Aurora rings are speculated to be of diagnostic value in recognizing ICD. They are series of concentric pale rings surrounding the lesion that are enhanced with narrow band imaging (NBI) and indigo carmine dye [8].

References

1. Etzioni D, Mack T, Beart R, Kaiser A (2009) Diverticulitis in the United States: 1998-2005: Changing patterns of disease and treatment. *Ann Surg* 249: 210-217.
2. Korman L, Overholt B, Box T, Winker C (2003) Perforation during colonoscopy in endoscopic ambulatory surgical centers. *Gastrointest Endosc* 58: 554-557.
3. Tulchinsky H (2006) Incidence and management of colonoscopic perforations: 8 years' experience. *World J Gastroenterol* 12: 4211-4213.
4. Paoluzi O, Tosti C, Andrei F, Stroppa I, Pallone F (2010) Look out before polypectomy in patients with diverticular disease – A case of a large, inverted diverticulum of the colon resembling a pedunculated polyp. *Can J Gastroenterol* 24: 61-63.
5. Warner E, Crighton E, Moineddin R, Mamdani M, Upshur R (2007) Fourteen-year study of hospital admissions for diverticular disease in Ontario. *Can J Gastroenterol* 21: 97-99.
6. Yusuf S, Grant C (2000) Inverted colonic diverticulum: a rare finding in a common condition? *Gastrointest Endosc* 52: 111-115.
7. Lefere P, Gryspeerdt S (2011) CT colonography: Avoiding traps and pitfalls. *Insights Imaging* 2: 57-68.
8. Tarik Adioui H (2014) Inverted colonic diverticulum. *Ann Gastroenterol* 27: 411.
9. Share M, Avila A, Dry S, Share E (2013) Aurora rings: A novel endoscopic finding to distinguish inverted colonic diverticula from colon polyps. *Gastrointest Endosc* 77: 308-312.