

Cameron Lesions: Keep in Mind in Chronic Anemia

Hernandez GH^{1*}, Soto ICF¹ and Garcia CAJ²

¹Medical Endoscopy Service of Hospital Regional de Toluca, ISSEMyM, Mexico

²Surgical Coordinator of Hospital Regional de Toluca, ISSEMyM, Mexico

*Corresponding author: Guillermo Hernandez Hernandez, Medical Resident Gastrointestinal Endoscopy Service, Medical Institute of Social Security of the State of Mexico and Municipalities (ISSEMyM), Toluca de Lerdo, Mexico; Tel: 01 52 7223687921; E-mail: winspang@hotmail.com

Received date: April 5, 2016; Accepted date: May 11, 2016; Published date: May 18, 2016

Copyright: © 2016 Hernandez GH, et al. This is an open-access article distributed under the terms of the Creative Commons Attribution License, which permits unrestricted use, distribution, and reproduction in any medium, provided the original author and source are credited.

Abstract

Cameron lesions was first described by Cameron and Higgins in 1986 as a linear gastric erosion located impingement height diaphragm or proximal to this generally occurs in the lesser curvature of the stomach is associated with the presence of hiatal hernia which is present in 0.8 to 2.9 % of all patients who undergo upper endoscopy both erosions and ulcers are two entities that are part of the same disease. The main manifestation is the presence of chronic or the presence of iron deficiency anemia acute bleeding and/or. Medical treatment should be based on inhibition of acid secretion and refractory cases should go to surgery.

Keywords: Cameron Lesions; Anemia; Hiatal Hernia.

Clinical Case

A 65 year-old male hypertensive treated with amlodipine, surgical history of appendectomy, occasional alcohol intake, denies any other history relevant to current condition.

His current condition is initiated two years ago with the presence of upper gastrointestinal bleeding it manifested by melena at that time he underwent to upper endoscopy where found hiatal hernia however without showing the site of bleeding he was discharged on this occasion.

Two years later he was admitted in our hospital with hemoglobin 11.4 grs/dl and epigastric pain is performed upper endoscopy finding sliding hiatal hernia of 7 cm. and into the hernia sac ulcer of 10 mm. located in lesser curvature of the stomach with clean base and covered by fibrin, endoscopic finding did not require any endoscopic therapy and the patient is currently received medical treatment based Proton Pump Inhibitor (PPI).

Literature Review

Cameron and Higgins in 1986 first described the today called "Cameron Lesions" which it was described as linear gastric erosions located at the edges of the mucosal folds located near or at the diaphragm [1]. The sliding hiatal hernia as a sine qua non condition for the presence of "Cameron lesion" occurs when the gastroesophageal junction or part stomach moves above the diaphragm clamping.

The cause of hiatal hernia is unknown its frequency of hiatal hernia increases with age being a frequent finding in the elderly it is usually asymptomatic but commonly associated with the presence of gastroesophageal reflux disease. Complications of hiatal hernia are iron deficiency anemia, bleeding acute or chronic with or without the presence of erosions and/or ulcers.

Other complications include mucosal prolapse, gastric volvulus, incarceration and short esophagus [2]. The prevalence of hiatal hernia is 0.8-2.9% of all patients who undergo to upper endoscopy (Figure 1) [3].

The term "Cameron lesions" is used to erosions and ulcers located at the diaphragm or proximal to this, the lesions are usually found in the lesser curvature of the stomach. Cameron lesions are found in 5% of the patients known with hiatal hernia who undergo to upper endoscopy [3]. The size of the hiatal hernia has a proportional relationship to the risk of lesion because in hernias larger than 5cm the prevalence is 10-20%. Both erosions and ulcers are two entities that form part of the same disease, called Cameron lesions [4].

The pathophysiology of Cameron lesions is not entirely clear, but its formation is due to a mechanical trauma caused by ventilatory movements of diaphragm muscle, other etiologies include acid reflux, ischemia, and infection by *Helicobacter pylori*, gastric stasis and vascularstasis. Ischemia as a causal factor was described by Mozkowitz et al. who they found through biopsy histopathologic findings consistent focal ischemic gastropathy in coagulative necrosis [5].

The role of *Helicobacter pylori* infection in formation of Cameron lesions has been studied by Weston who in a group of patients with Cameron lesions took biopsies in search of bacteria, a total of 28 patients They found that *Helicobacter pylori* infection was present only in 9 patients (32%) [6].

The most common clinical manifestation is the presence of gastrointestinal bleeding, chronic bleeding will be manifested as iron deficiency anemia, acute bleeding manifested by hematemesis, vomiting coffee grounds and/or melena.

In patients with obscure gastrointestinal bleeding, Cameron lesions should be borne in mind as a possible diagnostic. Occasionally it is not discovered at first endoscopy, however the "second look" or during pulsion enteroscopy is discovered. The role of the capsule endoscopic diagnosis of the Cameron lesions has not yet been defined (Figure 2) [4].

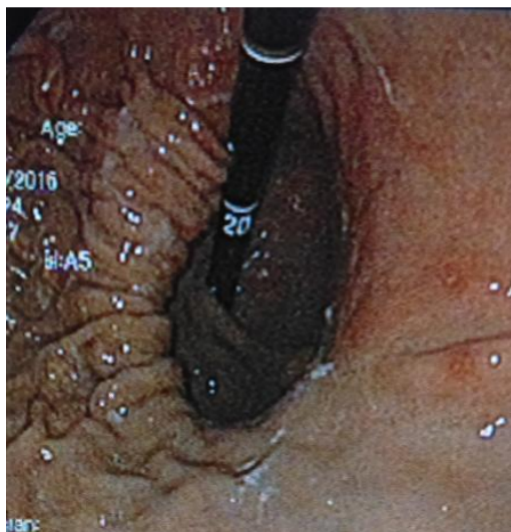


Figure 1: Hiatal hernia view retro vision.

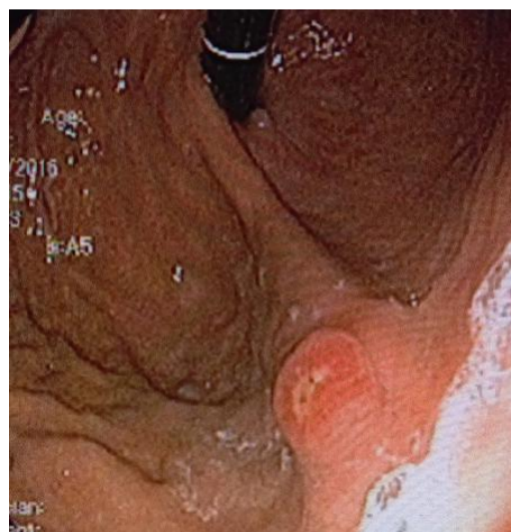

Figure 2: Cameron lesions, into the hiatal hernia.

The treatment is divided into medical and surgical, however it is recommended that first line therapy should be with PPI and prokinetics, surgery should be reserved for refractory cases. The therapy supplementary oral iron is made in cases presenting with concomitant anemia. The most Cameron lesions patients will have disease problems associated with gastroesophageal reflux disease, esophagitis and peptic ulcer. So they already have inhibitor therapy acid secretion, however in these circumstances should be intensified therapy for healing of these lesions. Surgical treatment, as mentioned above, it is reserved for refractory cases to medical treatment, massive

bleeding, volvulus, incarceration, perforation and consists in performing laparoscopic fundoplication surgery or through open [3].

Endoscopic treatment of acute bleeding from an Cameron lesions is it recommended with dual therapy, that should be made with an injection method more thermal method contact (heat probes) or contact (argon plasma, Lasser YAG) must be therapeutics elección [7].

Discussion

The pathophysiology of Cameron lesions is still not well understood; there some predisposing factors such as mechanical trauma of the diaphragmatic impingement, hiatal hernia, focused ischemia, vascular stasis and even relationship with infection *Helicobacter pylori*, however all these theories are inconclusive, but we can ensure multifactorial etiology. The prevalence of this lesion is well related presence of hiatal hernia, and it is presentation has a direct relationship to hernia size being up to 20% for greater than 5 cm. It is an entity understudied and upper endoscopy studies cannot be seen, it is clinical manifestations can be varied from mild iron deficiency anemia to massive hematemesis that can represent a challenge for the endoscopist and his work team, in the case presented above the patient had presented hematemesis two years before the identification of Cameron lesions, at that time did not identify the origin of bleeding and the patient continues with microscopic bleeding that conditioned iron deficiency anemia. We must keep in mind the presence of this lesion in patient with obscure gastrointestinal bleeding overt and occult, this could bring significant benefits for patient care in regarding costs, number of procedures and even hospital stay, avoiding continue the protocol study with capsule endoscopy, deep enteroscopy and colonoscopy. The PPI are the first line of therapy, usually with appropriate response, in cases non-responders to PPI should go to laparoscopic or open fundoplication to remove the trigger, the hiatal hernia.

Conflict of Interests

The authors have no conflict of interest in this work.

References

1. Cameron AJ, Higgins JA (1986) Linear gastric erosion. A lesion associated with large diaphragmatic hernia and chronic blood loss anemia. *Gastroenterology* 91: 338-342.
2. (2010) Sleisenger & Fordtran's *Gastrointestinal and Liver Disease* (9th edn.) Philadelphia, Saunders, Elsevier pp: 381-383.
3. Kishore M, Richard L (2008) Cameron Lesions: Unusual Cause of Gastrointestinal Bleeding and Anemia. *Digestion* 77: 214-217.
4. Samir K, Sophia J, Atul K (2012) Cameron ulcers: An atypical source for a massive upper gastrointestinal bleed. *World J Gastroenterology* 18: 4959-4961
5. Moskovitz M, Fadden R, Min T, Jansma D, Gavaler J (1992) Large hiatal hernias, anemia, and linear gastric erosion: studies of etiology and medical therapy. *Am J Gastroenterology* 87: 622-626.
6. Weston AP (1996) Hiatal hernia with Cameron ulcers and erosions. *Gastrointest Endoscopy Clin N Am* 6: 671-679.
7. Ian M, Gralnek M (2014) Gastrointestinal bleeding. *Gastroint Endoscopy* 80: 392-395.