

## Bullous Erythrodermic Mycosis Fungoides: A Case Report

Naciri Ilhame<sup>1\*</sup>, Ebongo Christelle<sup>1</sup>, Askour Majda<sup>1</sup>, Rimani Mouna<sup>2</sup>, Meziane Mariam<sup>1</sup>, Senouci Karima<sup>1</sup> and Hassam Badredine<sup>1</sup>

<sup>1</sup>Department of Dermatology-Venereology, Ibn Sina University Hospital, Mohammed V University, Rabat, Morocco

<sup>2</sup>Department of General Surgery A, Ibn Sina University Hospital, Mohammed V University, Rabat, Morocco

\*Corresponding author: Naciri Ilhame, Department of Dermatology-Venereology, Ibn Sina University Hospital, Mohammed V University, Rabat, Morocco, Tel: +212-645-30-70-37; E-mail: ilhamenaciri@hotmail.com

Received date: February 02, 2017; Accepted date: March 29, 2017; Published date: April 07, 2017

Copyright: © 2017 Ilhame N, et al. This is an open-access article distributed under the terms of the Creative Commons Attribution License, which permits unrestricted use, distribution, and reproduction in any medium, provided the original author and source are credited.

### Abstract

Bullous mycosis fungoides is a rare entity of cutaneous T-cell lymphomas; however, it can be particularly aggressive with an unfavorable prognosis. Mechanism of formation of bullous lesions in bullous lymphoma remains poorly understood, it can be explained by excessive epidermotropism or tumor infiltration's toxicity. We report the case of a bullous erythrodermic mycosis fungoides.

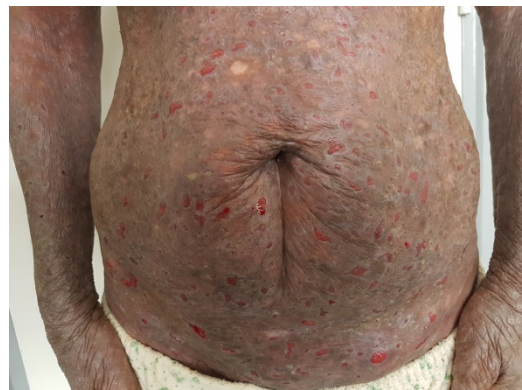**Keywords:** Cutaneous lymphoma; Mycosis fungoides; Erythroderma; Blisters; Rare

### Introduction

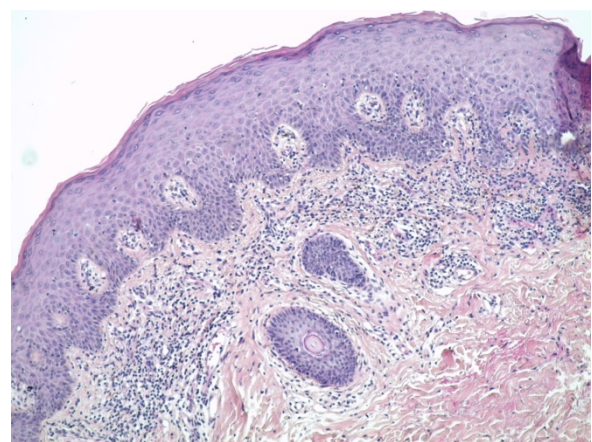
Bullous mycosis fungoides (MF) is a rare entity with only about 20 cases reported in literature [1]. However, it is particularly aggressive with poor prognosis [2]. We report a case of bullous erythrodermic MF.

### Clinical Case

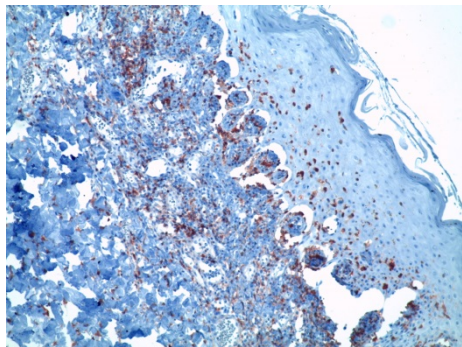
A 52-years-old woman with no significant pathological past history presenting for 3 years multiple erythematous-squamous and pruritic plaques of the trunk, aggravated 3 months ago by the progressive installation of diffuse bullous and erosive lesions. This evolving without fever nor alteration of general condition. Clinical examination showed a dry erythroderma, with post-bullous erosions of the trunk and limbs (Figure 1), Nikolsky sign was negative. Bilateral firm and painless inguinal lymphadenopathies were also found, the largest one was of 2 cm. Skin biopsy showed an epidermal cleavage without visible acantolysis, associated to an epidermotropism, a dense and a pilotropism (Figure 2). The infiltrate was made of atypical lymphocytes, mainly expressing anti-CD4 (Figure 3), and anti-CD3 antibodies (Figure 4), and lacking anti-CD8 (Figure 5), anti-CD20, and anti-CD30 antibodies. Direct immunofluorescence was negative. Hemogramme, hepatic and renal assessment, blood levels of beta2microglobulin and LDH were normal. There was less than 5% of circulating Sezary cells and screening for atypical lymphocytes in the peripheral lymph nodes and the bone marrow was negative. Thoraco-abdomino-pelvic tomodensitometry was normal. The diagnosis of stage III (T4N1B0M0) bullous erythrodermic MF was retained and the patient treated by 25 mg/week methotrexate, with a slight improvement, marked by the disappearance of erosive lesions after three months of treatment. But a relapse occurred after 8 months, then we switched for the association of PUVA-therapy (at the rate of 3 sessions per week) and acitretin 1 mg/kg/day. The outcome was favorable, with a 6-month decline.



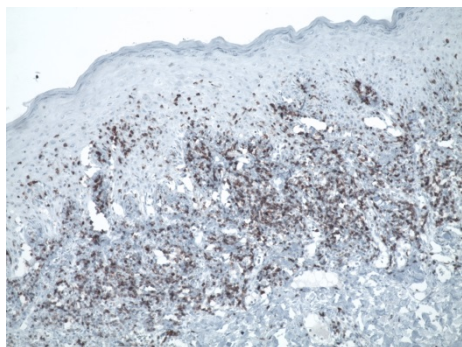
**Figure 1:** Dry Erythroderma with diffuse post bullous erosions on the trunk and limbs.



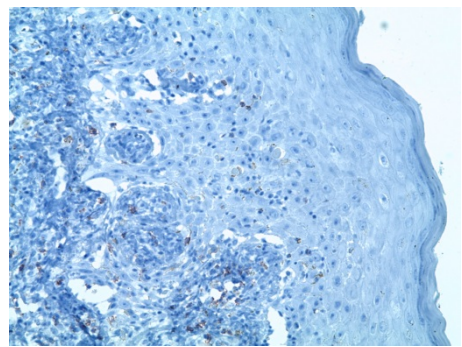
**Figure 2:** Cutaneous histology (HES, G x 100), dermal lymphoid infiltrate with epidermotropism and pilotropism.



**Figure 3:** Immunohistochemistry (G x 100), dermal and epidermotropic lymphocytes labeled with anti-CD4 antibodies, with an under epidermis detachment.



**Figure 4:** Immunohistochemistry (G x 100), dermal and epidermotropic lymphocytes labeled with anti-CD3 antibodies.



**Figure 5:** Immunohistochemistry (G x 200), dermal and epidermotropic lymphocytes predominantly CD8.

## Comments

MF is the most frequent subtype of cutaneous T-cell lymphomas, however bullous lesions remain extremely rare. The first case of bullous MF was described by Kaposi in 1887 as pemphigus-like mycosis fungoides [3]. Bullous MF usually occurs in the elderly, without sex predominance. Bullous lesions usually appear several months or years after the classic MF plaques, but in some cases they may be inaugural, making the diagnosis very difficult [4]. Bowman et al. proposed criteria for the diagnosis of bullous MF, including the presence of clinical blisters, pathognomonic histological signs of MF, immunofluorescence negativity and exclusion of other bullous dermatoses [2]. The exact mechanism of blisters formation in bullous MF remains poorly understood. Several hypotheses have been suggested: the direct or indirect degeneration of dermic collagen fibers induced by neoplastic cells [5]. Tumor's infiltration toxicity, the release of certain lymphokines, and their interference with the normal cohesion of Keratinocytes [6], and a direct mechanical effect of the accumulation of lymphocytes between epidermic cells of the basal layer in the event of excessive epidermotropism, leading to loss of coherence between adjacent cells [7]. The presence of a massive tumoral infiltrate in our patient suggests that the third mechanism may play important role in our case.

## Conclusion

Although mycosis fungoides bullosa is extremely rare, however, it can be particularly aggressive and associated with a poor prognosis. It has to be regarded as an important clinical subtype of cutaneous T-cell lymphoma.

## References

1. Kneitz H, Bröcker EB, Becker JC (2010) Mycosis fungoides bullosa: a case report and review of the literature. *J Med Case Rep* 4: 78.
2. Bowman PH, Hogan DJ, Sanusi ID (2001) Mycosis fungoides bullosa: report of a case and review of the literature. *J Am Acad Dermatol* 45: 934-939.
3. Kaposi M (1887) "Mycosis fungoides" und ihre beziehungen zu anderen ähnlichen erkrankungsformen. *Wien Med Wochenschr* 19: 22-37.
4. McBride SR, Dahl MG, Slater DN, Sviland L (1998) Vesicular mycosis fungoides. *Br J Dermatol* 138: 141-144.
5. Ueda C, Makino T, Asano Y, Watanabe H, Hanakawa H, et al. (2011) An ultrastructural examination of a blistering lesion of mycosis fungoides bullosa. *Br J Dermatol* 165: 213-214.
6. Kartsonis J, Brettschneider F, Weissmann A, Rosen L (1990) Mycosis fungoides bullosa. *Am J Dermatopathol* 12: 76-80.
7. Konrad K (1979) Mycosis fungoides bullosa. *Lymphoproliferative Diseases of the Skin* (Christophers E, Goos M, eds). New York, NY: Springer-Verlag, 157-162.