

Bradycardia and Hypotension after Consumption of Wild Honey: Case Reports of Two Patients from the Eastern Nepal

Shah B*, Ojha I, Pandey K, Bhandari A, Dahal P and Dahal K

BP Koirala Institute of Health Sciences, Dharan, Nepal

*Corresponding author: Bhupendra Shah, Assistant Professor of Internal Medicine, BP Koirala Institute of Health Sciences, Dharan, Nepal, Tel: 765-409-4813; E-mail: doctorbhupen@gmail.com

Received date: July 21, 2017; Accepted date: August 14, 2017; Published date: August 21, 2017

Copyright: © 2017 Shah B, et al. This is an open-access article distributed under the terms of the Creative Commons Attribution License, which permits unrestricted use, distribution, and reproduction in any medium, provided the original author and source are credited.

Abstract

Wild honey consumption as an alternative medicine for acid peptic disease, musculoskeletal pain, depression and decreased libido is still common practice in different parts of the world. Honey made from the nectar of certain species of rhododendron may contain grayanotoxin which can cause adverse cardiovascular and gastrointestinal events. We report case history of two patients who consumed wild honey as a mood elevator and for acid peptic disease respectively and later presented to the emergency room of B.P. Koirala Institute of health sciences in eastern Nepal with gastrointestinal symptoms and near the fatal cardiac event. Both of them recovered with symptomatic treatment. However, the chemical analysis of mad honey couldn't be done due lack of facilities at B.P. Koirala Institute of health sciences.

Keywords: Wild honey; Grayanotoxin; Cardiac event; Nepal

Introduction

Honey is a common breakfast item worldwide. It is added to beverages as a sweetener. In Nepal, there are additional uses of wild honey [1]. It is taken as an alternative medicine for the treatment of gastritis, coronary artery disease, musculoskeletal pain, decreased libido and depression [2].

Honey poisoning is caused by the consumption of wild honey (mad honey) made by bees from certain species of rhododendron [2]. Grayanotoxin is a naturally occurring sodium channel toxin found in honey made by bees from the pollen and nectar of the *Ericaceae* family of the *Rhododendron* genus [3]. Honey containing Grayanotoxin called 'mad honey', can cause dramatic effects when ingested. Mad honey ingestion can cause nausea, vomiting and various adverse cardiac effects [4]. Shrestha et al. [5] reported from central Nepal that wild honey consumption causes nausea, vomiting, and cardiac depression. Chen et al. [6] from Hong Kong reported that consumption of 30 ml of mad honey causes the hypotension, bradycardia and diffuse ST elevation in electrocardiogram mimicking the acute myocardial infarction [6]. Here, we report about two cases of wild honey poisoning in which patients presented with cardiovascular and gastrointestinal symptoms and subsequently recovered with symptomatic management. The written informed consent was taken from the patients for case reporting and both the patients received standard care of treatment.

Case One

A 53-year-old patient from Dharan presented to the emergency department of B.P. Koirala Institute of health sciences with a history of multiple episodes of projectile vomiting, generalized body weakness and burning sensation of the whole body after ingestion of 8-10 ml of wild honey purchased from Sungdel, Khotang in the hilly region of Nepal. The patient developed the symptoms after 15 min of ingestion

of honey. The patient had consumed the honey to elevate the mood. The patient had a history of low mood after the son succumbed to death in a road traffic accident seven months back. The patient's relative in Khotang district had similar symptoms of nausea and vomiting after consuming a similar type of honey and was admitted to the local hospital.

In the emergency room, the patient was feeble and had a pulse of 42 beats per minute, Blood pressure of 60/20 mmHg, and respiratory rate of 24 breath/min. The patient's sensorium was normal. Systemic examination including cardiovascular findings was normal.

On investigation, Electrocardiogram showed sinus bradycardia with a rate of 42 beats per minute without conduction disturbances (Figure 1). Blood leukocyte counts, serum cardiac enzymes, arterial blood gas and other metabolic parameters were normal. The patient was treated with Injection Atropine 0.6 mg intravenous route (single dose) and with intravenous fluids. 15 hrs after admission, the patient's blood pressure was 130/90, pulse was 70 beat per minute and respiratory rate was 18 cycle per minute. The Electrocardiogram showed normal sinus rhythm. On day three of admission, we did a psychiatry consultation for low mood. The patient was diagnosed as a dysthymia and was prescribed an antidepressant. Four days after admission, we discharged the patient from the hospital.

Case Two

A 67-year old patient from the mountain region of eastern Nepal presented to emergency room with complaints of multiple episodes of projectile vomiting, dizziness and tingling sensation of the whole body. The patient developed the symptoms within 1 hr of ingestion of about 15 ml of wild honey brought from the Taplejung. The patient's sister had symptoms of loose stool and vomiting after ingestion of same honey which improved at home without taking any medication.

The patient had a pulse rate of 52 beats per minute, respiratory rate was 26 breath per minute and blood pressure was 140/90 mmHg. She had normal body temperature. The electrocardiogram of the patient

showed sinus bradycardia of 54 per minute. The routine hematological and biochemical parameters were within normal limits.

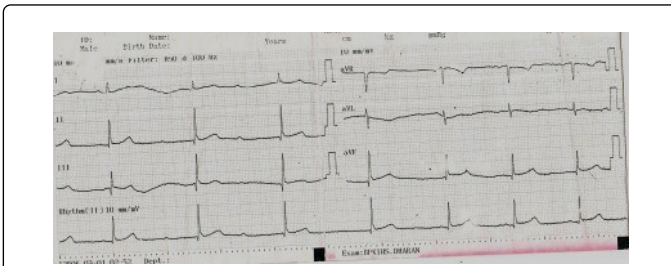


Figure 1: Electrocardiogram of Case One after consumption of wild honey showing Sinus bradycardia of heart rate 42/min at Emergency room.

The patient was admitted to the department of Internal Medicine of B.P. Koirala Institute of Health Sciences and kept 24 hrs cardiac monitoring. She was given intravenous fluid (0.9% Normal saline) and anti-emetics. The patient was asymptomatic and heart rate normalizes after 40 hrs of hospital admission. The patient was discharged on day third of admission.

Discussion

We report two cases of wild honey poisoning. The first patient after consuming a wild honey as mood elevator have near fatal cardiac adverse events later recovered with a single dose of atropine and IV fluids within a 24 hrs hospital admission. The second patient consumed wild honey for acid peptic disease, which had sinus bradycardia later recovered spontaneously. Wild honey contains Grayanotoxin which prevents the inactivation of sodium channel leading to membrane hyperpolarization which leads to sinus bradycardia and conduction block in the heart [7].

Similar to clinical symptoms in our case reports, Shrestha and Paudel [8] reported in their case report that mad honey poisoning causes dizziness, vomiting, and sinus bradycardia. The toxic effects of wild honey poisoning are rarely fatal and usually last for no more than 24 hrs. Generally, they induce dizziness, weakness, perspiration, salivation, nausea, vomiting, hypotension, bradycardia, atrioventricular block, and syncope [2]. Symptoms may come on as quickly as within 10 min and be delayed as long as 4 hrs. Grayanotoxin poisoning generally responds well to atropine and supportive therapy and generally resolves in 24 h without complication. But in patients with decreased coronary reserve, patients on anti-ischemic medications, and patients on antihypertensive therapies, additional monitoring is warranted, and these patients should be followed until clinical condition completely resolves [9].

There is no literature on Grayanotoxin containing *Rhododendron* species yet available in Nepal [10]. These case reports highlight the urgent need of study of rhododendron species and identifying the Grayanotoxin containing species.

Strength: There were case reports on mad honey poisoning from central Nepal. As far as author's knowledge: This is first case reports of mad honey poisoning from Eastern Nepal which highlight the need for knowledge dissemination among the population of Eastern Nepal regarding the toxic effects of mad honey consumption.

Limitation: Though we believe the wild honey consumed by our patient contain Grayanotoxin, We could not identify the exact chemical composition due to lack of facilities of chemical analyses.

Conclusion

Wild honey consumption is still a prevalent practice in hilly and mountain region of Nepal. It has high demand in Nepali market. Some wild honey brought from Himalayan areas like Taplejung, kotang of Eastern Nepal may contain grayanotoxin and lead to vomiting, dizziness, tingling sensation, bradycardia, and hypotension as in the reported patients. Hence, Grayanotoxin containing honey consumption should be discouraged and message should be disseminated by concerned stakeholder to the population of Eastern Nepal as soon as possible.

Acknowledgment

We acknowledge our patient and her attendant for participating in this case report.

References

1. Jauhari AC, Johorey AC, Banerjee I, Shrestha P, Singhal KC (2009) Nearly fatal wild honey intoxication a case report of seven cases. J Clin Diagn Res 3: 1685-1689.
2. Dubey L, Maskey A, Regmi S (2009) Bradycardia and severe hypotension caused by wild honey poisoning. HJC 50: 426-428.
3. Gunduz A, Turedi S, Russell RM, Ayaz FA, (2008) Clinical review of grayanotoxin/mad honey poisoning past and present. Clin Toxicol 46: 437-442.
4. Jansen SA, Kleerekooper I, Hofman ZL, Kappen IF, Stary-Weinzinger A, et al. (2012) Grayanotoxin poisoning: Mad honey disease and beyond. Cardiovasc Toxicol pp: 208-215.
5. Shrestha P, Vaidya R, Sherpa K (2009) Mad honey poisoning: a rare case report of seven cases. Nepal Med Coll J 11: 212-213.
6. Chen S, Lam Y, Ng V, Lau F, Sze Y, et al. (2013) Mad honey poisoning mimicking acute myocardial infarction. Hong kong Med J 19: 354-356.
7. Gami R, Dhakal P (2017) Mad honey poisoning: A review. Journal of Clinical & Experimental Dermatology Research 7: 15.
8. Shrestha B, Paudel P (2015) A case report on mad (wild) honey intoxication. J Chitwan Med Coll 5: 40.
9. Okuyan E, Uslu A, Levent MO (2010) Cardiac effects of "mad honey": a case series.
10. Cheng PG, Shyi-Kuenb W, Wang H (2015) Case report: Lateral capsular release for acute extension deficit in a child with congenital radioulnar synostosis. J Pediatr Orthop B 24: 71-74.