

Bertolotti Syndrome: Prevalence, Classification and Current Concepts of Management: A Review

Nilesh Barwar*

AIIMS, Jodhpur, Rajasthan, India

*Corresponding author: Dr. Nilesh Barwar, MS (orthopedics) AIIMS, Jodhpur, Rajasthan, India, E-mail: nileshbarwar123@gmail.com

Received date: December 07, 2018; Accepted date: January 02, 2018; Published date: January 09, 2019

Copyright: © 2019 Barwar N. This is an open-access article distributed under the terms of the Creative Commons Attribution License; which permits unrestricted use; distribution; and reproduction in any medium; provided the original author and source are credited.

Abstract

Bertolotti's Syndrome (BS) or Lumbosacral Transitional Vertebra (LSTV) is the most common congenital malformation of the lumbosacral junction. It encompasses from sacralization of L5 to lumbarization of S1. The prevalence ranges from 5% to 15% in different population base. Adolescents and middle-aged people are commonly affected. Clinical spectrum can range from asymptomatic individual to a constant low Backache (LBA) with or without radicular pain in buttocks or legs. Currently, there is no consensus about its association with low back pain and its subsequent management. We thoroughly evaluated all prominent literature regarding its diagnostic methods, classification, and subsequent management.

Keywords: Bertolotti's syndrome; Lumbosacral transitional vertebra; Sacralisation; Lumbarisation

Introduction

Bertolotti's syndrome or lumbosacral transitional vertebra syndrome is a common cause of lower back pain, especially in the younger population. Since its identification by bertolotti in 1917, it has been a constant topic of debate regarding its association with a low backache and its subsequent management [1]. Being the most common congenital abnormality of the LS junction, symptomatology extends from asymptomatic incidental finding to a constant source of a low backache in adolescent to middle-aged population. Morphological changes in the L5 and/or S1 vertebrae lead to abnormal biomechanics and kinematics at LS junction that results in decrease motion at the involved parts with consequently increased mobility and stress at an adjacent segment of the spine. The problem ranges from the enlarged transverse process of a fifth lumbar vertebra, pseudo-arthritis between the enlarged transverse process and sacral ala and/or ilium, and complete fusion, to lumbarization of the first sacral vertebral body. As it involves a younger population, a constant LBA can cause psychosocial frustration, work inefficiency and loss of productive and economic activity. Presently, there is no consensus regarding its diagnostic methods and subsequent management.

Anatomical Changes and Pathology

In Lumbosacral Transitional Vertebra Syndrome (LSTV) either the last lumbar vertebra (L5) acquires varying degrees of articulation to the sacrum and/or to the ilium (sacralization) or the first sacral segment (S1) is separated from the sacrum with the transition to a lumbar configuration (lumbarization). A sacralization is a congenital anomalous enlargement of transverse processes of the most caudal lumbar vertebra with subsequent neo-articulation or fusion to the sacrum. Mario Bertolotti in 1917 first identified and termed it as bertolotti's syndrome. He stated that LSTV might cause low back pain due to arthritic changes at the pseudo-arthritis site. Further, radiographically classified it into four types [2] (Figure 1). A type first

comprises unilateral (Ia) or bilateral (Ib) dysplastic transverse processes, measuring at least 19mm of height in the vertical dimension. A type 2 involves unilateral (IIa, Figure 2) or bilateral (IIb) lumbarization/sacralization with the formation of a diarthrodial joint between the overgrown transverse process and sacral ala. A type 3 exhibits unilateral (IIIa) or bilateral (IIIb, Figures 3 and 4) fusion of enlarged transverse processes to sacral ala and/or ilium. Type IV involves a unilateral type II transition with a type III on the contralateral side. O' Driscoll et al., [3] classified lumbosacral junction into four types based on MRI finding.

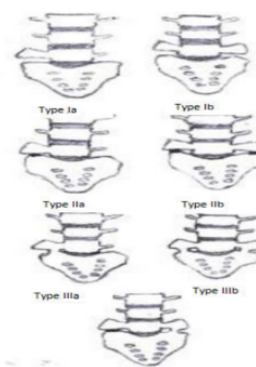


Figure 1: A drawing showing various types of LSTV as per Castellvi et al. [2].

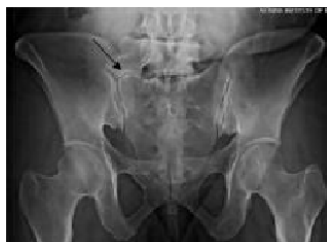

Figure 2: AP pelvic radiograph with the beam directed 300 cephalad showing unilateral neo-articulation. (Castellvi type IIa).

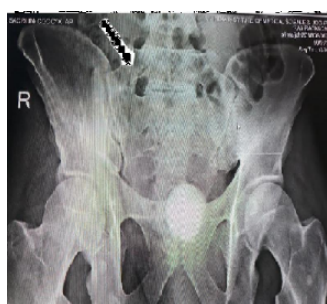

Figure 3: A Castellvi type III b with complete bilateral fusion in an asymptomatic 26 years old man.

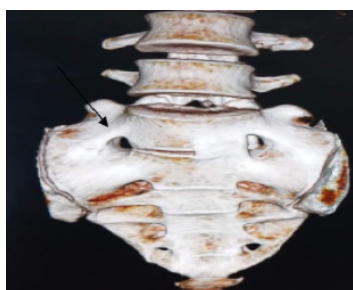

Figure 4: 3D reconstructed image of Castellvi type III b, complete assimilation of L5 into the sacrum.

On correlation with plane radiographs, it was found that 12 patients with type IV MRI appearance had radio-graphical similarities with either Castellvi type II or III. However, it was not confirmed whether the intervertebral disc concerned was between a lumbarized S1 and S2 or between sacralized L5 and S1 (Table1).

A cadaver study theorized that congenitally small sacral surface area tries to add more surfaces by the body's compensatory mechanism and functional requirement. Consequently, it involves L5 transverse processes in the neo-articulation and its subsequent fusion to sacral ala. Conversely, in case of large sacral surface area, the articulation leaves S1 from sacroiliac articulation and as a result, S1 lumbarization occurs [4].

Apart from transverse process changes and neo-articulation (sacralization), morphological changes also affect other parts of the vertebra affected. In sacralization, pedal height, its transverse and sagittal dimension, and saggital angulation are decreased and caudal angulation increased. The width of laminae and height of pars interarticularis (PI) decrease. A smaller PI renders the spine vulnerable to spondylolysis and spondylolisthesis [5]. Lumbarization of the S1 conversely results in obtuse pedicles, the short distance between facets and sacral promontory [6]. The transitional vertebra shows facets joint changes. In lumbarization, facet linear dimension and surface area are decreased and with maximal coronal orientation. Sacralisation does not show much changes in morphology [7]. Nicholson et al., observed a radiographically decreased intervertebral disc height between the lumbar transitional segment and the sacrum in comparison to a normal disc between L5 and S1 [8]. Conversely, in the case of lumbarization of S1, the S1-S2 disc assumes larger height, contrary to the normal disc, which is rudimentary and vestigial one.

There is always an ambiguity regarding which nerve is which in the scenario of LSTV because of altered anatomy. McCulloch and Waddle et al., stated that functional L5 root always originates from the last mobile segment of the spine [9]. The last mobile segment is defined as the vertebra, which has fully formed disc with bilaterally well-developed faced joints and separate transverse processes. Therefore, in sacralized L5, the functional L5 correspond to the anatomical L4 nerve root. In lumbarized S1, L5 nerve root corresponds to the S1 nerve root.

Epidemiology

Prevalence of LSTV is varied in the literature due to differences in definition and diagnostic modalities employed. It ranges from 4% to 35.9% with a mean of 12.3% [10-12]. Apazidis et al., reported LSTV Castellvi type Ia as the most common occurrence with a prevalence rate of 14.7%, though type Ia is considered of low clinical significance [13]. Nardo et al. reported that 40% of his cases of LSTV were of Castellvi type I and II [12]. Type III and type IV accounted for 11.5% and 5.25% respectively.

LSTV was reported more in men than women. A sacralization is more common in men, while lumbarization of S1 is more prevalent in women [12,14]. Common findings in some families suggested some genetic association responsible for the segmental development of the lumbosacral spine [11]. Embryonic development and segmentation of spine is probably controlled by families of genes, termed homeobox genes. These are abbreviated to Hox in mice and HOX in humans and are found on four clusters known as A, B, C, and D. Individual genes are numbered from 1 to 13. 1 is a cephalic gene and 13 is a more caudally placed gene [15].

Types	Status of the first sacral intervertebral disc
1	No disc material present between S1 and the remainder of the sacrum, the junction being identified by a low signal line
2	A small residual disc between S1 and the remainder of the sacrum, with the anteroposterior (AP) diameter of the disc being less than the AP diameter of the sacrum
3	A well-formed residual disc between S1 and the remainder of the sacrum, the AP diameter of the disc equalling the AP diameter of the sacrum
4	A well-formed residual disc between S1 and the remainder of the sacrum but also with an abnormal sagittal outline to the sacrum, i.e. "squaring" of the presumed upper sacral segment

Table 1: Classification of lumbosacral disc morphology [3].

Diagnosis and Imaging

Due to dysplastic changes in vertebrae and intervertebral disc space, it is not always easy to identify and number the vertebrae in the lumbosacral area. A Full x-ray of the whole spine or a CT scan is seldom done. Nonetheless, a standard anteroposterior and lateral radiograph of the lumbosacral spine can help reveal the transitional vertebra. Normally, most caudal rectangular or square shaped vertebra is considered as L5 in a lateral radiograph. In an LSTV, the last rectangular shape can coincide with either L4 or L6/S1, depending upon whether it is a sacralization or a lumbarisation. A transformation of S1 into lumbar configuration can be identified when it assumes a square shape from a rhombus or wedge shape, described as "squaring". The ratio of AP distance of superior end-plate and the inferior end-plate in lateral radiograph decreases and it is less than or equal to 1.37 [16]. The involved transitional vertebral body of S1 appears squared up. The normal acute angulation between L5 and S1 is reduced and lumbar lordosis is found to be exaggerated. Conversely, a sacralized L5 may depict the picture similar to S1 and transforms into a rhombus and wedge-shaped and the infrajacent disc space appears decreased in height and a vestigial one [17,18].

An anteroposterior radiograph with the beam directed 300 cephalad (Ferguson view) and coronal sections of CT scan reveal an array of information from a broadened and enlarged Transverse Processes (TP) of L5, a pseudo-articulation at TP and sacral ala and ilium to complete fusion. Axial cuts of CT scan highlight a neo-articulation, facet joint orientation and their spatial relationship. 3D NC-CT also allows seeing morphological changes in the transitional vertebra. A standard radiograph can fairly diagnose all types of LSTV with accuracy ranging from 53% to 58%.

The numbering of a vertebra in association with BS is also important as it has a great bearing on the localization of the level in the planning of surgery. Without definite identification and numbering, a wrong level surgery may ensue. For that purpose, a preoperative identification and numbering with correlation with intraoperative images are desired. Many times only a radiograph or MRI of the lumbosacral region is available. What appears as L1 with the transverse process in AP radiograph, in essence, maybe a T12 vertebra with hypoplastic ribs. Similarly, Hughes RJ et al. described the identification of iliolumbar ligament in MRI sections for the numbering purpose as it reliably arises from L5 transverse processes (TP) [19]. It originates from L5 TP and extends to the posteromedial iliac crest. It is visible as low signal images in both T1 and T2 weighted axial images. Hughes et al., labeled an LSTV as L5 when no iliolumbar ligament was identified at the level above. When an iliolumbar ligament was seen to arise above the LSTV, then the vertebral body with iliolumbar ligament was labeled L5 and the LSTV as S1 [19]. However, this technique assumes that there are always 7 cervicals, 12 thoracic and 5 lumbar vertebrae. It also does not respect the possibility of various segmentation anomalies at the thoracolumbar junction. A radiograph of the whole spine with the use of MR localizer helps in counting the vertebrae inferiorly from C2 and may help in true numbering [20]. However, MR sagittal images sometime may not pick up the changes. Tokgoz et al. did a large study in 1049 patients using MRI of the lumbosacral area with a whole spine localizer and reported that about 1.3% patients were wrongly diagnosed as having LSTV, while 35.1% patients of abnormal segmentation were wrongly labeled as having normal segmentation [21]. Even after correctly identifying LSTV, they reported incorrect vertebral level numbering in 60% of cases with a total diagnostic error in 14.1% cases. Lumbarization of S1 demonstrated a well-formed IVD

at S1-S2 level with squared up S1 body. Sacralization revealed a rhombus-shaped L5 body.

Some anatomic landmarks such as a right renal artery, aortic bifurcation, and level of conus medullaris have also been studied. Lee et al., stated that aortic bifurcation and right renal artery are reliable landmarks in MRI or CT for identification of lumbosacral segments [17]. Most of the times, right renal artery is present at L1-L2 disc level, but it is not always imaged or present in other locations in approximately 25% of cases [22].

Farshad et al., described a novel method of identifying an LSTV [23]. The difference in the vertical mid-vertebral angles (Diff-VMVA) and the difference in the vertical anterior vertebral angles (Diff-VAVA) of the last three caudal segment of the spine were calculated in sagittal MRI and lateral radiograph. A Diff-VMVA of <100 identified type III and type IV LSTV with a sensitivity of 100% and a specificity of 89% on MRI and a sensitivity of 94% and a specificity of 74% on the lateral radiograph. Also, a Diff-VAVA, a sensitivity of 100% and a specificity of 76% were obtained.

Paik et al., suggested the inclusion of the cervical spine in MR Imaging for numerically counting of the vertebrae to identify LSTV. In their study, 89.2% had 5 lumbar vertebrae (L5), 2.6% had 4 lumbar vertebrae (L4) and 8.2% had 6 lumbar vertebrae (L6) [11]. Types II, III, or IV LSTV were present in 10.6% of the patients, including 5.3% of sacralized L5 and 5.3% of lumbarized S1. Only 83.9% of patients were the modal type with 5 lumbar vertebrae without transitional vertebra. The last lumbar vertebra with no transition, looking like a modal L5 type, can be an L4 or an L6, as seen in 2.6% and 2.9% of the patients, respectively.

The exiting spinal nerves may get pinched because of bony growth. Weber et al. reported two cases of LSTV resulting in entrapment of L5 nerve root between enlarge transverse process and sacral ala with osteophytes and bone spur formation [15] (Figures 5 and 6). Excision of the abnormal growth and bony osteophytes resulted in successful relieving of radicular pain and dysesthesia in the L5 nerve distribution. Unilateral or bilateral dysplastic facet joints were also found just below the transitional vertebra.

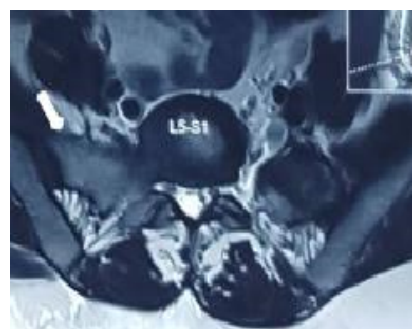


Figure 5: T2 weighted axial image of LS spine with overgrown Rt side transverse process of L5.

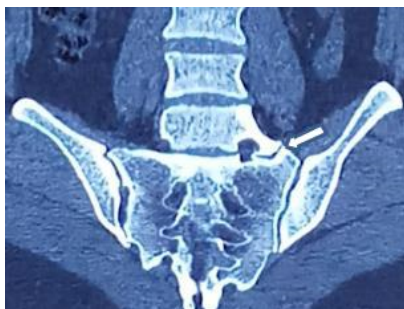


Figure 6: Coronal section of NC-CT scan showing pseudo-joint between TP and sacrum with sclerosis.

Radiographical presence of degeneration at the new articulation and intervertebral joints in LSTV may not correlate with patient's symptomatology. To find out the painful focus, the metabolic activity of the region was also studied widely by using planar and SPECT bone scintigraphy to find an inflammatory focus. Pekindil G et al., demonstrated non-focal mild uptake in eight asymptomatic LSTV cases [24]. Symptomatic LSTV without degeneration patients showed nonfocal mild uptake; whereas symptomatic LSTV patients with radiographically noted degenerative spine revealed focal, marked uptake on SPECT bone scintigraphy. It is the degenerative spine at the pseudo-articulation site and facet joints, which cast an increased uptake. Although, Jonsson et al., reported normal planar bone scan findings in eight patients with unilateral LSTV articulation [25]. In author's view, though a single modality may not diagnose the problem, yet a combination of investigations such as plane radiograph, CT scan, and MR localizer can fairly diagnose and classify all the variants of lumbosacral transitional vertebrae.

Mechanism of Pain Generation

The transitional vertebra in lumbosacral region disturbs normal biomechanical anatomy. The sacrum, a large triangular bone, dissipates and transmits body weight to the limb through SI joints. This capability of it surely depends on the surface area of the articulation. Pathophysiology of pain generation in presence of LSTV has always been unclear. Many studies found an increased prevalence of degenerative process at superjacent disc level to LSTV [2,26]. Causes of low back pain in association with transitional vertebra are multifactorial in origin. Presence of extra-foraminal stenosis, spinal stenosis; nerve root canal stenosis and facet joint degeneration were some of the proposed mechanisms for low back pain with or without radicular pain [27,28]. Connolly et al., studied skeletal scintigraphy in young patients with LSTV and demonstrated that mechanical stress at the pseudo-articulation could cause low back pain [29].

Even after identification of transitional vertebra, there are many controversies regarding its association and mechanism of LBA. An increase in the prevalence of disc degeneration and a protrusion or extrusion is found in the disc above the transitional L5 vertebra [2,9,30,31]. It has been found and theorized that an LSTV causing reduced mobility at L5-S1 leads to hypo-mobility at that level. Consequently, hypermobility and stress are generated at L4-L5, which cause disc degeneration, protrusion/extrusion, and early facet joint degeneration. In contrast, the Inter-vertebral disc at the transitional zone is protected (Figure 7) [16,30,31]. Asymmetric transitional

vertebra has been considered as a potential source of low back pain [29]. Presence of sclerotic changes and bony osteophytes signify that a slight amount of motion may occur at pseudo-articulation site, resulting in LBA [32].

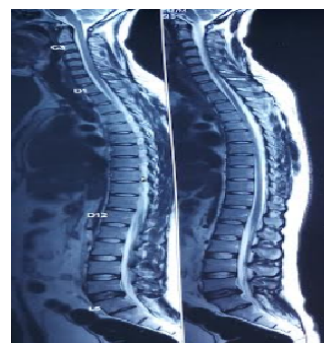

Figure 7: T2 weighted sagittal sections of MRI whole spine showing decreased L5-S1 disc space with early degeneration of superjacent disc at L4-L5 level in a 26 years old patient with Castellvi type III b.

Nardo et al. proposed that there is a positive relationship between LSTV type II and type IV and LBA [12]. Quinlan et al., also concluded that LSTV should be considered as a possible cause of LBA [33]. Wiltse, pointed out that the bony enlargement of the L5 transverse process can lead to nerve entrapment between the anomaly and sacral ala and named it "far out syndrome" [34].

Conversely, several studies also found contradictory results [35] Luoma et al., in an MRI study of asymptomatic patients found that though there was an increased prevalence of degeneration of the disc above the LSTV, an association between the findings and LBA was lacking [10]. Tiny et al., included 4000 patients and did not report that LSTV was associated with LBA [36].

Management

Treatment of lumbosacral transitional vertebra has been controversial as some studies refuted its association with a low backache [14,16]. In contrast, some authors also indicated its relationship with increased lumbar degenerative disc disease at the suprajacent level and pain generation at the false joint between the L5 transverse process and sacral ala [12,33]. Presence of transition vertebra and concurrent back pain pose a great diagnostic and treatment decision-making problem to the clinicians. Several authors indicated that LSTV, particularly castellvi type II and type IV potentially could be a source of low back pain [12] and should always be considered in differential diagnoses of low back pain in the younger population. Reduced mobility at the L5S1 level and consequently, increased abnormal and asymmetric stress can result in early degenerative changes within the "neo-articulation" or in the normal contralateral facet joint.

As far as management is concerned, it begins with conservative management, as is the case with patients of LBA without LSTV. There are several small studies and case reports about successful initial management of the patients using therapeutic mobilization and physical therapy [37] although, literature evidenced BS patients do benefit poorly if physiotherapy is used alone or in combination with anti-inflammatory and analgesic agents.

Considering the multifactorial origin site of pain, it is quite difficult to pinpoint the pain generators using a radiograph and/or an MRI alone. Injection of local anesthetic agents in the potential site of pain is a fairly good approach to pinpoint all the areas, which are problematic. In addition, bone scan or SPECT/CT scintigraphy may potentially suggest the culprit areas. Anuj et al. used a block method to locate the pain generators in BS caltelvi type IA [38]. In their study, after confirmation of pain site using blocks, radio-frequency ablation of the rami communicants, SI joint RF, DRG pRF and nucleoplasm were used as a definitive treatment with relief extended beyond 6 months. Out of them, neo-articulation was the worst in terms of pain relief. A sacroilitis also fared poorly with radiofrequency denervation.

Relief from local anesthetic and steroid injection at neo-articulation site has been variable with no consistent results. Robert C Mark et al., prospectively followed a cohort of 10 patients with severe LBA diagnosed with an LSTV on X-ray [39]. All patients received X-ray guided injection of steroids and local anesthetic agent. Out of them, 8 patients had immediate pain relief and 1 patient had total pain relief after one week of injection. 5 of them had a recurrence of pain ranging from 1 day to 12 weeks of injection. Three patients reported partial pain relief lasting from 7 to 41 months and 1 patient was pain-free till 2 years after the injection.

Avimadje et al., [40] retrospectively studied 12 patients with LSTV with same side LBA and buttock pain. 11 patients received steroid injection at pseudo articulation site. Out of them 9 patients reported 50% pain relief at 1 month follow up. One patient lost to follow up. 7 out of 8 patients had improved or had no pain at 6 to 24 months later 2 patients received 2nd injection at one and two months respectively, after the first injection. They emphasized that results of local steroid injection are also unpredictable, but still it should be considered in patients with LSTV before considering for surgical means of treatment.

There is a paucity of literature regarding surgical treatment of LBA in association with bertolotti's syndrome. Santavirta et al. treated 16 patients of bertolotti's syndrome aged 27 to 58 years (mean-34) with operative treatment [41]. Surgical methods included posterolateral fusion in half of the patients and surgical resection of enlarged transverse process in the other half. He observed that though pain intensity in the postoperative group was improved, it was only slightly better than the conservatively treated group. He emphasized that operative treatment should be considered in those patients who have exhausted the conservative treatment. Prior to surgical execution, disc pathology just above and below the transitional vertebra should be considered. Surgical resection of the transverse process should be considered when the pain truly arises from the neo-articulation site. Conversely, posterolateral fusion may be offered to those who have disc pathology in term of degeneration, protrusion etc. at infradjacent disc level.

Jonsson et al., anesthetized the neo-articulation first and observed considerable improvement in the majority of his patients, even-though bone scintimetry using 99m Tc MDP had not shown an increased uptake in most of the patients [25]. Out of 11 patients (mean follow up of 17 months), 9 patients reported long-lasting significant to complete alleviation of symptoms after surgical resection of the enlarged TP. It can be inferred that not all the neo-articulation site and subsequent degeneration their-of are painful and as a result, they may show a cold spot on bone scintigraphy. They postulated that it is the hypermobility rectification between the rostral lumbar segment and sacrum, which relieved the LBA following resection of neo-articulation.

Pain arising from the facet joint contra-lateral to the pseudo joint also has been claimed. Jeffrey S et al., treated one case of BS by prior confirmation with an injection of anesthetic agents and subsequent excision of neo-articulation site and had successful pain relief at the contralateral facet site at one-year follow-up [42].

The minimally invasive technique has also been employed to resect the overgrown transverse process of L5 and reported to having good pain relief in short term follow-up [43]. Li et al. treated 7 patients of BS using minimally invasive tubular resection of overgrown L5 TP [44]. 3 out of 7 patients reported complete relief in symptoms, 2 out of 7 reported reduced pain intensity and 2 of 7 reported initial pain relief but recurrence of pain at 1 and 4 years of surgery was observed.

Almeida et al., treated 5 patients of BS with prior infiltration of neo-articulation with the anesthetic agent [45]. 3 out of 5 got partial relief and 2 out of 5 had significant relief. The later were subjected to surgical resection of transverse mega-apophysis and got total pain relief in the long run. He theorized the principle of low back pain care in presence of bertolotti's syndrome. General norm of a low backache with BS starts from conservative management in form of NSAIDS, physiotherapy and chiropractic manipulations. Those who do not respond to this regime are a potential candidate for diagnostic and sometimes therapeutic injection of steroid and anesthetic agents at neo-articulation site or the contralateral facet joint, although, no previous studies reported any prognostic value of this procedure. Candidates, who have had partial/significant pain relief from the injection, may be enrolled for surgical resection of the overgrown L5 transverse process. In association with significant degeneration of contralateral facet joint, a fusion procedure at L5 and S1 in form of TLIF/PLIF is a better choice.

Chang il ju et al., studied 256 patients of bertolotti's syndrome and chose to give steroid injections at pseudo-articulation in 87 cases [22]. 26 cases were excluded from study analysis because of the elimination of confounding factors like the presence of other spinal diseases viz. spinal stenosis, disc herniation, and spondylolisthesis. Group A (39 cases) received local steroid and anesthetic agent injection at pseudo-articulation site and the group B (22 cases) received selective L4 nerve root block. After confirming temporary relief, all 61 patients were subjected to L5 transverse proctectomy. In group A, preoperative VAS score was 7.59 ± 0.93 and postoperative VAS score was 3.82 ± 1.59 . In group B, pre-surgical average VAS score was 7.50 ± 0.86 and post-surgical VAS score was 2.05 ± 1 . Average follow up duration was 10 months. In their study, effective pain relief with the injection was received only in 25% cases. They emphasized that the majority of the persistent pain could originate from another site other than pseudo-articulation site such as far out syndrome, foraminal stenosis, etc. In addition, they also pointed out that the LBA and radicular pain could also arise from L4 nerve compression because of overgrown L5 TP. They advocated additional decompression of L4 nerve root while bisecting the overgrown transverse process of L5.

Conclusion

Bertolotti's syndrome with LBA may pose a great diagnostic dilemma to a clinician. The origin of pain is multifactorial. A diagnostic search for pain points should be done using an array of investigations viz. x-ray, MRI; CT scan, SPECT and bone scan. Initial treatment starts from conservative management just as with LBA with no BS. Along with pain medications, physiotherapy should be employed. In refractory cases, diagnostic injection of steroid and

anesthetic agent can be given. If the pain relief is partial and short-lived, surgical means in form of resection or posterolateral fusion may be considered. Resection fares better only in cases where facet joints are not so degenerated, while fusion surgery appears to be a worthwhile approach if advanced facet joint degeneration, spondylolysis, and spondylolisthesis are present at transitional vertebral level. A need of individualization of treatment strategy is of paramount importance. Moreover, further studies of higher evidence with large sample size are needed to delineate a definite management strategy for this potentially ambiguous area.

References

1. Bertolotti M (1917) Contributo alla conoscenza dei vizi di differenziazione regionale del rachide con speciale riguardo all'assimilazione sacrale della V lombare. *Radiol Med (Torino)* 4: 113-114.
2. Castellvi AE, Goldstein LA, Chan DP (1984) Lumbosacral transitional vertebrae and their relationship with lumbar extradural defects. *Spine (Phila Pa 1976)* 9: 493-495.
3. O'Driscoll CM, Irwin A, Saifuddin A (1996) Variations in morphology of the lumbosacral junction on sagittal MRI: correlation with plain radiography. *Skeletal Radiol* 25: 225-230.
4. Mahato NK (2010) Morphological traits in sacra associated with complete and partial lumbarization of first sacral segment. *Spine J* 10: 910-915.
5. Mahato NK (2013) Pars inter-articularis and laminar morphology of the terminal lumbar vertebra in lumbosacral transitional variations. *N Am J Med Sci* 5: 357-361.
6. Mahato NK (2011) Pedicular anatomy of the first sacral segment in transitional variations of the lumbosacral junction. *Spine (Phila Pa 1976)* 36: E1187-1192.
7. Mahato NK (2011) Facet dimensions, orientation, and symmetry at L5-S1 junction in lumbosacral transitionals. *Spine (Phila Pa 1976)* 36: E569-573.
8. Nicholson AA, Roberts GM, Williams LA (1988) The measured height of the lumbosacral disc in patients with and without lumbosacral transitional vertebrae. *Br J Radiol* 61: 454-455.
9. McCulloch JA, Waddell G (1980) Variation of the lumbosacral myotomes with bony segmental anomalies. *Bone Joint J* 62: 475-480.
10. Luoma K, Vehmas T, Raininko R, Luukkonen R, Riihimäki H (2004) Lumbosacral transitional vertebra: relation to disc degeneration and low back pain. *Spine* 29: 200-205.
11. Paik NC, Lim CS, Jang HS (2013) Numeric and morphological verification of lumbosacral segments in 8280 consecutive patients. *Spine* 38: E573-E578.
12. Nardo L, Alizai H, Virayavanich W, Liu F, et al. (2012) Lumbosacral transitional vertebrae: association with low back pain. *Radiology* 265: 497-503.
13. Apazidis A, Ricart PA, Diefenbach CM, Spivak JM (2011) The prevalence of transitional vertebrae in the lumbar spine. *Spine J* 11: 858-862.
14. Dzupa V, Slepánek M, Striz M, Krbec M, Chmelova J, et al. (2013) Developmental malformations in the area of the lumbosacral transitional vertebrae and sacrum: differences in gender and left/right distribution. *Surgical and Radiologic Anatomy: SRA* 36: 689-693.
15. Collins P, Braude PR (2008) Embryonic induction and cell division. *Gray's Anatomy: The Anatomical Basis of Clinical Practice (40th edn)*, Churchill Livingstone, Edinburgh.
16. Wigh RE, Anthony HF Jr (1981) Transitional lumbosacral discs. Probability of herniation. *Spine (Phila Pa 1976)* 6: 168-171.
17. Lee CH, Seo BK, Choi YC, Shin HJ, Park JH, et al. (2004) Using MRI to evaluate anatomic significance of aortic bifurcation, right renal artery, and conus medullaris when locating lumbar vertebral segments. *AJR Am J Roentgenol* 182: 1295-1300.
18. Lee CH, Park CM, Kim KA, Hong SJ, Seol HY, et al. (2007) Identification and prediction of transitional vertebrae on imaging studies: anatomical significance of paraspinous structures. *Clin Anat* 20: 905-914.
19. Hughes RJ, Saifuddin A (2006) Numbering of lumbosacral transitional vertebrae on MRI: role of the iliolumbar ligaments. *AJR Am J Roentgenol* 187: W59-W65.
20. Hahn PY, Strobel JJ, Hahn FJ (1992) Verification of lumbosacral segments on MR images: identification of transitional vertebrae. *Radiology* 182: 580-581.
21. Tokgoz N, Ucar M, Erdogan AB, Kilic K, Ozcan C (2014) Are spinal or paraspinous anatomic markers helpful for vertebral numbering and diagnosing lumbosacral transitional vertebrae? *Korean J Radiol* 15: 258-266.
22. Ju CI, Kim SW, Kim JG, Lee SM, Shin H, et al. (2017) Decompressive L5 Transverse Processotomy for Bertolotti's Syndrome: A Preliminary Study. *Pain Physician* 20: E923-E932.
23. Farshad M, Aichmair A, Hughes AP, Herzog RJ, Farshad-Amacker NA (2013) A reliable measurement for identifying a lumbosacral transitional vertebra with a solid bony bridge on a single-slice midsagittal MRI or plain lateral radiograph. *Bone Joint J* 95: 1533-1537.
24. Pekindil G, Sarikaya A, Pekindil Y, Gültekin A, Kokino S (2004) Lumbosacral transitional vertebral articulation: Evaluation by planar and SPECT bone scintigraphy. *Nucl Med Commun* 25: 29-37.
25. Jonsson B, Strömquist B, Egund N (1989) Anomalous lumbosacral articulations and low-back pain. Evaluation and treatment. *Spine* 14: 831-834.
26. Otani K, Konno S, Kikuchi S (2001) Lumbosacral transitional vertebrae and nerve-root symptoms. *J Bone Joint Surg Br* 83: 1137-1140.
27. Konin GP, Walz DM (2010) Lumbosacral transitional vertebrae: classification, imaging findings, and clinical relevance. *Am J Neuroradiol* 31: 1778-1786.
28. Hughes RJ, Saifuddin A (2004) Imaging of lumbosacral transitional vertebrae. *Clin Radiol* 59: 984-991.
29. Connolly LP, Drubach LA, Connolly SA, Treves ST (2004) Young athletes with low back pain: skeletal scintigraphy of conditions other than pars interarticularis stress. *Clin Nucl Med* 29: 689-693.
30. Elster AD (1989) Bertolotti's syndrome revisited. Transitional vertebrae of the lumbar spine. *Spine (Phila Pa 1976)* 14: 1373-1377.
31. Vergauwen S, Parizel PM, Breusegem LV, Goethem JW, Nackaerts Y, et al. (1997) Distribution and incidence of degenerative spine changes in patients with a lumbosacral transitional vertebra. *Eur Spine J* 6: 168-172.
32. Weber J, Ernestus RI (2010) Transitional lumbosacral segment with unilateral transverse process anomaly (Castellvi type 2A) resulting in extraforaminal impingement of the spinal nerve: a pathoanatomical study of four specimens and report of two clinical cases. *Neurosurg Rev* 34: 143-150.
33. Quinlan JF, Duke D, Eustace S (2006) Bertolotti's syndrome. A cause of back pain in young people. *J Bone Joint Surg Br* 88: 1183-1186.
34. Wiltse LL, Guyer RD, Spencer CW, Glenn WV, Porter IS (1984) Alar transverse process impingement of the L5 spinal nerve: the far-out syndrome. *Spine* 9: 31-41.
35. Magora A, Schwartz A (1978) Relation between the low back pain syndrome and x-ray findings. 2. Transitional vertebra (mainly sacralization). *Scand J Rehabil Med* 10: 135-145.
36. Tini PG, Wieser C, Zinn WM (1977) The transitional vertebra of the lumbosacral spine: its radiological classification, incidence, prevalence, and clinical significance. *Rheumatol Rehabil* 16: 180-185.
37. Brenner AK (2005) Use of lumbosacral region manipulation and therapeutic exercises for a patient with a lumbosacral transitional vertebra and low back pain. *J Orthop Sports Phys Ther* 35.
38. Jain A, Agarwal A, Jain S, Shamsery C (2013) Bertolotti syndrome: A diagnostic and management dilemma for pain physicians. *Korean J Pain* 26: 368-373.

-
39. Marks RC, Thulbourne T (1991) Infiltration of anomalous lumbosacral articulations. Steroid and anesthetic injections in 10 back-pain patients. *Acta Orthop Scand* 62: 139-41.
 40. Avimadje M, Goupille P, Jeannou J, Gouthière C, Valat JP (1999) Can an anomalous lumbosacral or lumbo-iliac articulation cause low back pain? A retrospective study of 12 cases. *Rev Rhum Engl Ed* 66: 35-39.
 41. Santavirta S, Tallroth K, Ylinen P, Suoranta H (1993) Surgical treatment of Bertolotti's syndrome. Follow-up of 16 patients. *Arch Orthop Trauma Surg* 112: 82-87.
 42. Brault JS, Smith J, Currier BL (2001) Lumbosacral transitional vertebra resection for contralateral facetogenic pain. *Spine* 26: S226-S229.
 43. Yousif S, Wood M (2018) Minimally invasive resection of lumbosacral pseudojoint resulting in complete resolution of lower back pain-A case report and review of Bertolotti's syndrome. *J Clin Neurosci* 51: 67-68.
 44. Li Y, Lubelski D, Abdullah KG, Mroz TE, Steinmetz MP (2014) Minimally invasive tubular resection of the anomalous transverse process in patients with Bertolotti's syndrome. *J Neurosurg Spine* 20: 283-290.
 45. Almeida DB, Mattei TA, Sória MG, Prandini MN, Leal AG, et al. (2009) Transitional lumbosacral vertebrae and low back pain: diagnostic pitfalls and management of Bertolotti's syndrome. *Arq Neuropsiquiatr* 67: 268-272.