

Beneficiary Effect of Autologous Hematopoietic Cell Transplantation in Idiopathic Ulcerative Dermatitis C57BL/6 Mice

Senthilnathan Palaniyandi^{1,2}, Elisabeth Huber³, Sabarinath Venniyil Radhakrishnan^{1,2}, Elyse A Orchard⁴ and Gerhard C Hildebrandt^{1,2*}

¹Department of Medicine, Division of Hematology and Oncology, Feist-Weiller Cancer Center, Louisiana State University Health Sciences Center Shreveport, Shreveport, Louisiana, USA

²Department of Medicine, Division of Hematology and Hematologic Malignancies, University of Utah School of Medicine, Salt Lake City, Utah, USA

³Department of Pathology, University of Regensburg Medical School, Regensburg, Germany

⁴Veterinary Services Louisiana State University Health Sciences Center Shreveport, Shreveport, Louisiana, USA

Abstract

Idiopathic ulcerative dermatitis (IUD) is a distinctive skin disease in C57BL/6 mice. The pathogenesis of this disease is still unknown but it has been suggested that scratching character of this strain and immune complex induced vasculitis play a role. There is no established treatment for idiopathic ulcerative dermatitis. Naïve C57BL/6 with lesions suggestive of IUD with ulceration, necrosis and bleeding were identified and confirmed clinically by institutional veterinarian. Mice with severe lesions were euthanized and skin sample biopsies confirmed IUD by pathology. Mice with mild to moderate ulceration were distributed into two groups, of which one was treated with autologous hematopoietic cell transplantation (HCT) and the remaining were kept as observation control. For HCT, recipients received 950 cGy single dose total body irradiation followed by injection of bone marrow cells from IUD-free C57BL/6 mice. Animals were monitored daily until the end of week 4, when autologous transplant recipients showed improved skin condition without ulceration. Compared to observation controls, autologous transplant seemed to accelerate the healing process, suggesting that inducing temporary immune-incompetency targeting auto-reactive B and T lymphocytes seems beneficial in this disease. Suggesting that dysregulation of cellular immune responses is contributory to IUD, our findings further imply potential value for autologous HCT related immunosuppression in the treatment of chronic autoimmune dermatological diseases.

Keywords: Idiopathic ulcerative dermatitis; Euthanization; Myeloablation

Introduction

Idiopathic ulcerative dermatitis (IUD) is a spontaneously observed skin condition observed in C57BL/6 mice, which causes severe morbidity and can result in the need for premature euthanization of experimental animals [1,2]. Ulcerative skin lesions worsen progressively with evolution of irregular areas of ulceration, a dense inflammatory infiltrate and keratinocyte cell death, and the disease incidence peaking in mice beyond 10 to 16 months of age [3]. Although the etiology of IUD remains unclear, ulcerative skin lesions are associated with immune complex vasculitis [1], suggesting a potential autoimmune phenomenon. Prior study showed that high-fat diet significantly increased the incidence of ulcerative dermatitis in C57BL/6 mice and identified obesity as a risk factor [4]. Remarkable similarities between C57BL/6 mice ulcerative dermatitis and human central centrifugal cicatricial alopecia disease have been described [5]. Autologous hematopoietic cell transplantation (HCT) has been clinically employed to treat various severe and otherwise treatment-refractory autoimmune diseases [6]. Accordingly, we attempted to delineate the value of autologous HCT in animals suffering from IUD.

Materials and Methods

Animals

Naïve C57BL/6J mice developing IUD lesions were identified by the institutional veterinarian. Severe IUD was defined as ulcerative lesions of significant depth and resulting bleeding, whereas mild to moderate IUD was characterized as lesions without bleeding. The use of mice was approved by the IACUC of LSUHSC Shreveport. Animals were reported by the veterinary services as having clinical signs suggestive of IUD, and were monitored by the veterinary services for defined parameters of severity of IUD and for humane endpoints. Animals suffering from severe IUD and reaching humane endpoints (n=3) were sacrificed

and skin samples were collected for the analysis. Animals with mild to moderate IUD severity were stratified into two groups, of which one was treated with autologous HCT (n=6) and the other one (n=6) was observed only. Animals were distributed between groups equally with respect to severity and extent of disease. Following stratification, each mouse was housed individually. All the animals were cared for in accordance with Louisiana State University Health Sciences Center – Shreveport IACUC guidelines and were under the direct supervision of the institutional veterinarian.

Autologous HCT

C57BL/6 mice were conditioned using total body irradiation (TBI) at single dose of 950 cGy using Cesium source irradiator, followed by the infusion of 5×10^6 bone marrow cells from healthy C57BL/6 donors via tail vein injection.

Pathology and disease monitoring

Animals were monitored daily, and weight changes were recorded on day 0, 2,4,6,8,10,14,21 and 28. Severity of ulcerative skin lesions

***Corresponding authors:** Gerhard C. Hildebrandt, Division of Hematology & Hematologic Malignancies, Huntsman Cancer Institute, University of Utah School of Medicine, Huntsman Cancer Institute, 2000 Circle of Hope, Salt Lake City, UT, USA, 84112-5550; Tel: 801-585-3229; Fax: 801-585-2626; E-mail: Gerhard.Hildebrandt@hci.utah.edu

Received December 02, 2013; **Accepted** February 05, 2014; **Published** February 07, 2014

Citation: Palaniyandi S, Huber E, Radhakrishnan SV, Orchard EA, Hildebrandt GC (2014) Beneficiary Effect of Autologous Hematopoietic Cell Transplantation in Idiopathic Ulcerative Dermatitis C57BL/6 Mice. J Bone Marrow Res 2: 139. doi: 10.4172/2329-8820.1000139

Copyright: © 2014 Palaniyandi S, et al. This is an open-access article distributed under the terms of the Creative Commons Attribution License, which permits unrestricted use, distribution, and reproduction in any medium, provided the original author and source are credited.

was observed until 4 weeks after HCT, when animals were sacrificed. Skin samples were taken from areas within initially documented involvement with IUD. Skin samples were fixed in formalin for 48 hrs and then transferred into 70% ethanol, paraffin-embedded and sectioned. Hematoxylin–eosin-stained sections from individual mice were coded without reference to mouse type and treatment and skin was independently examined by two pathologists in blinded fashion.

IUD severity scoring system

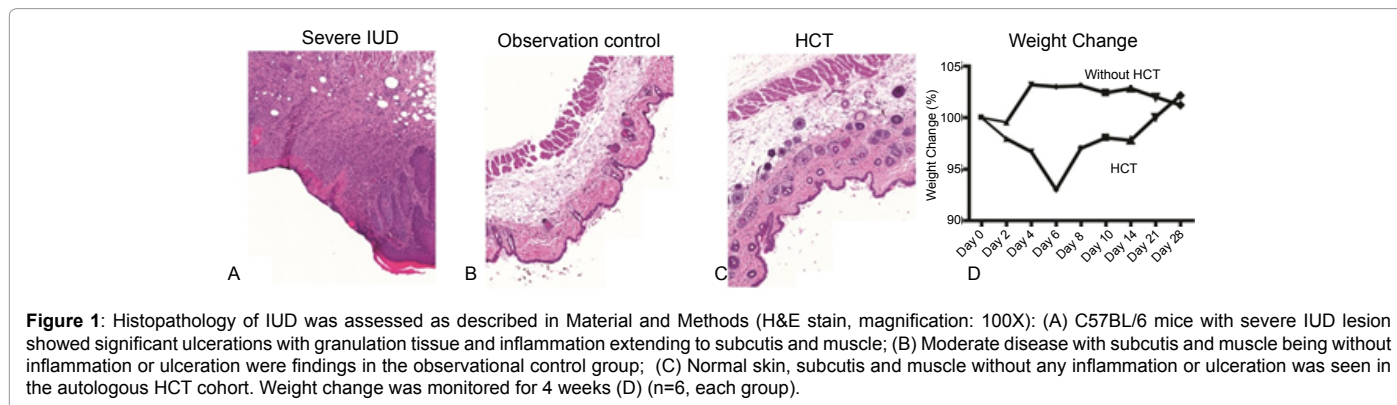
Clinical severity of IUD was defined on day 0 by using the parameters “character of lesion”, “length of lesion” and “regions affected” in modification of Hampton et al. [7].

Results and Discussion

15 animals with IUD were identified and stratified into three groups as described in materials and methods: one group was sacrificed on day 0 for baseline control, one group received TBI followed by auto HCT and one group was kept untreated during the observation period as control. Histopathologic changes of IUD skin lesions were compared between animals with severe IUD, which were initially sacrificed, and the observation group and the HCT group at four weeks. To avoid sampling bias, in both the observation group and the HCT group, skin lesions were initially identified and graphically documented, and then those regions were chosen for skin biopsy at time of analysis. In animals with initially severe IUD clinically, histology revealed ulcerations along

with abundant mast cells with basophilic granules. In the observation control group, a moderate number of mast cells with basophilic granules were seen along with skin injury, which had improved to before. HCT mice showed strongest improvement with only minor changes histologically without ulceration (Figure 1). The detailed pathology evaluation is depicted in (Table 1). Un-transplanted animals did not show significant weight changes, whereas consistent with radiation toxicity; HCT recipients experienced a temporary weight loss due to gastrointestinal injury. At time of sacrifice, the skin in animals receiving auto HCT macroscopically showed significant improvement with hardly any clinical signs of IUD, whereas in animals, which were observed only, skin integrity was still affected and the healing process appeared to be delayed.

Additionally, we analyzed a prior reported association of clinical presentation of IUD with survival [7]. All animals with a severity score of 7/8 died or fulfilled criteria for euthanization for humane reason, independently of treatment approach (n=2 in auto HCT group, n=2 in observation control). IUD is a common disease in long living mice especially of C57BL/6 background and the pathophysiology is still not fully understood. Oxidative injury has been proposed, and treatment of IUD with vitamin E was reported to be efficient [8], whereas a prophylactic vitamin E diet did not prevent IUD development and was associated with increased mortality [9]. However, recent work indicates that ulcerative dermatitis does result from a defect in the oxidative stress response [10]. As IUD is most prevalent in C57BL/6



Group	Mice	Pathology description
Severe IUD	1	Perivascular dermatitis, perivascular and interstitial, superficial and deep, mild. Moderate amount of mast cells with basophilic granules. Thicken blood vessels. Marked inflammation, large ulceration with granulation tissue and inflammation extending to subcutis and muscle.
	2	Perivascular dermatitis, perivascular and interstitial, superficial and deep, moderate. Moderate amount of mast cells with basophilic granules. Thicken blood vessels. No ulceration
	3	Perivascular dermatitis, perivascular and interstitial, superficial and deep, mild. No ulceration
Observation control group	1	Perivascular dermatitis, perivascular and interstitial, deep only, moderate. Moderate amount of mast cells with basophilic granules. No ulceration
	2	Perivascular dermatitis, perivascular and interstitial, superficial and deep, marked. Abundant mast cells with basophilic granules. Possible ulceration
	3	Perivascular dermatitis, perivascular and interstitial, deep only, marked. Focal inflammation around adnexa, no superficial inflammation
	4	Perivascular dermatitis, perivascular and interstitial, superficial and deep, moderate. Abundant mast cells with basophilic granules. No ulceration
HCT group	1	Perivascular dermatitis, interstitial, superficial, mild. No ulceration.
	2	Perivascular dermatitis, perivascular and interstitial, superficial and deep, mild. No ulceration.
	3	Perivascular dermatitis, perivascular and interstitial, superficial and deep, moderate. Ruptured epidermal inclusion cysts with granulation tissue. No ulceration.
	4	Diffuse dermatitis, mild. No ulceration.

Table 1: Pathology evaluation of skin lesions.

mice, a genetic predisposition potentially related with a barbering behavioral pattern has been discussed [3]. When housed individually, as in this study, animals with IUD tend to improve, but may result in behavioral changes such as increased hyperactivity and anxiety [11,12], often render them unusable in future experiments. Prior studies have suggested immune complex vasculitis [1] or obesity and high lipid diet related inflammation [13]. TBI is known to cause lymphocyte depletion [14], and has been successfully used in the allogeneic HCT setting to suppress the recipient's T cell responses and to prevent graft rejection across major and minor MHC mismatches. In addition, TBI given in lethal dosing results in myeloablation and lethal pancytopenia, which can be rescued only by reinfusion of autologous or allogeneic hematopoietic stem cells. Neutrophil recovery occurs usually within the first two weeks after autologous HCT, whereas adaptive immune recovery occurs over a period of months to years [15]. In our study, auto HCT seemed to accelerate the healing process, suggesting that inducing temporary immune-incompetency targeting autoreactive B and T lymphocytes, and potentially neutrophils, seems beneficial in this disease. Despite the limitations of small animal numbers in our study and the obvious non-feasibility to expose animals to auto HCT prior to their use in future experiments, we believe, that our findings support the concept of auto HCT related immunosuppression in the treatment of chronic inflammatory disease, such as autoimmune diseases [6].

References

1. Andrews AG, Dysko RC, Spilman SC, Kunkel RG, Brammer DW, et al. (1994) Immune complex vasculitis with secondary ulcerative dermatitis in aged C57BL/6N^{nia} mice. *Vet Pathol* 31: 293-300.
2. Williams-Fritze MJ, Carlson Scholz JA, Zeiss C, Deng Y, Wilson SR, et al. (2011) Maropitant citrate for treatment of ulcerative dermatitis in mice with a C57BL/6 background. *J Am Assoc Lab Anim Sci* 50: 221-226.
3. Kastenmayer RJ, Fain MA, Perdue KA (2006) A retrospective study of idiopathic ulcerative dermatitis in mice with a C57BL/6 background. *J Am Assoc Lab Anim Sci* 45: 8-12.
4. Neuhaus B, Niessen CM, Mesaros A, Withers DJ, Krieg T, et al. (2012) Experimental analysis of risk factors for ulcerative dermatitis in mice. *Exp Dermatol* 21: 712-713.
5. Sundberg JP, Taylor D, Lorch G, Miller J, Silva KA, et al. (2011) Primary follicular dystrophy with scarring dermatitis in C57BL/6 mouse substrains resembles central centrifugal cicatricial alopecia in humans. *Vet Pathol* 48: 513-524.
6. Hough RE, Snowden JA, Wulffraat NM (2005) Haemopoietic stem cell transplantation in autoimmune diseases: a European perspective. *Br J Haematol* 128: 432-59.
7. Hampton AL, Hish GA, Aslam MN, Rothman ED, Bergin IL, et al. (2012) Progression of ulcerative dermatitis lesions in C57BL/6Crl mice and the development of a scoring system for dermatitis lesions. *J Am Assoc Lab Anim Sci* 51: 586-593.
8. Lawson GW, Sato A, Fairbanks LA, Lawson PT (2005) Vitamin E as a treatment for ulcerative dermatitis in C57BL/6 mice and strains with a C57BL/6 background. *Contemp Top Lab Anim Sci* 44: 18-21.
9. Mader JR, Mason MA, Bale LK, Gades NM, Conover CA (2010) The Association of Early Dietary Supplementation with Vitamin E with the Incidence of Ulcerative Dermatitis in Mice on a C57BL/6 Background: Diet and Ulcerative Dermatitis in Mice. *Scand J Lab Anim Sci* 37: 253-259.
10. Williams LK, Csaki LS, Cantor RM, Reue K, Lawson GW (2012) Ulcerative dermatitis in C57BL/6 mice exhibits an oxidative stress response consistent with normal wound healing. *Comp Med* 62: 166-171.
11. Rodgers RJ, Cole JC (1993) Influence of social isolation, gender, strain, and prior novelty on plus-maze behavior in mice. *Physiol Behav* 54: 729-736.
12. Voikar V, Polus A, Vasar E, Rauvala H (2005) Long-term individual housing in C57BL/6J and DBA/2 mice: assessment of behavioral consequences. *Genes Brain Behav* 4: 240-252.
13. Perkins SN, Hursting SD, Phang JM, Haines DC (1998) Calorie restriction reduces ulcerative dermatitis and infection-related mortality in p53-deficient and wild-type mice. *J Invest Dermatol* 111: 292-296.
14. Dainiak N (2002) Hematologic consequences of exposure to ionizing radiation. *Exp Hematol* 30: 513-528.
15. Raimon D, Robert D (2009) Principles of bone marrow transplantation (BMT): Providing optimal veterinary and husbandry care to irradiated mice in BMT studies. *J Am Assoc Lab Anim Sci* 48: 11-22.