

Case Report

Open Access

Basosquamous Carcinoma Treated with Excision followed by Full-Thickness Skin Graft

Puguh Riyanto*

Department of Dermatology and Venereology, Faculty of Medicine, Diponegoro University/Kariadi Hospital, Indonesia

*Corresponding author: Puguh Riyanto, Department of Dermatology and Venereology, Faculty of Medicine, Diponegoro University/Kariadi Hospital, Dr Soetomo Street 18, Semarang City, Central Java, Indonesia Semarang, Indonesia, Tel: 0816650792; E-mail: Puguhungaran@gmail.com

Received date: March 21, 2017; Accepted date: March 31, 2017; Published date: March 31, 2017

Copyright: © 2017 Riyanto P. This is an open-access article distributed under the terms of the Creative Commons Attribution License, which permits unrestricted use, distribution, and reproduction in any medium, provided the original author and source are credited.

Abstract

Basosquamous carcinoma (BC) is a malignancy of the skin that rarely happens with histopathological picture shows basal cell carcinoma (BCC) and squamous cell carcinoma (SCC). Diagnosis basosquamous carcinoma (BC) is made by histopathology. The history and clinical picture basosquamous look like basal cell carcinoma. A woman, aged 51 years with a chief complaint that there are ulcers on the nose, shallow, diameter is ± 4 cm, demarcated, irregular, blackish brown colour, erythematous edge, no bleeding, rough surface, uneven, hard, no tenderness. Histopathological examination showed epidermal atrophy, looked pearl horn, cells oval, partially keratinized. Excision accompanied by full-thickness skin graft.

Keywords: Basosquamous carcinoma; Full-thickness skin graft

Introduction

Basosquamous carcinoma (BC) is a malignancy of the skin that rarely happens with histopathological picture shows basal cell carcinoma (BCC) and squamous cell carcinoma (SCC) [1]. Some experts believe that the disease is a variant of BCC [1,2]. However, some studies indicate that biologically more similar BCC than SCC. Basosquamous carcinoma also more aggressive, destructive, more commonly metastasize, and post-therapy recurrence rate is also more tinggi [1,3]. Synonyms BC are a basal cell carcinoma with squamous metaplasia [4]. Therapeutic options in the facial skin malignancies is excision followed by full-thickness skin graft [1].

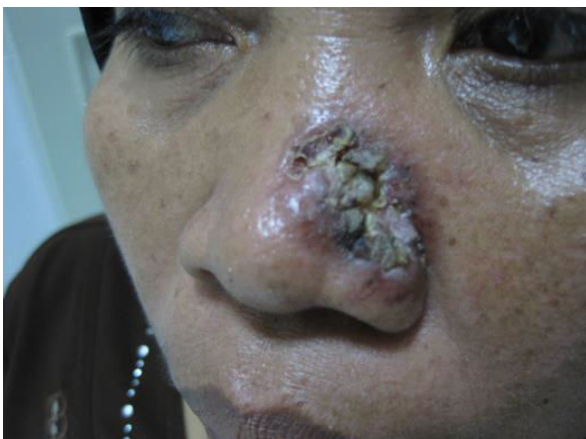

Figure1: BC shallow, ± 4 cm diameter, demarcated, irregular, blackish brown colour, erythematous edge, no bleeding.

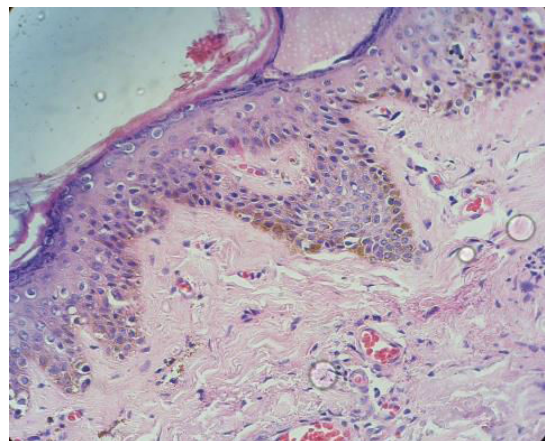


Figure 2: Epidermal atrophy, looked pearl horn, cells oval, partially keratinized.

Case Report

A woman, aged 51 years with a chief complaint that there are ulcers on the nose. History of this disease is approximately 3 years ago with raised nodule. Patients complain of blackish like a small mole on the nose, sometimes itchy, not easy bleeding, no pain, and often scratched by the patient to bleed and cause injuries. Moles are widening, and develop into such ulcers, blackish colour, sometimes itchy, bleed easily when scratched and ulcers that increase in width. These ulcers shallow, ± 4 cm diameter, demarcated, irregular, blackish brown colour, erythematous edge, no bleeding. Palpation rough surface, uneven, hard, no tenderness (Figure 1). Results of histopathological examination showed epidermal atrophy, looked pearl horn, cells oval, partially keratinized, supporting the diagnosis of BC (Figure 2). Excision accompanied by full-thickness skin graft on a tumour in his nose (Figure 3).

Discussion

Diagnosis BC is established based on histopathological examination. The history and clinical picture BC looks like BCC. The incidence increases with age and is more common in men than women. Several studies in Indonesia showed that the incidence in women more often than men. Research in Semarang Indonesia mentioned that in 5 years (1998-2002) 54 cases of BCC were found, which consisted of 36 women (66.7%) and 18 men (33.3%) [5]. Pathogenesis depends on several factors, including genetics, sunlight, carcinogens, chronic skin damage, exposure to the drug, and other factors [6].

In the last few years it has been discovered that gene nevroid basal cell carcinoma syndrome is located on chromosome 9q22 [3]. Mutations in these genes have been identified in sporadic basal cell

carcinoma. Fair skin that contains very little melanin is also a risk factor. Extrinsic risk factors mainly happen to BC upon exposure to sunlight. Exposure to sunlight after the age of 20 years can trigger the process of carcinogenesis manifestations which will appear 40-60 years later [7]. Besides artificial radiation such as phototherapy and photochemotherapy is also a pathogenetic factor. Chronic exposure to inorganic arsenic components that contaminate well water can trigger carcinoma 10-30 years later, although it is not exposed to sunlight. Cancer can occur on damaged skin such as scarring caused by immunization, trauma, varicella, burns and tattoos. Chronic ulcers such as severe stasis dermatitis can develop into BC. Nitrogen mustard used in the topical treatment of cutaneous T-cell lymphoma, PUVA is used in the treatment of psoriasis and other dermatoses, especially in patients who received the therapy time, this will increase the risk for BC.

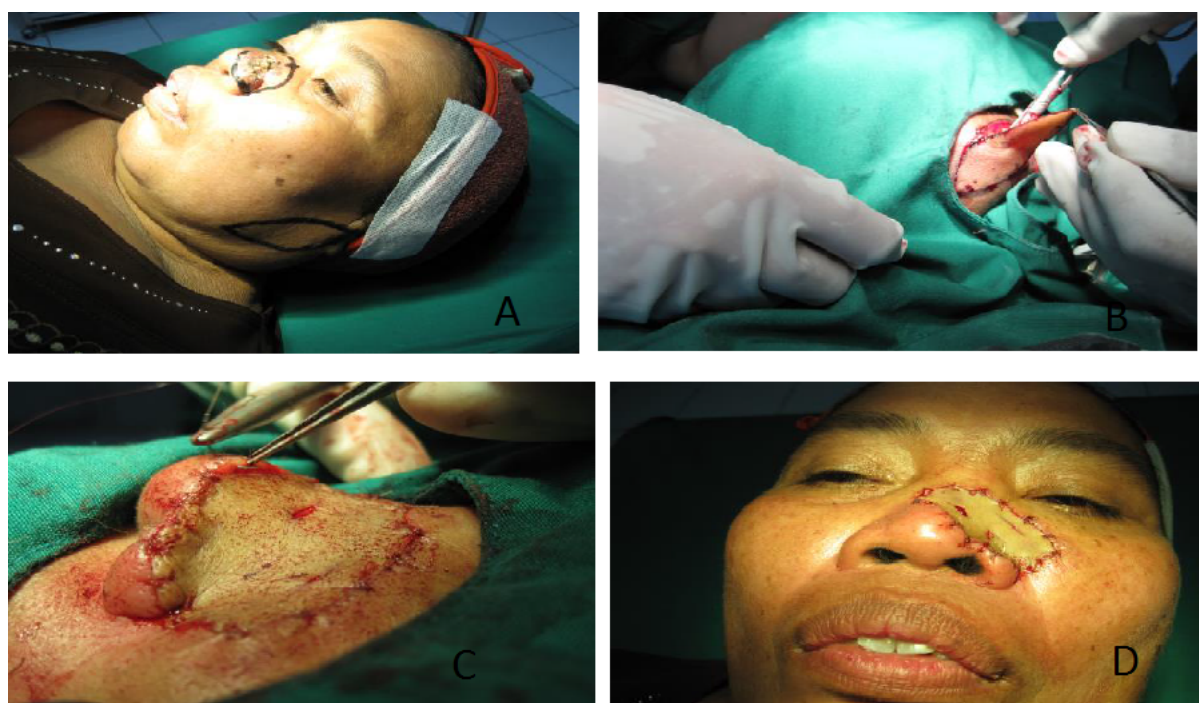

Figure 3: Excision followed by full-thickness skin graft. (A) Mapping performed on the recipient area in the nose that will excision with a limit of 5 mm from the edge of the lesion and the donor area in the left submandibular region for full-thickness skin graft. (B) Excision appropriate mapping, tumor tissue removed. (C,D) Placed on a donor tissue recipient area, then do the sewing thread is interrupted simple monocryl 5-0 suture.

Patients who are immunosuppressed have a substantial risk for the occurrence of BC, but immunologic factors that certainly could not be determined. Factors that affect the incidence of carcinoma in these patients suspected of exposure rays of sunlight continuously for several decades earlier [7,8]. Basosquamous carcinoma can arise in all places, but most often in areas exposed to sunlight such as the ala, columella, nasal septum and the edges, sulcus nasolabial, upper lip, ear front, sulcus pre and post aurikular, canthus medial, and limit petals eyes, scalp hair and forehead, all of this area is referred to as zone H [5,9]. This carcinoma can also occur in regional body, nipples, penis, scrotum, vulva and perianal area. Tumors never grow on the surface of mucosa [6]. Complaints are usually asymptomatic but can sometimes be found as itching, a little discomfort from inflammation or

secondary infections [9]. Lesions usually grows as a small lump that gradually increase in size, with ulceration in the middle and edges rising. The surface of the tumor is usually smooth but sometimes coarse, hyperchromatic or crusted, and found teleangiectasi, and easy bleeding from mild traumatic [3,10]. Basosquamous carcinoma has several variants form noduloulseratif, pigmented, superficial, morphoea and fibroepitelioma [1,3,11,12]. Histopathologic picture in this patient skin preparation nose showed epidermal atrophy, looked pearl horn, cells oval, partly keratinized. According to literature basosquamous carcinoma histopathological picture is composed of basaloid cells and squamoid but still retains the typical organization of BCC [1,13]. In this case excision therapy followed by full-thickness skin graft was done because of the location and extent of the lesion,

wherein only when excision alone, it will cause an asymmetrical skin, which will be interested and give cosmetically ugly result [14,15]. Therapy which was administered to this patient is excision followed by full-thickness skin graft. The goal of therapy of skin carcinoma is the eradication of the entire tumor perfectly up healing, both clinically and cosmetically [1,6,12]. In determining the method of treatment in carcinoma of the skin, a lot of things that must be considered depending on the characteristics of tumor sufferers, the condition of the patient, and facilities and surgeons available. Patient factors to consider are age, history of other diseases, psychological factors and medical history. Tumor factors that must be considered is the type of tumor, size, location, nature of growth and whether primary or recurrent tumor. Surgical excision with or without skin graft or flap continued to give a cure rate of about 90% and cosmetically satisfying. Limit excision of lesions 3-5 mm is recommended to achieve the best cure rate that also provides good cosmetical results [16]. Split-thickness skin graft is composed of the entire epidermis and dermis as well as some partial thickness or without adnexal structures [8,17]. Full-thickness skin graft is often used to repair abnormalities of reconstructive surgery as well as the removal of skin cancer and can give good results in terms of color, thickness and texture. Defects in the nose, the lower eyelid and ear are difficult for primary closing with FTSG [17-19].

Conclusion

Basosquamous carcinoma is a malignancy of the skin that rarely happens with histopathological picture that shows basal cell carcinoma and squamous cell carcinoma. Therapeutic treatment is excision followed by full-thickness skin graft.

References

1. Lang PG, Maize JC Sr (2005) Basal Cell Carcinoma. In: Riegel DS, Friedman RJ, Cancer of the Skin. Elsevier, China, pp. 101-125.
2. Martin RC, Edwards MJ, Cawte TG, Sewell CL, McMasters KM (2000) Basosquamous carcinoma: analysis of prognostic factor influencing recurrent. *Cancer* 88: 1365-1369.
3. Potent F, Lundeberg J (2003) Principles of Tumor biology and pathogenesis of BCCs and SCC. In: Bologna JL. *Dermatology*. Mosby, Spain, pp. 1663-1676.
4. Braun-Falco O, Plewig G, Wolff H, Winkelmann RK (2000) Malignant epithelial tumors. In: *Dermatology* (2nded), Springer-Verlag, Berlin, pp. 1463-1489.
5. MacKie RM, Quinn G (2004) Non Melanoma skin cancer and other epidermal skin tumours. In: Burns T. *Rook's Textbook of dermatology*. Oxford Blackwell Publishing, pp: 1-50
6. Carucci JA, Leffell DJ, Fitzgerald DA (2008) Basal cell carcinoma. In: Wolf K, Gold Smith LA, Katz SI, Gilchrist BA, Paller AS, Leffell DJ. *Fitzpatrick Dermatology in general medicine* (7thed), Mc Graw-Hill Book company, New York, pp: 1036-1042.
7. Emmet AJJ (1991) Basal Cell Carcinoma. In: Emmet AJJ, O'Rourke MG, eds. *Malignant skin tumor* (2nded). Churchill-Livingstone, Edinburgh, pp.109-141.
8. Spencer JM (2002) Basal cell carcinoma. In: Lebowitz M, Heymann WR, Jones JB, Coulson I, eds. *Treatment of skin disease: comprehensive therapeutic strategies*. Mosby, London, pp. 78-83.
9. Christensen DR, Arpe CJ, Whitaker DC (2005) Skin grafting. In: Robinson JK, Hankey CW, Sengelman RD, Siegel DM. *Surgery of the skin, Procedural Dermatology*. Elsevier Mosby Inc, Spain, pp. 365-380.
10. Stulberg DL, Crandell B, Fawcett RS (2004) Diagnosis and treatment of basal cell and squamous cell carcinomas. *Am Fam Physician* 70: 1481-1488.
11. Thomas DJ, King AR, Peat BG (2003) Excision margin for non melanotic skin cancer. *Plast Reconstr Surg* 112: 57-63.
12. Jiang SB, Szyfelbein K (2005) Pathology: Basal cell carcinoma.
13. Kuriakose MA (2004) Basal cell carcinoma of the skin.
14. Kirkham N (2005) Tumor and cysts of the epidermis. In: Elder DE, Elenitsas R, Johnson Jr. BL, Murphy GF, eds. *Lever's histopathology of the skin* (9thed) Lippincott William & Wilkins, Philadelphia, pp. 622-634.
15. Del Rosso ID, Siegel RJ (1994) Management of basal cell carcinoma. In: Wheeland RG. *Cutaneous Surgery* (1sted) WB Saunders Company, Philadelphia, pp: 731-751.
16. Hayes CM, Whitaker DC (1996) Surgical treatment of malignant lesion. In: Lask GP, Moy RL, eds. *Principles and technique of cutaneous surgery*, Mc Graw-Hill, New York, pp. 235-247.
17. Moy RL, Taheri DP, Ostad A (1999) Practical management of skin cancer. China, Lippincott-Raven, pp: 73-105.
18. Wanner M, Adams C, Rutner D (2007) Skin grafts. In: Rohrer TE, Cook JL, Nguyen TH, Mallette JR. *Flaps and graft. Dermatology Surgery*, Saunders, USA, Chapter 9.
19. Trent JT, Krisner RS (2003) Skin grafting. In: Nouri K, Leal-Khoury S. *Techniques in Dermatology surgery*. Mosby, London, pp. 153-160.