

Bandeiraea Simplicifolia Isolectin B4 Binds Mast Cells in Human Skin and this Latter Binding is Up-Regulated in Patients with Atopic Dermatitis and Stinging

Solbritt Lonne-Rahm^{1*}, Husameldin El-Nour¹ and Hakan Aldskogius²

¹Dermatology and Venereology Unit, Department of Medicine, Karolinska University Hospital, Solna and Karolinska Institutet, Stockholm, Sweden

²Department of Neuroscience, Uppsala University Biomedical Center, Uppsala, Sweden

Abstract

The causes of sensitive skin, a common problem in patients with acne rosacea or atopic dermatitis, and even in individuals without obvious skin disease, remain unclear. The density of nerve fibers, levels of neuropeptides as well as the nature and number of mast cells may play a role in this connection. Unmyelinated nociceptive neurons mediate most of the sensation from the skin, and a large part of these neurons are characterized by their ability to bind the lectin *Bandeiraea simplicifolia isolectin B4* (IB4). We therefore, examined whether the distribution and extent of IB4-labeling is modified in patients with enhanced skin sensitivity compared to controls. We used immunohistochemistry to label IB4-binding elements in skin biopsies from patients with atopic dermatitis. Of the 20 patients with atopic dermatitis subjected to the stinger test, 11 were stinger-positive and 9 stinger-negative. Stinger-positive papillary dermis contained a significantly larger number of IB4 binding cells, which were shown by double staining for tryptase as well to be mast cells. Binding of IB4 was also detected on dermal nerves associated with adnexa structures in the stratum corneum and on keratinocytes.

Since IB4 binds to specific carbohydrate moieties, the increased binding of IB4 by mast cells indicates that alterations in their glycoprotein composition may play a pathophysiological role in connection with stinging.

Keywords: Atopic dermatitis; Stinging; Lectin binding; Mast cells; Nerves

Introduction

Subjective cutaneous irritation such as tingling, burning or other forms of discomfort is a common problem. 40-50% of the women in the USA, Europe and Japan experience a sensitive skin [1], with symptoms ranging from visible signs of irritation (e.g., erythema and scaling) to more subjective neurosensory forms of discomfort (e.g., stinging, burning and itching) [2].

Increased cutaneous sensitivity without visible signs of inflammation is referred to as stinging [3]. Skin of this type is prone to over-react to external factors and is diagnosed on the basis of its response to lactic acid, the so called stinger test [4].

Although a variety of mechanisms and multi-factorial conditions, including certain environmental stimuli [5], have been proposed to be involved, the etiology of stinging remains unclear. Dryness indicates that the skin barrier may be impaired and predisposes for enhanced cutaneous sensitivity and vascular reactivity [6]. Stinging following application of potent steroid creams [7] or tacrolimus [8] has also been described. This condition is most common among patients with atopic dermatitis [9] or rosacea [10], but also occurs in individuals without obvious skin disease.

Previously, we demonstrated that areas of skin in patients with atopic dermatitis that exhibit a positive stinger test contain elevated number of nerve fibres that express vasoactive intestinal polypeptide (VIP) and of mast cells; a tendency towards a larger number of nerve fibers that express substance P, and a reduced levels of calcitonin gene polypeptide (CGRP)-related peptide in nerves fibers, compared to stinger- negative skin in these same patients [9]. Furthermore, pulsed dye laser treatment of rosacea diminishes both stinging and the number of nerve fibers in the affected areas of skin [11].

Sensory cutaneous sensory nerves are unmyelinated C-fibers, which produce a variety of neuromediators [12], as do mast cells, keratinocytes and eosinophil granulocytes, in close contact with these nerves in the dermis and epidermis [13]. Cutaneous mast cells preferentially localize in the vicinity of nerves, blood vessels and hair follicles and may be involved in a wide range of physiological functions [14]. These cells express a wide array of targets for various immunomodulating ligands on their surface and are implicated in several cutaneous disorders. For example, elevated numbers of mast cells are present in lichenified eczematous skin [2].

Bandeiraea simplicifolia isolectin B4 (IB4) is commonly employed for histochemical labeling of alpha-D-galactopyranosyl groups in cellular and basement membranes [15]. IB4 labeling is prominent on the surface of differentiating epidermal keratinocytes [16], as they leave the basal cell layer [17]. Moreover IB4 binds specifically to a subset of unmyelinated primary sensory neurons [18] that signal nociceptive and thermoceptive information from the skin.

These sensory neurons that bind IB4 project, along with sensory neurons expressing substance P and calcitonin gene-related peptide (CGRP), to the superficial laminae of the spinal cord dorsal horn.

***Corresponding author:** Solbritt Lonne-Rahm, Dermatology and Venereology Unit, Department of Medicine, Karolinska University Hospital, Solna, S-171 76 Stockholm, Sweden, E-mail: sol-britt.lonne-rahm@karolinska.se

Received May 30, 2012; **Accepted** September 07, 2012; **Published** September 14, 2012

Citation: Lonne-Rahm S, El-Nour H, Aldskogius H (2012) *Bandeiraea Simplicifolia Isolectin B4* Binds Mast Cells in Human Skin and this Latter Binding is Up-Regulated in Patients with Atopic Dermatitis and Stinging. J Clin Exp Dermatol Res 3:156. doi:10.4172/2155-9554.1000156

Copyright: © 2012 Lonne-Rahm S, et al. This is an open-access article distributed under the terms of the Creative Commons Attribution License, which permits unrestricted use, distribution, and reproduction in any medium, provided the original author and source are credited.

However, the IB4-binding neurons exhibit longer action potentials and process nociceptive stimuli via different mechanisms than unmyelinated peptidergic sensory neurons [19]. Since IB4-binding neurons appear to play a major role in processing nociceptive information, (in particular in the initial signaling response to acute nociceptive stimuli), as well as in the plasticity of reactions to pain [20], these neurons may be involved in stinging.

Here, we have examined immunohistochemically the binding of IB4 in the skin of stinger-positive and -negative patients with atopic dermatitis. Somewhat unexpectedly, this binding was localized almost exclusively to mast cells, dermal nerves associated with adnexa structures, the stratum corneum and keratinocytes.

Patients and Methods

Patients

20 Caucasian female patients (mean age=41 range 18-58 years) referred to our neurocutaneous unit for moderate-to -severe atopic dermatitis (defined according to the criteria proposed by Hanifin and Rajka [21]) were included in the present investigation. All patients had skin of type II-III and experienced increased sensitivity. Despite this wide range in the stinger-positive individuals all had the same problems, regardless of age. When their response to lactic acid was examined [22], 11 (55%) of the patients proved to be stinger-positive, with a mean score of 6.5 (range 5-9, whereas 9 (45%) were negative, with a mean score of 0.3 (range 0-2). None of the patients had lesions in the areas of the face subjected to the stinger test. This study was pre-approved by The Regional Ethics Review Board.

The cutaneous response to lactic acid; the stinger test

The facial areas beneath the eyes were cleaned with soap (applied with a soft paper towel and water), rinsed thoroughly with water, and then patted dry. Thereafter, sweating was induced by exposure to a commercial facial sauna (Silhouet-Tone 50126, Montréal, Canada) for 15 minutes. Subsequently 5% lactic acid in water was applied (with a swab using a gentle circular rubbing motion) to one side of the cheek (from beside the upper lip and upwards) and, as a placebo, water alone was applied in the same manner to the opposite cheek. 2, 4 and 5 minutes later the subjects were asked to describe the occurrence and intensity of any sensations, in the treated skin according to the following scale 0=none, 1=slight, 2=moderate, 3=severe. If the cumulative score of the scale was 3 or greater, the subject was designated as a "stinger".

None of the stinger- positive patients experienced any reaction to water alone.

Skin biopsies

Following injection of lidocaine skin biopsies 3 mm in diameter were taken from the nasolabial fold, in the stinger-positive area, and immediately fixed in phosphate-buffered 4% formalin (v/v) containing 0.2% picric acid (w/v) at 4°C for 2 h. These tissue samples were subsequently rinsed in cold 0.1 M Sorensen's phosphate-buffered saline (PBS) supplemented with 10% sucrose (4°C) for at least 48 h, snap frozen and stored at -70°C until further processing.

Immunohistochemistry and microscopical analysis

14 µm-thick sections were cut on a Ditté's cryostat, placed on coded slides, which were then rinsed in PBS. A blocking solution (1% bovine serum albumin (w/v), 0.3% Triton X-100, and 0.1% sodium azide in PBS) was placed gently on top of each section, followed by incubation

for 1 h at room temperature. After removing this solution, the sections were incubated with *Bandeiraea simplicifolia isolectin B4* (IB4) (10 µg/ml solution, L-1104, Vector, Burlingame, CA, USA) overnight at 4°C in a humid chamber. After rinsing in PBS, the sections were incubated for 40 min at room temperature with a polyclonal goat antibody directed against IB4 (AS-2104, 1:1,000; Vector) and thereafter, again washed in PBS three times. Finally the primary antibodies were visualized by incubating the sections with fluorescein Cy2 conjugated anti-goat IgG (1:2,000; Amersham, Biotech, Uppsala, Sweden), for 40 min at room temperature.

Double staining

Tryptase was utilized as a marker for mast cells. Double-labeling was performed by incubation with IB4 and then with the goat polyclonal antibody against IB4 in combination with monoclonal mouse antibodies against tryptase (1:1,000 Chemicon, Temecula, CA, USA). Following incubation with anti-IB4 antibody, a secondary biotinylated antibody was incubated followed by Texas Red (SA-5006, 1:5,000; Vector). Immunolabeling for tryptase was visualized by incubating the sections with FITC-conjugated rabbit anti-mouse IgG (F0261, 1:40; Dako, Glostrup, Denmark). All slides were rinsed in PBS, and mounted with glycerol/gelatine (Merck, Darmstadt, Germany).

As a positive control for IB4 immunolabeling we processed cryosections from human spinal ganglion in the same manner as those from the skin biopsies. As negative controls designed to detect unspecific binding, the primary antibody against IB4 was omitted, the IB4 was incubated without the anti-IB4 antibody or the latter was incubated without IB4. All negative controls resulted in an abolished signal.

The slides were examined under a Nikon epifluorescence microscope (Eclipse E800, Yokohama, Japan), viewing FITC fluorescence with an excitation filter at 465-495 nm, and Texas Red fluorescence with an excitation filter at 540-580 nm. All slides were coded prior to being examined in a blinded manner by the same investigator (SLR). Labeled structures were counted in the entire epidermis and papillary dermis on two slides from each biopsy areas 70 µm apart in each section and the averages was calculated.

The results were recorded with a video camera (Nikon digital camera DXM 1200) attached to the fluorescence microscope and connected to a personal computer. A confocal microscope Leica TCS SP5 (Leica Microsystems, Wetzlar, Germany) was also used to study in more detail the cellular localization of immunolabeling.

Statistical Analysis

For statistical analysis the Mann-Whitney U test was employed with a p-value of <0.05 being considered statistically significant.

Results

Sections from human spinal ganglion, prepared in the same manner as those from the skin biopsies, and utilized as a positive control for IB4 demonstrated abundant labeling (Figure 1a). No labeling was observed in our negative controls (Figure 1b). IB4 immunoreactivity was observed in the epidermis (stratum corneum), acrosyringium (Figure 2), and sebaceous glands. A diffuse epidermal labeling was present in the stratum corneum in 9 of the patients, whereas in 7 of the other patient labeling was present throughout 10% of the epidermal thickness. In addition, this binding occurred across 20% of the epidermal thickness in two patients, 15% in one and 50% in another.

However, very few epidermal nerve fibers were labeled with IB4, and no difference was observed in this regard between stinger positive and stinger negative patients.

In the dermis IB4-labeling was observed in endothelial cells in the blood vessels, in nerve fibers in the vicinity of the hair follicles and sebaceous glands, as well as in mononuclear cells (Figure 2). Counts of dermal nerve fiber profiles revealed no difference between stinger positive and stinger negative patients. However, significantly larger numbers of mononuclear cells were IB4-positive in stinger-positive (48 ± 29 ; mean \pm SD) than in stinger-negative patients (17 ± 18 ; $p < 0.01$). By double labeling with tryptase, we identified all the IB4-positive cells in the dermis as mast cells (Figures 3a-3c). Confocal microscopy revealed that IB4 expression in mast cells was localized in the cytoplasm (Figure 4).

Discussion

Our major finding is that IB4 binds to mast cells and that a significantly greater numbers of IB4-binding cells are present in the skin of stinger-positive compared to stinger-negative patients with atopic dermatitis.

IB4, a well established marker for a non-peptidergic subpopulation of unmyelinated cutaneous nerve fibers, binds to nerve fibers in the skin of numerous mammalian species [23], including man. Here we observed IB4-binding nerve fibers in the vicinity of hair follicles and

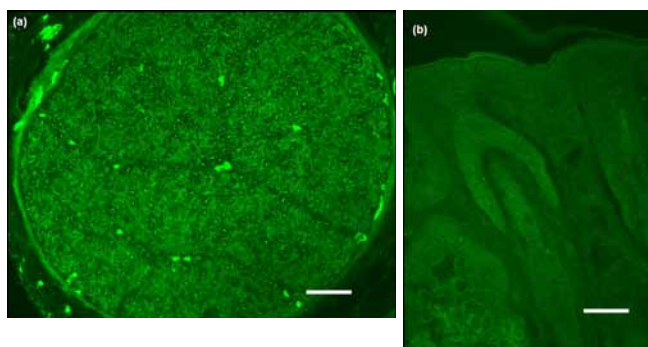


Figure 1: (a) Positive control photomicrograph showing immunoreactivity in human spinal ganglion. (b) Negative control showing abolished staining after incubation with the primary antibody without IB4. Scale bars 40 μ m.

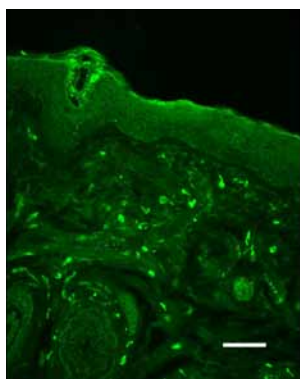


Figure 2: IB4-labeling in the facial skin of a stinger-positive patient. Immunoreactivity is seen on apical epidermis, adnexa structures and mononuclear cells in the dermis. Scale bar 40 μ m.

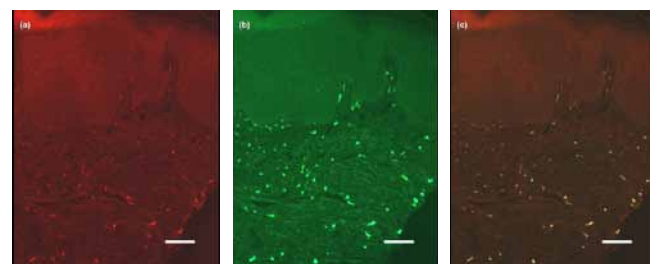


Figure 3: (a) Double staining pictures showing IB4-labeled mononuclear cells (red colour) in the upper region of the dermis. (b) The same cells being tryptase-positive mast cells (green). (c) Colocalization seen with the double filter (orange-yellowish colour). Scale bars 40 μ m.

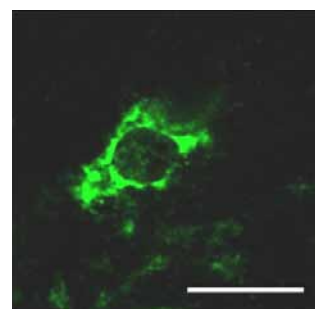


Figure 4: Confocal microscopy depicting the cytoplasmic expression of IB4 in a mast cell. Scale bar 25 μ m.

eccrine glands in the dermis, but only few such fibers in the epidermis. This finding differs dramatically from previous reports on the apparent abundant presence of IB4-positive nerve fibers in both the dermis and epidermis of rodent skin [24]. Moreover, we observed distinct labeling of endothelial cells, which are well known to bind this lectin, and the cells in control sections from rat spinal cord also exhibited pronounced binding of IB4. Thus, the sparse binding by cutaneous nerve fibers in our patients is unlikely to reflect methodological limitations, but rather indicates the absence or, at least, very low levels of the target carbohydrate moiety in their non-peptidergic, unmyelinated nerve fibers. At the same time, the rodent studies have been performed on hairy and glabrous body skin and not on facial skin, so a regional difference cannot be entirely excluded.

Previously, we demonstrated enhanced VIP and a reduced CGRP innervation in the skin of atopic dermatitis patients with stinging [9] and, in addition, that laser treatment of rosacea patients decreases the overall innervation of their dermis and epidermis [11]. Here, we examined the possible involvement of small non-peptidergic unmyelinated sensory neurons that bind IB4 [25] in stinging by comparing IB4-binding in the skin of stinger-positive and -negative patients. IB4-binding sensory neurons appear to play a key role in mediating nociceptive and thermoceptive sensory information [26] and their presence may be a prerequisite for the development of hyperalgesia induced by mechanical nerve injury [27]. However, we found no evidence of any change in the IB4-binding population of nerve fibers or endothelial cells in stinger-positive skin, but rather a significantly elevated number of IB4-positive mast cells. This increase in the number of mast cells agrees with our previous findings [9], but their IB4-binding was unexpected and appears not to have been observed before. Our finding thus suggests IB4-binding by mast cells, may be implicated in stinging.

Different pathogenetic mechanisms for the development of stinging have been proposed and this syndrome appears to be associated with fair skin [4]. Mast cells are highly specialized immune cells that play key roles in immediate-type hypersensitivity reactions [28]. Since IB4 binds specifically to terminal alpha-D-galactose, our present observations indicate that this carbohydrate moiety is expressed at a higher level by mast cells in stinger than in normal skin. This same carbohydrate moiety binds the beta 2 chain of laminin, as well as the light and medium subunits of neurofilaments [29]. Laminin 7 and 11, which both contain the beta 2 chain, are located in the basement membrane, at the dermal-epidermal junction [30]. Thus, enhanced interaction between mast cells and the extracellular matrix in the skin may contribute to stinging.

It is speculated that local nerve fibers could be triggered. Mast cells play a regulatory role by producing histamine, leukotrienes and prostaglandins [31]. In addition, these cells are considered to be important components in the action of nerve growth factor [32], which, like serotonin and histamine induces mast cell degranulation and is known to have a key role in the development of hyperalgesia following inflammatory injury [33].

Recently, the dry skin in which the barrier is disrupted was found to tend to be more sensitive on the cheeks and flexor forearms of patients with atopic dermatitis patients to electronic currents that stimulate A δ and C fibers than is the skin of healthy individuals [3]. Furthermore, the density of cutaneous nerves is higher in atopic skin than in corresponding regions of skin from healthy subjects [34,25]. In addition, it has been suggested that neuropeptides may be involved in the pathogenesis of atopic dermatitis [35], and contacts between mast cells and nerves are enhanced in the dermis of eczema patients [36]. Thus, activation of mast cells by a topical agent, such as an irritative allergen [22] could initiate interactions between mast cells and sensory neurons which result in cutaneous hypersensitivity, dysesthesia and pain. In this context, it is noteworthy that mast cell hyperplasia appears to be associated with increased excitability of IB4-binding visceral sensory neurons in an experimental model of irritable colon [37].

It has been proposed that neurogenic inflammation is caused by release of neuropeptides from unmyelinated sensory neurons in response to noxious stimuli [38]. One subpopulation of nociceptive fibers is activated by capsaicin, the ingredient in red peppers that produces a burning sensation when eaten or placed on the skin, through its action on the non-selective cation channel TRPV1 [39]. At the same time most IB4-binding neurons respond to capsazepine, an antagonist of this same channel [40]. Thus, triggering factors that act locally on the skin, may cause IB4-binding mast cells to activate sensory nerves, which subsequently mediate the sensation of stinging.

We observed varying extent of diffuse IB4-binding in most of the patients, but with no difference between stinger-positive and negative patients. Since this labeling was absent in our negative controls, and not present in all of the patients, we infer that IB4 is, indeed, able to bind to keratinocytes, but we have no clue to the possible significance of this binding. Keratinocytes also express TRPV1 [41], and may therefore have a role in stinging, which is not associated with modifications of IB4-binding

In conclusion, we have demonstrated here the previously unrecognized binding of IB4 to mast cells in human facial skin and, moreover that the number of IB4-binding mast cells is significantly higher in the sensitive skin of stinger patients than in normal skin. Thus, interaction of mast cells with sensory nerves and other components of

skin via a specific carbohydrate moiety may be of significance for the sensation of stinging.

Acknowledgements

This study was funded by a grant from the Finsen/Welander Foundation. We are grateful to Mrs. Anna-Lena Kastman for her excellent technical assistance.

References

1. Kligman AM, Sadiq I, Zhen Y, Crosby M (2006) Experimental studies on the nature of sensitive skin. *Skin Res Technol* 12: 217-222.
2. Weber S, Kruger-Krasagakes S, Grabbe J, Zuberbier T, Czarnetzki BM (1995) Mast cells. *Int J Dermatol* 34: 1-10.
3. Kobayashi H, Kikuchi K, Tsubono Y, Tagami H (2003) Measurement of electrical current perception threshold of sensory nerves for pruritus in atopic dermatitis patients and normal individuals with various degrees of mild damage to the stratum corneum. *Dermatology* 206: 204-211.
4. Drew LJ, Rohrer DK, Price MP, Blaver KE, Cockayne DA, et al. (2004) Acid-sensing ion channels ASIC2 and ASIC3 do not contribute to mechanically activated currents in mammalian sensory neurones. *J Physiol* 556: 691-710.
5. Berg M, Lonne-Rahm SB, Fischer T (1998) Patients with visual display unit-related facial symptoms are stingers. *Acta Derm Venereol* 78: 44-45.
6. Draeos ZD (1997) Sensitive skin: perceptions, evaluation, and treatment. *Am J Contact Dermat* 8: 67-78.
7. Kantor I, Cook PR, Cullen SI, Willis I, Gibson JR, et al. (1991) Double-blind bilateral paired comparison of 0.05% halobetasol propionate cream and its vehicle in patients with chronic atopic dermatitis and other eczematous dermatoses. *J Am Acad Dermatol* 25: 1184-1186.
8. Torok HM, Maas-Irslinger R, Slayton RM (2003) Clacortolone pivalate cream 0.1% used concomitantly with tacrolimus ointment 0.1% in atopic dermatitis. *Cutis* 72: 161-166.
9. Lonne-Rahm S, Berg M, Marin P, Nordlind K (2004) Atopic dermatitis, stinging, and effects of chronic stress: a pathocausal study. *J Am Acad Dermatol* 51: 899-905.
10. Lonne-Rahm SB, Fischer T, Berg M (1999) Stinging and rosacea. *Acta Derm Venereol* 79: 460-461.
11. Lonne-Rahm S, Nordlind K, Edström DW, Ros AM, Berg M (2004) Laser treatment of rosacea: a pathoetiological study. *Arch Dermatol* 140: 1345-1349.
12. Luger TA, Lotti T (1998) Neuropeptides: role in inflammatory skin diseases. *J Eur Acad Dermatol Venereol* 10: 207-211.
13. Raap U, Ikoma A, Kapp A (2006) Neurophysiology of pruritus. *Hautarzt* 57: 379-380, 382-384.
14. Maurer M, Theoharides T, Granstein RD, Bischoff SC, Bienenstock J, et al. (2003) What is the physiological function of mast cells? *Exp Dermatol* 12: 886-910.
15. Peters BP, Goldstein IJ (1979) The use of fluorescein-conjugated *Bandeiraea simplicifolia* B4-isolectin as a histochemical reagent for the detection of alpha-D-galactopyranosyl groups. Their occurrence in basement membranes. *Exp Cell Res* 120: 321-324.
16. Zieske JD, Bernstein IA (1983) Molecular changes in the cell surface of differentiating epidermal keratinocytes. *Curr Probl Dermatol* 11: 243-251.
17. Zieske JD, Bernstein IA (1982) Modification of cell surface glycoprotein: addition of fucosyl residues during epidermal differentiation. *J Cell Biol* 95: 626-631.
18. Thornton PD, Gerke MB, Plenderleith MB (2005) Histochemical localisation of a galactose-containing glycoconjugate expressed by sensory neurones innervating different peripheral tissues in the rat. *J Peripher Nerv Syst* 10: 47-57.
19. Stucky CL, Lewin GR (1999) Isolectin B(4)- positive and -negative nociceptors are functionally distinct. *J Neurosci* 19: 6497-6505.
20. Vulchanova L, Olson TH, Stone LS, Riedl MS, Elde R, et al. (2001) Cytotoxic targeting of isolectin IB4-binding sensory neurons. *Neuroscience* 108: 143-155.
21. Hanifin JM, Rajka G (1980) Diagnostic features of atopic dermatitis. *Acta Derm Venereol (Stockh)* 92: 44-47.

22. Bornstein J, Goldschmid N, Sabo E (2004) Hyperinnervation and mast cell activation may be used as histopathologic diagnostic criteria for vulvar vestibulitis. *Gynecol Obstet Invest* 58: 171-178.
23. Gerke MB, Plenderleith MB (2002) Analysis of the distribution of binding sites for the plant lectin *Bandeiraea simplicifolia* I-isolectin B4 on primary sensory neurones in seven mammalian species. *Anat Rec* 268: 105-114.
24. Haberberger RV, Bodenbenner M (2000) Immunohistochemical localization of muscarinic receptors (M2) in the rat skin. *Cell Tissue Res* 300: 389-396.
25. Urashima R, Mihara M (1998) Cutaneous nerves in atopic dermatitis. A histological, immunohistochemical and electron microscopic study. *Virchows Arch* 432: 363-370.
26. Albers KM, Woodbury CJ, Ritter AM, Davis BM, Koerber HR (2006) Glial cell-line-derived neurotrophic factor expression in skin alters the mechanical sensitivity of cutaneous nociceptors. *J Neurosci* 15: 2981-2990.
27. Chen CL, Broom DC, Liu Y, de Nooij JC, Li Z, et al. (2006) Runx1 determines nociceptive sensory neuron phenotype and is required for thermal and neuropathic pain. *Neuron* 49: 365-377.
28. Trautmann A, Toksoy A, Engelhardt E, Bröcker EB, Gillitzer R (2000) Mast cell involvement in normal human skin wound healing: expression of monocyte chemoattractant protein-1 is correlated with recruitment of mast cells which synthesize interleukin-4 in vivo. *J Pathol* 190: 100-106.
29. Fullmer JM, Riedl MS, Higgins L, Elde R (2004) Identification of some lectin IB4 binding proteins in rat dorsal root ganglia. *Neuroreport* 15: 1705-1709.
30. Aumailley M, Rousselle P (1999) Laminins of the dermo-epidermal junction. *Matrix Biol* 18: 19-28.
31. Liebich HG (1985) Functional morphology of stomach secretions. *Tierarztl Prax* 13: 455-469.
32. Shu XQ, Mendell LM (1999) Neurotrophins and hyperalgesia. *Proc Natl Acad Sci U S A* 96: 7693-7696.
33. Heppenstall PA, Lewin GR (2000) Neurotrophins, nociceptors and pain. *Curr Opin Anaesthesiol* 13: 573-576.
34. Tobin D, Nabarro G, Baart de la Faille H, van Vloten WA, van der Putte SC, et al. (1992) Increased number of immunoreactive nerve fibers in atopic dermatitis. *J Allergy Clin Immunol* 90: 613-622.
35. Ostlere LS, Cowen T, Rustin MH (1995) Neuropeptides in the skin of patients with atopic dermatitis. *Clin Exp Dermatol* 20: 462-467.
36. Harvima IT, Nilsson G, Naukkarinen A (2010) Role of mast cells and sensory nerves in skin inflammation. *G Ital Dermatol Venereol* 145: 195-204.
37. Qian AH, Liu XQ, Yao WY, Wang HY, Sun J, et al. (2009) Voltage-gated potassium channels in IB4-positive colonic sensory neurons mediate visceral hypersensitivity in the rat. *Am J Gastroenterol* 104: 2014-2027.
38. Järvikallio A, Harvima IT, Naukkarinen A (2003) Mast cells, nerves and neuropeptides in atopic dermatitis and nummular eczema. *Arch Dermatol Res* 295: 2-7.
39. Liu L, Simon SA (1994) A rapid capsaicin-activated current in rat trigeminal ganglion neurons. *Proc Natl Acad Sci U S A* 91: 738-741.
40. Liu M, Willmott NJ, Michael GJ, Priestley JV (2004) Differential pH and capsaicin responses of *Griffonia simplicifolia* IB4 (IB4)-positive and IB4-negative small sensory neurons. *Neuroscience* 127: 659-672.
41. Denda M, Tsutsumi M (2011) Roles of transient receptor potential proteins (TRPs) in epidermal keratinocytes. *Adv Exp Med Biol* 704: 847-860.