

Association between the Hanging Chin Sign and Mortality in Critically Ill Patients, a Retrospective Observational Study

Martinus TA Van Beijnen^{1*}, Maria J Zegers², Maarten H Van Leuken³, Cornelis PC De Jager² and Koen S Simons²

¹Department of Emergency Medicine, Jeroen Bosch Ziekenhuis, Postbus 90153, 5200 ME, 's-Hertogenbosch, the Netherlands

²Department of Intensive Care Medicine, Jeroen Bosch Ziekenhuis, Postbus 90153, 5200 ME, 's-Hertogenbosch, the Netherlands

³Department of Radiology, Jeroen Bosch Ziekenhuis, Postbus 90153, 5200 ME, 's-Hertogenbosch, the Netherlands

Abstract

Purpose: Define a new sign called the 'Hanging Chin Sign' (HCS) and discuss its clinical significance by evaluating if it is associated with poor hospital outcome in critically ill patients.

Methods: A retrospective observational study was performed. 331 adult patients presenting to the emergency department (ED) between 1 April 2011 and 31 July 2013, for which an Intensive Care Unit (ICU) physician was consulted and a supine chest X-ray was taken, were included. HCS was defined as radiological projection of the jawbone (os mandibula) over one or more ribs on the chest X-ray. In-hospital mortality, ICU admission and hospital length of stay (LOS) was compared between patients with and without a HCS.

Results: In patients presenting with a HCS, mortality was significantly higher. After case mix correction for age, gender, Glasgow Coma Scale and neurological pathology, there was no significant independent association between the HCS and mortality, ICU admission, hospital LOS, ICU LOS and APACHE II score.

Conclusion: Critically ill patients presenting to the ED with a HCS have higher in-hospital mortality. Although there is no independent association between the HCS and severity of disease, it can be used as an additional clinical marker for mortality and frailty.

Keywords: Hanging chin sign; X-ray; Critical illness; Mortality; Critical care; Frailty

Abbreviations

HCS: Hanging Chin Sign

ED: Emergency Department

ICU: Intensive Care Unit

LOS: Length of Stay

GCS: Glasgow Coma Scale

ICU-LOS: Intensive Care Unit Length of Stay

Introduction

In daily medical practice, taking a patients' history and a thorough physical examination is, despite of the availability of advanced diagnostic tools, still of major importance and the mainstay of establishing a diagnosis. Medical students and doctors are trained to search for specific signs and symptoms and recognize certain patterns learned from literature. Additionally, specific knowledge is obtained from senior staff members, attendants and nurses based on daily experience which is not learned from books. An example of this phenomenon can be seen in the novel 'the house of God', where the O sign (mouth lays open in a perfect geometric round shape) and the Q sign (O sign with tongue sticking to one side of the mouth) are described by Shem [1]. In our hospital, attention was attracted to chest X-ray exams of critically ill patients presenting to the ED. Due to weakness caused by severe illness and frailty, patients can have difficulty keeping their head up during the chest X-ray exam. As a result, part of the jaw bone can be seen on the chest X-ray.

In our daily practice, we call this radiological appearance the 'Hanging Chin Sign' (HCS). We also presume this to be associated with severe illness, frailty and poor hospital outcome, comparable to the O-sign and the Q-sign.[1] A literature search for the term 'hanging

chin sign' retrieved no results. The comparable dropped head syndrome (DHS) has only been described as a syndrome seen in patients with neuromuscular disease [2].

To investigate if the HCS is a useful clinical marker for poor hospital outcome, we studied if the presence of a HCS is associated with in-hospital mortality and severity of disease in severely ill patients presenting to the ED.

Materials and Methods

A retrospective observational study was performed. Patients were selected from a cohort of critically ill adult patients presenting to the ED of Jeroen Bosch Ziekenhuis, 's-Hertogenbosch, the Netherlands between 1 April 2011 and the 31 July 2013. This is a teaching hospital with approximately 40.000 patients presenting to the ED annually. Patients were defined as critically ill when consultation of an ICU physician was necessary, which was independently decided by the treating physician in the ED.

Patients were included if a chest X-ray in supine or Fowler's position was obtained in the ED at presentation [3]. As a result of patient position, chest X-rays were performed with anterior-posterior radiation [4]. The HCS was defined as radiological projection of the jawbone (os mandibula) over one or more ribs on a chest X-ray

***Corresponding author:** Martinus TA van Beijnen, Department of Emergency Medicine, Jeroen Bosch Ziekenhuis, Postbus 90153, 5200 ME, 's-Hertogenbosch, the Netherlands, Tel: +31735332700; E-mail: ma.v.beijnen@jzbz.nl

Received May 29, 2018; **Accepted** June 18, 2018; **Published** June 25, 2018

Citation: Van Beijnen MTA, Zegers MJ, Van Leuken MH, De Jager CPC, Simons KS (2018) Association between the Hanging Chin Sign and Mortality in Critically Ill Patients, a Retrospective Observational Study. Emergency Med 8: 369. doi:10.4172/2165-7548.1000369

Copyright: © 2018 Van Beijnen MTA, et al. This is an open-access article distributed under the terms of the Creative Commons Attribution License, which permits unrestricted use, distribution, and reproduction in any medium, provided the original author and source are credited.

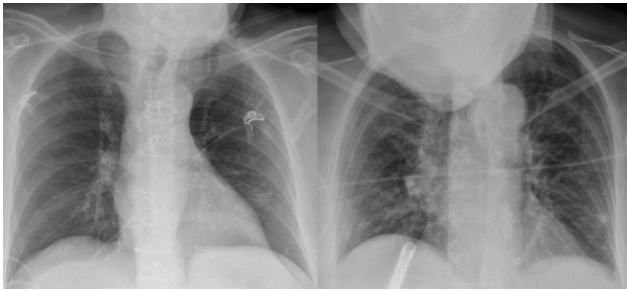


Figure 1: HCS image view.

performed as described (Figure 1).

Chest X-rays were retrospectively evaluated by an independent radiologist and scored for the presence of a HCS. The radiologist was blinded for patient outcomes.

Patients were excluded if the chest X-ray was of poor quality, for example when incomplete and/or non-perpendicular imaging was performed. Furthermore, patients with an endotracheal tube at time of X-ray were excluded, since these patients were generally sedated what would probably influence the presence of a HCS due to use of muscle relaxants.

Primary outcome was in-hospital mortality. Secondary outcomes were ICU admission and hospital LOS. The presence of a HCS was expressed dichotomously as present or not present. Baseline patient characteristics were collected as continuous and categorical data and were shown as absolute numbers with percentages or median with interquartile percentages where appropriate. Outcomes were compared between patients with and without a HCS using the χ^2 test and the Mann-Whitney U test. Furthermore, to calculate the odds ratio's of in-hospital mortality for patients with a HCS compared to patients without a HCS, an univariate logistic regression analysis was performed. To calculate the association between the HCS and hospital LOS a linear regression analysis was performed.

To perform a case mix correction for variables that could influence the ability to keep the head up during the chest X-ray, a multivariate logistic and linear regression analysis was conducted. Variables included were age (years), gender, Glasgow Coma Scale (GCS) and the presence of neurological pathology.

Finally, a subgroup was defined by patients admitted from the ED to the ICU. In this subgroup, in-hospital mortality, hospital LOS, ICU LOS and severity of disease, defined by the APACHE II score, was analysed.

A p-Value < 0.05 was considered statistically significant. Analyses were performed using SPSS Statistics

24.0. Necessity of informed consent was waived because of the retrospective observational design of the study. Ethical approval was obtained by the Medical Ethical Trial Committee Brabant.

Results

Patient characteristics

Between 1 April 2011 and 31 July 2013, 524 patients presented at the ED where an ICU physician was consulted and a supine chest X-ray was performed at presentation. One-hundred thirty-six (26%) patients were excluded because of poor quality chest X-ray. Fifty-seven (11%) patients were excluded because they were intubated at time of X-ray. Eventually, 331 patients were included in the study. Baseline

characteristics of the total study population and the ICU population are shown in Table 1.

In the total study population, 62 (18.7%) patients presented with a HCS. Patients with a HCS were significantly older compared to patients without a HCS (Table 1a). Furthermore, patients with a HCS did not present to the ED more often with neurological pathology.

Two-hundred thirty-five patients (71%) were admitted to the ICU. In these patients, 38 (16.2%) presented with a HCS. Also in this subgroup, patients with a HCS were significantly older (Table 1b).

Outcomes

Table 2 shows the outcomes of the total study population and the ICU population. In the total study population, in-hospital mortality was significantly higher in patients presenting with a HCS.

The unadjusted OR for in-hospital mortality was 2.00 (95% CI 1.10 to 3.63). After case mix correction using a multivariate logistic regression analysis for gender, age, GCS and neurological pathology, there was no significant higher risk of in-hospital mortality in patients with HCS compared to patients without a HCS (OR 1.09, 95% CI 0.52 to 2.30). There was no difference in ICU admission between patients with and without a HCS. Finally, hospital LOS was not significantly different between patients with and without a HCS and there was no association after case mix correction between the presence of a HCS and hospital LOS (p=0.91).

In patients admitted to the ICU, there was no difference in in-hospital mortality between patients with and without a HCS (Table 2a). The unadjusted OR for in-hospital mortality was 1.08 (95% C.I. 0.46 to 2.54). After case mix correction, there was no significant higher risk of in-hospital mortality in patients with HCS compared to patients without a HCS (OR 0.74 (95% CI 0.26 to 2.08)).

Furthermore, there was no significant difference in hospital LOS, ICU LOS or severity of disease as defined by APACHE II score between patients with and without a HCS (Table 2b). Finally, the HCS was not associated with hospital LOS (p=0.83), ICU-LOS (p=0.52) or severity of disease in patients admitted to the ICU (p=0.38).

Discussion

There are a lot of well-studied and described clinical signs to assess severity of illness, for example Cullen's sign (superficial oedema with bruising in the subcutaneous fatty tissue around the peri-umbilical region) and Grey Turner's sign (ecchymosis in the flank) in acute pancreatitis or the psoas sign (right lower quadrant pain with active hip flexion) and Rovsing's sign (pain in the right lower quadrant with palpation of the left lower quadrant) in acute appendicitis [5-7]. Also, radiological signs are used to identify disease and predict prognosis, like the Hampton hump (a shallow, wedge-shaped opacity in the periphery of the lung with its base against the pleural surface) and Westermarck's sign (sharp cut-off of pulmonary vessels with distal hypoperfusion in a segmental distribution within the lung) on a chest X-ray or CT-scan in a pulmonary embolus [8].

Additionally, in daily practice signs are used which are learned from the experience of senior attendants, nurses or supervisors. These signs are widely used to assess a patients' condition and outcome, however some are not studied of scientifically proven.

We observed that in severely ill and frail patients presenting to the ED sometimes the jawbone was visible on a chest X-ray, due to the inability to keep the head up. We called this the 'Hanging Chin Sign'. To

Table 1: Patient characteristics in the total study population (1a) and ICU population (1b).

1a: Total study population, N=331				
Variable		HCS (%) (N=62)	No HCS (%) (N=269)	p-value
Gender	Male	36 (58.1)	151 (56.1)	0.78
Age (years) (median, interquartile range)		71.5 (63.8-80.0)	64 (47.0-74.0)	< 0.001 *
Admission specialism	Other	51 (82.3)	174 (65.2)	0.030‡
	Surgery	9 (14.5)	69 (25.8)	
	Neurology	2 (3.2)	24 (9.0)	
Glascow Coma Scale (median, interquartile range)		14 (5.0-15.0)	14 (6.0-15.0)	>0.05
1b: ICU study population, N=235				
		HCS (%) (N=38)	No HCS (%) (N=197)	p-value
Gender	Male	25 (65.8)	107 (54.3)	0.19
Age (years) (median, interquartile range)		67.0 (61.0-75.3)	63.0 (47.0-73.0)	< 0.001 *
Admission specialism	Other	30 (78.9)	121 (62.1)	0.15
	Surgery	7 (18.4)	56 (28.7)	
	Neurology	1 (2.6)	18 (9.2)	
Glascow Coma Scale (median, interquartile range)		11.0 (4.0-15.0)	13 (6.0-15.0)	>0.05
Note: p* $p < 0.05$ using Mann-Whitney U test				
‡ $p < 0.05$ using χ^2 test				

Table 2: Outcomes in the total study population (2a) and ICU population (2b).

2a: Total study population, N=331			
Outcome	HCS (%) (N=62)	No HCS (%) (N=269)	p-value
In-hospital mortality	22 (35.5)	58 (21.6)	0.02 ‡
ICU admission	38 (61.3)	197 (73.2)	0.06
Hospital LOS (days) (median, interquartile range)	9 (3.8-16.3)	9 (4.0-16.0)	>0.05
2b: ICU study population, N=235			
	HCS (%) (N=38)	No HCS (%) (N=197)	p-value
In-hospital mortality	8 (21.1)	39 (19.8)	0.86
Hospital LOS (days) (median, interquartile range)	12.0 (6.0-17.3)	10 (6.0-18.0)	>0.05
ICU LOS (days) (median, interquartile range)	3.0 (2.0-5.0)	3.0 (2.0-5.8)	>0.05
APACHE II score (median, interquartile range)	19 (14.0-24.5)	19.0 (13.0-25.0)	>0.05

Note: ‡ $p < 0,05$ using a χ^2 test

see if this sign was of clinical importance, we investigated the relation of the HCS with hospital outcome.

First of all, we found that in-hospital mortality was significantly higher in patients with a HCS compared to patients without a HCS; mortality was more than 10% higher and the risk of mortality was twice as high. After case-mix correction for gender, age, GCS and the presence of neurological pathology, there was no independent association between the presence of a HCS and in-hospital mortality nor hospital LOS, ICU LOS and severity of disease measured by the APACHE score.

These results confirm our hypothesis that the presence of a HCS in critically ill patients is associated with poor prognosis. Although not an independent predictor for severity of disease, the HCS can be used as an additional marker for frailty and the risk of mortality. Indeed, patients with a HCS were significantly older and the fact that they are not able to keep their head up during the chest X-ray is indicative of general weakness. Apart from age, there were no significant differences in presumed risk factors for a HCS, such as level of consciousness in the ED or neurologic pathology.

Secondly, patients with a HCS were not more often admitted to the ICU. When they were admitted to the ICU, mortality and severity of disease were comparable between patients with and without a HCS. The fact that patients with a HCS were not more often admitted to the ICU could be due to the fact that patients with a HCS were too severely ill for ICU admission or died before ICU admission. Of the 62 patients presenting to the ED with a HCS, 24 were not admitted to the ICU. All of these 24 patients were too severely ill or were too frail due to extensive comorbidity to be admitted to the ICU and extensive treatment in the ICU was withheld. The age of these patients was comparable to patients admitted to the ICU. These results also suggest that the presence of a HCS is a sign of frailty and severe illness.

There are several limitations in this study, first this was a retrospective study using patient charts, which makes it difficult to recall missing data and interpret some results. Furthermore, the GCS was not always reported and the presence of neuromuscular diseases was not exactly defined. This could cause information bias. However since these are probably equally distributed over patients with and without a HCS, this does not appear to influence the results. Reinforcing this assumption, case-mix correction with and without GCS and neurological pathology did not change our results.

Finally, in patients not admitted to the ICU, severity of disease could not be defined since calculating the APACHE score in these patients was not retrospectively possible. Therefore, severe illness or critically ill patients were defined by the need of consultation of an ICU physician.

Conclusion

In conclusion, the HCS is a sign which is seen in daily practice in critically ill patients but has not been described and studied before. In this study, we showed that the presence of a HCS leads to higher in-hospital mortality and probably reflects weakness and frailty in critically ill patients. Although there is no independent association between the HCS and mortality or severity of disease, it can be used in daily practice as an additional clinical marker for frailty and poor in-hospital outcome.

Funding

This research did not receive any specific grant from funding agencies in the public, commercial, or not-for-profit sectors.

Financial/Nonfinancial Disclosures

None.

Conflict of Interest Statements

No conflicts exist for all authors.

References

1. Shem S (1978) House of God. Books and Media Reviews.
2. Sharan AD, Kaye D, Charles Malveaux WM, Riew KD (2012) Dropped head syndrome: Etiology and management. *J Am Acad Orthop Surg* 20: 766-774.
3. Fowler GR (1900) Diffuse septic peritonitis, with special reference to a new method of treatment, namely, the elevated head and trunk posture, to facilitate drainage into the pelvis, with a report of nine consecutive cases of recovery. *The Medical Record, New York* 57: 617-623.
4. Dol-Jansen J, Geers-van Gemeren S (1997) Radiodiagnostisch onderzoek. pp: 394-95.
5. Valette X, du Cheyron D (2015) Images in clinical medicine. cullen's and grey turner's signs in acute pancreatitis. *N Engl J Med* 24: 373.
6. Izbicki JR, Knoefel WT, Wilker DK, Mandelkow HK, Müller K, et al. (1992) Accurate diagnosis of acute appendicitis: A retrospective and prospective analysis of 686 patients. *Eur J Surg* 158: 227-231.
7. Rovsing NT (1907) Ein Beitrag zur diagnostik der Appendicitis und Typhlitis. *Zentralbl Chir* 34: 1257.
8. Worsley DF, Alavi A, Aronchick JM, Chen JT, Greenspan RH, et al. (1993) Chest radiographic findings in patients with acute pulmonary embolism: Observations from the PIOPED study. *Radiology* 189: 133-136.