

Assessment of the Prophylactic Activity of the Ethanolic Extract of *Momordica charantia* Leaves against Acetaminophen-Induced Liver Impairment in Wistar Rats

Abiola T^{*}, Akinyode OA, Oduwale R and Egbeolu O

Department of Chemical Sciences, Biochemistry Unit, College of Natural and Applied Sciences, Oduduwa University, Ipetumodu, Ile-Ife, Osun State, Nigeria

***Corresponding Author:** Abiola T, Department of Chemical Sciences, Biochemistry Unit, College of Natural and Applied Sciences, Oduduwa University, Ipetumodu, Ile-Ife, Osun State, Nigeria, Tel: +2348039152859; E-mail: debotem100@yahoo.com

Received Date: October 04, 2017; **Accepted Date:** October 17, 2017; **Published Date:** October 24, 2017

Copyright: ©2017 Abiola T, et al. This is an open-access article distributed under the terms of the Creative Commons Attribution License, which permits unrestricted use, distribution, and reproduction in any medium, provided the original author and source are credited.

Abstract

Background: Various parts of *M. charantia* have been reported to possess pharmacological properties against some diseases due to its phytochemicals constituents.

Aim: This research was aimed at assessing the prophylactic effect of the ethanol extract of *M. charantia* against acetaminophen-induced liver damage in Wistar rats.

Methodology: A total of sixteen rats were randomly divided into four groups with four rats in each group. The experiment spanned through fourteen days. Group 1 served as the control, group 2 received 1500 mg/kg per body weight (pbw) of acetaminophen orally throughout, group 3 received 250 mg/kg (pbw) of extract throughout while group 4 received 250 mg/kg (pbw) of extract for six days and thereafter was given 1500 mg/kg (pbw) acetaminophen orally from day 7 to day 14. The biochemical parameters of liver function- aspartate transaminase (AST), alanine transaminase (ALT), alkaline phosphatase (ALP), and protein levels were determined. In addition the following antioxidant parameters- reduced glutathione (GSH) and malondialdehyde (MDA) were also measured from the serum of experimental animals. Histopathological changes in the liver were also investigated.

Results: Results show that the oral pre-treatment with extract of *M. charantia* (250 mg/kg body weight) revealed significant ($P < 0.05$) reduction of serum activities of ALT, AST and ALP. Also, pre-treatment with the extract caused a significant ($P < 0.05$) increase in total protein and GSH level with a significant ($P < 0.05$) decrease in the MDA compared to the control group. Histopathological analysis confirmed the amelioration of liver damage and reduced laceration caused by acetaminophen.

Conclusion: This study substantiates the prophylactic activity of *M. charantia* leaf ethanol extract against liver impairment which might be attributed to some of its intrinsic phytochemical constituents which possess anti-oxidant activities.

Keywords: Prophylactic; Acetaminophen; *Momordica charantia*; Antioxidant; Hepatotoxicity

Introduction

The liver regulates the levels of most chemicals in the blood and is the main organ responsible for detoxification of drugs. It produces bile, distributes nutrients and produces urea- an excretory by-product [1]. The liver can become inflamed or impaired due to viruses or other non-infectious causes such as excess alcohol, drugs, allergic reactions [2]. Hepatotoxicity is associated with disturbances in various metabolic functions of the liver. Reactive oxygen species have been implicated in the initiation and progression of liver associated diseases which often results in tissue damage and pathological conditions *in vivo* [3,4]. Chemical toxins such as acetaminophen, carbon tetrachloride (CCl_4) are usually used to cause liver impairment for experimental studies *in vivo* [5,6].

Paracetamol, also known as acetaminophen when taken in excess induces damage of the hepatocytes and subsequently lipid

peroxidation with the formation of the intermediate oxidative product of paracetamol (N-acetyl P-benzoquinone imine) [7]. Despite recent advances in medicine, no effective drug has successfully prevented the progression of hepatic diseases and most often, these drugs often have stringent side effects and hence the dire need for a natural prophylactic agent that can protect against liver impairment as the liver is continually burdened with the task of detoxifying various xenobiotics and endogenous toxins. All-encompassing studies have shown that plant products with antioxidant activities are potent enough to prevent the oxidative stress induced liver pathologies due to specific interactions [8].

In the light of these, medicinal plants are being investigated to assess their pharmacotherapeutic properties because some of these plants contain various bioactive constituents which can act as natural prophylactic agents that can offer protection against certain ailments and diseases.

The plant *Momordica charantia* belongs to the Cucurbitaceae family and is popularly called bitter melon. Extracts from bitter melon have been found to possess antioxidant, antimicrobial and hypoglycemic

properties [9,10]. The presence of biologically active chemicals such as triterpenes, steroids etc. in *M. charantia* extracts are responsible for its medicinal properties. *M. charantia* leaves also contains considerable amounts of protein, carbohydrates, minerals and vitamins and hence the leaves have also been utilised as food [11]. Nonetheless, little is still known about the *in vivo* hepatoprotective activity of *M. charantia* and hence the aim of this study was to assess the *in vivo* hepatoprotective activity of the ethanolic extract of *M. charantia* leaves against acetaminophen-induced liver damage in Wistar rats.

Materials and Methods

Plant sample collection and identification

The leaves of *M. charantia* were obtained from Obada market, Ipetumodu, Osun State, Nigeria. The sample was identified and authenticated at the Department of Biological Sciences, Obafemi Awolowo University, Ile-Ife, Osun State Nigeria and was tagged with the voucher specimen number MC-3431.

Sample processing and extract preparation

The leaves of *M. charantia* were washed with tap water and then sun-dried for seven days before being blended into fine powder using an electric blender. 100 g of the powder was then weighed into a beaker and 1000 ml of ethanol was added to the weighed *M. charantia* powder and stirred gently. The solvent was removed by evaporation and the extract was concentrated using vacuum rotary evaporator.

Drugs and chemicals

Acetaminophen (500 mg) tablet of the brand Emzor was purchased from a licensed pharmacy outlet. Diagnostic kits for the determination of serum ALT, AST and ALP were purchased from Randox Laboratories (LTD), United Kingdom. Bovine serum albumin (BSA), Trichloro acetic acid (TCA), thiobarbituric acid (TBA), reduced glutathione (GSH), pyrophosphate, ethylene diamine tetra acetic acid disodium salt (EDTA), 5,5-dithiobis (2-nitrobenzoic acid) (DTNB), β nicotinamide adenine dinucleotide hydrogen (NADH) were obtained from Sigma Chemical (St. Louis, MO, USA). All other chemicals and reagents used were of analytical grade.

Phytochemical determination

Quantitative analysis for phytochemicals in the extract was carried out using standard procedures [12,13]. Saponin according to Obadoni and Ochuko [14]; alkaloid by Harborne [13], phenol by Harris [15] and flavonoids according to Bohm and Koupai – Abyazani [16].

Alkaloid determination: 5 g of the sample was weighed into a 250 ml beaker and 200 ml of 10% acetic acid in ethanol was added and covered and allowed to stand for 4 hours. This was filtered and the extract was concentrated on a water bath to one-quarter of the original volume. Concentrated ammonium hydroxide was added drop wise to the extract until the precipitation was complete. The whole solution was allowed to settle and the precipitated was collected and washed with dilute ammonium hydroxide and then filtered. The residue is the alkaloid, which was dried and weighed.

Determination of flavonoid: 10 g of the plant sample was extracted repeatedly with 100 ml of 80% aqueous methanol at room temperature. The whole solution was filtered through whatman filter paper No 42 (125 mm). The filtrate was later transferred into a crucible and

evaporated into dryness over a water bath and weighed to a constant weight.

Determination of total phenol: The fat free sample was boiled with 50 ml of ether for the extraction of the phenolic component for 15 minutes. 5 ml of the extract was pipetted into a 50 ml flask, then 10 ml of distilled water was added. 2 ml of ammonium hydroxide solution and 5 ml of concentrated amyl alcohol were also added. The sample was made up to mark and left to react for 30 minutes for colour development. This was measured at 505 nm.

Determination of saponin: The samples were ground and 20 g of each were put into a conical flask and 100 cm³ of 20% aqueous ethanol were added. The samples were heated over a hot water bath for 4 h with continuous stirring at about 55°C. The mixture was filtered and the residue re-extracted with another 200 ml 20% ethanol. The combined extracts were reduced to 40 ml over water bath at about 90°C. The concentrate was transferred into a 250 ml separating funnel and 20 ml of diethyl ether was added and shaken vigorously. The aqueous layer was recovered while the ether layer was discarded. The purification process was repeated. 60 ml of N-butanol was added. The combined N-butanol extracts were washed twice with 10 ml of 5% aqueous sodium chloride. The remaining solution was heated in a water bath. After evaporation the samples were dried in the oven to a constant weight; the saponin content was calculated as percentage.

Experimental design

Animals: A total of sixteen adult white Wistar albino rats weighing 80-140 g were used for the study. They were allowed to acclimatize under standard conditions for two weeks. The animals were kept in clean propylene cages and maintained under the standard laboratory condition for temperature (26 ± 2), humidity ($60 \pm 5\%$) and controlled environment (12:12 h light/dark cycle) and were allowed free access to standard pellet and water. All the experimental procedures were carried out in accordance to the guidelines of the Institutional Animal Ethics Committee (IAEC). All the ethical and humanity considerations as well as euthanasia of the animals were considered and performed.

Experimental design and treatment: The basis of the LD50 value of *M. charantia* determined from the acute toxicity studies has been reported [17]. After acclimatization for a period of two weeks, the animals were randomly divided into four groups with four rats in each group.

Group 1: served as normal control for 14 days

Group 2: (toxin control) were administered 1500 mg/kg per body weight of acetaminophen for 14 days.

Group 3: were orally given 250 mg/kg of *M. charantia* extract per body weight for 14 days

Group 4: were orally administered 250 mg/kg per body weight of extract from day 1 to day 6 and then given 1500 mg/kg body weight of acetaminophen from day 7 to day 14.

Assessment of hepatoprotective activity

Evaluation of biochemical parameters of liver function: At the end of the experimental period, animals were fasted overnight for 12 hours. The animals were sacrificed under light ether anaesthesia by cervical dislocation. Blood samples were collected by direct cardiac puncture. The serum was separated from the blood by centrifuging at 2500 rpm for 15 minutes and the activity of the level of the following biochemical

parameters of liver function (AST, ALT, ALP) were determined colorimetrically using standard reagent kits (Randox Laboratories, United Kingdom). AST and ALT was assayed for as described by Reitman and Frankel [18]; ALP by Wright [19]. The serum protein level was determined using biuret method as described by Gonall [20].

Determination of aspartate transaminase (AST): 10 µl of each sample was added to the bottom of the microplate wells. 50 µl of AST reagent mix was added to the wells and the mixture was incubated for 30 minutes at 37°C. 50 µl of 2, 4 dinitrophenylhydrazine (DNPH) was then added to each well and the plate was incubated at 37°C for 10 minutes. This was followed by the addition of 200 µl of 0.5M sodium hydroxide to each well after which the plate was incubated at 37°C for 5 minutes. The absorbance of each sample was measured at 510 nm and the activity of AST read from the standard curve.

Determination of alanine transaminase (ALT): 10 µl of each sample was added to the bottom of the microplate wells. 50 µl of ALT reagent mix was added to the wells and the mixture was incubated for 30 minutes at 37°C. 50 µl of 2, 4 dinitrophenylhydrazine (DNPH) was then added to each well and the plate was incubated at 37°C for 10 minutes. This was followed by the addition of 200 µl of 0.5M sodium hydroxide to each well after which the plate was incubated at 37°C for 5 minutes. The absorbance of each sample was measured at 510 nm and the activity of ALT read from the standard curve.

Determination of alkaline phosphatase (ALP): 5 µl of each sample was added to the bottom of the microplate wells. 30 µl of ALP reagent mix was added to the wells and the initial absorbance read. The mixture was incubated for 1 minute at 37°C and the absorbance of each sample was measured against blank at 405 nm.

Estimation of protein in samples: 1 ml of each sample was taken and 4 ml of biuret reagent was added to each and the mixture was allowed to stand at room temperature for 30 minutes. The absorbance was read at 540 nm against blank containing 1 ml of distilled water and 4 ml of biuret reagent. The protein content of samples was extrapolated from the standard protein curve.

Evaluation of serum antioxidant parameters malondialdehyde determination: Malondialdehyde (MDA), an index of lipid peroxidation was assayed for based on MDA reaction with thiobarbituric acid (TBA) as described by the method of Buege and Aust (1978). 1.0 ml of the supernatant was added to 2 ml of (1:1:1 ratio) TCA-TBA-HCl reagent (thiobarbituric acid 0.37%, 0.24N HCl and 15% TCA) tricarboxylic acid- thiobarbituric acid-hydrochloric acid reagent boiled at 100°C for 15 min, and allowed to cool. Flocculent materials were removed by centrifuging at 3000 rpm for 10 min. The supernatant was removed and the absorbance read at 532 nm against a blank. MDA was calculated using the molar extinction coefficient for MDATBA- complex of $1.56 \times 10^5 \text{ M}^{-1}\text{CM}^{-1}$.

Reduced glutathione (GSH) determination: The reduced glutathione (GSH) content of blood tissue as non-protein sulphhydryl was estimated according to the method described by Sedlak and Lindsay (1968). To the serum, 10% TCA was added, centrifuged. 1.0 ml of supernatant was treated with 0.5 ml of Ellmans reagent (19.8 mg of 5, 5-dithiobisnitro benzoic acid (DTNB) in 100 ml of 0.1% sodium nitrate) and 3.0 ml of phosphate buffer (0.2M, pH 8.0). The absorbance was read at 412 nm.

Histopathological study of the liver

A small segment of the liver tissue was taken and fixed in 10% formaldehyde. After several treatments for dehydration in alcohol, the tissue segment was cleared in xylene and embedded in paraffin. Sections having 4 µm thickness were cut and stained with haemotoxylin and eosin [21] and afterwards examined under a microscope.

Statistical analysis

The results were expressed as the Mean ± (SD) using one way analysis of variance (ANOVA), followed by the Dunnett post-hoc test and P<0.05 was considered statistically significant when compared to the hepatotoxic (acetaminophen) control.

Results

Phytochemical analysis: The result of the phytochemical analysis presented in Table 1 indicated the presence of certain plant bioactive compounds in the ethanol extract of *M. charantia*. Alkaloid was found to be the highest (28.2 mg/100 g) with phenol being the lowest (15.22 mg/100 g) of the phytochemicals analysed.

Alkaloids (mg/100 g)	Flavonoids (mg/100 g)	Phenol (mg/100 g)	Saponin (mg/100 g)
28.2 ± 0.45	18.68 ± 1.43	15.22 ± 0.42	23.21 ± 1.46

Table 1: Quantitative phytochemical analysis of *M. charantia* leaves (Values are Mean ± SD of triplicates determinations).

Effect of *M. charantia* extract on the serum levels of liver function markers

The results for the effect of *Momordica charantia* extract on serum biochemical parameters of liver function (Table 2). The levels of serum AST, ALT and ALP were markedly elevated and that of protein decreased in the hepatotoxic group given acetaminophen which indicated liver damage. However, there was a significant (P<0.05) decrease in the AST, ALT and ALP and a significant (P<0.05) increase in the protein levels of the rats pre-treated with extract of *M. charantia* (250 mg/kg) body weight as compared to the hepatotoxic group.

Group	AST (IU/L)	ALT (IU/L)	ALP (IU/L)	Protein (g/DL)
1	51.28 ± 0.42*	37.25 ± 0.83*	82.57 ± 1.56*	25.28 ± 1.11*
2	164.55 ± 1.75***	128.06 ± 0.16***	179.25 ± 0.27***	23.66 ± 1.99*
3	55.30 ± 0.65*	42.14 ± 3.07*	77.21 ± 0.74*	25.72 ± 2.11*
4	77.33 ± 0.83*	55.17 ± 0.56*	90.97 ± 0.96*	45.95 ± 1.88***

Table 2: Effect of *M. charantia* ethanolic extract on serum AST, ALT, ALP and Protein levels in acetaminophen-induced hepatotoxic rats (Values are Mean ± SD; *Mean values within the same column are significantly different at (P<0.05); 1=Control, 2=Acetaminophen only, 3=*M. charantia* extract only, 4=Pre-treated with *M. charantia* extract +Acetaminophen)

Effect of *M. charantia* extract on levels of antioxidant parameters (MDA and GSH)

The antioxidant parameters were significantly ($P < 0.05$) altered as shown in Table 3. There was a significant ($P < 0.05$) decrease in the GSH level of the acetaminophen-induced hepatotoxic rats and a significant ($P < 0.05$) increase in the MDA level of the hepatotoxic rats as compared to the control. However oral pre-treatment with *M. charantia* extract (250 mg/kg body weight) resulted in a significant ($P < 0.05$) increase in the GSH level and a significant ($P < 0.05$) decrease in the MDA level of the rats as compared to the hepatotoxic rats.

Group	GSH ($\mu\text{Mol/ml}$)	MDA ($\mu\text{Mol/ml}$)
1	67.83 \pm 1.06***	1.91 \pm 0.08***
2	35.65 \pm 0.53***	2.94 \pm 0.24*
3	43.97 \pm 2.49**	2.46 \pm 0.18*
4	48.31 \pm 1.66**	2.62 \pm 0.17*

Table 3: Effect of *M. charantia* extract on serum antioxidant parameters (GSH and MDA) in acetaminophen induced hepatotoxic rats (Values are Mean \pm SD; *Mean values within the same column are significantly different at ($P < 0.05$); 1=Control, 2=Acetaminophen only, 3=*M. charantia* extract only, 4=Pre-treated with *M. charantia* extract +Acetaminophen).

Histopathological findings

The histopathological analysis of liver section showed that acetaminophen resulted in liver damage by causing extensive degenerative changes in the liver and a central lobular necrosis. However, pre-treatment with 250 mg/kg ethanol extract of *M. charantia* leaves showed only mild degenerative changes as the acetaminophen-induced necrosis in rats was significantly ameliorated as shown in Figure 1a-d.

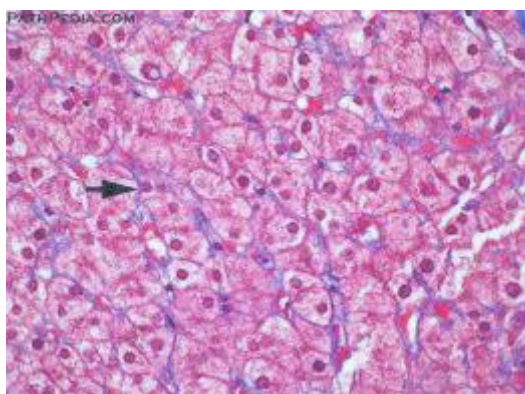


Figure 1a: Normal control group.

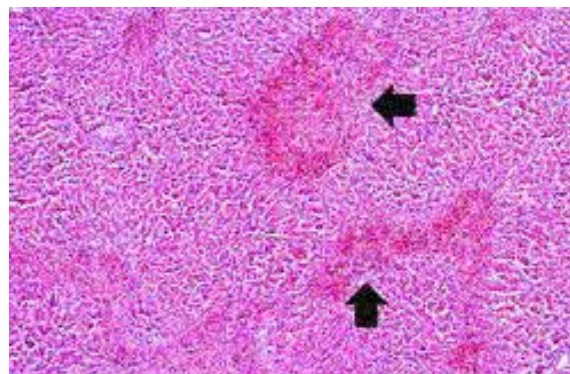


Figure 1b: Acetaminophen (1500 mg/kg) treated control (hepatotoxic group).

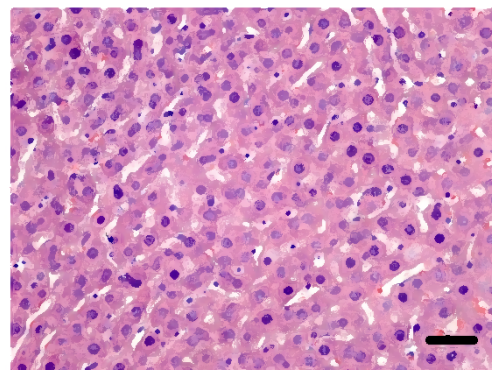


Figure 1c: Ethanol extract of *M. charantia* (250 mg/kg) treated group.

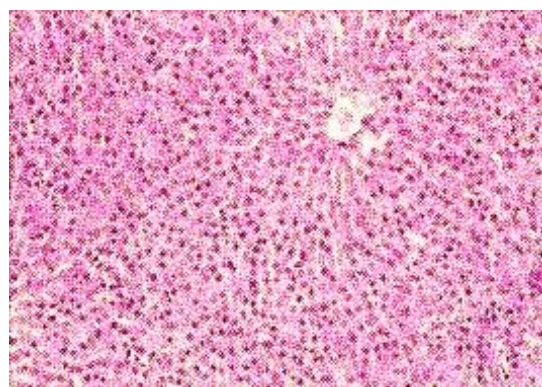


Figure 1d: *M. charantia* ethanol extract (250 mg/kg) pre-treated + Acetaminophen (1500 mg/kg) group.

Discussion

This research work was done to assess the prophylactic effect of *M. charantia* ethanol extract against acetaminophen-induced liver impairment in rats. Acetaminophen when used in high doses results in liver damage due to the excess formation of its intermediate oxidative product (N-acetyl-P-benzoquinone imine) which leads to the production of lipid peroxides [7]. The results of the quantitative phytochemical analysis of *M. charantia* leaves revealed the presence of alkaloid (28.2 mg/100 g), flavonoid (18.68 mg/100 g), phenol (15.22 mg/100 g) and saponins (23.21 mg/100 g). Previous studies by Williamson [22] and Leelaprakash [23] revealed the presence of glycosides, terpenoids, proteins, sterols, fatty acids and volatile constituents like voleric acid and aldehydes in *M. charantia*. Flavonoids have been reported to exhibit antioxidant and hepatoprotective activity [24]. Saponins have also been reported to demonstrate hepatoprotective activity by reducing the risk of liver injury via modulation of its antioxidant activities [25]. Alkaloids play diverse roles in the metabolic system of humans and also reduce the risk of liver sinusoidal obstruction syndrome [26]. Phenol also reduces the risk of liver damage [27]. Studies on the proximate composition of the leaves revealed that the leaves contain a considerable amount of vitamins, with vitamin C being the highest [28].

Liver damage induced by acetaminophen is a classical model for evaluating the hepatoprotective activity of plants. Alanine aminotransferase (ALT), aspartate aminotransferase (AST) and alkaline phosphatase (ALP) are biochemical indices (enzymes) of liver function. Necrosis of the liver leads to the diffusion of large amounts of ALT and AST out of the liver into the blood stream. ALP levels in the serum also rise with cholestasis and infiltrative diseases of the liver [29]. This was also confirmed from our research as there was a significant increase in the levels of these enzymes in the serum of the hepatotoxic rats which is adduced to the liver damage caused by acetaminophen. Oral pre-treatment with *M. charantia* leaves extract resulted in a significant ($P < 0.05$) decrease in the levels of these enzymes which implies the hepatoprotective activity of the extract. In the case of liver damage, there is reduced protein synthesis as seen from our study but oral pre-treatment of the extract led to a significant ($P < 0.05$) increase in the protein levels of the pre-treated rats when compared to the acetaminophen-induced liver impaired rats.

Stimulation of protein synthesis has been proposed as a contributory hepatoprotective mechanism that stimulates the regeneration process and the production of liver cells [30].

The ability of an hepatoprotective drug lies in the ability to preserve the normal physiological functions initially compromised by hepatotoxins [31]. Hepatoprotective properties have also been observed from other plants like *Pisonia acuelata* L. [32] and *Acacia nilotica* L. [33].

Malondialdehyde (MDA) is an index for lipid peroxidation produced as a by-product of lipid peroxidation. Lipid peroxidation leads to reduction in the levels of antioxidants. In this study, there was a significant ($P < 0.05$) increase in the MDA levels of the acetaminophen-induced hepatotoxic rats which substantiates the fact that intake of excess acetaminophen leads to increased lipid peroxidation. However, there was a significant ($P < 0.05$) decrease in the MDA levels of rats pre-treated with oral *M. charantia* leaves extract.

Glutathione (GSH) is a tri-peptide present in the liver and also an antioxidant parameter. It scavenges free radical species and also

conserves membrane protein thiols [34]. In our study, there was a significant ($P < 0.05$) increase in the GSH levels of the rats pre-treated with the oral extract of *M. charantia* leaves extract. These results suggest the antioxidant properties of *M. charantia* leaves.

Phytochemicals have been shown to stimulate synthesis of antioxidants enzymes and detoxification systems at the transcriptional level through antioxidant response elements. The antioxidant properties of *M. charantia* leaves might be attributed to the presence of flavonoids, phenol, saponin and also the presence of a considerable amount of vitamin C which is also an antioxidant vitamin as they all help to mop out free radicals generated by the administration of acetaminophen that resulted in liver damage.

The histological analysis of the hepatocytes of acetaminophen-induced hepatotoxic rats showed extensive vascular degenerative changes and central lobular necrosis. Pre-treatment with ethanol extract of *M. charantia* leaves showed mild degenerative changes and absence of necrosis which further affirms the hepatoprotective ability of the leaves that can be linked to the presence of phytochemicals.

Conclusion

The outcome of this study showed the prophylactic activity of *M. charantia* in ameliorating the biochemical and histopathological changes in the liver that resulted from exposure to acetaminophen most likely due to the synergistic interactions of alkaloids, tannins with the free radicals scavenging compounds especially flavonoids, phenol, saponin and Vitamin C that are present in the seed. However more work should be done to identify and isolate the lead compound in *M. charantia* responsible for its hepatoprotective potential and the molecular mechanism behind its therapeutic action should also be elucidated.

References

1. Buraimoh AA, Bako IG, Ibrahim FB (2011) Hepatoprotective effect of ethanolic leaves extract of *Moringa oleifera* on the histology of paracetamol induced liver damage in wistar rats. *Animal Vet Adv* 3: 10-13.
2. Navarro VJ, Senior JR (2006) Drug-related hepatotoxicity. *N Engl J Med* 354: 731-739.
3. Halliwell B, Gutteridge JMC (1999) In *Free radicals in biology and medicine* (3rd Ed.) Oxford: Oxford University Press.
4. Nagata K, Suzuki H, Sakaguchi S (2007) Common pathogenic mechanism in development progression of liver injury caused by non-alcoholic or alcoholic steatohepatitis. *J Toxicol Sci* 32: 453-468.
5. Kucera O, Cervinkova Z, Lotkova H, Krivakova P, Rousar T, et al. (2006) Protective effect of Sadenosylmethionine against galactosamine-induced injury of rat hepatocytes in primary culture. *Physiol Res* 55: 551-560.
6. Domenicali M, Caraceni P, Giannone F, Baldassarre M, Lucchetti G, et al. (2009) A novel model of CCl₄-induced cirrhosis with ascites in the mouse. *J Hepatol* 51: 991-999.
7. Kapur V, Dillai KK, Husain SZ, Balani DK (1994) Hepatoprotective activity of "jigrine" on liver damage caused by alcohol, Carbontetrachloride and paracetamol in rats. *Ind J Pharmacol* 26: 301-303.
8. Vitaglione B, Morisco F, Caporaso N, Fogliano V (2004) Dietary antioxidant compounds and liver health. *Crit Rev Food Sci Nutr* 44: 575-586.
9. Nagata K, Suzuki H, Sakaguchi S (1996) Common pathogenic mechanism in development progression of liver injury caused by non-alcoholic or alcoholic steato hepatitis. *J Toxicol Sci* 32: 453-468.

10. Welihinda (2005) Evaluation of the chemical composition of indigenous spices and flavouring Agents. *Global J Pure Appl Sci* 7: 455-459.
11. Ullah M, Chy FK, Sarkar SK, Islam MK, Absar N (2011) Nutrient and Phytochemical analysis of four varieties of bitter gourd (*Momordica charantia*) grown in Chittagong Hill tracts. *Asian J Agric Res* 5: 186-193.
12. Trease GE, Evans WC (2010) In: *Pharmacognsy*. 11th edn. Brailliar Tiridel Can Macmillian publishers. Van-Burden TP.
13. Harborne JB (1973) *Photochemical Methods: A Guide to Modern Techniques of Plant Analysis*. Chapman and Hall. London pp: 279.
14. Obadoni BO, Ochuko PO (2011) Phytochemical studies and comparative efficacy of the crude extracts of some homeostatic plants in Edo and Delta States of Nigeria. *Global J Pure Applied Sci* 8: 203-208.
15. Harris H (2012) Ancient medicine and modern targets. *J Adv Pharm Technol Res* 3: 83-91.
16. Bohm BA, Koupai-Abyazani MR (1994) Flavonoids and condensed tannins from leaves of Hawaiian *Vaccinium reticulatum* and *V Calycinum* (Ericaceae). *Paci Sci* 48: 458-463.
17. Mada SB, Inuwa HM, Abarshi MM, Mohammed HA, Aliyu A (2014) Hepatoprotective effect of *M. charantia* extract against CCL4 induced liver damage in rats. *Br J Pharm Res* 4: 368-380.
18. Reitman S, Frankel S (2014) Relative susceptibility of a few vegetable crops to two species root-knot nematodes. *Haryana J Hort Sci* 24: 76-78.
19. Wright PJ, Plummer DT, Leathwood PT (2015) Enzyme in rat urine Alkaline phosphatase. *Enzymologia* 42: 317-327.
20. Gonall AG, Bardawill CJ, David MM (1949) Determination of total protein. *J Biol Chem* 177: 751-760.
21. Banchroft JD, Stevens A, Turner DR (1996) In: *Theory and Practice of Histological Techniques*. Fourth ed. Churchill Livingstone, NewYork, London, San Francisco, Tokyo, pp: 125.
22. Williamson (2015) Dietary antioxidant compounds and liver health. *Crit Rev Food Sci Nutr* 44: 575-586.
23. Obadoni BO, Ochuka PO (2011) Phytochemical studies and comparative efficacy of the crude extracts of some Homostatic plants in Edo and Delta States of Nigeria. *Global J Pure Appl Sci* 8: 203-208.
24. Tapas AR, Sakarkar DM, Kakde RB (2008) Flavonoids as nutraceuticals: a review. *Tropical J Pharm Res* 7: 1089-1099.
25. Elekofehinti OO, Adanlawo IG, Komolafe K, Ejelonu OC (2012) Saponins from *Solanum anguivi* fruits exhibit antioxidant potential in Wistar rats. *Ann Bio Res* 3: 3212-3217.
26. Janzen (2010) Anti-Diabetic properties and phytochemistry of *Momordica charantia* L. (Cucurbitaceae). *Phytomedicine* 2: 349-362.
27. Hovelstad H, Leirset I, Oyaas K, Fiksdahl A (2006) Screening Analyses of Pinoslyvin still benes, Resin acids and lignans in Norwegian conifers. *Molecules* 11: 103-114.
28. Miniraj NM, Prasanma KP, Peter KV (1993) Bitter gourd (*Momordica* spp) In: Kalloo G, Bergh BO (Eds) *Genetic Improvement of Vegetable Plants*, Pergamon Press, Oxford, pp: 239-246.
29. Sanmugopriya E, Venkataraman S (2006) Studies on hepatoprotective and antioxidant actions of *Strychnos potatorum* Linn. seeds on CCL4-induced acute hepatic injury in experimental rats. *J Ethnopharmacol*: 105: 154-160.
30. Rip JW, Rupar CA, Ravi K, Carroll KK (1985) Distribution, metabolism and function of dolichol and polyprenols. *Prog Lipid Res*: 24: 269-309.
31. Yadav NP, Dixit VK (2003) Hepatoprotective activity of leaves of *Kalanchoe pinnata* Pers. *J Ethnopharmacol* 86: 197-202.
32. Palanivel MG, Rajkapoor B, Kumar RS, Einstein JW, Kumar EP, et al. (2008) Hepatoprotective and Antioxidant Effect of *Pisonia aculeata* L. against CCL4- Induced Hepatic Damage in Rats. *Sci Pharm*: 76: 203-215.
33. Kannan N, Sakthivel SK, Guruvayoorappan C (2013) Protective Effect of *Acacia nilotica* (L.) against Acetaminophen-Induced Hepatocellular Damage in Wistar Rats. *Adv Pharmacol Sci*.
34. Prakash J, Gupta SK, Singh N (2001) Chemopreventive activity of *Withania somnifera* in experimentally induced fibro sarcoma tumors in Swiss albino rats. *Phytother Res*. 15: 200-204.