

# Antibodies to Ribosomal P in Lupus Psychosis Resolving after Rituximab plus Cyclophosphamide – A Case Report

Nicola C. G. Stein<sup>1,2</sup>, Karsten Conrad<sup>3</sup> and Martin Aringer<sup>1\*</sup>

<sup>1</sup>Department of Medicine III, University Medical Center Carl Gustav Carus, TU Dresden, Dresden, Germany

<sup>2</sup>Division of Rheumatology, Medizinische Klinik und Poliklinik IV, University of Munich, Munich, Germany

<sup>3</sup>Institute of Immunology, Faculty of Medicine Carl Gustav Carus, TU Dresden, Dresden, Germany

## Abstract

**Background:** Central nervous disease manifestations in systemic lupus erythematosus (SLE) are variable, but may be severe. A subset of these manifestations in the central nervous system (CNS) is caused by antibodies. One antibody in particular, against ribosomal P, is supposed to play a significant role in neuropsychiatric SLE, especially lupus psychosis. Our case supports this idea.

**Case:** We present a case of a young female who developed severe lupus psychosis after discontinuation of her immunosuppressive treatment for systemic lupus erythematosus without prior central nervous or psychiatric manifestations. Cerebral imaging and liquor analysis was unremarkable, serum analysis showed high titers of both, anti-dsDNA and anti-ribosomal P antibodies. When disease could not be controlled with high dose methylprednisolone, a combination of cyclophosphamide and rituximab was administered. Approximately two weeks after the immunosuppressive combination therapy, mood stabilization and clinical recovery were apparent. After two months the patient was recovered completely. Serology showed a striking decrease in anti-ribosomal P antibodies at this time.

**Conclusion:** The disease course of this young patient with severe lupus psychosis suggests that the effect of pulse methylprednisolone was on the blood-brain barrier, with only with a dose of 1 g q.d. being effective. Therewith, it supports the idea of lupus psychosis being caused by auto-antibodies entering the CNS. The very high titres of anti-ribosomal P antibodies in full-blown psychosis, and the pronounced fall of these antibodies thereafter, concomitant with reaching clinical remission, support the concept of anti-ribosomal P antibodies causing lupus psychosis.

**Keywords:** Neuropsychiatric SLE, Lupus psychosis; Autoantibody; Ribosomal P; Rituximab; cyclophosphamide

## Introduction

Systemic lupus erythematosus (SLE) is a chronic autoimmune disease with a broad spectrum of clinical manifestations. Up to 80 % of SLE patients show some involvement of the central nervous system (CNS), which may occur at any time during the disease [1]. CNS disease in SLE encompasses a wide spectrum of neurologic and psychiatric features ranging from strokes, chorea, or psychosis, to more subtle cognitive abnormalities such as attention or memory defects [2-4]. To depict this wide range, the American College of Rheumatology (ACR) nomenclature for neuropsychiatric SLE defines 19 neuropsychiatric syndromes, including seizures, stroke, headache, polyneuropathy, mononeuropathy, depression and psychosis as case definitions for neuropsychiatric SLE (NPSLE) [5].

Many of these SLE CNS symptoms derive from ischemia, most commonly caused by anti-phospholipid antibodies, by accelerated atherosclerosis or, much less common, by CNS vasculitis [6]. Another subset of CNS problems is caused by antibodies, which reversibly alter neuronal functions. Among these antibodies, those to ribosomal P probably play a role in lupus psychosis [7]. These autoantibodies are directed against three highly conserved phosphorylated P proteins [8]. Auto-antibodies recognizing the ribosomal P protein (aRP), first characterized in 1985 [9], are highly specific for SLE [10,11] and are associated with disease activity and neuropsychiatric events in SLE [12]. High levels of anti-ribosomal P antibodies have been found in psychotic SLE patients [13-15] and in major depressive/psychotic SLE patients [10,16], although not all studies have seen such association [17].

Importantly, however, there are animal data well in line with such hypothesis. Katzav et al. found that anti-ribosomal P antibodies bind to specific areas in the normal mouse brain tissue including the limbic and olfactory areas. Moreover, intrathecal anti-ribosomal P antibodies could induce psychiatric symptoms as well as impair the sense of smell in mice, consistent with the areas bound [18,19]. The current case report supports the idea that such antibodies may also cause lupus psychosis.

## Case

A 24-year old woman with a five year history of SLE presented herself in the department of dermatology because of an obvious skin flare, with prominent malar rash and erythematous, firm, maculopapular lesions on her legs, in addition to a livid reticular pattern of both arms. Her SLE had been well controlled for several years, until she stopped all immunosuppressive medication six months before the admission. Approximately five months off medication she recognized growing light sensitivity and increasing activity of skin lesions. In

**\*Corresponding author:** Martin Aringer, MD, Division of Rheumatology, Department of Medicine III, University Medical Center Carl Gustav Carus at the TU Dresden, Fetscherstrasse 74, 01309 Dresden, Germany, Tel: +49-351-458/4422; Fax: +49-351-458/5802; E-mail: [Martin.Aringer@uniklinikum-dresden.de](mailto:Martin.Aringer@uniklinikum-dresden.de)

**Received** October 01, 2013; **Accepted** October 23, 2013; **Published** October 30, 2013

**Citation:** Stein NCG, Conrad K, Aringer M (2013) Antibodies to Ribosomal P in Lupus Psychosis Resolving after Rituximab plus Cyclophosphamide – A Case Report. J Clin Cell Immunol 4: 168. doi:10.4172/2155-9899.1000168

**Copyright:** © 2013 Stein NCG, et al. This is an open-access article distributed under the terms of the Creative Commons Attribution License, which permits unrestricted use, distribution, and reproduction in any medium, provided the original author and source are credited.

addition, she lost about 10 kg of weight within 4 months, which was not perceived as a sign of sickness at this time. During the last week before hospitalization she felt weak and sleepy, but had not headaches. She developed heart burn, intermittent diarrheas, abdominal pain and meteorism, painful mucosal ulcers, and night sweats and fevers of up to 38.5°C. At the dermatology department she was immediately started on prednisolone 50 mg/d and cefuroxime 250 mg/d and sent to the emergency department.

Upon first examination, she was well orientated to all qualities, but lethargic. Her husband reported mood disorders, which had never occurred before. During the four days before admission, he had recognized progressive slowing of her thoughts, failure to respond adequately, and “day dreaming”. On clinical examination, she appeared acutely ill, but was afebrile and in stable condition, with heart rate, blood pressure and breathing frequency in the normal range. Her skin was pale and showed an obvious butterfly rash and a livid reticular pattern on her arms. She was oriented and the neurological examination found no sign of focal disorders. The mucosal surfaces were dry, with ulcers and suspected oral mycosis. Mild abdominal pain was noticed in the epigastrium and left lower quadrant.

Treatment with prednisolone 50 mg/d and cefuroxime 250 mg was continued and fluconazol, pantozol, and topical amphotericine were started. Immunology results showed high titer ANA (1:2,560) with a homogeneous pattern, anti-dsDNA-antibodies on CLIFT of > 1:320, and positive anti-cardiolipin IgG and IgM antibodies (29.3 U/ml and 67.7 U/ml, respectively). She was positive for anti-Sm, but negative for anti-Ro- and anti-La antibodies.

The patient slowly became drowsy, and cerebral MRI and lumbar puncture were preformed to rule out infection and intracerebral lesions, but both were unremarkable (Figure 1). CSF-analysis also found no indication of intrathecal IgG-synthesis.

Over the next days, she received 1g of i.v. methylprednisolone q.d., cleared up completely, and was transferred to the rheumatology ward. At this time point, her skin had also clearly improved. Hydroxychloroquine was started after a normal ophthalmologic examination.

However, when prednisolone was reduced to 50 mg q.d., she developed frank psychosis with both acoustical and optical hallucinations. At the same time, the livedoreticularis pattern became more prominent. A cerebral CT scan excluded bleeding or focal lesions, and methylprednisolone was again increased to 1 g q.d. Serum analysis showed high titers of both, anti-dsDNA and anti-ribosomal P antibodies (>300.00 IU/ml and 112.99 U/ml, respectively). Methylprednisolone pulse therapy again led to rapid improvement, but 250 mg q.d. was not able to maintain control of her organic brain syndrome, even despite concomitant antipsychotic medication. Therefore, 750 mg of cyclophosphamide and 1g of rituximab were administered.

Her further course was complicated by severe early dyskinesias as an adverse effect of neuroleptic therapy, which subsided only when the anti-psychotic medication was exchanged. Nevertheless, approximately two weeks after rituximab and cyclophosphamide, mood stabilization and clinical recovery were apparent and the psychiatric medication could be reduced. While the effect of goserelin for gonadale protection was waited for, the second rituximab infusion was administered two weeks after the first, with the second cyclophosphamide bolus following 11 days after. A follow-up MRI again found no cerebral lesions. After one month, the young woman was clinically stable and could be discharged to a rehabilitation centre on 200 mg hydroxychloroquine

and 20 mg of prednisolone q.d. with a schedule of stepwise withdrawal of any psychiatric medication. Four weeks after discharge, she was seen in the Rheumatology outpatient clinic, without any psychiatric and any obvious other organ manifestation. Repeat serology showed a striking decrease in anti-ribosomal P antibodies at this time, to a level of 11.01 U/ml, a > 95% reduction from baseline (Figure 2).

## Discussion

The case of this young SLE patient is fairly typical for severe lupus psychosis. An infection could be clearly ruled out, as were vascular problems, although there were some indications compatible with anti-phospholipid syndrome and/or vasculitis at presentation. However, the almost immediate effect of 1g pulse methylprednisolone, but not of slightly lower methylprednisolone doses, was remarkable. In fact, this suggested a direct effect on the blood-brain barrier, keeping auto-antibodies from entering the CNS.

The very high titre of anti-ribosomal P antibodies in full-blown

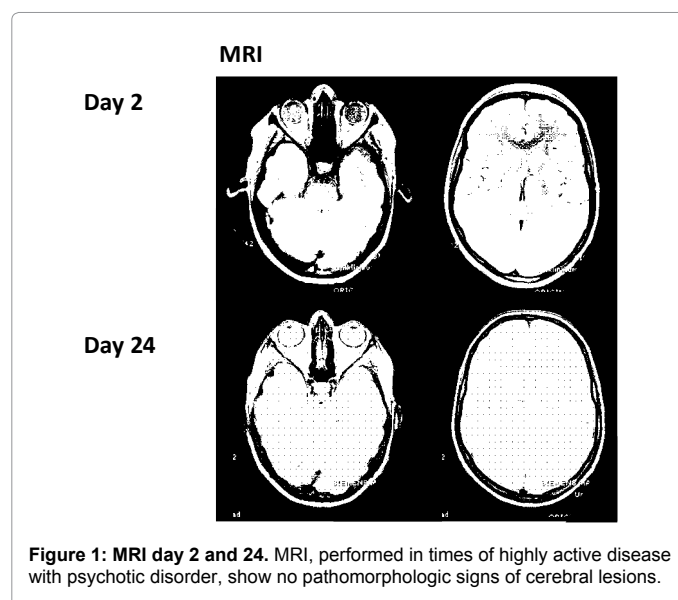


Figure 1: MRI day 2 and 24. MRI, performed in times of highly active disease with psychotic disorder, show no pathomorphologic signs of cerebral lesions.

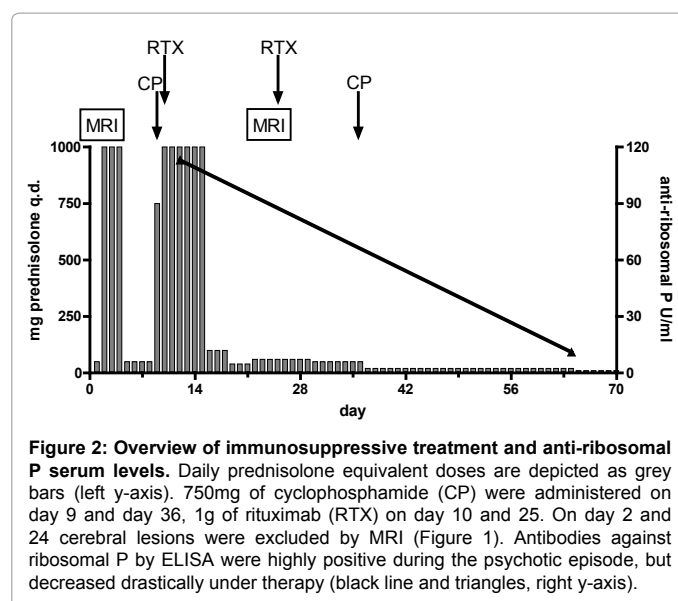


Figure 2: Overview of immunosuppressive treatment and anti-ribosomal P serum levels. Daily prednisolone equivalent doses are depicted as grey bars (left y-axis). 750mg of cyclophosphamide (CP) were administered on day 9 and day 36, 1g of rituximab (RTX) on day 10 and 25. On day 2 and 24 cerebral lesions were excluded by MRI (Figure 1). Antibodies against ribosomal P by ELISA were highly positive during the psychotic episode, but decreased drastically under therapy (black line and triangles, right y-axis).

psychosis and the pronounced fall of these antibodies thereafter, concomitant with reaching clinical remission, strongly support the concept of anti-ribosomal P antibodies causing lupus psychosis, as found in an animal model [18,19] and in the majority of clinical studies [9-16]. As already described above, intrathecal anti-ribosomal P antibodies effect psychiatric disease manifestations in mice, consistent with their specific binding pattern.

However, while neuronal apoptosis has been invoked [20], this is most likely not true for true lupus psychosis, which reacts promptly to pulse steroids and mostly disappears without apparent sequelae, as highlighted by complete recovery and a normal MRI in this patient. This hypothesis is supported by a study of 102 NPSLE patients, 47% of whom had no brain abnormalities in the MRI scan [21].

Anti-ribosomal P antibodies showed high grade correlations with lupus psychosis in NPSLE cohorts. Bonfa et al. described serum IgG to P ribosomal proteins in 18 of 20 patients with neuropsychiatric manifestations [14]. Two inception cohort studies [22,23], with 219 and 1047 SLE patients, respectively, found anti-ribosomal P antibodies significantly associated with lupus psychosis.

Abdel-Nasser et al. again demonstrated a significant correlation of anti-ribosomal P with psychiatric but not neurological manifestations of NPSLE [15], and the data of Hanly et al. likewise underline the specific clinical-serologic association between anti-ribosomal P and psychosis attributed to SLE [24]. Although Karassa et al. denies anti-ribosomal P antibodies a high diagnostic value for NPSLE, data of different studies show that anti-ribosomal P antibodies apparently are quite sensitive for lupus psychosis [15,19,25]. Thus, their absence in an acutely psychotic SLE patient may warrant further investigations in other directions.

The other interesting aspect in this case history is the efficacy of the combination of pulse cyclophosphamide and rituximab, following the Isenberg SLE dosing regimen [26]. In the case of this young patient, it became apparent that corticosteroids alone would not likely resolve the problem. Moreover, there was a pressing need for rapid improvement on the one hand, and reluctance to use higher doses of cyclophosphamide for fear of ovarian failure on the other. Although we can neither exclude that cyclophosphamide alone would have been sufficient, nor that rituximab monotherapy would have worked, we believe that it was the combined approach that effectively and safely resolved a rather dramatic clinical situation. While this may be even more obvious in situations where remaining damage has to be feared, the situation warranted the most effective approach, also because of suicidal ideas of the patient.

Taken together, this young SLE patient experienced a severe psychotic flare half a year after stopping her immunosuppressive medication. The flare was associated with very high titres of anti-ribosomal P antibodies, consisting with the idea that these antibodies cause lupus psychosis. While corticosteroids were effective only in doses directly affecting the blood-brain barrier, combination therapy with rituximab and cyclophosphamide drastically reduced the anti-ribosomal P antibodies and led to rapid clinical remission.

#### Acknowledgements

The work was not supported by any grants or other financial supporters. M.A. has served on Advisory boards for Roche, the manufacturer of rituximab. The other authors have no conflicts of interest to declare.

#### References

1. Alkhotani A (2013) Neuropsychiatric lupus. *Sultan Qaboos Univ Med J* 13: 19-25.

2. Brey RL, Holliday SL, Saklad AR, Navarrete MG, Hermosillo-Romo D, et al. (2002) Neuropsychiatric syndromes in lupus: prevalence using standardized definitions. *Neurology* 58: 1214-1220.

3. Unterman A, Nolte JE, Boaz M, Abady M, Shoenfeld Y, et al. (2011) Neuropsychiatric syndromes in systemic lupus erythematosus: a meta-analysis. *Semin Arthritis Rheum* 41: 1-11.

4. Meszaros ZS, Perl A, Faraone SV (2012) Psychiatric symptoms in systemic lupus erythematosus: a systematic review. *J Clin Psychiatry* 73: 993-1001.

5. ACR ad hoc committee on Neuropsychiatric Lupus Nomenclature (1999) The American College of Rheumatology nomenclature and case definitions for neuropsychiatric lupus syndromes. *Arthritis Rheum* 42: 599-608.

6. Bertias GK, Ioannidis JP, Aringer M, Bollen E, Bombardieri S, et al. (2010) EULAR recommendations for the management of systemic lupus erythematosus with neuropsychiatric manifestations: report of a task force of the EULAR standing committee for clinical affairs. *Ann Rheum Dis* 69: 2074-2082.

7. Fanouriakis A, Boumpas DT, Bertias GK (2013) Pathogenesis and treatment of CNS lupus. *Curr Opin Rheumatol* 25: 577-583.

8. Zandman-Goddard G, Chapman J, Shoenfeld Y (2007) Autoantibodies involved in neuropsychiatric SLE and antiphospholipid syndrome. *Semin Arthritis Rheum* 36: 297-315.

9. Elkon KB, Parnassa AP, Foster CL (1985) Lupus autoantibodies target ribosomal P proteins. *J Exp Med* 162: 459-471.

10. Schneebaum AB, Singleton JD, West SG, Blodgett JK, Allen LG, et al. (1991) Association of psychiatric manifestations with antibodies to ribosomal P proteins in systemic lupus erythematosus. *Am J Med* 90: 54-62.

11. Carmona-Fernandes D, Santos MJ, Canhão H, Fonseca JE (2013) Anti-ribosomal P protein IgG autoantibodies in patients with systemic lupus erythematosus: diagnostic performance and clinical profile. *BMC Med* 11: 98.

12. Li J, Shen Y, He J, Jia R, Wang X, et al. (2013) Significance of antibodies against the native ribosomal P protein complex and recombinant P0, P1, and P2 proteins in the diagnosis of Chinese patients with systemic lupus erythematosus. *J Clin Lab Anal* 27: 87-95.

13. Bonfa E, Golombek SJ, Kaufman LD, Skelly S, Weissbach H, et al. (1987) Association between lupus psychosis and anti-ribosomal P protein antibodies. *N Engl J Med* 317: 265-271.

14. Toubi E, Shoenfeld Y (2007) Clinical and biological aspects of anti-P-ribosomal protein autoantibodies. *Autoimmun Rev* 6: 119-125.

15. Abdel-Nasser AM, Ghaleb RM, Mahmoud JA, Khairy W, Mahmoud RM (2008) Association of anti-ribosomal P protein antibodies with neuropsychiatric and other manifestations of systemic lupus erythematosus. *Clin Rheumatol* 27: 1377-1385.

16. Arnett FC, Reveille JD, Moutsopoulos HM, Georgescu L, Elkon KB (1996) Ribosomal P autoantibodies in systemic lupus erythematosus. Frequencies in different ethnic groups and clinical and immunogenetic associations. *Arthritis Rheum* 39: 1833-1839.

17. Eber T, Chapman J, Shoenfeld Y (2005) Anti-ribosomal P-protein and its role in psychiatric manifestations of systemic lupus erythematosus: myth or reality? *Lupus* 14: 571-575.

18. Katzav A, Solodeev I, Brodsky O, Chapman J, Pick CG, et al. (2007) Induction of autoimmune depression in mice by anti-ribosomal P antibodies via the limbic system. *Arthritis Rheum* 56: 938-948.

19. Katzav A, Ben-Ziv T, Chapman J, Blank M, Reichlin M, et al. (2008) Anti-P ribosomal antibodies induce defect in smell capability in a model of CNS-SLE (depression). *J Autoimmun* 31: 393-398.

20. Matus S, Burgos PV, Bravo-Zehnder M, Kraft R, Porras OH, et al. (2007) Antiribosomal-P autoantibodies from psychiatric lupus target a novel neuronal surface protein causing calcium influx and apoptosis. *J Exp Med* 204: 3221-3234.

21. Steup-Beekman GM, Zirkzee EJ, Cohen D, Gahrman BM, Emmer BJ, et al. (2013) Neuropsychiatric manifestations in patients with systemic lupus erythematosus: epidemiology and radiology pointing to an immune-mediated cause. *Ann Rheum Dis* 72 Suppl 2: ii76-79.

22. Briani C, Lucchetta M, Ghirardello A, Toffanin E, Zampieri S, et al. (2009) Neurolyupus is associated with anti-ribosomal P protein antibodies: an inception cohort study. *J Autoimmun* 32: 79-84.

- 
23. Hanly JG, Urowitz MB, Su L, Bae SC, Gordon C, et al. (2011) Autoantibodies as biomarkers for the prediction of neuropsychiatric events in systemic lupus erythematosus. *Ann Rheum Dis* 70: 1726-1732.
24. Hanly JG, Urowitz MB, Siannis F, Farewell V, Gordon C, et al. (2008) Autoantibodies and neuropsychiatric events at the time of systemic lupus erythematosus diagnosis: results from an international inception cohort study. *Arthritis Rheum* 58: 843-853.
25. Karassa FB, Afeltra A, Ambrozic A, Chang DM, De Keyser F, et al. (2006) Accuracy of anti-ribosomal P protein antibody testing for the diagnosis of neuropsychiatric systemic lupus erythematosus: an international meta-analysis. *Arthritis Rheum* 54: 312-324.
26. Chambers SA, Isenberg D (2005) Anti-B cell therapy (rituximab) in the treatment of autoimmune diseases. *Lupus* 14: 210-214.