

Antiarthritic Effects of *Daphne giraldii* Nitsche (Thymelaeaceae) Mainly through Suppression of the Secondary Inflammation

Sheng Wang^{1,2}, Xiaotao Xu^{1,2}, Yue Zang^{1,2}, Xiaoxing Huang^{1,2}, Yifei Wang^{1,2}, Bin Zheng^{1,2}, Li Liu^{1,2*} and Qibing Mei^{1,2*}

¹China State Institute of Pharmaceutical Industry, Shanghai, China

²State Key Laboratory of New Drug and Pharmaceutical Process, Shanghai Institute of Pharmaceutical Industry, Shanghai, China

Abstract

The present study focuses on the anti-arthritis effect of Zushima cataplasms (ZC) in adjuvant arthritic (AA) rats. AA rats were treated with ZC from the 3rd day before immunization and continued until the 20th day after immunization. The severity of arthritis was evaluated by swelling, heat, nociceptive, histopathology and radiological changes. The levels of IL-1 β , TNF- α in the serum were measured by ELISA. ZC showed no effect on alleviating swelling in primary inflammation, while ZC 0.75 g/kg dramatically reduced the swelling, and showed a significant increment of mechanical pain thresholds in secondary inflammation. The synovial hyperplasia and inflammatory cells infiltration were suppressed by ZC in secondary inflammation but not in primary inflammation. The radiographic studies further provided supportive evidence for histopathology analysis. Additionally, There was significant reduction in production of interleukin-1 β (IL-1 β), tumor necrosis factor (TNF- α) in serum of AA rats treated with ZC.

Keywords: Zushima; Adjuvant-induced arthritis; Primary inflammation; Secondary inflammation; Swelling; Nociceptive thresholds

Introduction

Rheumatoid arthritis (RA), characterized by severe morbidity, functional impairment, permanent disability, and increased mortality, is a chronic, destructive inflammatory polyarticular joint and systemic autoimmune disease which leads to the destruction of synovial membranes, cartilage and bone [1]. Although the etiology remains unknown, the recent advancements have demonstrated that many different cell components are involved in the RA development, including neutrophils, T and B lymphocytes, and monocytes/macrophages [2-4]. Activation of these cells leads to the production of cytokines which are responsible for inflammation. However, the hierarchy of the immune-inflammatory and its relationship with synovial stroma activation is not fully understood. Overwhelming evidence indicates that the immunological response, both in its innate and adaptive immunity, can play a critical role in early and advanced stages of the disease [5,6].

RA pathogenesis is a multistep process consisting early phase, involving the generation of autoantibodies, an "initiation phase", where synovial inflammation emerges, and advanced stages, which is dominated by non-resolving synovial inflammation and joint destruction [7]. Compelling evidence supporting this conclusion, a rat model of antigen-induced arthritis characterized by acute phase (primary inflammation) and a chronic phase (secondary inflammation), was triggered by systemic immunization followed by local challenge with Freund's complete adjuvant (FCA) [5]. In the acute phase, antigen challenge in peripheral tissue results in dendritic activation, with local activation of naïve or central T and B cells, and effector lymphocytes favor the removal of the antigen, leading to the primary inflammation [8,9]. Besides, effector lymphocytes secrete inflammatory cytokines, such as tumor necrosis factor- α (TNF α), interleukin-1 (IL-1), and IL-6, which enter the systemic circulation and induce the secondary inflammation [10,11].

The goals for antiarthritic are long-term relief of pain, prevention

of joint inflammation and morphological changes. Drugs used for the treatment of RA exhibit antiarthritic effect by affecting the onset and symptoms of inflammation [12]. Zushima (Chinese name), the dried stem bark and root bark of *Daphne giraldii* Nitsche (Thymelaeaceae), a traditional Chinese medicine used for over two thousand years in China for inflammation related symptoms, including joint pain, is mainly used to treat rheumatoid arthritis (RA) in clinics [13,14]. Previous phytochemical studies reported that *Daphne giraldii* Nitsche mainly contained coumarin compounds, flavonoids and biscoumarin glycosides. And Zushima-Pian (ZP), a traditional Chinese medicine tablet, was officially recorded in the Ministry of Public Health of China for the treatment of arthritis, rheumatic arthritis [1]. The above evidences indicate that Zushima has showed good activity for antiarthritic, but reports on anti-inflammation effect of Zushima were relatively limited in recent 5 years and underlying mechanisms of action were not clear. Thus, the present study was focused on the evaluation of the anti-arthritis effects of Zushima cataplasms (ZC) using FCA induced AA rats. The potential activities of ZC on controlling TNF- α and IL-1 β production in serum were determined by ELISA. Moreover, the severity of arthritis in the knee joints was evaluated by histological assessment of cartilage destruction and X-ray photographs.

***Corresponding authors:** Qibing Mei, PhD, State Key Laboratory of New Drug and Pharmaceutical Process, Shanghai Institute of Pharmaceutical Industry, China State Institute of Pharmaceutical Industry, No. 1 Zhongshan North Road, Hongkou District, Shanghai, 200437, China, Tel: 021-65449361; Fax: 86 2165449361; E-mail: qibingmei@126.com

Li Liu, PhD, State Key Laboratory of New Drug and Pharmaceutical, Shanghai Institute of Pharmaceutical Industry, China State Institute of Pharmaceutical Industry, No. 1 Zhongshan North Road, Hongkou District, Shanghai, 200437, China, Tel: 021-55514600; Fax: 86 2155514600; E-mail: liuli1129@hotmail.com

Received November 09, 2015; **Accepted** November 17, 2015; **Published** November 20, 2015

Citation: Wang S, Xu X, Zang Y, Huang X, Wang Y, et al. (2015) Antiarthritic Effects of *Daphne giraldii* Nitsche (Thymelaeaceae) Mainly through Suppression of the Secondary Inflammation. Pharm Anal Chem Open Access 1: 107. doi:10.4172/2471-2698.1000107

Copyright: © 2015 Wang S, et al. This is an open-access article distributed under the terms of the Creative Commons Attribution License, which permits unrestricted use, distribution, and reproduction in any medium, provided the original author and source are credited.

Materials and Methods

Animals

All experiments were performed on male Sprague-Dawley (SD) rats, weighing 180-220 g, provided by the Animal Center of Shanghai Institute of Medical Sciences. Throughout the experiments, rats were maintained in plastic cages at $21 \pm 2^\circ\text{C}$, on a 12 h light/dark cycle and with free access to water. Animal welfare and experimental procedures were carried out in accordance with the Guide for the Care and Use of Laboratory Animals, and were approved by the animal ethics committee of Genetics and Cytology of Shanghai Institute of Pharmaceutical Industry. The registration number of animal ethics committee is 2013235 HM and the approved date of animal ethics December 23, 2013. All possible efforts were made to minimize the animals' suffering and to reduce the number of animals used.

Induction of AA and treatments

The method described by Talwar was followed for this investigation [15,16]. SD rats were randomly divided into five groups, control, model and test groups (three different doses), ten rats in each group. Firstly, right hind paw of all rats were un-haired with 8% sodium sulfide (Na_2S) to promote transdermal absorption of ZC (Gansu Wuwei Pharmaceutical Co., Ltd.), and were fed for 5 days. Then, rats of test groups were pretreated topically with ZC (0.25, 0.5, 0.75 g/kg), while control and model rats were treated topically with inert paste as the control for 3 days, covered with gauze and a layer of plastic film, sealed, and fixed with desensitized adhesive plaster. The optimal doses of ZC were utilized based on the clinical doses. AA was induced by intradermal injection with 0.1 ml FCA into the right hind paw of the rats in model and test groups on the 4th day, and control group animals received an intradermal injection with an equal volume of PBS. After FCA immunization, the rats were treated consecutively for 20 days. On the final day of treatment, all rats were anesthetized with ethyl ether, then the blood was collected from each rat by carotid artery cannulation.

Swelling and heat observation of ankle joint

The volume of the ankle of both hind limbs was measured by YLS-7B plethysmometer (Shandong Province Academy of Medical Science, China). The volume of primary side (right limb) was recorded both before and post FCA injection on the 1st (3 h, 6 h, 9 h), 5th, 6th, 7th, 8th, 9th, 10th, 13th, 15th and 20th day throughout the whole experiment, and the volume of secondary side (left hind limb) was measured both before and post FCA immunization on the 18th day. Then, the degree of swelling was calculated.

The degree of swelling = the volume after FCA immunization - the volume before FCA immunization

The heat of primary side (right limb) was detected by infrared thermometer both before and after FCA immunization at the same time above mentioned, and raised temperature (Δt) was calculated.

Measurement of mechanical nociceptive thresholds

The mechanical nociceptive thresholds of the hind paw both primary and secondary side were recorded at 6th and 18th day separately by von Frey hair. Before each nociceptive test, all animals were habituated to chambers with mesh floors and handled prior to test, and were allowed to habituate to the environment for at least 15 min [17]. The plantar surface of each foot was stimulated with von Frey hairs (Linton, UK) of increasing gram force breaking points [18]. Each

von Frey hair tested was applied a total of 5 times to each hind paw, and the number of times that an animal withdrew the paw from each stimulus was counted. The withdrawal threshold was determined from the resultant stimulus response.

Secondary arthritis assessment

The rats were assessed for signs of arthritis by five independent observers who were blinded to the experimental design. The secondary arthritis, including left hind limb and whole body (hind limbs, forelimbs, ears and tail), were graded and scored for severity and swelling on a scale of 0-4 point at the 18th and 22th day separately: (0: normal, with no macroscopic signs of arthritis; 1: only redness; 2: redness and mild swelling; 3: redness and severe swelling; 4: joint deformation and arthroclisis [19]. Besides, one nodule on ears or tail scored as 1 point, and severity of secondary arthritis was evaluated by the cumulative scores.

Histopathology of ankle joint

The rats were sacrificed on the final day and their hind paws were fixed as described below. The ankle joints were separated and kept in 10% neutral buffered formalin for 24 h, decalcified with a solution containing HCl and 0.1 M EDTA. After completion of the decalcification process, the ankle joints were embedded in paraffin, sectioned, and stained with hematoxylin-eosin. The histological scoring system was done based on inflammatory infiltrate and synovial hyperplasia; inflammatory infiltrate: 0-3 (0: absent, 1: mild, 2: moderate, 3: severe), synovial hyperplasia: 0-3 (0: absent, 1: mild, 2: moderate, 3: severe), and histopathology of ankle joint was evaluated by the cumulative scores [20].

Radiological imaging

On the 22th day, the anesthetized rats were kept on a table, and radiographs of the hind paws and forepaws were taken by using X-ray. The film focus distance was 45 inch. and the machine was operated at 60 kV peak, 8 mA, and the exposure time was 0.08 s [15]. The radiological alterations were recorded for severity as reported previously [21].

IL-1 β and TNF- α in serum

Levels of proinflammatory cytokines TNF α and IL-1 β in serum were determined by using commercially available ELISA kits (Nanjing Jiancheng Bioengineering Institute, Nanjing, China) according to manufacturer instructions.

Statistical analysis

The data obtained were presented as means \pm SD, and statistical comparisons between groups were performed using one-way ANOVA followed by Student's t-test with P values of <0.01 (**) or <0.05 (*) compared with model and P values of <0.01 (##) or <0.05 (#) compared with control.

Results and Discussion

Effects of ZC on primary inflammation

AA rat is an experimental immunopathologic model which shares many features of RA [22]. Firstly, clinical parameters were assessed to investigate the effects of ZC on primary and acute inflammation: degree of swelling, heat of the ankle joint and mechanical nociceptive thresholds [23]. After FCA induction, the injection right hind paws of all rats swelled and appeared red. The right hind paws in model groups were obviously larger than control group ($P < 0.01$), but the right hind

paws of rats in all ZC-treated (three different doses) group showed no difference compared with model ($P>0.05$) (Figure 1A). As indicated in Figure 1B, compared to control, the right hind limb of model rats showed a significant increase in the joint surface temperature, and treatment with ZC exhibited an inhibition of temperature increment compared with model. Figure 1C illustrated that withdrawal threshold was decreased significantly in the model group compared with that in control group ($P<0.01$). Treatment with ZC 0.25 g/kg significantly mitigated the mechanical allodynia compared with model ($P<0.01$). Unexpectedly, ZC 0.5 g/kg and 0.75 g/kg had no effect ($P>0.05$). The results indicated that ZC relieved heat and pain in primary inflammation to some extent, but showed no effect on alleviating swelling in primary inflammation.

Effects of ZC on secondary inflammation

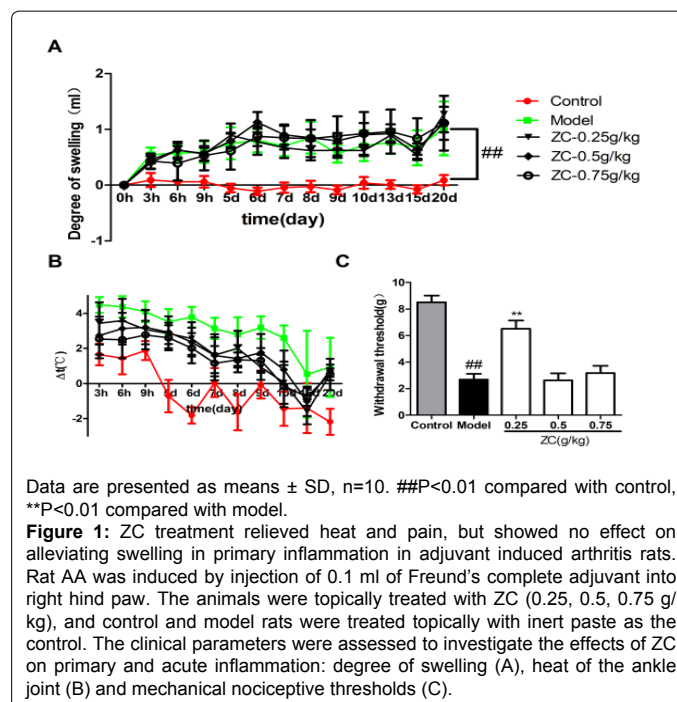
In our experiment, left hind paws (non-injected) of rats appeared swollen and red on day 15, and 80% rats in model group showed swelling or redness on day 18. Therefore, we evaluated the degree of swelling and joint score (left hind paw) on day 18 to assess the effect of ZC on secondary inflammation. The results indicated that the degree of swelling in model group was significantly higher than control ($P<0.01$), and treatment with ZC 0.75 g/kg dramatically reduced the swelling ($P<0.05$) (Figure 2A). As shown in Figure 2B, the withdrawal threshold was dramatically reduced in the model group compared with control. Treatment with 0.25 g/kg, 0.5 g/kg and 0.75 g/kg showed a significant increment of mechanical pain thresholds ($P<0.01$). Figure 2C showed a joint score (left hind paw) was 2.5 ± 0.9 in the model group, and ZC 0.25 g/kg, 0.5 g/kg, 0.75 g/kg significantly decreased the joint score ($P<0.05$). Besides, we investigated whether ZC mitigated the pain in secondary inflammation. Furthermore, the systemic inflammation score was evaluated including four limbs, ears and tail of each rat. As indicated in Figure 2D, the systemic inflammation score is 9.9 ± 5.4 in the model group, and ZC 0.25 g/kg, 0.5 g/kg, 0.75 g/kg significantly decreased the systemic inflammation score ($P<0.01$).

Effects of ZC on histopathology of primary and secondary inflammatory joint

In the control group, the articular cavities were very clean. The articular surfaces were smooth, and there were loose connective tissues and fatty tissues under the synovial membranes (Figure 3A, G). In the model group, the histopathology of ankle joints showed multiple layers of synovium hyperplasia and inflammatory cell infiltration (Figure 3B, H). Synovial cells became proliferated, enlarged in size and disorderly arranged. The loose connective tissues under the synovial membranes became hyperaemia and infiltrated with inflammatory cells. In the ZC-treated groups, there were obvious synovium hyperplasia and inflammatory cell infiltration in the primary inflammatory joint (right hind paw), showing no effects on alleviating primary inflammation (Figure 3C, D, E, F). In contrast, in secondary inflammatory joint, ZC treatment significantly inhibited the synovium hyperplasia, and reduced the number of infiltrated inflammatory cells (Figure 3I, J, K). The scores for synovium hyperplasia and cell infiltration were reduced significantly and dose-dependently by treatment with ZC compared with the model group (Figure 3L) ($P<0.01$).

Effects of ZC on radiographic changes

The radiographic evaluation revealed severe joint erosion and joint destruction in both the forelimbs and hind limbs. Figure 4 showed X-ray radiographs of the different treatment group animal paws taken on the 22th day. In the model group, adjuvant treated rats



Data are presented as means \pm SD, $n=10$. ## $P<0.01$ compared with control, ** $P<0.01$ compared with model.

Figure 1: ZC treatment relieved heat and pain, but showed no effect on alleviating swelling in primary inflammation in adjuvant induced arthritis rats. Rat AA was induced by injection of 0.1 ml of Freund's complete adjuvant into right hind paw. The animals were topically treated with ZC (0.25, 0.5, 0.75 g/kg), and control and model rats were treated topically with inert paste as the control. The clinical parameters were assessed to investigate the effects of ZC on primary and acute inflammation: degree of swelling (A), heat of the ankle joint (B) and mechanical nociceptive thresholds (C).

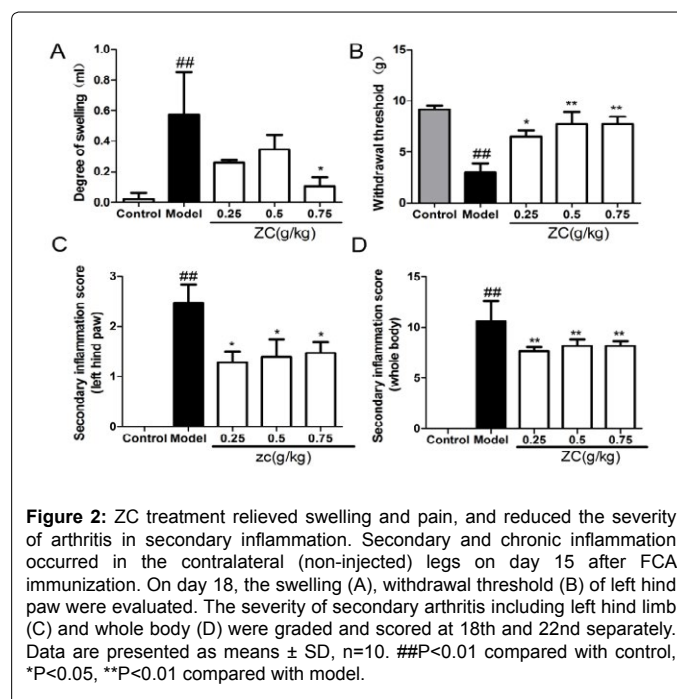
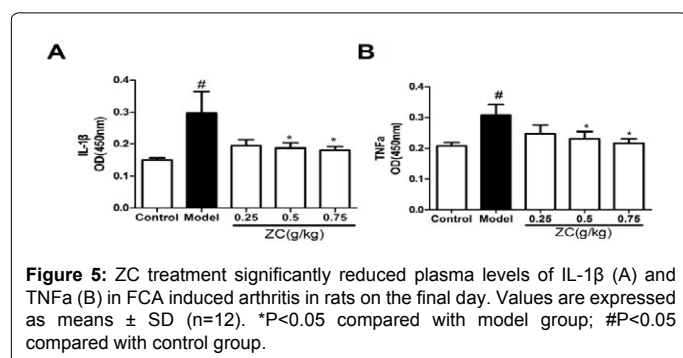
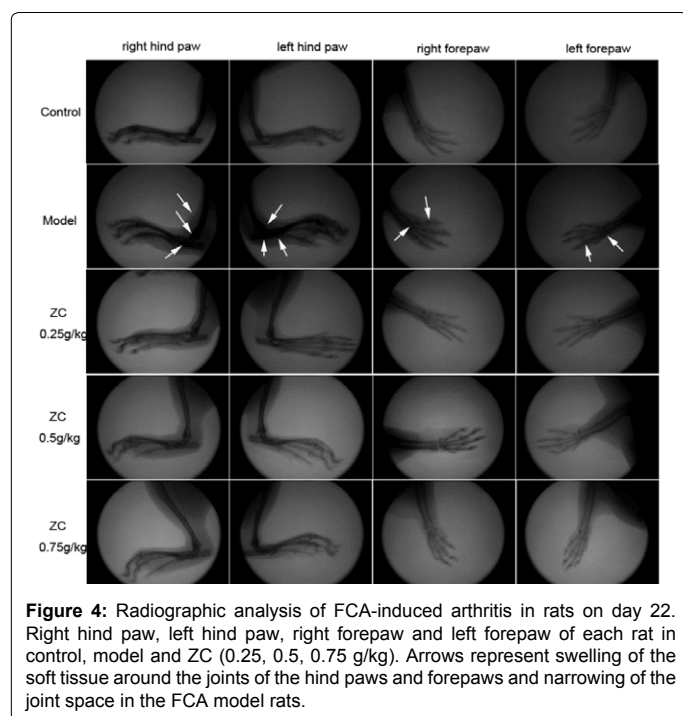
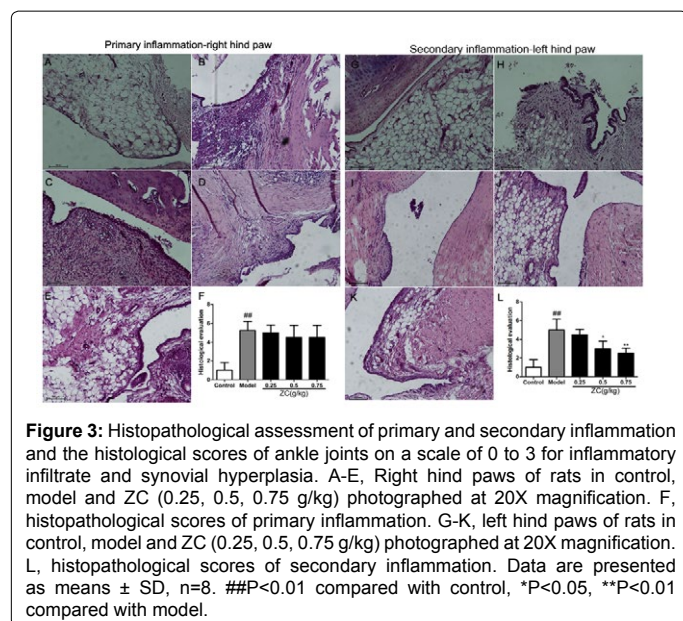


Figure 2: ZC treatment relieved swelling and pain, and reduced the severity of arthritis in secondary inflammation. Secondary and chronic inflammation occurred in the contralateral (non-injected) legs on day 15 after FCA immunization. On day 18, the swelling (A), withdrawal threshold (B) of left hind paw were evaluated. The severity of secondary arthritis including left hind limb (C) and whole body (D) were graded and scored at 18th and 22nd separately. Data are presented as means \pm SD, $n=10$. ## $P<0.01$ compared with control, * $P<0.05$, ** $P<0.01$ compared with model.

had developed definite joint space narrowing of the intertarsal joints, diffuse soft tissue swelling, marked cystic enlargement of bone and extensive erosions. All these pathology above produced narrowing or pseudo widening of ankle joints in both forelimbs and hind limbs. ZC treatment significantly alleviated the swelling and dysarthrosis of joint in left hind paw, right forepaw and left forepaw, which were all caused by secondary inflammation. In contrast, ZC treatment had no obvious effect on the ankle joint in right hind paw which mainly caused by primary inflammation. The results of radiographic studies provided supportive evidence for histopathology analysis.



Effects of ZC on IL-1 β and TNF- α level

Based on this promising observation, we made a further study on the potential mechanism of antiarthritic effect. In terms of plasma level of IL-1 β (Figure 5A), the IL-1 β level of model group was significantly increased compared with that of control group (P<0.05). ZC 0.5 g/kg and 0.75 g/kg treated groups significantly reduced the levels of IL-1 β (P<0.05) compared with model group. Figure 5B showed the level of TNF α in the model group was enhanced significantly compared with that of control group (P<0.05). TNF- α levels of rats received ZC 0.5 g/kg and 0.75 g/kg were dropped significantly (each p<0.05) compared with that of model group.

Currently, although available agents, including the neutralization of cytokines (by soluble receptors or monoclonal antibodies), receptor blockade, and the activation of anti-inflammatory pathways by bioengineered versions of immuno-regulatory cytokines, are effective in suppressing inflammation, but not capable of re-establishing immunological homeostasis, with disease relapse in the majority of patients on drug withdrawal [5]. It is likely that further insights not only into the pathogenesis of inflammation and joint damage, but also into the upstream mechanisms sustaining these processes will be essential to switch off the disease [24]. A large number of compounds of varied chemical structures isolated from medicinal plants have been shown to possess anti-inflammatory activity, and over 300 compounds isolated from plants with anti-inflammatory activity recorded in Chemical Abstracts from 1950-2000 [25]. Zushima has been clinically used in China as an effective traditional Chinese medicine for the treatment of RA. In addition, Daphnetin, the chemical marker for quality evaluation of Zushima and its preparations, has been reported to make important contributions to antiarthritic activity of Zushima [1]. Zushima cataplasms (ZC) are widely used to treat RA patients in clinic at present, and the efficacy is confirmed by amounts of clinical trials [26]. However, there are scarcely reports about the anti-arthritic and anti-inflammatory activity of ZC. Some scientific problems remain unclear. Firstly, the clinical efficacy is not supported by proper and scientific experiment data and the mechanism is not clear. Secondly, RA patients who see a doctor are generally in the secondary inflammation stage. Thus, we cannot understand the efficacy of clinical drugs in primary inflammation or secondary inflammation of RA. This study focused mainly on resolving these two questions.

To support the clinical efficacy initially, we firstly evaluate the anti-arthritis effects of Zushima cataplasm in FCA-induced arthritis rats. AA rat induced by FCA, a rat model is characterized by acute phase (primary inflammation) and a chronic phase (secondary inflammation). It is well known that many reports on RA have revealed that different pathomechanisms play important role in different stages, particularly in primary and chronic stages. In addition, longitudinal studies in human patients with RA have revealed that the production of Th1/Th2-type cytokines are not the same in the primary and chronic stages, which suggests that there may be a shift in the Th1/Th2 balance at different development stages of RA. A Th2 response dominates in the peripheral blood mononuclear cells (PBMCs) at early stages of RA, while long-term chronic RA exhibits a Th1 dominant response [27-29]. Maybe, the reason ZC selectively suppress the secondary inflammation of RA is that ZC affects the Th1 cytokines [30-34].

Conclusion

Based on this study, it could be concluded that the reported studies could partly support the claim about the traditional usage of ZC for the cure of RA in folk medicine. ZC possessed antiarthritic activities mainly due to the inhibition of secondary inflammation, possibly mediated by affecting the levels of IL-1 β and TNF- α . Further studies are needed to clarify the exact mechanisms.

Acknowledgements

We would like to thank Dr. Yang Zhao, University of Sydney, for checking the language for this manuscript.

Conflict of Interest

The authors declare no conflicts of interest.

References

- Gao Q, Shan J, Di L, Jiang L, Xu H (2008) Therapeutic effects of daphnetin on adjuvant-induced arthritic rats. *Journal of Ethnopharmacology* 120: 259-263.
- Tag HM, Kelany, Tantawy, Fahmy (2014) Potential anti-inflammatory effect of lemon and hot pepper extracts on adjuvant-induced arthritis in mice. *The Journal of Basic & Applied Zoology*: 1-9.
- Wright HL, Moots RJ, Bucknall RC, Edwards SW (2010) Neutrophil function in inflammation and inflammatory diseases. *Rheumatology* 49: 1618-31.
- Wang B (2014) Anti-arthritic effect of astragaloside IV and its molecular mechanism. *Inflammation and Cell Signaling* 1: e130
- Antonio M, Michele B, Frances H, Costantino P (2010) Secondary and ectopic lymphoid tissue responses in rheumatoid arthritis: from inflammation to autoimmunity and tissue damage/remodeling. *Immunological Reviews* 233: 267-285
- Bing L, Hong Z, Zhao X, Khalid R, Ying W, et al. (2013) Inhibitory effects of the root extract of *Litsea cubeba* (Lour.) Pers. on adjuvant arthritis in rats. *Journal of ethnopharmacology* 147: 327-334.
- Lee A, Qiao Y, Grigoriev G, Chen J, Park-Min K H, et al. (2013) Tumor necrosis factor alpha induces sustained signaling and a prolonged and unremitting inflammatory response in rheumatoid arthritis synovial fibroblasts. *Arthritis and rheumatism* 65: 928-938.
- Iain B M, Georg S (2011) The pathogenesis of rheumatoid arthritis. *N Engl J Med* 365: 2205-2219.
- Firestein GS (2003) Evolving concepts of rheumatoid arthritis. *Nature* 423: 356-361.
- Ernest HS, Choy MD, Gabriel Panayi MD (2001) Cytokine Pathways and Joint Inflammation in Rheumatoid Arthritis. *N Engl J Med* 344: 907-916.
- Sattar N, Mccarey DW, Capell H, McInnes IB (2003) Explaining how "high-grade" systemic inflammation accelerates vascular risk in rheumatoid arthritis. *Circulation* 108: 2957-2963.
- Vinod N, Surender S, Gupta YK (2011) Evaluation of the disease modifying activity of *Colchicum luteum* Baker in experimental arthritis. *Journal of Ethnopharmacology* 133: 303-307.
- Zhang CF, Zhang SL, He X, Yang XL, Wu HT, et al. (2014) Antioxidant effects of *Genkwa flos* flavonoids on Freund's adjuvant-induced rheumatoid arthritis in rats. *Journal of Ethnopharmacology* 153: 793-800.
- Jiang CP, He X, Yang XL, Zhang SL, Li H, et al. (2014) Anti-rheumatoid arthritic activity of flavonoids from *Daphne genkwa*. *Phytomedicine: International journal of phytotherapy and phytopharmacology* 21: 830-837.
- Talwar S, Nandakumar K, Nayak PG, Bansal P, Mudgal J, et al. (2011) Anti-inflammatory activity of *Terminalia paniculata* bark extract against acute and chronic inflammation in rats. *Journal of Ethnopharmacology* 134: 323-328.
- Bao Y, Gao Y, Du M, Hou W, Yang L, et al. (2015) Topical Treatment with Xiaozheng Zhitong Paste (XZP) Alleviates Bone Destruction and Bone Cancer Pain in a Rat Model of Prostate Cancer-Induced Bone Pain by Modulating the RANKL/RANK/OPG Signaling. *Evidence-Based Complementary and Alternative Medicine*: 1-14.
- Hulse RP, Beazley-Long N, Hua J, Kennedy H, Prager J, et al. (2014) Regulation of alternative VEGF-A mRNA splicing is a therapeutic target for analgesia. *Neurobiology of disease* 71: 245-259.
- Ellis A, Wieseler J, Favret J, Johnson KW, Rice KC, et al. (2014) Systemic Administration of Propentofylline, Ibudilast, and (+)-Naltrexone Each Reverses Mechanical Allodynia in a Novel Rat Model of Central Neuropathic Pain. *The Journal of Pain* 15: 407-421.
- Naoto H, Takaharu N, Itsuro H, Hayato K, Takako Y, et al. (2013) Muscle wasting associated with pathologic change is a risk factor for the exacerbation of joint swelling in collagen-induced arthritis in cynomolgus monkeys. *BMC Musculoskeletal Disorders* 14: 205-214.
- Snehalatha U, Anburajan M, Venkatraman B, Menaka M (2012) Evaluation of complete Freund's adjuvant-induced arthritis in a Wistar rat model. *Zeitschrift für Rheumatologie* 72: 375-382.
- Yamaguchi T, Kakefuda R, Tanimoto A, Watanabe Y, Tajima N (2012) Suppressive effect of an orally active MEK1/2 inhibitor in two different animal models for rheumatoid arthritis: a comparison with leflunomide. *Inflammation research* 61: 445-454.
- Bevaart L, Vervoordeldonk MJ, Tak PP (2010) Evaluation of therapeutic targets in animal models of arthritis: how does it relate to rheumatoid arthritis? *Arthritis and rheumatism* 62: 2192-2205.
- Divya G, Arulmozhi S, Subhash LB, Kakasaheb RM (2014) Anti-arthritic and in vivo antioxidant effect of *Hibiscus rosa-sinensis* in Freund's complete adjuvant induced arthritis. *Der Pharmacia Lettre* 6: 172-187.
- Ash Z, Gaujoux-Viala C, Gossec L, Hensor EM, Fitzgerald O, et al. (2012) A systematic literature review of drug therapies for the treatment of psoriatic arthritis: current evidence and meta-analysis informing the EULAR recommendations for the management of psoriatic arthritis. *Annals of the rheumatic diseases* 71: 319-326.
- Perez RM (2001) Anti-inflammatory activity of compounds isolated from plants. *The Scientific World Journal* 1: 713-784.
- Liang S, Shen Y, Feng Y, Tian J, Liu X, et al. (2010) Terpenoids from *Daphne aurantiaca* and their Potential Anti-inflammatory Activity. *J Nat Prod* 73: 532-535.
- Gerli R, Bistoni O, Russano A, Fiorucci S, Borgato L, et al. (2002) In vivo activated T cells in rheumatoid synovitis. Analysis of Th1- and Th2-type cytokine production at clonal level in different stages of disease. *Clin Exp Immunol* 129: 549-555.
- Burmester GR, Feist E, Dorner T (2014) Emerging cell and cytokine targets in rheumatoid arthritis. *Nature reviews. Rheumatology* 10: 77-88.
- Davignon JL, Hayder M, Baron M, Boyer JF, Constantin A, et al. (2013) Targeting monocytes/macrophages in the treatment of rheumatoid arthritis. *Rheumatology* 52: 590-608.
- Okuda Y, Ohnishi M, Matoba K, Jouyama K, Yamada A, et al. (2014) Comparison of the clinical utility of tocilizumab and anti-TNF therapy in AA amyloidosis complicating rheumatic diseases. *Modern rheumatology/The Japan Rheumatism Association* 24: 137-143.
- Steffen G, Renate EG, William JK (1993) Molecular and cellular mechanisms of joint destruction in rheumatoid arthritis: two cellular mechanisms explain joint destruction? *Annals of the rheumatic diseases* 52: 39-47.
- Van Hamburg JP, Asmawidjaja PS, Davelaar N, Mus AM, Colin EM, et al. (2011) Th17 cells, but not Th1 cells, from patients with early rheumatoid arthritis are potent inducers of matrix metalloproteinases and proinflammatory cytokines upon synovial fibroblast interaction, including autocrine interleukin-17A production. *Arthritis and rheumatism* 63: 73-83.
- Zivojinovic SM, Pejnovic NN, Sefik-Bukilica MN, Kovacevic LV, Soldatovic II, et al. (2012) Tumor necrosis factor blockade differentially affects innate inflammatory and Th17 cytokines in rheumatoid arthritis. *The Journal of rheumatology* 39: 18-21.
- Zvaifler NJ (1973) The Immunopathology of Joint Inflammation in Rheumatoid Arthritis. *Adv Immunol* 16: 265-336.