

## Angiomyolipoma of the Testis: A Case Report

Wadah Ceifo<sup>1\*</sup>, Imad Al Qadri<sup>1</sup> and Anupama Malik<sup>2</sup>

<sup>1</sup>Department of Urology, Al-Jahra Hospital, Kuwait

<sup>2</sup>Department of Histopathology, Al-Jahra Hospital, Kuwait

### Abstract

Angiomyolipoma, AML is a benign tumor that is composed of a mixture of fat, smooth muscle cells, and blood vessels. It is particularly associated with tuberous sclerosis, which mainly involves the kidneys. Herein we present a case of testicular AML in a 25 years male presented to urology clinic complains of mild hardness and swelling over his right testis without any history of blunt trauma with nonspecific ultrasound study of the testis and normal testicular tumor markers, diagnosed only on the base of histopathological examination post orchiectomy, review of literatures of such cases.

**Keywords:** Testis; Tumor; Angiomyolipoma

### Introduction

Testicular Angiomyolipoma (AML) is extremely rare tumor encountered in clinical practice. However the cellular origin of testicular angiomyolipoma remains unknown. It might be a rare subtype of the testicular teratoma of germ cell origin. These lesions also occasionally arise in extra renal locations, including the lung, liver and skin [1].

### Case Report

A 25 year previously healthy male patient presented to urology clinic complains of mild hardness and swelling over his right testis started suddenly before one day without any history of testicular pain or blunt trauma. The pain was almost continuous with dragging and dull aching sensation and was associated with mild testicular swelling. The pain and swelling gradually increases in severity. There was no associated colour or temperature change over the swelling. Past medical or surgical history was unremarkable. General examination was also unremarkable, local examination revealed mild tender swelling of right testis, fluctuating in nature, trans-illumination test was negative, right spermatic cord and inguinal region were normal. Left testis was normal with mild varicocele of left testicular venous plexus.

His Laboratory investigations including testicular tumor markers were in normal range (Alpha-Fetoprotein: 3µg/L, Human Chorionic Gonadotropin: 1500 mIU/mL).

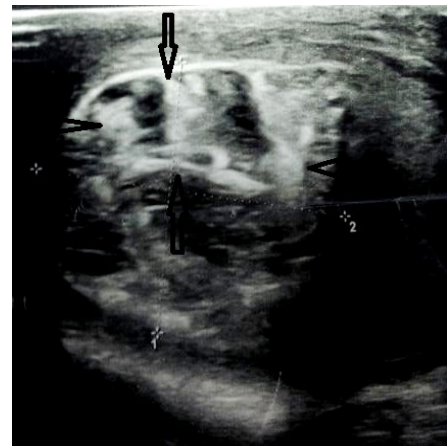Ultrasonographic evaluation revealed confusing picture with smaller right testis with hypoechoic pattern with reduced vascularity and complex heterogenous hyperechoic lesion within the testicular capsule (Figure 1), whereas the abdominal and pelvic study was normal. Scrotal nuclear medicine scan showed increasing of blood flow in the right hemi-scrotum with a large central photon deficient area which is equivocal for missed torsion or a space occupying lesion. Inguinal Exploration of the right Testis performed, the Testis found hard with regular margin, the epididymis and spermatic cord were normal.

Frozen section biopsy was done intraoperative and the microscopic examination showed areas of testicular infarction and possible of Existence of a benign tumor in the rest of the sample, so right orchiectomy was done. The Final Histopathological examination reveals that the testis measured 4x3x3cm and the spermatic cord 6.5x2cm. A hematoma was identified on cutting (2x1.7cm) while the rest of the testicular tissue appeared necrotic (Figure 2). Microscopy showed infarcted testis, organizing hematoma and a partly infarcted lesion composed of cavernous blood vessels (Hematoxylin & eosin stain), adipose tissue and smooth muscle bundles around vessels

(Figure 3), (Masson's trichrome stain). The latter is also highlighted by the muscle marker desmin on immunohistochemistry (Figure 4). The overall morphological features are diagnostic of angiomyolipoma. However, the HMB-45 immunostains was negative. The patient was discharged in a very good general condition and follow up 6 month, 1 year later with CT (chest, abdomen, and pelvis) showed no evidence of any recurrence and he still under our care in out-patient clinic.

### Discussion

Angiomyolipoma is a rare benign tumor, presents in women over 50 years of age, which mainly involves the kidneys and 20% associated particularly with tuberous sclerosis. This tumor is consisting of thick-walled blood vessels, smooth muscle, and adipose tissue [2]. It was initially regarded as a form of hamartoma, but today is considered to be a tumor derived from perivascular epithelioid cells, which can affect



**Figure 1:** Ultrasonography of the Scrotum: showing smaller right testis with hypoechoic pattern and complex heterogenous hyperechoic lesion within the testicular capsule (arrow).

**\*Corresponding author:** Wadah Ceifo, Department of Urology, Al-Jahra Hospital, Kuwait, Tel.: 0096597390065, Fax: 24569431; E-mail: [wceifo@gmail.com](mailto:wceifo@gmail.com)

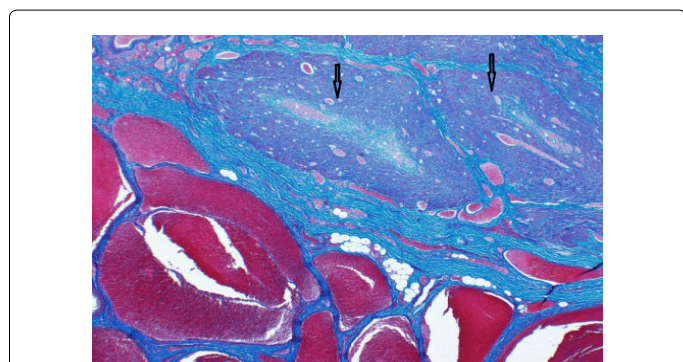
**Received** September 18, 2015; **Accepted** October 16, 2015; **Published** October 21, 2015

**Citation:** Ceifo W, Qadri IA, Malik A (2015) Angiomyolipoma of the Testis: A Case Report. Med Surg Urol 4: 155. doi:10.4172/2168-9857.1000155

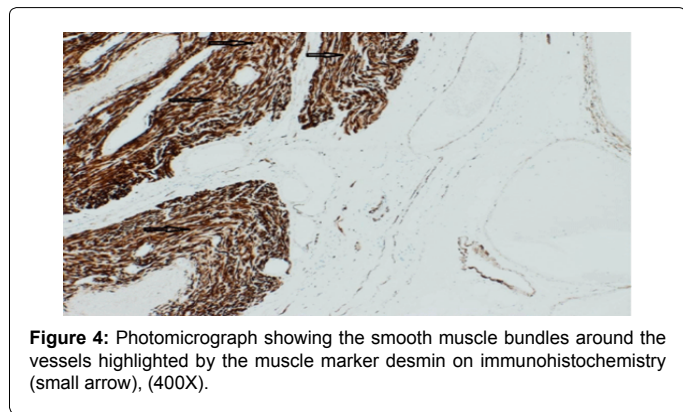
**Copyright:** © 2015 Ceifo W, et al. This is an open-access article distributed under the terms of the Creative Commons Attribution License, which permits unrestricted use, distribution, and reproduction in any medium, provided the original author and source are credited.



**Figure 2:** Photograph showing: The testis measured (4x3x3cm). A hematoma and necrosis was identified on cutting (short arrow), while the rest of the testicular tissue appeared pale and hard, AML of the testis (long arrow).



**Figure 3:** Photomicrograph exhibiting a partly infarcted lesion composed of cavernous blood vessels, Adipose tissue and smooth muscle bundles around the vessels (small arrow), (Masson's trichrome stain 400X).



**Figure 4:** Photomicrograph showing the smooth muscle bundles around the vessels highlighted by the muscle marker desmin on immunohistochemistry (small arrow), (400X).

the visceral organs including the kidney, lung, Liver, retroperitoneum, pelvis, skin, testis and scrotum [3-8].

The diagnosis and treatment strategy for testicular AML has not been established. Ultrasound is usually an adequate study for evaluation of scrotal region and testis [9].

The conflicting picture of scrotal ultrasound and testicular scan with clinical examination and absence of previous history of trauma of Genitalia made the picture more confusing then we decided to proceed with scrotal exploration which showed necrotic bluish testicular tissue and the intraoperative frozen section microscopic examination was performed and revealed angiomyolipoma of testis, so histopathologic study provided the definite diagnosis.

The Immunohistochemistry for smooth muscle actin (SMA) and endothelial marker (CD34) are typically expressed in AML lesions, but in our case we didn't use it because it was not available in our department of histopathology [9]. The immunohistochemical study with HMB-45[10], which is considered a melanoma associated antigen, as we did in our case, strongly indicated benign testicular AML with a non-germ cell origin, which has been demonstrated as uniformly positive in renal and liver AML, whereas its typically negative in cutaneous and testicular AML and there might be significant biological differences between testicular AML and typical AML in the kidney as the testicular AML in the present case showed negative staining in the entire tumor for HMB-45.

In case of large testis lesions, even if benign, when the organ sparing surgery or conservative surgery (such as partial orchiectomy) is not possible, the role of intraoperative frozen section is limited and radical orchiectomy should be scheduled anyway. This management was necessary in this case where the normal tissue was lost at ultrasound and confirmed by histology. However in small testis lesions (<1.5cm), not palpable and discovered by ultrasound, an organ sparing surgery should be attempted if benign lesion is confirmed by intraoperative frozen section of the surgical specimen. This surgical management of small testis lesion described by Sbrollini G et al. is mainly based on dimension of the lesion and the amount of normal tissue around [11].

To our knowledge, there are only a few cases of a primary testicular AML in the published reports, so long-term follow-up may be required since the true biological nature of testicular AML is still unknown, so the tumor treatment and approach must be modified according to each case.

## Conclusion

Angiomyolipoma is an uncommon, benign tumor that is rarely located in the scrotum. Its diagnosis has not been established. Ultrasound findings of scrotal region can be inconclusive, so histopathologic study can provide the definitive diagnosis in such uncommon tumors, and the approach to the tumor treatment must be modified according to each case.

## References

1. Yang L, Feng XL, Shen S, Shan L, Zhang HF, et al. (2012) Clinicopathological analysis of 156 patients with angiomyolipoma originating from different organs. *Oncol Lett* 3: 586-590.
2. Farrow G, Harrison EG, Utz DC, Jones DR (1968) Renal angiomyolipoma. A clinicopathologic study of 32 cases. *Cancer* 22: 564-570.
3. Marcheix B, Brouchet L, Lamarche Y, Renaud C, Gomez-Brouchet A, et al. (2006) Pulmonary angiomyolipoma. *Ann Thorac Surg* 82: 1504-1506.
4. Tryggvason G, Blöndal S, Goldin RD, Albrechtsen J, Björnsson J, et al. (2004) Epithelioid angiomyolipoma of the liver: case report and review of the literature. *APMIS* 112: 612-616.
5. Gleeson FC, de la Mora Levy JG, Zhang L, Levy MJ (2008) The differential broadens. EUS FNA appearance and cytological findings of pancreatic angiomyolipoma. *JOP* 9: 67-70.
6. Lin CY, Chen HY, Jwo SC, Chan SC (2005) Ileal angiomyolipoma as an unusual cause of small-intestinal intussusception. *J Gastroenterol* 40: 200-203.
7. Singh K, Pai RR, Kini H, Kini UA (2009) Cutaneous angiomyolipoma. *Indian J Pathol Microbiol* 52: 242-243.
8. Tseng CA, Pan YS, Su YC, Wu DC, Jan CM, et al. (2004) Extrarenal retroperitoneal angiomyolipoma: case report and review of the literature. *Abdom Imaging* 29: 721-723.
9. Giulianelli R, Albanesi L, Attisani F, Brunori S, Gentile BC, et al. (2012) A case of angiomyolipoma of the spermatic cord and testicle. *Archivio italiano di Urologia e Andrologia* 84: 165-166.

- 
10. Saito M, Yuasa T, Nanjo H, Tsuchiya N, Satoh S, et al. (2008) A case of testicular angiomyolipoma. *Int J Urol* 15: 185-187.
11. Sbrollini G, Mazzaferro D, Ettamimi A, Montironi R, Cordari M, et al. (2014) Diagnostic-therapeutic pathway for small lesions of the testis. *Arch Ital Urol Androl* 86: 397-399.