

Anatomical Variations of the Common Carotid Artery Bifurcations in Relation to the Cervical Vertebrae in Ethiopia

Woldeyes DH*

Department of Human Anatomy, College of Medicine and Health Sciences, Bahir Dar University, Ethiopia

*Corresponding author: Dawit Habte Woldeyes, Department of Human Anatomy, College of Medicine and Health Sciences, Bahir Dar University, P.O.Box 79, Ethiopia
Tel: 251938221383; E-mail: dwthabte@gmail.com

Rec date: Apr 05, 2014, Acc date: May 30, 2014, Pub date: June 01, 2014

Copyright: © 2014 Woldeyes DH. This is an open-access article distributed under the terms of the Creative Commons Attribution License, which permits unrestricted use, distribution, and reproduction in any medium, provided the original author and source are credited.

Abstract

Background: The carotid arterial system which consists of right and left common carotid arteries is the main arterial supply of the head and neck. Studies show that variations exist to the level of bifurcation of the common carotid artery. Knowledge of these variations is of importance for surgical approaches in the head and neck region, such as carotid endarterectomy, radical neck dissection, catheterization etc, thereby reduce the risk of operative morbidity and mortality in patients undergoing operations, involving the common carotid artery.

Objective: The main purpose of the study was to assess height of the common carotid artery bifurcation in relation to the cervical vertebrae.

Method: Observational based descriptive study was conducted on thirteen human preserved cadavers, which were obtained from the departments of human anatomy, Colleges of Medicine and Health Sciences, Gondar and Bahirdar Universities and Gamby College of Medical Sciences–Bahirdar after the approval of the ethical committee.

Results: The bifurcation of the common carotid artery was found high in 12 (46.15%) of the cases among which the most common levels of bifurcation was at the level of C3 (42.3%). 14 (53.85%) of the cases was standard of which C4 (38.4%) was the most common and low bifurcation was not found. It was also found that in 61.5% of the cases the carotid bifurcation was asymmetrical between the right and left sides.

Conclusions: The present study showed that standard level of bifurcations was found to be more common than high level and low bifurcation was not found. The level of bifurcation was generally asymmetrical between right and left sides. Thus anatomical knowledge of the variability of carotid bifurcation levels will be useful for clinicians, to avoid unnecessary complications.

Keywords: Carotid bifurcation; Carotid artery; Cervical vertebrae; Symmetry; Height of bifurcation.

Introduction

The neck region not only serves to connect the head with the rest of the body, it also houses structures within it that act as conduits for blood and nerve impulses traveling both to and from the brain [1].

Many important structures are crowded together in the neck, such as muscles, glands, arteries, veins, nerves, lymphatics, trachea, esophagus, and vertebrae (within them the cervical segment of the spinal cord); consequently, the neck is a well known region of vulnerability [2]

The structures of the neck are packed so tightly that nearly every lesion expresses itself as a visible or palpable bulge; neoplasms and infection can affect any of the lymph nodes in more than a dozen of the fascial spaces in the neck, Persistent embryonic structures may occupy spaces no longer assigned to them [3].

The carotid arterial system which begins from the common carotid arteries (CCAs) is the main arterial supply of the head and neck. Like other arteries in the vascular system, the carotid arteries can become diseased with cholesterol plaque; this condition may result in carotid

artery stenosis. Atherosclerosis of the carotid arteries is a major cause of stroke and transient ischemic attack. Plaques typically form in the common carotid artery bifurcation and extend distally into the internal carotid arteries (ICAs) [4].

The carotid arteries and the jugular veins lying anterolaterally in the neck are the major structures commonly injured in penetrating wounds of the neck [2]. The disruption of CCA, ECA and ICA may cause a bleeding that can threaten life [5].

Carotid artery injury is uncommon but not a rare complication of various diagnostic and therapeutic procedures. The consequence of inadvertent carotid artery injury may be quite devastating, but its incidence can be reduced by understanding the mechanisms of injury, i.e., how and when it happens. Properly managing the complication can reduce a patient's mortality and morbidity [6].

A high common carotid artery bifurcation possesses a higher risk of being hit by intra articular screws during procedures on cervical the vertebrae [7-15]. Thus, knowledge on the anatomical variations of the carotid bifurcation (CB) is necessary for the correct interpretation of results obtained by means of different radiological procedures and for vascular surgical procedures in the region mainly because of the significant rates of the occurrence of variations. Therefore the current

study aimed to determine the height of CCA bifurcation in relation to cervical vertebrae and its side symmetry in Ethiopian population.

Materials and Methods

Observational based descriptive study design was conducted to describe the CCA bifurcation. A total of thirteen unclaimed cadavers (1 female and 12 male) or 26 specimens (13 cadavers, left and right sides) which were obtained during routine dissection at Departments of Human Anatomy, University of Gondar, Bahirdar University, and GAMBY College of Medical Sciences, Amhara region; Ethiopia.

Ethical approval was obtained from School of Medicine University of Gondar Ethics and Review Committee. Official letters were submitted to the different colleges, explaining the purpose and the importance of the study. Confidentiality was maintained at all levels of the study.

Cadavers which were dry and difficult to dissect, those which were damaged by students before data collection were excluded from the study.

Operational definitions: High bifurcation is division of CCA at the level of 3rd or above 3rd cervical vertebrae, Standard (common) bifurcation is when CCA divides at the level of 4th cervical vertebra or between 3rd and 4th cervical vertebra, Low bifurcation when CCA bifurcates below 4th cervical vertebra.

Procedures

CCA was exposed in the left and right side of the cadavers by the dissection technique which we use regularly for teaching; (According to the standard procedures of Cunningham’s manual of dissection volume III). All dissections were carried out on the bodies placed in supine position on a flat surface with the neck in neutral position, bilateral CCAs, ECAs, and ICAs were dissected.

The anatomical relationship between the CCA bifurcation and of cervical vertebra was inspected on thirteen necks and at its bifurcation CCA was related to the level of transverse process of cervical vertebra in both right and left sides.

Photographs were taken using digital camera (Sony-Model DSC-W610/BQE37 16.1Megapixel) and the data observed was recorded, on the data collection form. Data obtained on the level of bifurcation of CCA, in relation to cervical vertebra was checked for clarity, accuracy and consistency before analysis. Then the data was divided by sides for description of their distribution in the left and right sides. Figures and Tables were used for presentation of the results; analysis was performed manually.

Results

Levels of bifurcations

General information

A total of thirteen unclaimed adult cadavers (1 female and 12 male) or 26 specimens (13 cadavers, left and right sides). The height of cadavers ranges from 165 cm – 180 cm.

All cadavers were found in one state of Ethiopia which was homogenous society (from the aforementioned areas) and the results of the study are summarized as follows:

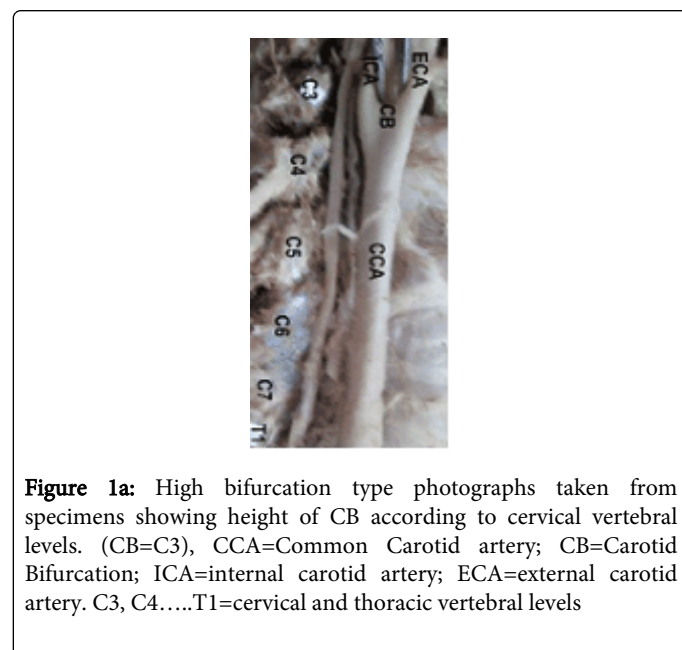
Standard bifurcation of the CCA was found in 14 sides (53.85%) of the cases, of which the most common bifurcation was at the level of C4 (38.5%), high bifurcation occurred in (46.15%) and low bifurcation was not found (Table 1 and Figure 1).

Level of bifurcation		Frequency	percentage
High	C2	-	-
	C2-C3	1	3.85%
	C3	11	42.31%
Standard	C3-C4	4	15.38%
	C4	10	38.46%
Low	C4-C5	-	-
	C5	-	-
	C5-C6	-	-
	C6	-	-
	C6-C7	-	-
Others		-	-

Table 1: Location of the CB according to the studied cervical vertebral levels

Side symmetry

In this study, the level of CB was found in 5(38.5%) of the cases to be symmetrical (same height found at the level of C3 and C4) in the right and left sides. However in 8(61.5%) of the cases the level of CB was found to be asymmetrical; right side higher in 38.5% and left side higher in 23% of the cases (Table 2).



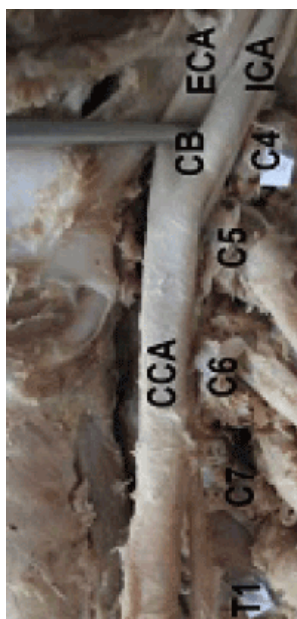


Figure 1b: Standard bifurcation type photographs taken from specimens showing height of CB according to cervical vertebral levels. (CB=C4), CCA=Common Carotid artery; CB=Carotid Bifurcation; ICA=internal carotid artery; ECA=external carotid artery. C3, C4.....T1=cervical and thoracic vertebral levels

Cadaver number	Level of bifurcation	
	Right side	Left side
1	C2-C3	C3
2*	C3	C3
3	C3-C4	C3
4*	C3	C3
5	C3	C4
6	C3	C4
7*	C4	C4
8	C3-C4	C4
9	C4	C3-C4
10	C4	C3-C4
11	C3	C4
12*	C4	C4
13*	C3	C3

Table 2: Distribution of CB according to the cervical vertebra in right and left sides of each cadaver. (* Symmetrical between right and left sides; Cadaver 2 is a female cadaver)

Discussion

Height of bifurcation of the common carotid artery

It is commonly accepted that the CCA bifurcation occurs at about the level of the 4th cervical vertebra for clinicians [16]. Nevertheless, most anatomical text books and references in the literature describe the upper border of the thyroid cartilage as the bifurcation level, With the advent of the radiological investigations, and the need of a more accurate interpretation of them, external anatomical land marks turned to be useful, in regular clinical practice [15,17].

The level of the CCA bifurcation is subject to individual variations; the CCAs may bifurcate higher or lower than the usual levels [8]; a high bifurcation is more common, the bifurcation can occur as high as the hyoid bone (C3) or even the styloid process, or as low as the cricoid cartilage (C6). Variations are of importance for surgical approaches in the head and neck region [8].

According to the results of this study standard bifurcation of the CCA was found in 14 sides (53.85%) of the cases, of which the most common bifurcation was at the level of C4 (38.5%). This is comparable to studies in done in Japan (57.5%) [13] and Croatia (50%) [14].

However high bifurcation occurred in (46.15%) in this study and this is not comparable to any of the studies mentioned in the literatures; these differences which were encountered between the results of the other studies and of this study may be due to the difference in the number of samples used in the studies (Table 3).

In this study low bifurcation is not found but in a research done in Croatia [14] 12.5% and in New Zealand [11]. 5% were low bifurcations; these differences may be due to the number of samples used for the study and may be because this variation is rare variation (Table 3).

Study area	No. of specimens used	Result		
		Standard bifurcation	High bifurcation	Low bifurcation
Japan	80 sides	57.5%	31.2%	11.3%
Croatia	40 sides	50%	37.5%	12.5%
Newzealand	67 sides	39%	55%	5%
Saudi Arabia	60 sides	67%	28%	6%
Kenya	80 sides	30%	63.8%	6.25%
This study	26 sides	53.85%	46.15%	0%

Table 3: Summary of researches done in different areas of the world show the following results

Side symmetry of CCA Bifurcation

Although the level of bifurcation can vary from C1 to T2, in individuals the left and right CB are usually at the same level [12]. in this study 38.5% of the cases were symmetrical (found at the level of C3 and C4) in right and left sides and 61.5% of the cases were asymmetrical; right higher in 38.5%, left higher in 23% of the cases (Table 2). According to the study done in U.S.A, significant

asymmetry between left and right CB levels were found: left higher in 50%, right higher in 22%, same height in 28% [9].

A study conducted in India; on 95 cadavers showed that the bifurcation level of the CCA was determined to be asymmetrical; left side higher in 9% of the cases [8]. These are in contrast to this study which shows right side higher in 38.5%.

In a study done in Newzealand on 67 specimens (36 cadavers), 15 of 31 cadavers (48%), the level of CCA bifurcations were asymmetrical between the left and right sides [10]. The level of bifurcation according to the research done in Kenya on 40 cadavers was symmetrical in all cases [7], and another study done in Japan, Tokyo, on 49 cadavers found no difference in level between the two sides in all cases [13].

Conclusions

In all cases CCA bifurcates on the neck region and absence of bifurcation was not found. Standard level of bifurcation was found to be more common. Low bifurcation was not found in this study and the level of carotid bifurcation was generally asymmetrical and higher on the right side than on the left side.

Although the sample size is limited to generalize our data, Clinicians need to take the standard and variable heights of the carotid bifurcation into consideration; to avoid unnecessary complications. Further research needs to be done on large number specimens so that generalizations for the population will be more accurate.

Acknowledgement

I would like to acknowledge Aseggedech Bekele (Ph.D., Associate professor), Prof. Dieter Reissig, Mr. Wagnew Mitiku for their technical assistance and departments of human anatomy, Gondar, Bahirdar Universities and Gamby College of Medical Sciences - Bahirdar for allowing me to use the available cadavers.

References

1. Shane TR, Mark R, Loukas M, Shoja MM, Mortazavi M, et al. (2011) Use of the triangle of Farabeuf for neurovascular procedures of the neck. *Biomedicine International* 2:39-42.
2. Moore K, Dalley A, Agur A (2010) *Anterior cervical region: Clinically oriented Anatomy*. 6th ed. Lippincott Williams & Wilkins, Philadelphia 998-1012.
3. Skandalakis J, Gray S, Rowe J. *Anatomical complications in general surgery* :1.
4. Adams GJ, Simoni DM, Bordelon CB Jr, Vick GW 3rd, Kimball KT, et al. (2002) Bilateral symmetry of human carotid artery atherosclerosis. *Stroke* 33: 2575-2580.
5. Ozgur Z, Govsa F, Ozgur T (2008) Anatomic evaluation of the carotid artery bifurcation in cadavers: implications for open and endovascular therapy. *Surg Radiol Anat* 30: 475-480.
6. Inamasu J, Guiot BH (2005) Iatrogenic carotid artery injury in neurosurgery. *Neurosurg Rev* 28: 239-247.
7. Anangwe DI, Saidi H, Ogeng'o J, Awori KO (2008) Anatomical variations of the carotid arteries in adult Kenyans. *East Afr Med J* 85: 244-247.
8. Anu VR, Pai MM, Rajalakshmi R, Latha VP, Rajanigandha V, et al. (2007) Clinically-relevant variations of the carotid arterial system. *Singapore Med J* 48: 566-569.
9. Radswiki, Jeremy J et al. (2012) *Internal carotid artery*
10. Lo A, Oehley M, Bartlett A, Adams D, Blyth P, et al. (2006) Anatomical variations of the common carotid artery bifurcation. *ANZ J Surg* 76: 970-972.
11. Lemaire V, Jacquemin G, Nelissen X, Heymans O (2005) Tip of the greater horn of the hyoid bone: a landmark for cervical surgery. *Surg Radiol Anat* 27: 33-36.
12. Zumre O, Salbacak A, Cicekcibasi AE, Tuncer I, Seker M (2005) Investigation of the bifurcation level of the common carotid artery and variations of the branches of the external carotid artery in human fetuses. *Ann Anat* 187: 361-369.
13. Hayashi N, Hori E, Ohtani Y, Ohtani O, Kuwayama N, et al. (2005) Surgical anatomy of the cervical carotid artery for carotid endarterectomy. *Neurol Med Chir (Tokyo)* 45: 25-29.
14. Lucev N, Bobinac D, Maric I, Drescik I (2000) Variations of the great arteries in the carotid triangle. *Otolaryngol Head Neck Surg* 122: 590-591.
15. Agur A, Arthur D. (2009) *Deep dissection of carotid triangle: Granta's Atlas of Anatomy*. (12th edn), Lippincott Williams & Wilkins 765.
16. Avadhani R, Chakravarthi K. (2012) Multiple bilateral anomalies of carotid arteries. *NUJHS* 2.
17. Ellis H (2006) *The head and neck: Clinical Anatomy A revision and applied anatomy for clinical students*. (11th edn), Blackwell publishing.