

Analysis with Ultrasound of Different Surgical Meshes for Abdominal Hernia Repair: Experimental Study

Grossi JVM^{1*}, Manna BB², Montes JHM³, Nicola RF³, Nery LA², Cavazzola S⁴, Cavazzola LT⁵ and Leão HZ⁶

¹Resident of Gastrointestinal Surgery, Department of Surgery, General Surgery, Saint Lucas Hospital, Pontific Catholic University of Porto Alegre, PUCRS Porto Alegre-RS, Brazil

²Faculty of Medicine, Lutheran University of Brazil, Brazil

³Department of Radiology, Saint Lucas Hospital, Pontific Catholic University of Porto Alegre RS, Brazil

⁴Faculty of Medicine, Lutheran University of Brazil, Brazil

⁵Full Professor of Morphology and Surgery, Faculty of Medicine, Lutheran University of Brazil, Brazil

⁶Full Professor of Human Anatomy, Federal University of Rio Grande do Sul, Porto Alegre - RS, Brazil

*Corresponding author: João Vicente Machado Grossi, Department of Surgery, General Surgery, Saint Lucas Hospital, Pontific Catholic University of Porto Alegre, PUCRS Porto Alegre-RS, Brazil, Tel: 55 51 81550660; E-mail: jvicentegrossi@gmail.com

Rec date: Apr 12, 2014, Acc date: June 14, 2014, Pub date: June 16, 2014

Copyright: © 2014 Grossi JVM, et al. This is an open-access article distributed under the terms of the Creative Commons Attribution License, which permits unrestricted use, distribution, and reproduction in any medium, provided the original author and source are credited.

Abstract

Objective: To evaluate the ultrasound dampening effect of the different types of meshes abdominal surgery after implantation in Wistar rats.

Method: We used two Wistar rats, assessed positions and different types of meshes. The animals were anesthetized prior to surgery to open the abdominal cavity for placement of the prosthesis. Divided into three stages, 1) analysis of the abdominal cavity with ultrasound and no mesh 2) onlay position (mesh placed anterior the abdominal muscles) 3) underlay (intraperitoneal) for the posterior muscular. The meshes were used polypropylene (PP), polyester (PE), polypropylene/poliglecaprone (PU), polytetrafluoroethylene condensate (MO), polyester/collagen (PC) and polypropylene/polydioxanone/oxidized regenerated cellulose (PRO). The animals were euthanized after the procedure.

Results: There was no need to exclude the animals. The initial assessment showed no areas of difficulty or ease that would harm the exam. In all analyzes there was no problem identifying the the skin and subcutaneous tissue. There was a statistically significant difference in the attenuation of the meshes in both the onlay position $p < 0.001$. Underlay position there was a small improvement in the graduation, with PE median (min-max) of 3 (2-5), PP, PU with 2 (1-5) and PC 2 (2-5) followed by PRO mesh with 1 (2-5) and MO with 0 (0-5) with statistical significance at $p = 0.001$. However there was no comparison to the same mesh in two positions on the all meshes.

Conclusion: All types of meshes used in this study was independent of the position of the sound degree attenuation in ultrasound examination. The polyester mesh got to take a lower degree of attenuation compared with other meshes of the study. Is needed a new test to check the attenuation in the long term.

Keywords:

Incisional-hernia; Mesh; Adhesions; Polypropylene; Polyester; Ultrasound; Attenuation

Introduction

Prostheses and biomaterials represent a major contribution in the repair of abdominal wall defects. Currently, its use is accepted and spread throughout the world, especially in difficult and recurrent in both conventional surgery and laparoscopic hernia repair in approach [1].

Currently there is a wide variety of biomaterials that can be used in the repair of hernias. The lack of consensus on the use of these meshes become necessary analyzes the advantages and disadvantages of each one specifically.

The present study is an object of these questions of how to establish parameters that may indicate a better screen for postoperative monitoring of hernia repair work being graduation graduate in Functional Anatomy Imaging on Lutheran University of Brazil. His proposal is to evaluate parameters such as the degree of ultrasound attenuation of different types of meshes, from the intra- and extraperitoneal placement of prostheses six different compositions in adult Wistar rats. The fabrics used are monofilament polypropylene (Marlex®), multifilament polyester (Parietex®), absorbable and nonabsorbable part, polypropylene polyglecaprone (UltraPro®), condensed polytetrafluoroethylene (PTFEc - MottifMesh®), polypropylene/polydioxanone associated with oxidized cellulose regenerated (Proceed®), polyester coated with collagen (Parietex Composite®).

Methods

Delineation

The present study was conducted in the form of a longitudinal experimental, prospective study. Developed on the premises of the bioterium, Lutheran University of Brazil (ULBRA) through the use of the protocols used by the institution and approved by the ethics committee itself.

Sample

Was used for sample 2 Wistar rats (*Rattus norvegicus albinus* Rodentia mammalia). Adult with 30 weeks of life. The animals were housed in the same cage until the period of the examination, at a temperature between 22°C and 24°C, with supply of water and food ad libitum (ration Nuvital, Nuvilab, Colombo, PR, Brazil). The animals were randomly allocated by a simple draw.

Inclusion criteria

- 1) Wistar rat aged 30 weeks or weighing more than 450 grams
- 2) Do not have brothers
- 3) Have not undergone previous treatment

Exclusion criteria

- 1) Visible anatomical distortion before the ultrasound
- 2) Visible anatomical distortion during the ultrasound examination
- 3) Anatomic distortion viewed at necropsy

Sequence of procedure

Two animals that were on ultrasound met all the criteria above. Initially anesthetized prior to examination to identify the structures evaluated.

Times of measurement

- 1) Analysis of ultrasound abnormalities of the abdominal cavity; gone to the next step and score check sonographic scores negative.
- 2) Insert each prior to the rectus abdominis mesh below the subcutaneous tissue and attempt to visualize the proposed structures, being replaced until the sixth mesh to be seen by switching the animals and masked analysis of the radiologist;
- 3) Evaluation and visualization in the intraperitoneal position with ultrasound for examination of abdominal structures.

Procedures

For the procedures, the animals were anesthetized with an intramuscular injection of Xylazine (0.1 ml of 2% solution diluted in 0.2 ml of 0.9% saline) at a dose 5 mg/kg and an intramuscular injection of ketamine (0.35 ml of 50 mg/ml solution) at a dose of 50 mg/kg, as directed by the responsible veterinary bioterium.

After anesthetic induction, the animals were placed in the supine position correctly and members with the help of cords were fixed. Shaving the anterior abdominal wall, and then antiseptic with an alcoholic solution of 2% chlorhexidine was performed [2-21].

Ultrasound examination was performed by an experienced radiologist masked to the types of meshes and positioning the mesh (before or after the abdominal wall muscles). The ultrasound device used in the analysis was a model Medison SA-5500 Sonoace CO.LTDA (digital), Korea. The frequency of 7.5 MHz transducer (probe) to capture linear images and recorded using camera Sony DSC 1154 (Tokyo, Japan).

After antiseptics, lateral skin incision was made was made larger area to leave a smooth surface for ultrasound analysis. After, there was a dissection of the subcutaneous and placement of meshes one by one leaving exposed only the area of comparative interest.

In the third steps, the median 4 cm incision was made to access the peritoneal cavity and insertion of the mesh under the rectus abdominis and new ultrasound analysis. The incision was closed in plans with suture mononylon 4.0 continuous. After the end of the procedure the animal was euthanized closed with carbon monoxide with one-way valve system camera. After euthanasia, review of abnormality of the abdominal cavity was performed. The degree of visualization was identified according to the tables of the degree of ultrasound visualization [22,23] (Table 1).

Degree	Definition
5	Normal
4	Minimal restriction
3	Partly distinguishes
2	Distinguished, but with restrictions
1	Unable to distinguish the structures
0	Not displayed structures (acoustic shadow)

Table 1: Description of the degree of visualization by ultrasound attenuation

Variables

The study evaluated the following variables: the normal presence and distribution of the structures in the abdominal cavity and wall. Were evaluated by scores from (Table 1) the structures skin, subcutaneous tissue, muscles of the anterior wall, liver, spleen, kidney, bowel and bladder, with or without the presence of prosthesis in two different positions. The position described as onlay was placed anterior to the abdominal wall prosthesis and underlay placed intraperitoneally (on the posterior of the abdominal wall).

Data analysis

Continuous variables were described by median, minimum and maximum. The categorical variables were described in association. The test used was the Wilcoxon and Friedman verifies the association between variables. In all tests the significance level of 5% was used. Analyses were performed using SPSS (Statistical Package for Social Science) version 17.0.

Ethical aspects

This work was submitted to the Lutheran University of Brazil Ethics Committee, passed in accordance with the protocols required by this committee for experiments to be conducted on animals.

Financial aspects

The survey was conducted only with resources from researchers without support from external sponsors or companies having no conflicts of interest in this study.

Results

All animals offered for analysis met the criteria for the study. At the initial examination was not found anatomical changes. The thickness of the skin and subcutaneous tissue was 3 mm, with the same measure in relation to the muscles of the anterior abdominal wall, in the two animals (Figure 1).

In the evaluation of the prostheses placed in both the anterior abdominal wall muscles (onlay) and the position intraperitoneal (underlay) position was no loss of display quality in all devices used.

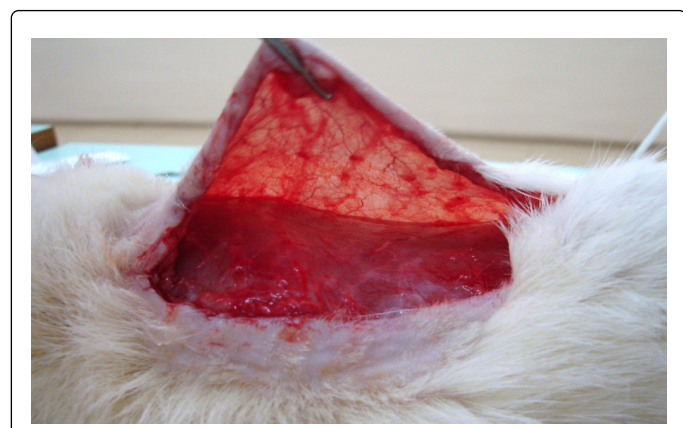

Figure 1: Lateral incision for insertion of the meshes in onlay position




Figure 2: Different types of meshes used: a) Polypropylene, b) Polypropylenepolyglecaprone, c) Polypropylene-polydioxanon/cellulose oxidized regenerated, d) Polyester/collagen and e) polyester, f) condensed polytetrafluoroethylene (PTFEc)

The analysis of the meshes in the attenuation was no difference between the meshes in the same position with $p < 0.001$ and $p = 0.001$ for onlay to underlay (Figure 2 and Table 2). Graduation of the meshes relative to onlay placement (Figure 3) presented with PE mesh structures analyzed a median of 2 with a

minimum of 2 and maximum of 5. Meshes PP, PU and PC had similar view with respect to a median of 2 and a minimum of 1 and maximum of 5. Then the PRO mesh with a median of 1, minimum 1 and maximum of 5, with the worst performance and effect of posterior acoustic shadowing the MO mesh with median 0, minimum 0, maximum 5).

Type of Meshes	Onlay	Underlay	Value-p*
	Md (min – max)	Md (min – max)	
PP polypropylene	2 (1 – 5)	2 (1 – 5)	0,257
PE- Polyester	2 (2 – 5)	3 (2 – 5)	0,102
UP - PP/ polyglecaprone	2 (1 – 5)	2 (1 – 5)	0,102
MO - (PTFEc)	0 (0 – 5)	0 (0 – 5)	0,317
PRO - PP/ cellulose	1 (1 – 5)	1 (2 – 5)	0,059
PC - Polyester/ collagen	2 (1 – 5)	2 (2 – 5)	0,102
Value-p**	<0,001	0,001	

* test of Wilcoxon ** test of Friedman

Table 2: Distribution of median score in the ultrasound analysis of the meshes and the position in relation to the muscles of the anterior wall (md=median, min=minimum and max=maximum)

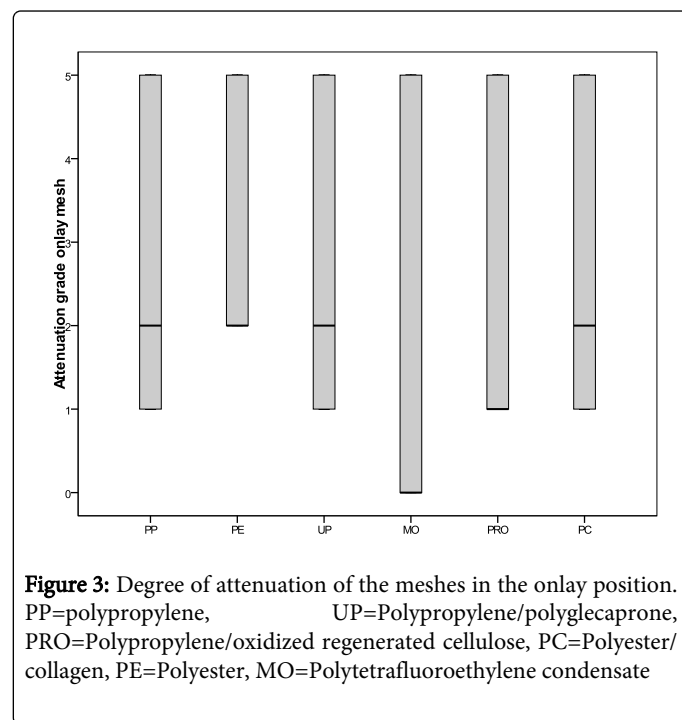


Figure 3: Degree of attenuation of the meshes in the onlay position. PP=polypropylene, UP=Polypropylene/polyglecaprone, PRO=Polypropylene/oxidized regenerated cellulose, PC=Polyester/collagen, PE=Polyester, MO=Polytetrafluoroethylene condensate

Underlay in position (Figure 4) remained the same relationship of onlay and there was a small improvement in the graduation, with PE median (min-max) of 3 (2-5), PP, PU with 2 (1-5) and PC 2 (2-5) followed by PRO mesh with 1 (2-5) and MO with 0 (0-5) with

statistical significance at $p=0.001$, using the Friedman test (Table 2 and Figure 5).

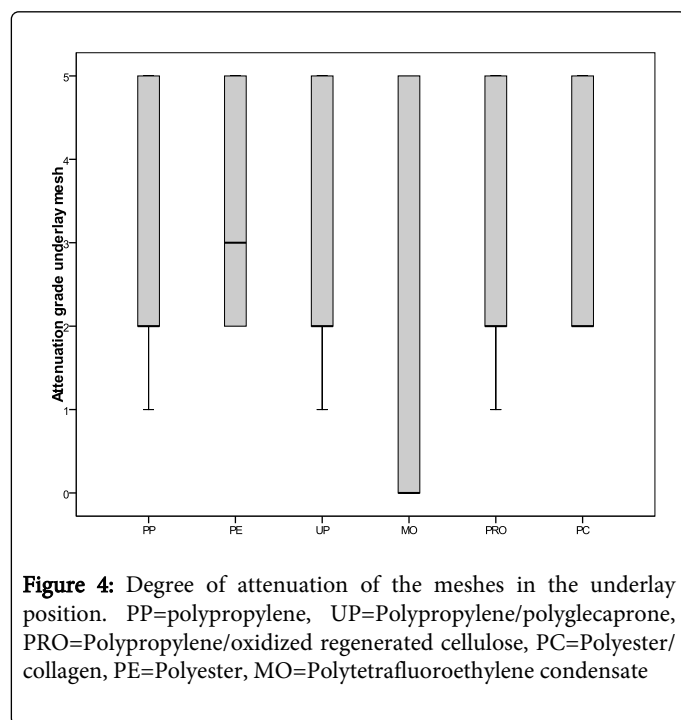


Figure 4: Degree of attenuation of the meshes in the underlay position. PP=polypropylene, UP=Polypropylene/polyglycecaprone, PRO=Polypropylene/oxidized regenerated cellulose, PC=Polyester/collagen, PE=Polyester, MO=Polytetrafluoroethylene condensate

Discussion

The use of only two animals was the optimization of laboratory animals and the possibility of comparison. There was no need to exclude the animals by anatomical defect and can be evaluated. The initial assessment showed no difficulty or mitigation areas that harmed the exam. In all the analysis were visualized seamlessly skin and subcutaneous tissue.

In concordance with previous studies, the animals of this study, which received independent implementation of the previous meshes in intraperitoneal position shows a loss of quality of the ultrasound image [23,24].

Whereas there was no significant statistical difference between the same mesh in different positions, showed a trend towards a higher degree when placed in position underlay (intraperitoneal), since the identification of muscle tissue can be fully evaluated at this position.

Following the trend of decreasing the obstructive effect of attenuation of the sound beam was no significant difference between the meshes used. The characteristics of the meshes being used single sided as PP, PE, PU and MO just had different behavior depending on their composition monofilament or multifilament, thicknesses and pore size. In this evaluation the mesh was less attenuation PE mesh, followed by PP and UP, and worst reviewed MO mesh for presenting the effect of posterior acoustic shadowing in both positions [25-29].

The analysis of meshes with double-sided (covering) there was a lower degree of attenuation using the PC mesh in relation to the PRO, but no statistical difference between them, however there was no spare acoustic MO [29] seen on mesh [30].

The limitation of the study is the use of only two animals and a single analysis.

Since the analysis after inflammatory process could influence the image and degree of attenuation of the ultrasound beam.

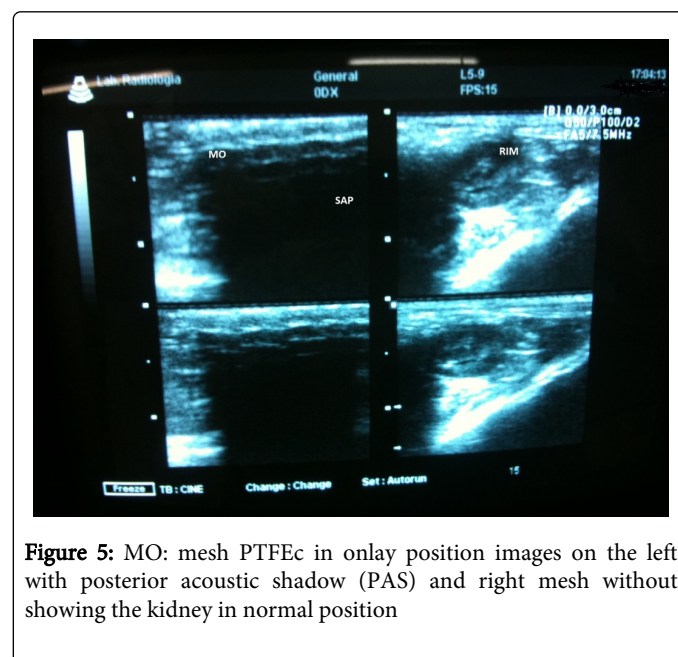


Figure 5: MO: mesh PTFEc in onlay position images on the left with posterior acoustic shadow (PAS) and right mesh without showing the kidney in normal position

An evaluation to be considered is the time of review, requiring the comparative long-term inflammation caused by foreign body and also by absorption of the fabrics or fabrics with double sided coated.

Conclusion

All types of meshes used in this study and previous or intraperitoneal position there was a statistically significant greater attenuation of the sound beam on ultrasound examination. The polyester mesh got to take a lower degree of attenuation compared with other meshes of the study. Is needed a new test to verify attenuation in the long term.

Acknowledgment

To Prof. Henrique Záquia Leão with extreme competence and dedication helped in the study and the possible radiological structure to make this article.

References

1. Sebben GA, Rocha SL, Von Bahten LC, Biondo-Simões Mde L, Ramos FH, et al. (2006) Infection on polypropylene mesh implantation site in the abdominal wall of rats with induced bacterial peritonitis. *Acta Cir Bras* 21: 155-160.
2. Greca FH, Souza Filho ZA, Rocha SL, Borsato KS, Fernandes HAD, et al. (2004) Submucosa de intestino delgado no reparo de defeitos em parede abdominal de ratos. *Acta Cir Bras* 19: 471-477.
3. Scalco PPC, Costa RG, Lontra MB, Jotz GP, Marques FB, et al. (2008) Comparação entre a tela de submucosa intestinal suína acelular (Surgisis) e a tela polipropileno (Marlex) na formação de aderências peritoneais- estudo experimental em ratos. *Rev AMRIGS* 52: 197-203.
4. Beggs AD, Thomas PR (2013) Point of use ultrasound by general surgeons: review of the literature and suggestions for future practice. *Int J Surg* 11: 12-17.
5. DeBord JR (1998) The historical development of prosthetics in hernia surgery. *Surg Clin North Am* 78: 973-1006, vi.

6. Gaertner WB, Bonsack ME, Delaney JP (2010) Visceral adhesions to hernia prostheses. *Hernia* 14: 375-381.
7. Zinther NB, Wara P, Friis-Andersen H (2010) Intraperitoneal onlay mesh: an experimental study of adhesion formation in a sheep model. *Hernia* 14: 283-289.
8. Anthony T, Bergen PC, Kim LT, Henderson M, Fahey T, et al. (2000) Factors affecting recurrence following incisional herniorrhaphy. *World J Surg* 24: 95-100.
9. Sikkink CJ, Vries de Reilingh TS, Malyar AW, Jansen JA, Bleichrodt RP, et al. (2006) Adhesion formation and reherniation differ between meshes used for abdominal wall reconstruction. *Hernia* 10: 218-222.
10. Aveline C, Le Hetet H, Le Roux A, Vautier P, Cognet F, et al. (2011) Comparison between ultrasound-guided transversus abdominis plane and conventional ilioinguinal/iliohypogastric nerve blocks for day-case open inguinal hernia repair. *Br J Anaesth* 106: 380-386.
11. Puttini SMB (2006) Avaliação da resposta inflamatória desencadeada pelas telas de polipropileno e politetrafluoretileno expandido implantadas no espaço intraperitoneal. Estudo experimental em camundongos. Dissertação (Mestrado- Ciências Médicas)- Faculdade de Medicina, Universidade de Brasília.
12. Amid PK, Shulman AG, Lichtenstein IL, Hakakha M (1995) [Biomaterials and hernia surgery. Rationale for using them]. *Rev Esp Enferm Dig* 87: 582-586.
13. Conze J, Kingsnorth AN, Flament JB, Simmermacher R, Arlt G, et al. (2005) Randomized clinical trial comparing lightweight composite mesh with polyester or polypropylene mesh for incisional hernia repair. *Br J Surg* 92: 1488-1493.
14. Seiler C, Baumann P, Kienle P, Kuthe A, Kuhlitz J, et al. (2010) A randomised, multi-centre, prospective, double blind pilot-study to evaluate safety and efficacy of the non-absorbable Optilene® Mesh Elastic versus the partly absorbable Ultrapro® Mesh for incisional hernia repair. *BMC Surgery* 10: 21.
15. Pundek MRZ, Czecko NG, Yamamoto CT, Pizzato RF, Czecko LEA, et al. (2010) estudo das telas cirúrgicas de polipropileno/poliglicaprone e de polipropileno/polidioxanona/celulose regenerada oxidada na cicatrização de defeito produzido na parede abdominal em ratos. *Arq. Bras Cir Dig* 23: 94-99.
16. LeBlanc KA, Bellanger D, Rhynes KV 5th, Baker DG, Stout RW (2002) Tissue attachment strength of prosthetic meshes used in ventral and incisional hernia repair. A study in the New Zealand White rabbit adhesion model. *Surg Endosc* 16: 1542-1546.
17. Voskerjian G, Rodriguez A, Gingras PH (2007) Macroporous condensed poly(tetra fluoro-ethylene). II. In vivo effect on adhesion formation and tissue integration. *J Biomed Mater Res A* 82: 426-435.
18. Baroncello JB, Czecko NG, Malafaia O, Ribas-Filho JM, Nassif PA, et al. (2008) [The repair of abdominal defects in rabbits with Parietex and Surgisis meshes abdominal wall]. *Arq Gastroenterol* 45: 323-329.
19. Benchetrit S, Debaert M, Detruit B, Dufilho A, Gaujoux D, et al. (1998) Laparoscopic and open abdominal wall reconstruction using Parietex® meshes clinical results in 2700 hernias. *Hernia*: 57-62.
20. Jacob BP, Hogler NJ, Durak E, Kim T, Fowler DL (2007) Tissue ingrowth and bowel adhesion formation in an animal comparative study: Polypropylene versus Proceed versus Parietex Composite. *Surg Endosc* 21: 629-633.
21. Balique JG, Benchetrit S, Bouillot JL, Flament JB, Gouillat C, et al. (2005) Intraperitoneal treatment of incisional and umbilical hernias using an innovative composite mesh: four-year results of a prospective multicenter clinical trial. *Hernia* 9: 68-74.
22. Matsuoka MW, Oliveira IRS, Widman A, Zanoto A, Kodaira SK, et al. (2011) Contribuição da ultrassonografia para o diagnóstico das alterações histopatológicas presentes na hepatite C crônica, com ênfase na esteatose hepática. *Radiol Bras*. 44: 141-146
23. Sigel B, Golub RM, Loiacono LA, Parsons RE, Kodama I, et al. (1991) Technique of ultrasonic detection and mapping of abdominal wall adhesions. *Surg Endosc* 5: 161-165
24. Kodama I, Loiacono LA, Sigel B, Machi J, Golub RM, et al. (1992) Ultrasonic detection of viscera slide as an indicator of abdominal wall adhesions. *J Clin Ultrasound* 20: 375-380.
25. Bigelow TA, O'Brien WD Jr (2005) A model for estimating ultrasound attenuation along the propagation path to the fetus from backscattered waveforms. *J Acoust Soc Am* 118: 1210-1220.
26. Cerise EJ, Busuttil RW, Craighead CC, Ogden WW 2nd (1975) The use of Mersilene mesh in repair of abdominal wall hernias: a clinical and experimental study. *Ann Surg* 181: 728-734.
27. Demir U, Mihmanli M, Coskun H, Dilege E, Kalyoncu A, et al. (2005) Comparison of prosthetic materials in incisional hernia repair. *Surg Today* 35: 223-227.
28. van 't Riet M, de Vos van Steenwijk PJ, Bonthuis F, Marquet RL, Steyerberg EW, et al. (2003) Prevention of adhesion to prosthetic mesh: comparison of different barriers using an incisional hernia model. *Ann Surg* 237: 123-128.
29. Konarzewski NS, Bigolin AV, Montes JHM, Lambert B, Kist C, et al. (2009) Avaliação das aderências intraperitoneais associadas ao uso da tela de dupla camada pfee/ polipropileno em reparo de hérnias ventrais - estudo experimental em ratos. *Bras J Video-Sur* 2: 2-10.
30. Lambert B, Manna B, Montes JHM, Bigolin AV, Grossi JVM, et al. (2012) Estudo experimental das telas de polipropileno e poliéster revestida com colágeno- Avaliação da formação de aderências intraperitoneais. *Bras J Video-Sur* 5: 37-43.