

Analysis of Related Factors on the Vertebral Height Restoration of Percutaneous Vertebral Augmentation

Weixing Xie and Daxiang Jin*

Department of Orthopaedics, The First Affiliated Hospital of Guangzhou University of Traditional Chinese Medicine, Baiyun District, Zip code 510405, Guangzhou City, Guangdong Province, China

*Corresponding author: Daxiang Jin, Medical Doctor, Department of Orthopaedics, The First Affiliated Hospital of Guangzhou University of Traditional Chinese Medicine, Baiyun District, Zip code 510405, Guangzhou City, Guangdong Province, China, Tel: 020-36591222; E-mail: 642366579@qq.com

Received date: October 03, 2017; Accepted date: October 20, 2017; Published date: October 27, 2017

Copyright: © 2017 Xie W, et al. This is an open-access article distributed under the terms of the Creative Commons Attribution License, which permits unrestricted use, distribution, and reproduction in any medium, provided the original author and source are credited.

Abstract

Study design: The related factors for the vertebral height restoration were retrospectively reviewed in 97 patients who underwent percutaneous vertebral augmentation (PVA).

Objective: To discuss the factors associated with the vertebral body height restoration and follow-up height loss of patients underwent PVA for osteoporotic vertebral compression fractures.

Background: PVA is widely applied for the treatment of osteoporotic vertebral fractures. The degree of vertebral body height restoration and deformity correction after the procedure is not consistent.

Methods: We retrospectively reviewed 97 patients who underwent PVA, because of osteoporotic vertebral compression fractures. The following data about the patients were recorded: age, gender, bone density, number of treated vertebrae, severity of fracture of the treated vertebrae, operative approach, volume of injected bone cement, preoperative vertebral compression ratio, preoperative local kyphosis angle, cement leakage, postoperative vertebral body height restoration ratio, follow-up period, and latest follow-up height loss ratio. Bivariate regression analysis and t-test were applied for univariate analysis, while multivariate linear regression analysis was applied for multivariate analysis.

Results: The postoperative vertebral body height restoration ratio was $(14.7 \pm 15.2)\%$ and the last follow-up height loss ratio was $(13.5 \pm 11.5)\%$. The multivariate analysis showed that the number of treated vertebrae, preoperative vertebral compression ratio, and preoperative local kyphosis angle are the main factors influencing the postoperative vertebral body height restoration. The univariate analysis also showed that only the postoperative vertebral body height restoration ratio is related to the last follow-up height loss ratio.

Conclusion: The number of treated vertebrae, preoperative vertebral compression ratio and preoperative local kyphosis angle are the main influencing factors of patients' vertebral body height restoration after PVA and the postoperative vertebral body height restoration ratio is the main factor influencing the last follow-up height loss ratio.

Keywords: Percutaneous vertebral augmentation; Vertebral height restoration; Local kyphosis angle; Vertebral height loss

Abbreviations PVA: Percutaneous Vertebral Augmentation; PVP: Percutaneous Vertebroplasty; PKP: Percutaneous Kyphoplasty; MRI: Magnetic Resonance Imaging

Introduction

Vertebral compression fracture is a common complication of osteoporosis that can lead to persistent back pain, kyphosis, reduced quality of life, and increased mortality [1]. About one third of vertebral compression fracture patients suffer from sustained pain because of ineffective conservative treatments [2]. PVA include percutaneous vertebroplasty (PVP) and percutaneous kyphoplasty (PKP). They are minimally-invasive techniques of percutaneous injection of bone cement (usually polymethyl methacrylate) into fractured vertebrae. In recent years, PVA are widely applied to the treatment of osteoporotic

vertebral compression fractures, and satisfying clinical efficacy has been received.

Many reports have confirmed that PVA help patients with osteoporotic vertebral compression fractures gain immediate relief of pain and improvement of mobility. However, the degree of vertebral body height restoration and deformity correction after the procedure is not consistent, owing to the differences in patients' preoperative conditions. Paul et al. [3] reported that on average, 34% of PKP and 39% of PVP did not result in satisfactory vertebral body height restoration and kyphosis correction. Hence, clinicians pay great attention to the factors that influence the postoperative vertebral body height restoration and the follow-up height loss.

In this study, a retrospective review of 97 patients who underwent vertebral augmentation procedure was conducted. The patients received the treatments during April 2009 to August 2011 because of osteoporotic vertebral compression fractures. The factors related to

postoperative vertebral height restoration and the follow-up height loss are discussed in this article.

Materials and Methods

Patients

The patient population included 97 patients, 14 male and 83 female, aged 51 to 92 years (73.1 on average). Informed consent was obtained from all the patients before enrollment in the study. This study was retrospectively performed and approved by the institutional Ethics Committees of our hospital and conducted in accordance with the ethical guidelines of the Declaration of Helsinki. And written informed consent was given by participants for their clinical records to be used in this study. All patients were diagnosed of acute osteoporotic vertebral compression fracture or chronic fracture that has not healed, confirmed by MRI. All patients met the following criteria: (1) one or more OVCFs; (2) focal back pain in the midline; (3) conservative treatments they received have not been efficacious; (4) back pain related to the location of the VCF on radiography; (5) the presence of bone marrow edema on magnetic resonance imaging (MRI) T2-weighted short-tau inversion recovery sequences in the corresponding collapsed vertebral body.

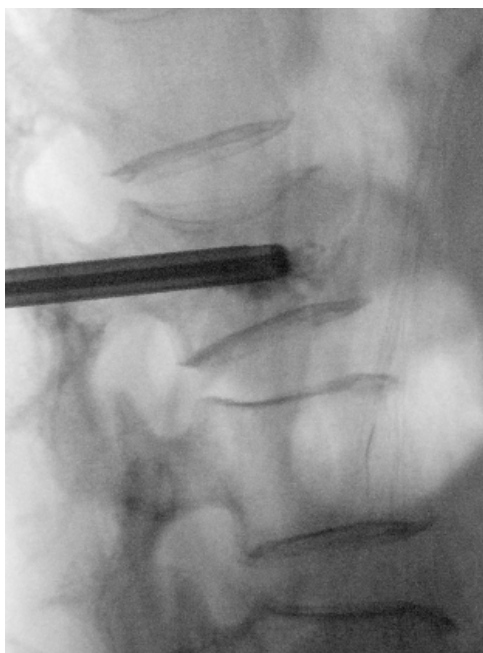

Figure 1: PVP of one vertebral body. Lateral fluoroscopic project of spine demonstrating cement that just came out of the trocar inside the vertebral body.

Technique of PVA

Through antero-posterior and lateral fluoroscopy with C-arm, the position of the fractured vertebra and its pedicle were determined. After local anesthesia, the needle was gradually advanced through the cortex and pedicle into the vertebral body by bilateral transpedicular approach (Figure 1). If it was a PKP procedure, an inflatable bone tamp was introduced into the vertebral body, and after dilation of the bone

tamp (Figure 2), bone cement was injected into the vertebral body in a slow and smooth manner. Fluoroscopy with C-arm was frequently used to monitor the injection in order to prevent the leakage of bone cement from the vertebral body.

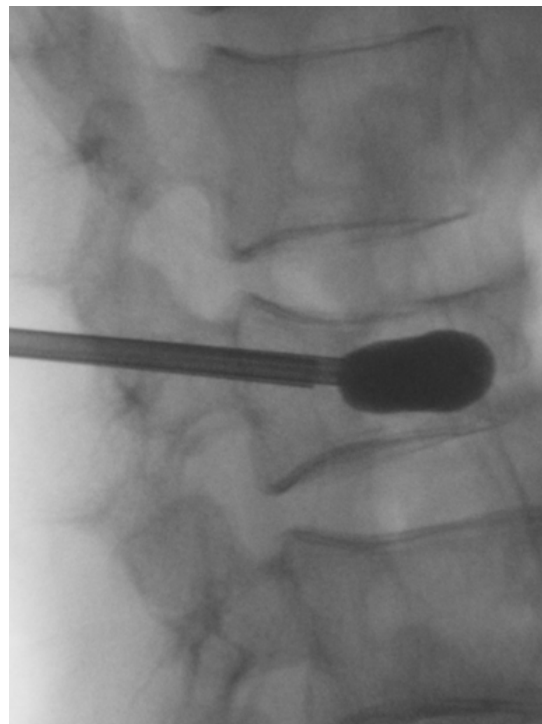


Figure 2: PKP of one vertebral body. Lateral fluoroscopy view-the balloon is inflated under manometric control to restore the collapsed endplate to its normal position and to create a cavity within the vertebra.

Clinical evaluation

The following data of the patients were recorded: age, gender, bone density, number of fractured vertebrae, number of treated vertebrae, severity of fracture of the treated vertebrae, operative approach (PVP or PKP), volume of injected cement, preoperative vertebral compression ratio, preoperative local kyphosis angle, cement leakage, postoperative vertebral body height restoration ratio, follows up period, and last follow-up height loss.

The severity of vertebral fractures was determined with the semi-quantitative vertebral fracture assessment technique proposed by Genant et al. [4]. If the X-ray image shows 20~25% vertebral body height reduction and 10~20% loss of area, the fracture was considered slight fracture; a vertebra with 26~40% vertebral body height reduction and 21~40% loss of area was considered moderate fracture; and a vertebra with over 40% of both figures was considered severe fracture.

Then, three equations were used to assess the preoperative vertebral compression ratios, vertebral height restoration ratios, and follow-up height loss ratios of anterior and central vertebral body and the means of the obtained values were used as the three ratios to evaluate the preoperative vertebral compression, postoperative vertebral body height restoration, and follow-up height loss conditions.

The three equations are: preoperative vertebral compression ratio=preoperative vertebral body height/estimated original vertebral body height, postoperative vertebral body height restoration ratio=(postoperative vertebral body height – preoperative vertebral body height)/estimated original vertebral body height and last follow-up height loss ratio=(postoperative vertebral body height – vertebral body height at the last follow-up)/estimated original vertebral body height). In the equations, the original vertebral body height was estimated by averaging the heights of the two adjacent vertebrae of the treated vertebrae. The local kyphosis angle was obtained by measuring the angle between the upper and lower endplates of the treated vertebrae Figures 3 and 4.

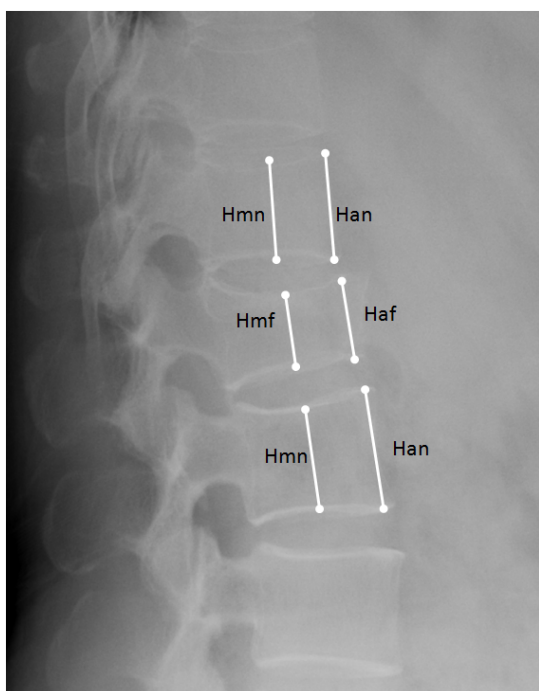


Figure 3: Measurement of normal middle (Hmn), normal anterior (Han) vertebral height and fracture middle (Hmf) and fracture anterior(Haf) vertebral height.

Statistics

All data are expressed in the format of mean \pm standard deviation in this article. Statistical software SPSS 15.0 was employed for the statistical analysis. Bivariate regression analysis and t-test were applied for univariate analysis, while multivariate linear regression analysis was employed for multivariate analysis. Through the univariate and multivariate analyses, the correlations between a variety of factors and the postoperative vertebral body height restoration and follow-up height loss were investigated. $P < 0.05$ was considered statistically significant.

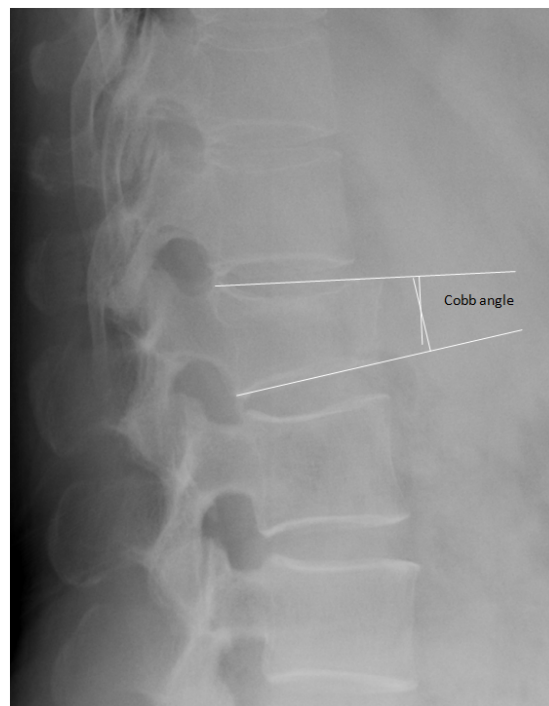


Figure 4: Measurement of Cobb angle.

Results

The 97 patients had totally 256 fractured vertebrae before the treatments and 146 were assessed as painful vertebral compression fractures and underwent PVA. The average follow-up period for all patients was 616 ± 311.6 (range: 182-1381) days, and the average preoperative bone density (T-value) was -3.844 ± 1.16 . Most fractured vertebrae were at the thoracolumbar spine. Of the treated vertebrae, 60.3% (88 vertebrae) were T11-L2 vertebrae. According to the severity classification, the treated vertebrae included 72 slightly fractured vertebrae, 45 moderately fractured vertebrae and 29 severely fractured vertebrae. Cement leakage occurred in 47 of 146 (32.19%) vertebrae that underwent augmentation procedure. All of the cement leakage was asymptomatic and further treatment because of cement leakage was not needed. According to CIRSE classification system for complications [5], all of the cement leakage was graded as Grade 1. During the follow-ups, new vertebral fractures were found in 25 (25.77%) of the 97 patients. For the 146 vertebrae that underwent the treatment, the preoperative vertebral compression ratio was $(24.8 \pm 16.6)\%$, the postoperative vertebral height restoration ratio was $(14.7 \pm 15.2)\%$, the last follow-up height loss ratio was $(13.5 \pm 11.5)\%$, the preoperative vertebral kyphosis angle was $(8.1 \pm 7.9)^\circ$, the postoperative vertebral kyphosis angle was $(6.2 \pm 6.3)^\circ$ and the vertebral kyphosis angle at the last follow-up was $(7.1 \pm 7.7)^\circ$. Comparing with the preoperative conditions, after the treatment the anterior and central vertebral body heights and the local kyphosis of fractured vertebrae all improved, and the differences were statistically significant. At the last follow-up, the anterior and central vertebral body height losses and the secondary enlargement of local kyphosis were all statistically significant comparing with the postoperative values (Table 1). And the vertebral body height and local kyphosis

angle at the last follow-up were no significant difference while comparing with the preoperative values.

	x ± S	Pearson correlation coefficient	P Value
Age	73.11 ± 8.431	0.172	0.038*
Bone density	-3.844 ± 1.16	-0.059	0.48
Number of treated vertebrae	1.51 ± 0.79	-1.7	0.04*
Volume of injected bone cement	5.25 ± 1.637	-0.091	0.276
Preoperative vertebral compression ratio	24.8 ± 16.6)%	0.787	0.000*
Preoperative kyphosis angle	8.1 ± 7.9	0.246	0.003*

Table 1: Measurement data of 97 patients and bivariate regression analysis result for postoperative vertebral body height restoration ratio (* Statistically significant parameter).

Out of the 97 patients studied, 69 (107 vertebrae) underwent PVP, while 28 (39 vertebrae) underwent PKP. The number of patients in PVP and PKP group did not match. For patients underwent PVP, the postoperative vertebral body height restoration ratio was (13.8 ± 15.1)%, while the value for the patients underwent PKP was (17.3 ± 15.4)%, displaying insignificant difference. The postoperative local kyphosis corrections were (1.4 ± 5.8)° and (3.4 ± 5.1)° for the two groups of patients, respectively, exhibiting statistically significant difference, where the patients underwent PKP procedure experienced better postoperative local kyphosis correction (Table 1).

	Kendall correlation coefficient	P Value	Spearman correlation coefficient	P Value
Gender	0.026	0.707	0.031	0.708
Operative approach	0.084	0.216	0.103	0.218
Severity of vertebral fracture	0.449	0	0.554	0*

Table 2: Categorical data of 97 patients and bivariate regression analysis result for postoperative vertebral body height restoration ratio. (* Statistically significant parameter).

It was shown by the univariate analysis that the factors that are to a certain extent related to the postoperative vertebral body height restoration (P<0.05, as shown in Tables 2 and 3) include the patient's age, the number of treated vertebrae, preoperative vertebral compression ratio, preoperative local kyphosis angle, and severity of vertebral fracture. Other factors investigated, including gender, bone density, number of fractured vertebrae before treatment, operative approach, and volume of injected cement, did not show obvious relation with the postoperative vertebral body height restoration (P>0.05, as shown in Tables 2 and 3). The multivariate analysis showed that the number of treated vertebrae, preoperative vertebral compression ratio and preoperative local kyphosis angle are the main factors influencing the postoperative vertebral body height restoration, with standardized partial regression coefficients of -0.222, 0.948, and -0.293, respectively (Table 4). The univariate analysis also showed that only the postoperative vertebral body height restoration ratio is related

to the last follow-up height loss ratio (Pearson correlation coefficient: 0.202 and P=0.014, Table 5).

Variable	Partial regression coefficient	Standard error of regression coefficient	Standardized partial regression coefficient	T Value	P Value
Number of treated vertebrae	-0.035	0.008	-0.222	-4.407	0*
Preoperative vertebral compression ratio	0.869	0.075	0.948	11.659	0*
Preoperative kyphosis angle	-0.006	0.001	-0.293	-4.675	0*

Table 3: Influencing factors and multivariate linear regression analysis result for postoperative vertebral body height restoration ratio. (* Statistically significant parameter).

	x ± S	Pearson correlation coefficient	P Value
Age	73.11 ± 8.431	0.147	0.076
Bone density	3.844 ± 1.16	0.129	0.12
Number of fractured vertebrae	2.64 ± 2.1	0.063	0.452
Number of treated vertebrae	1.51 ± 0.79	0.065	0.437
Volume of injected bone cement	5.25 ± 1.637	0.008	0.922
Preoperative vertebral compression ratio	(24.8 ± 16.6)%	0.032	0.704
Preoperative kyphosis angle	8.1 ± 7.9	0.108	0.195
Postoperative vertebral body height restoration ratio	(14.7 ± 15.2)%	0.202	0.014*

Table 4: Measurement data of 97 patients and bivariate regression analysis result for last follow-up height loss.

Discussion

Among the worldwide aging population, osteoporosis has become a common disease threatening the health of the elderly especially postmenopausal women. A main complication of osteoporosis is vertebral fracture. Because of pain, the patients need long-term bed rest, and lose the ability to work or take care of themselves, which lead to obvious decrease of their quality of life, and bring burden to the patients' families. In 1987, Deramond and Galibert reported the world's first PVP procedure [6]. Now, PVA is widely adopted for the treatment of osteoporotic vertebral compression fracture. PVA could rapidly, effectively relieve the pain of patients and improve their quality of life. Its efficacy is evidently satisfactory. However, owing to the difference in patients' preoperative conditions, the postoperative

vertebral body height restoration, local kyphosis correction, and the follow-up retaining of vertebral body height of different patients are not consistent. Therefore, clinicians pay great attention to approaches that, to the maximum extent, restore the vertebral body height while relieve patients' pain and improve their mobility. This study presents an analysis of the possible factors influencing the vertebral body height restoration and retaining after vertebral augmentation procedure. It is concluded that the main factors influencing the postoperative vertebral body height restoration are the number of treated vertebrae, preoperative vertebral compression ratio, and preoperative local kyphosis angle, whereas the main factor influencing the vertebral height loss at the latest follow up is the postoperative vertebral body height restoration ratio.

	Kendall correlation coefficient	P Value	Spearman correlation coefficient	P Value
Gender	0.07	0.301	0.086	0.303
Operative approach	0.005	0.938	0.006	0.939
Severity of vertebral fracture	0.013	0.836	0.015	0.856
Cement leakage	0.019	0.781	0.023	0.782

Table 5: Categorical data of 97 patients and bivariate regression analysis result for last follow-up height loss.

Vertebral Body Height Restoration and Local Kyphosis Correction After PVA

The efficacy of PVP and PKP in reducing the kyphosis angle of fractured vertebrae and restoring the vertebral body height has been proved by plenty of studies. PVP procedure itself does not restore the height of vertebral body by mechanical means. It relies on patient positioning or the insertion of bolsters to induce lordosis, to increase the height of the vertebra and reduce the kyphotic angle [7,8]. Studies assessing the ability of vertebroplasty to restore height identified preoperative dynamic mobility as a good indicator of the potential to restore vertebral height. Mckierman et al. [9] showed that osteoporotic mobile fractures can achieve some height restoration following vertebroplasty, while non-mobile fractures cannot.

As an improved version of PVP, PKP is considered having the advantage of not only reduced risk of cement leakage, but also more effective restoration of vertebral body height and correction of kyphosis [10-12]. PKP is performed with the introduction of an inflatable balloon into the compressed vertebral body aiming to elevate the endplates. This is carried out by creating a cavity inside the vertebral body that is filled with cement; during PKP, the cement injection is held at low pressure [13]. Voggenreiter [14] reckoned that the restoration of vertebral body height by PKP can be attributed to the mobility of dynamic bone fracture and the expansion of the inflatable bone tamp. When the patient is placed in prone position with the spine extended by chest and pelvic bolsters, spontaneous reduction in deformity that may occur, and then the dilation of the bone tamp will induce further restoration of vertebral body height and correction of kyphosis. In this study, the patients underwent PVP or PKP procedure all exhibited obvious improvement of vertebral body height and kyphosis. Comparing with the patients who underwent PVP procedure, the patients underwent PKP procedure showed higher

vertebral body height restoration ratios; however the difference was not statistically significant. As for the correction of local kyphosis angle, the patients underwent PKP procedure experienced greater correction, and the difference was statistically significant.

Influence of the Number of Treated Vertebrae on Post-Operative Vertebral Body Height Restoration

Some studies reckon that multilevel treatment in a single session has been shown to be feasible with no compromise of the technique's safety and efficacy and PVA is an efficient and safe technique for symptomatic vertebral fractures independently of the vertebrae number treated per session [15,16]. However, through multivariate linear regression analysis, we found in this study that the number of treated vertebrae is an important factor influencing the postoperative vertebral body height restoration. Greater value of this number was associated with lower restoration of vertebral body height, exhibiting a negative correlation. There have been studies that proved the efficacy of vertebral augmentation procedure on multi-level vertebral compression fracture, yet such procedure is much more challenging than on single vertebra. Patients with multi-level vertebral fractures are often old, with more primary diseases and poorer tolerance. Meanwhile, since the patients we studied underwent the operations with local anesthesia, as the number of vertebrae to be treated increased, patients' cooperation degree often decreased during the operation and whether the patient can cooperate and lay in a suitable stretching position has great influence on the patient's postoperative vertebral body height restoration. Because of the accumulation of pain stimulus and the prolonged duration of the procedure, patients receiving multi-level vertebral augmentation treatment often struggle to lie in suitable position, which may have reduced the postoperative vertebral height restoration.

Influence of Pre-Operative Vertebral Compression Ratio and Local Kyphosis Angle on Post-Operative Vertebral Body Height Restoration

In this study, it was observed that greater preoperative vertebral compression ratio and larger preoperative local kyphosis angle lead to higher postoperative restoration of vertebral body height in PVA. Vertebrae that have were more seriously compressed before the procedure are more likely to be restored to a higher extent, probably because that such vertebrae have more serious structural damage and poorer stability, allowing greater restoration of their vertebral body height. This conclusion is consistent with that of Teng et al. [17], who conducted a retrospective study of 53 patients (73 fractured vertebrae) who received PVP, and found that the correction of kyphosis was directly associated with the preoperative vertebral body height loss, i.e. the greater kyphosis angle caused by original loss of vertebral height, the larger postoperative correction of kyphosis. However, more serious structural damage of vertebrae also leads to higher risk of the operation, thus such vertebrae should be treated with extra caution.

Influence of the Volume of Injected Cement on post-Operative Vertebral Body Height Restoration

Some studies reckon that the restoration of vertebral morphology and correction of kyphosis are related to the volume of the injected cement [18]. In this study, however, the univariate analysis showed that there is no relation between the cement injection volume and the

postoperative vertebral body height restoration. A study of Liebschner et al. [19] showed that as long as the injected cement in each vertebra reaches 15% of the vertebra's volume, the vertebral strength can recover to its pre-damage level, thus the volume of injected cement is not proportional to the degree of the patient's pain relief. Instead, it is associated with the incidence of cement leakage; excess injection of cement increases the risk of cement leakage. Therefore, we advocate that the injected cement should only fill the cavity, without forced injection of more cement. This way, the expected efficacy of the procedure can be achieved, and the risk of cement leakage reduced.

Influence of Post-Operative Vertebral Body Height Restoration on Last Follow-Up Height Loss

It was found in this study that at the last follow-up, the anterior and central heights of treated vertebrae all experienced different degrees of loss, and secondary enlargement of local kyphosis occurred. Comparing with the postoperative data, the loss and enlargement were all statistically significant. This is similar to the result obtained by Zhao et al. [20], who conducted a prospective study of 45 female patients who underwent PKP, and found that the loss of vertebral height occurred as soon as four months after the procedure. They think that when rigid cement fills the vertebral body, it could cause compression fracture of the adjacent vertebrae, or damage to the unfilled trabecular bone in the same vertebra. In this study, the univariate analysis showed that only the postoperative vertebral body height restoration ratio is related to the last follow-up height loss, exhibiting a positive correlation, i.e. the higher postoperative restoration ratio, the higher last follow-up height loss. The restoration of vertebral body height is related to the dynamic mobility of the fractured vertebra. A fractured vertebra with poorer mobility is likely to gain greater height restoration after augmentation procedure. During vertebral augmentation treatment of osteoporotic vertebral compression fracture, it is hard to fully fill the entire fractured vertebra with cement. In the unfilled area of the vertebra, the vertebral body may collapse again, causing loss of the vertebral body height. In addition, we noticed that although there is no apparent connection between bone density and last follow-up height loss, patients with lower bone density tend to experience greater vertebral body height losses. Therefore, for patients with more serious osteoporosis, anti-osteoporosis treatment is still necessary after the procedure.

The present study has some limitations. In this study, the number of patients in PVP and PKP group did not match, so the number of patients in both groups was different. We only measured the change in vertebral height and local kyphosis angle on imaging. We hadn't assessed the correlation between the restoration of vertebral height and the patients' clinical outcome.

Conclusion

Vertebral height and local kyphosis angle were significantly improved while comparing with the preoperative conditions. However, vertebral body height losses and secondary enlargement of local kyphosis were all significant in the follow-up. At the last follow-up, the anterior and central vertebral body height and local kyphosis angle were no significant difference while comparing with the preoperative values. The number of treated vertebrae, preoperative vertebral compression ratio, and preoperative local kyphosis angle are the major influencing factors of the vertebral body height restoration after percutaneous vertebral augmentation procedure. The postoperative

vertebral body height restoration ratio is the main influencing factor of the vertebral body height loss ratio at the last follow-up. Observing these indicators of patients will help predict the postoperative vertebral body height restoration and follow-up height losses.

Acknowledgement

This study was supported by Traditional Chinese Medicine Bureau of Guangdong Province (No.20151231) and Medical Scientific Research Foundation of Guangdong Province (No. A2016515), China.

References

1. Kado DM, Browner WS, Palermo L, Nevitt MC, Genant HK, et al. (1999) Vertebral fractures and mortality in older women: A prospective study. Study of Osteoporotic Fractures Research Group. *Arch Intern Med* 159: 1215-1220.
2. Tseng YY, Yang TC, Tu PH, Lo YL, Yang ST (2009) Repeated and multiple new vertebral compression fractures after percutaneous transpedicular vertebroplasty. *Spine* 34: 1917-1922.
3. Hulme PA, Krebs J, Ferguson SJ, Berlemann U (2006) Vertebroplasty and kyphoplasty: A systematic review of 69 clinical studies. *Spine* 31: 1983-2001.
4. Genant HK, Wu CY, van Kuijk C, Nevitt MC (1993) Vertebral fracture assessment using a semi quantitative technique. *J Bone Miner Res* 1993; 8: 1137-1148.
5. Filippidis DK, Binkert C, Pellerin O, Hoffmann RT, Krajina A (2017) Cirse quality assurance document and standards for classification of complications: The cirse classification system. *Cardiovasc Intervent Radiol*. 40: 1141-1146.
6. Galibert P, Deramond H, Rosat P, Le Gars D (1987) Preliminary note on the treatment of vertebral angioma by percutaneous acrylic vertebroplasty. *Neurochirurgie* 33: 166-168.
7. Carlier RY, Gordji H, Mompoin DM, Vernhet N, Feydy A, et al. (2004) Osteoporotic vertebral collapse: Percutaneous vertebroplasty and local kyphosis correction. *Radiology* 233: 891-898.
8. Teng MM, Wei CJ, Wei LC, Luo CB, Lirng JF, et al. (2003) Kyphosis correction and height restoration effects of percutaneous vertebroplasty. *AJNR Am J Neuroradiol* 24: 1893-1900.
9. McKiernan F, Jensen R, Faciszewski T (2003) The dynamic mobility of vertebral compression fractures. *J Bone Miner Res* 18: 24-29.
10. Phillips FM, Ho E, Campbell-Hupp M, McNally T, Todd Wetzel F, et al. (2003) Early radiographic and clinical results of balloon kyphoplasty for the treatment of osteoporotic vertebral compression fractures. *Spine* 28: 2260-2265.
11. Theodorou DJ, Theodorou SJ, Duncan TD, Garfin SR, Wong WH (2002) Percutaneous balloon kyphoplasty for the correction of spinal deformity in painful vertebral body compression fractures. *Clin Imag* 26: 1-5.
12. Ledlie J, Renfro M (2003) Balloon kyphoplasty: one-year outcomes in vertebral body height restoration, chronic pain, and activity levels. *J Neurosurg* 98: 36-42.
13. Aparisi F (2016) Vertebroplasty and kyphoplasty in vertebral osteoporotic fractures. *Semin Musculoskelet Radiol* 20: 382-391.
14. Voggenreiter G (2005) Balloon kyphoplasty is effective in deformity correction of osteoporotic vertebral compression fractures. *Spine* 30: 2806-2812.
15. Katonis P, Hadjipavlou A, Souvatzis X, Tzermiadianos M, Alpentaki K, et al. (2012) Respiratory effects, hemodynamic changes and cement leakage during multilevel cement balloon kyphoplasty. *Eur Spine J* 21: 1860-1866.
16. Mailli L, Filippidis DK, Brountzos EN, Alexopoulou E, Kelekis N, et al. (2013) Clinical outcome and safety of multilevel vertebroplasty: Clinical experience and results. *Cardiovasc Intervent Radiol* 36: 183-191.
17. Tohmeh AG, Mathis JM, Fenton DC, Levine AM, Belkoff SM (1999) Biomechanical efficacy of unipedicular versus bipedicular vertebroplasty

-
- for the management of osteoporotic compression fractures. Spine 24: 1772-1776.
18. R ger M, Schmoelz W (2009) Vertebroplasty with high viscosity polymethyl methacrylate cement facilitates vertebral body restoration *in vitro*. Spine 34: 2619-2625.
19. Lieberman IH, Dudeney S, Reinhardt MK, Bell G (2001) Initial outcome and efficacy of "kyphoplasty" in the treatment of painful osteoporotic vertebral compression fractures. Spine 26: 1631-1638.
20. Zhao YL, Yang HL, Konrad J, Liu J, Moral M, et al. (2010) Kyphoplasty does not maintain all restored height postoperatively: A prospective, comparative study. Orthopedics 33.