

Anaesthetic Management for Emergency Caesarean Section in a Parturient with Klippel Feil Syndrome

Sharma BL*, Bhati Sushil, Chatterjee CS and Nanda Smridhi

SMS Medical College and Associated Hospitals, Jaipur, India

*Corresponding author: BL Sharma, SMS Medical College and Attached Hospital, Jaipur, Rajasthan, India, Tel: +917688823100/7688823100; E-mail: anjusinghchoudhary@gmail.com

Received date: November 08, 2016; Accepted date: December 05, 2016; Published date: December 12, 2016

Copyright: © 2016 Sharma BL, et al. This is an open-access article distributed under the terms of the Creative Commons Attribution License, which permits unrestricted use, distribution, and reproduction in any medium, provided the original author and source are credited.

Abstract

A 20 year old female with Klippel Feil Syndrome was scheduled for emergency caesarian section during her 1st pregnancy. We present the successful anaesthetic management of this patient highlighting the various anomalies associated with Klippel Feil Syndrome and the presence of a difficult airway.

Keywords: Klippel Feil syndrome; Difficult airway; Subarachnoid block

Introduction

In 1912, Klippel and Feil [1] first reported on a patient with a short neck, a low posterior hairline, and severe restriction of neck movements due to complete fusion of the cervical spine, the classic clinical triad which is the hallmark of Klippel-Feil syndrome (KFS).

Case Report

A healthy 20-year-old woman was admitted at term in labour during her first pregnancy (G1POA0). Investigation done at the time of admission was: Blood group: 0 (negative), Hb: 9.6 gm/dl, Random blood sugar: 86 mg/dl.

On examination the patient was a short (height 132 cm), moderately built and nourished with Weight-48 kg, b.p.-122/78 mmHg, pulse rate-84/min, respiratory rate 18/min, no jaundice, mild pedal oedema. She had a short webbed neck and a low posterior hairline with no flexion or extension of the neck (Figure 1).

Examination of the airway showed that there was no flexion or extension of the neck, she had adequate mouth opening and reduced thyromental distance=3 cm and sternomental distance=4.4 cm and Mallampatti grade was 3 (Figure 2).

Electrocardiogram was within normal limits. Radiograph (X-ray taken after delivery of baby) revealed fusion of atlanto axial joint and associated thoracic kyphoscoliosis (Figures 3 and 4). On auscultation bilateral air entry in lungs was equal, no added sounds S1 and S2 were normal and no murmur was present.

On per vaginal examination: 2-3 cm os dilated, semi effaced cervix and Cephalo-pelvic disproportion also revealed. Patient was shifted to emergency OT for emergency LSCS. In O T, pre anaesthetic assessment was done. Patient was fasting for 6 hrs. There was no personal and family history of same problem. She was not taking any medication, and not having history of any drug allergy. The anaesthetic management option in this case included either a general anaesthesia with an anticipated difficult endotracheal intubation or a regional

anaesthesia. After a thorough discussion, we planned to give subarachnoid block as we considered it safe.



Figure 1: Short webbed neck and a low posterior hairline with no flexion or extension of the.

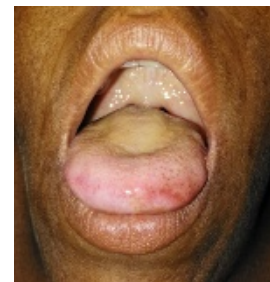


Figure 2: Mallampatti grading.

Emergency tray with direct laryngoscope, fiberoptic laryngoscope, different sizes ETT, ETT style, LMA of appropriate sizes, Intubating LMA, Laryngeal tube, boogie etc. kept ready for intubation because of chances of failure of regional block or high spinal. Surgeon was standby for tracheostomy in condition of failed intubation.

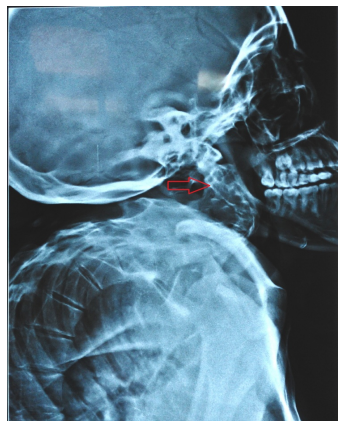


Figure 3: Radiograph of lateral view of cervical spine showing fusion of atlanto-occipital joint and cervical Vertebrae.

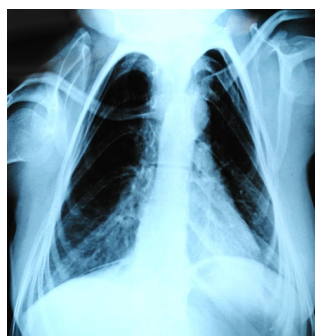

Figure 4: AP view of thorax showing deviation of trachea and marked kyphoscoliosis of thoracic spine.

Intravenous line was secured with 18G cannula. Inj. Ringer lactate was started. Inj ranitidine 50 mg and Inj metoclopramide 10 mg were given by slow i.v. Injection. Monitors were attached to the patient. Preop vitals: NIBP: 130/86 mmHg, pulse: 88/min, SPO₂: 98% on room air. Under all aseptic conditions, subarachnoid block was given in left lateral position at L3-L4 space using 25G quincke needle with 1.4 ml inj bupivacaine 5% heavy.

Just after block patient was given supine position. Effect of subarachnoid block was checked and surgery for LSCS started. Inj- oxytocine 2.5 units stat and 10 units in infusion given after extraction of baby. Baby was crying spontaneously with Apgar score of 8. A total of 1500 ml ringer lactate given. Post-operative vital was- BP: 122/86 mmHg, PR: 78/ min, RR: 14/min, patient was fully conscious and had no other complain.

Discussion

Some valuable lessons may be learnt from this case. Klippel feil syndrome is estimated to occur in 1 in 40,000 to 42,000 new-borns worldwide. Mutations in the GDF6 and GDF3 genes can cause KFS [2]. But in some people there are no identified mutations in the GDF6 or GDF3 genes and the etiology remains unknown. Mutations in MEOX 1 have been found to occur in association with Klippel-Feil syndrome [3]. Most cases of Klippel Feil are sporadic. Some cases are due to autosomal dominant or autosomal recessive inheritance.

It is a rare skeletal disorder primarily characterized by abnormal union or fusion of two or more cervical vertebrae. Other commonly associated anomalies include scoliosis, renal abnormalities, Sprengel deformity, deafness, synkinesia and congenital heart disease. The most common heart disease variant was ventricular septal defect. Less commonly associated are ptosis, lateral rectus palsy, facial nerve palsy and upper extremity anomalies.

There are 3 variants of klippel feil syndrome [4,5]. Type 1 is an extensive abnormality where elements of several cervical & upper thoracic vertebrae are incorporated into a single block. In type 2, failure of complete segmentation occurs at one or two cervical interspaces. Type 3 variant includes type 1 or 2 deformities with co-existing segmentation errors in the lower thoracic or lumbar spine.

Our patient had type 1 Klippel Feil syndrome with massive fusion of the cervical spines. These patients have a potentially unstable cervical spine and abnormal atlanto-occipital junction and are prone to an increased risk of neurological damage. Syncopal attacks may be precipitated by sudden rotatory movements of the neck in patients with Klippel Feil syndrome.

Falk and Mackinnon⁹ reported that airway control can be temporarily lost after induction and an LMA may be required to attain control of the airway. In 1988, Daum and Jones [6] suggested that the most prudent and effective way is an awake fiberoptic intubation with good conditions found in awake patients since they can assist in clearing their own secretions, phonating or panting. The nasal route is preferred since the tongue is out of the way and the patient cannot bite down on the tube or scope. However oral intubation may attempt using an appropriate airway cum bite block like the ovassapian airway. Blind nasotracheal intubation is an alternate mode of securing the airway in difficult intubations [7], this technique however is associated with flexion and extension, two maneuvers which are avoided in patients with an unstable spine. There was also a failure in fiberoptic intubation on two separate occasions [8].

The intubating LMA has also been used to facilitate intubation without manipulation of the head and neck. Keller and Brimacomb [9] suggest that cervical pressures generated by the Laryngeal mask devices can produce posterior displacement of the normal cervical-spine. Therefore caution must be used when extrapolating these findings to the unstable cervical-spine. It would entail difficulty for regional anaesthesia keeping in view the spinal fusion and scoliosis. The dose of a single bolus of spinal anaesthetic would be difficult to judge in this patient and epidural anaesthesia might prove technically difficult and is associated with an increased risk of inadvertent dural puncture and poor spread within the dural space [10].

This patient's abnormality posed problems for all the commonly used techniques for caesarian section. GA could be complicated by difficult intubation while greater use of regional anaesthesia may have reduced the number of deaths due to failed intubation in obstetrical

anaesthesia practice. A subarachnoid block for this emergency LSCS was considered a the best first option (with emergency intubation tray and standby surgeon ready in failed spinal block or failed intubation condition) for delivery of the baby by our team and the case was managed successfully with favourable outcome to both mother and baby.

References

1. Klippel M, Fell A (1912) Un cas d'absence des vertebres cervicales. Soc Anat Paris Bull et Mem 14: 185.
2. <http://ghr.nlm.nih.gov/condition/klippel-feil-syndrome>
3. Mohamed JY, Faqeih E, Alsiddiky A, Alshammari MJ, Ibrahim NA, et al. (2013) Mutations in MEOX1, encoding mesenchyme homeobox 1, cause Klippel Feil anomaly. Am J Hum Genet 92: 157-161.
4. William C, Warner Jr (2003) Paediatric Cervical Spine: In: Campbell's operative orthopaedics. (10th edn). Mosby 2: 1737-1740.
5. Falk RH, Mackinnon J (1976) Klippel-Feil syndrome associated with aortic coarctation. Br Heart J 38: 1220-1221.
6. Daum RE, Jones DJ (1988) Fiberoptic intubation in Klippel-Feil syndrome. Anaesthesia 43: 18-21.
7. Crosby ET, Lui A (1990) The adult Cervical Spine: implications for airway management. Can J Anaesth 37: 77-93.
8. Asai T, Shingu K (2004) Difficulty in advancing a tracheal tube over a fiberoptic bronchoscope. Br J Anaesth 92: 870-881.
9. Keller C, Brimacombe J, Keller K (1999) Pressures exerted against the cervical vertebrae by the standard and intubating laryngeal mask airways. Anesth Analg 89: 1296-1300.
10. Dresner MR, Maclean AR (1995) Anaesthesia for caesarian section in a patient with klippel-Feil syndrome. Anaesthesia 50: 807-809.