

An Umbilical Nodule: A Case Report

Zaouri H^{*}, Amarouch H, Elmakrini N, Berbich L, Senouci K and Hassam B

Department of Dermatology, Ibn Sina Hospital University Rabat Morocco, Morocco

***Corresponding author:** Hasnaa Zaouri, MD, Department of Dermatology, Ibn Sina Hospital University Rabat Morocco, Morocco, Tel: 00212661223823; E-mail: hasnaazaouri@yahoo.fr

Received date: March 10, 2016; **Accepted date:** April 21, 2016; **Published date:** April 28, 2016

Copyright: © 2016 Zaouri H, et al. This is an open-access article distributed under the terms of the Creative Commons Attribution License, which permits unrestricted use, distribution, and reproduction in any medium, provided the original author and source are credited.

Abstract

The nodule of Sister Mary Joseph is a cutaneous metastasis of an intra-abdominal cancer. Herein, we report a case of a 57 years old female, who had a four months history of an umbilical nodule. The paraclinical investigation showed a cutaneous metastasis of a colon adenocarcinoma, with peritoneal carcinomatosis and a hepatic metastasis. Patient underwent a palliative chemotherapy with a fatal evolution after the second cure. Through this case report, we highlight the importance of an active search for an underlying neoplasm in front of an umbilical nodule.

Keywords: Sister Mary Joseph's nodule; Umbilical metastasis; Colon adenocarcinoma

Introduction

The umbilical cutaneous metastasis of visceral tumors is rare, they are known as "the Mary Joseph's nodule". Herein, we report a new case of an umbilical nodule revealing a metastatic colon adenocarcinoma.

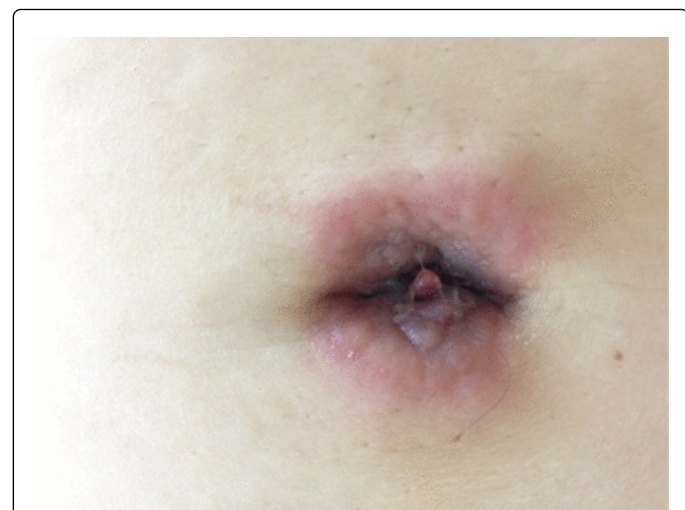

Figure 1: Reddish and firm umbilical nodule (Sister Mary Joseph's nodule).

Clinical Case

A 57 years old female, who presented with a four months history of a reddish and firm umbilical nodule, which gradually increased in size and pain (Figure 1). The histopathological finding showed a cutaneous metastasis of a well-differentiated adenocarcinoma partially mucinous, CK20+ (Figures 2 and 3). Colonoscopy showed a budding tumor, the biopsy confirmed the primary origin of the adenocarcinoma. CT

showed a widespread peritoneal carcinomatosis with hepatic metastasis (Figure 4). A palliative chemotherapy with capecitabine, oxaliplatin and bevacizumab was indicated. The patient died two weeks after the 2nd cure of chemotherapy.

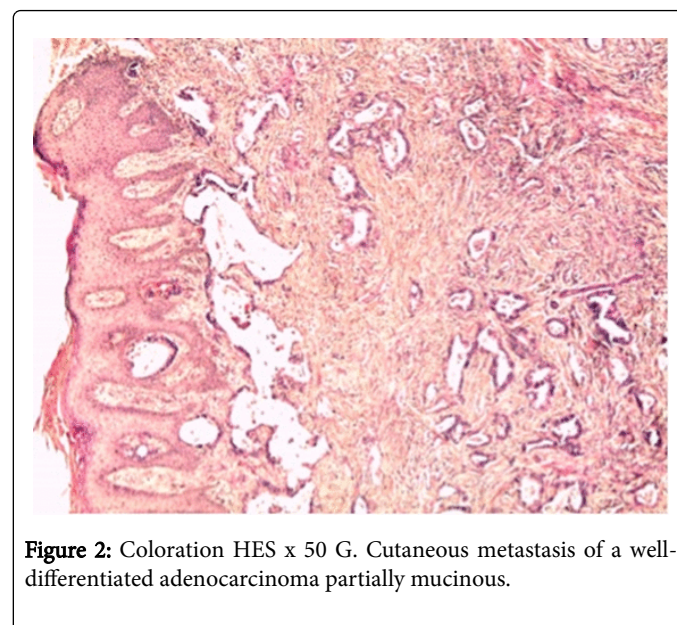


Figure 2: Coloration HES x 50 G. Cutaneous metastasis of a well-differentiated adenocarcinoma partially mucinous.

Comments

Mary Joseph's nodule is usually associated with gastrointestinal tract cancer and ovarian carcinoma. This nomination refers to Sister Mary Joseph, a catholic nurse who worked with the Mayo brothers, and who noticed that patients with terminal carcinoma sometimes developed red papular lesions in the umbilicus [1]. Several hypotheses explain the tumorigenesis of this nodule. Indeed, neoplastic cells can disseminate into the umbilicus through different mechanism: a hematogenous spread; or an extension from the liver round ligament, by contiguity through the dermal vessels of the navel; and finally a retrograde lymphatic flow mechanism [2].

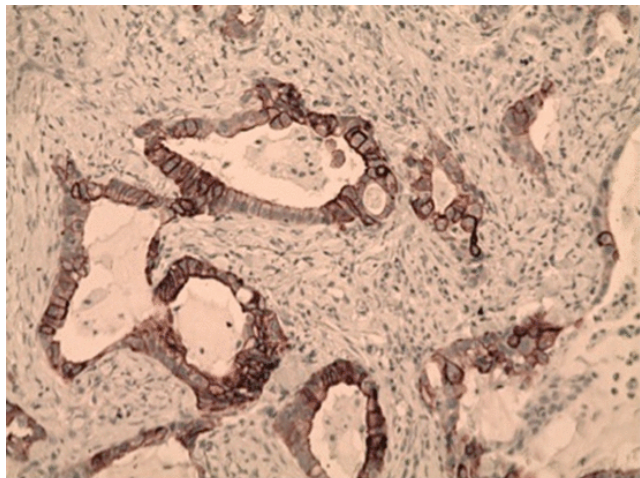


Figure 3: IHC x 200 G. Expression of CK20 by tumor cells.

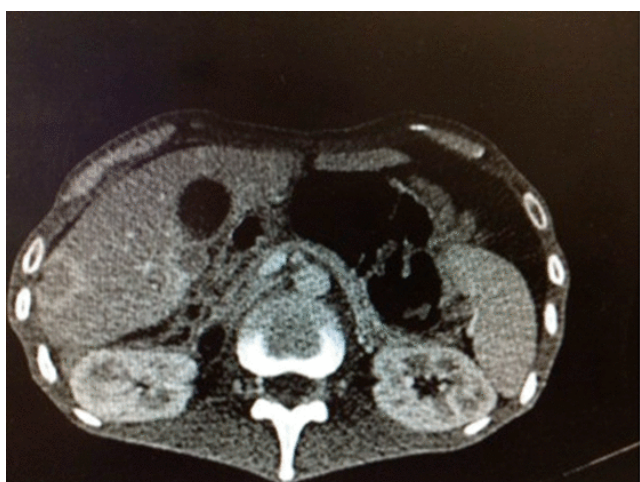

Figure 4: CT thoraco-abdominal-pelvic: Peritoneal carcinomatosis with hepatic metastasis.

The clinical presentation is an indurated and irregular painless nodule, with variable diameter (typically less than 5 cm), often with a vascular appearance. The surface can be fissured or ulcerated with hemorrhagic, mucinous, serous, or purulent discharge. The histological findings confirm the diagnosis of an adenocarcinoma in 75% of cases, rarely squamous cell carcinoma, and undifferentiated cancer or carcinoid tumors. Primary neoplasms have usually an abdominoperineal origin (ovarian, endometrial, cervix, pancreas, and biliary tract, gastrointestinal or genitourinary tumors). Nevertheless, in 10-30 % of cases, the primary tumor remains unknown. Till now, there isn't a well-defined consensus on treatment. However, surgery combined with a chemotherapy treatment have improved survival [3,4]. Mary Joseph's nodule have a poor prognosis, the average survival after the onset of umbilical metastasis is about six months [3].

In summary, an umbilical nodule is easily accessible to clinical examination, its recognition as a secondary lesion of a primary abdominoperineal cancer can enable early diagnosis and treatment.

References

1. Albano EA, Kanter J (2005) Sister Mary Joseph's Nodule. *N Engl J Med* 352: 1913.
2. Touraud JP, Lentz N, Dutronc Y, Mercier E, Sagot P, et al. (2000) Métastase cutanée ombilicale (ou nodule de Soeur Mary Joseph) révélatrice d'un adénocarcinome ovarien. *Gynécol Obstét Fertil* 28: 719-721.
3. Papalas JA, Selim MA (2011) Metastatic vs primary malignant neoplasms affecting the umbilicus: clinicopathologic features of 77 tumors. *Ann Diagn Pathol* 15: 237-242.
4. El khadir A, Hliwa W, Alaoui R (2013) Umbilical cutaneous metastasis (Sister Mary Joseph's nodule) as the presenting symptom of a small bowel adenocarcinoma-A case report. *Hegel* 3: 2013.