

## All-Inside Arthroscopic Proximal Patellar Realignment

Mohamad H. Fahmy\*

Faculty of Medicine, Zagazig University, Zagazig, Sharkia, Egypt

\*Corresponding author: Mohamed Hamed Fahmy, Faculty of Medicine, Zagazig University, Zagazig, Sharkia, Egypt, Tel: 00201221053987; E-mail: mhamed375@gmail.com

Received date: May 11, 2015, Accepted date: July 13, 2015, Published date: July 20, 2015

Copyright: ©2015 Fahmy MH. This is an open-access article distributed under the terms of the Creative Commons Attribution License, which permits unrestricted use, distribution, and reproduction in any medium, provided the original author and source are credited.

### Abstract

**Background:** Patello femoral joint injuries are very common in athletes especially the young age and adolescents. Over 100 operations have been described for the management of recurrent lateral patellar instability.

**Purpose:** The purpose of this study was to determine the clinical results of arthroscopic all-inside proximal patellar realignment.

**Patients and methods:** 17 patients (19 knees) with chronic lateral patellar instability were managed by arthroscopic all- inside proximal Patellar Realignment. There were 7 male knees and 12 female knees. The right leg was involved in 11 patients, and the left leg in 8. The average patient age was 17 years (range, 14 to 18 years). Medial retinacular sutures were introduced percutaneously using an epidural needle 17–20 gauge. Two accessory superolateral portals were created and a 6mm cannula is introduced in each portal. Each pair of suture was then delivered one by one to the distal accessory superolateral portal and standard arthroscopic knot tying was performed.

**Results:** The Lysholm score improved from 35 preoperatively to 81 postoperatively. The results were excellent in ten knees (%52.6), good to excellent in four knees (%21.1), fair to good in two knees (%10.5), fair in two knees (%10.5) and poor in one knee (%5.3).

**Conclusions:** All - inside arthroscopic technique can be used to correct mild lateral patellar instability with 1 to 2+ lateral patellar glide and in teenagers with 3 to 4+ lateral patellar glide with no or mild trochlear dysplasia. It has relatively few complications if proper rules are followed.

**Keywords:** All-inside; Proximal patellar realignment; Arthroscopic

### Introduction

Stability of the patellofemoral joint is maintained through a complex interaction between soft tissues and bony structures. These are divided into 3 groups: (1) active stabilizers, represented by the quadriceps muscles (2) passive stabilizers, represented by the retinacula and the medial patellofemoral ligaments, and (3) static stabilizers, represented by articular geometry. This complex interaction may be disturbed by anatomic variation or trauma, resulting in patellofemoral instability [1]. Proximal patellar realignments are generally done for patients with lateral patellar instability. These include all-arthroscopic, arthroscopically assisted, mini-open or open reefing procedures, and reconstruction of the MPFL. Arthroscopic reefing of the MPFL and the medial retinacular restraints are generally performed by an arthroscopically assisted technique of imbricating the medial tissue [2].

All-arthroscopic techniques are used for patients with mild lateral patellar instability (an increased glide of 1–2 quadrants, with no trochlear dysplasia) and a miniopen “reefing” or advancement of the MPFL when there have only been a few episodes of dislocation, the integrity of the ligament is excellent, and the femoral attachment is intact. For more severe cases of 3 to 4+ lateral patellar instability, particularly when trochlear dysplasia is present, MPFL reconstruction

is preferred since the tissue has already proven that it has failed [2]. MPFL reefing or reconstruction is an operation for instability, not an operation for pain or arthrosis, so careful clinical examination of the patient and radiographic evaluation is necessary before surgery to avoid complications [2].

There are many techniques described. The International Patellofemoral Study Group preferred the technique described by Halbrecht, [3] since it is relatively simple and free of complications. Technically, the ability to tie knots arthroscopically is imperative, particularly using the Halbrecht technique [2]. Arthroscopic medial retinacular repair was first described by Yamamoto et al. It reinforces the passive stabilizers of the patellofemoral joint, which represents the combination of the medial patellofemoral complex with the medial patellofemoral ligament (MPFL) and has been shown to be the main anatomic restraint to patellar lateralization. So repair of the medial structures has been advocated as adequate therapy for patellofemoral instability [4].

In 2001 Jeffrey L. Hallbricht [3], described his technique of arthroscopic all-Inside proximal Patellar Realignment that was considered a major breakthrough in the treatment of patellar instability [3]. Although the idea and the surgical technique were brilliant at the time but when the technique was popularized researchers found that some surgical steps needed to be further studied

and reanalyzed. By far the most controversial step in Hallbricht technique was the step of lateral retinacular release.

## Patients and Methods

Between May 2010 and May 2012, 17 patients (19 knees) with chronic lateral patellar instability were managed by arthroscopic all-inside proximal Patellar Realignment. There were 7 male patients and 10 female patients. Two female patients had bilateral knee involvements and they had surgery for both right and left knees. There were 7 male knees and 12 female knees. The right leg was involved in 11 patients, and the left leg in 8. The average patient age was 17 years (range, 14 to 18 years).

Careful history and clinical examination was performed. All cases reported a history of relevant trauma of valgus force with a planted foot and an internal rotation of the femur or an external rotation of the tibia after which symptoms of anterior knee pain, crepitus and giving way started.

We examined the Hip and the foot to exclude cases of severe femoral anteversion associated with patellar instability as it requires a derotational osteotomy of the femur. Patellar tracking, was examined in the standing position and in the sitting position as well. Medial and lateral patellar glide at 0 and 30°. Passive patellar tilt and Sage sign will help determine clinically whether or not the lateral retinaculum is tight and needs to be addressed. Follow-up duration for all patients was 24 months.

## Patellofemoral radiographs

A true lateral at 30° of flexion to measure patellar height and also to determine whether or not trochlear dysplasia is present. The measurement techniques of Caton-Deschamps provide a more accurate assessment of patella height than that of Insall-Salvati as they are based on the articulating length of the patella. A normal ratio is between 0.8 and 1.2. A true lateral will allow for observation of the crossing-sign or trochlear bump found in trochlear dysplasia. CT patellar tracking study was performed. This includes a set of images of mid-axial images from 0 to 60° in 10° increments to look at patellar tracking in this range. Lateral patellofemoral angle, congruence angle, and tilt angle were better evaluated from axial CT scans at incremental degrees of flexion.

Fixed-frame images from proximal to the trochlea distally through the tibial tubercle were taken. Through these images we can measure the TT-TG or the tibial tubercle-trochlear groove distance. The classic study by Jones [5] indicates a TT-TG of greater than 20 mm is highly abnormal, 12-20 mm is borderline, and less than 12 mm is considered normal.

When the TT-TG becomes more than 20 mm, one must seriously consider a distal realignment procedure. All patients had a preoperative MRI examination. The MPFL is carefully studied for attenuation or rupture (Figure 1). Concomitant knee pathology was also diagnosed.

The inclusion criteria for this study were patients with mild lateral patellar instability (an increased glide of 1-2 quadrants) who had failed at least 6 months of conservative treatment and teenagers with 3 to 4+ lateral patellar glide with no or mild trochlear dysplasia.

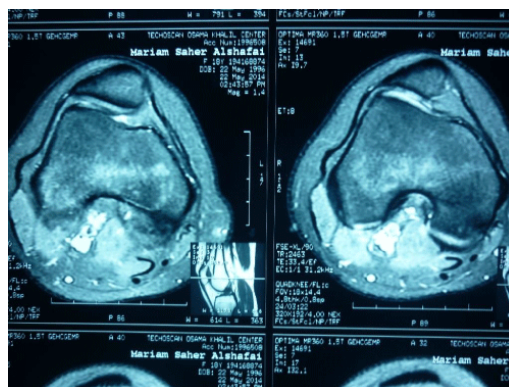


Figure 1: Pre op MRI showing dysplastic trochlea, weak and stretched MPFL due to chronic lateral patellar dislocation.

The exclusion criteria were, Patients with MPFL rupture, Patients with abnormal TT-TG distance of more than 20 mm, Patients with significant trochlear dysplasia and Patients with patella Alta with a ratio of 1.3 or greater according to the Caton-Deschamps index. Follow-up examination included physical, radiographs, Lysholm score and Patella score designed by Halbrect.

## Surgical technique

Patients were placed in the supine position. Surgery was performed under spinal anesthesia, thigh tourniquet, preoperative antibiotics and a controlled pressure arthroscopic pump.

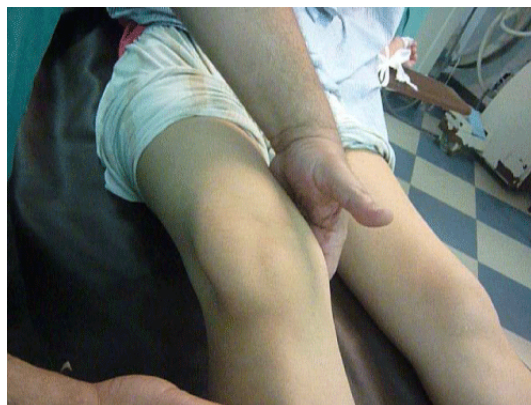
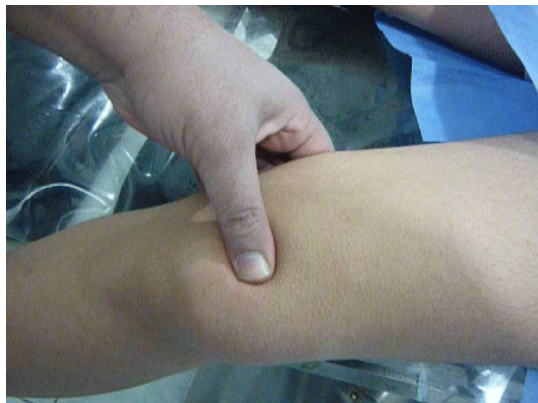
Figure 2: Pre op clinical photo showing lateral patellar glide 4+ of the right knee with the knee at 30° flexion.

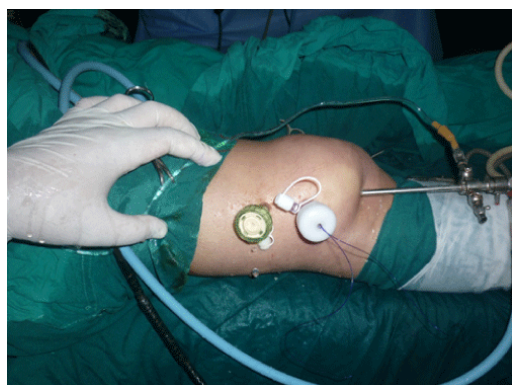
Examination under anesthesia revealed lateral patellar instability by use of minimal force with the knee flexed between 25° and 45° in all cases (Figures 2 and 3). We begin with standard arthroscopy examination of the knee through a standard anterolateral viewing portal and an anteromedial working portal. The patellofemoral joint was examined through a superolateral portal.



**Figure 3:** Pre op clinical photo showing lateral patellar glide 4+ of the left knee of the same patient at 30° flexion.

Examination through this portal allows better visualization of the joint because the arthroscope is at a greater distance from the patella. Chondral lesions of the patella and trochlear sulcus of the distal femur were carefully looked for and recorded. The knee was moved through its range of motion and tracking was observed and recorded. The medial retinaculum was roughened by use of a Linvatec shaver (Linvatec, Largo, FL) to encourage healing before insertion of the sutures. Medial retinacular sutures were introduced percutaneously using an epidural needle 17–20 gauge (Tuohy Needle; Rusch, Deluth, GA). We never use spinal needles for suture passage because it has a cutting edge that cut the suture. An epidural needle is essential because of the noncutting edge on the inner bevel of the tip that prevents cutting of the suture.

Two accessory superolateral portals were created and a 6mm cannula is introduced in each portal (Figure 4). The proximal portal was used for suture storage and the distal one was used for arthroscopic knot tying.

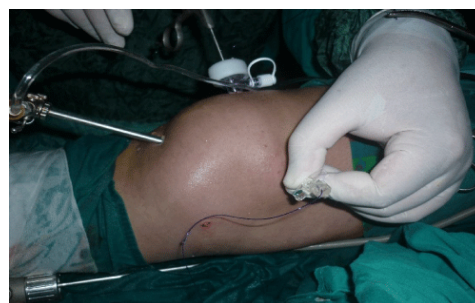

**Figure 4:** Intraoperative photo showing two cannulas one placed in the superolateral portal and another one placed in an accessory proximal superolateral portal for suture storage.

The needle is placed adjacent to the medial patella and a No. 1 PDS suture is passed manually through the needle and retrieved arthroscopically through the proximal accessory superolateral portal

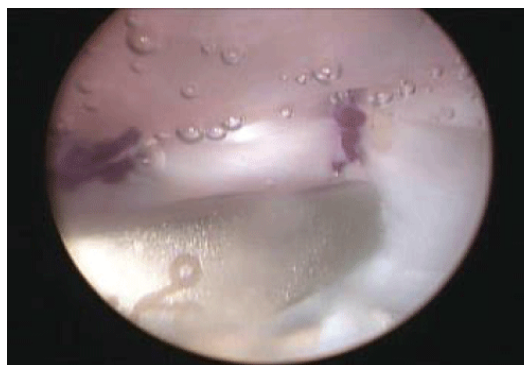
(Figure 5). The needle is gently withdrawn from the retinaculum but not out of the skin. The needle is then redirected subcutaneously approximately 2 to 3 cm posteriorly and reinserted through the retinaculum again. This creates a loop of suture that is retrieved again through the same accessory portal.

As the sutures are passed, the higher the degree of laxity, the more imbrication should be performed. To avoid injury to some of the branches of the saphenous nerve we must be sure that the suture is passed just outside the capsule and does not capture any of the subcutaneous tissue. If there is any question, a mini-incision can be made to free up the suture from the subcutaneous tissue, by hand, before they are tied. A grasper forceps is used to hold the second pass of the suture then the needle is withdrawn from the retinaculum. Each one Centimeter of retinacular tissue received one suture, in average 4 to 5 sutures were placed. Each pair of suture was clamped and stored in the proximal accessory superolateral portal for proper recognition.



**Figure 5:** Intra operative photo showing, scope in the anterolateral portal, epidural needle delivering NO 1 PDS suture into the medial patellar retinaculum and a grasper forceps retrieving the PDS through the superolateral cannula.

Each pair of suture was then delivered one by one to the distal accessory superolateral portal and standard arthroscopic knot tying was performed. We started with the most proximal suture and proceeded distally (Figure 6).



**Figure 6:** Intra-operative photo showing medial knots with plicated medial structures.

Full correction of tracking of the patella was confirmed by inspection through the superolateral portal while moving the knee

through range of motion. Arthroscopic lateral release was never performed in all of our cases.

### Postoperative treatment

Involved a brace locked in full extension for 1 week during which closed-chain exercises were allowed. After the first week, the brace was unlocked to enable patients to begin range of motion exercises, but bracing was continued for 3 to 4 weeks until quadriceps strength returned. Patients were not allowed to flex past 90° for 4 weeks, but could begin weight bearing immediately in the brace. Open-chain kinetic exercises were instituted at 6 weeks. At 3 months, intensive weight resisted vastus medialis obliquus and quadriceps exercises were started and light sporting activity was introduced, whereas contact sports were allowed at 6 months.

### Results

Patients were evaluated at 3, 6, 12 and 24 months post-operative. Final outcome score was recorded at 24 months follow-up.

The Lysholm score improved from 35 preoperatively to 81 postoperatively. The results were excellent in ten knees (%52.6), good to excellent in four knees (%21.1), fair to good in two knees (%10.5), fair in two knees (%10.5) and poor in one knee (%5.3).

**Patella score:** This score was introduced by Halbrecht to evaluate the results of arthroscopic surgery of the unstable patella. It is a subjective rating scale for pain, swelling, crepitus, and instability, with 10 considered the worst possible symptoms, and 0 as no symptoms. Patients reported an improvement in pain from 8.3 preoperatively to 2.1 postoperatively. Crepitus improved from 6.2 preoperatively to 2.2 postoperatively. Swelling improved from 7.0 to 0.5. Instability improved from 8.5 to 0.9.

According to Halbrecht, return to sports participation was rated on a reverse scale, with 10 being full return to sports and 0 being sedentary. Patients improved from an average preoperative score of 2.0 to 7.0 postoperatively.

**Range of motion:** only one case, a Syrian teenager had a loss of the last 10° of flexion at final evaluation and his parents refused to subject him to manipulation under anesthesia and they reported that they are satisfied with this result.

On the other hand, all other cases regained full range of motion postoperatively. None of the patients required manipulation or repeat surgery.

**Atrophy:** Two patients had a thigh atrophy of 8 mm at final evaluation.

**Radiographic evaluation:** All of our patients had postoperative radiographic evaluation by standard Merchant views.

**Congruence angle:** The congruence angle improved from an average of 32.0° preoperatively to 8.0° postoperatively.

**Lateral translation:** Preoperative lateral translation improved from 9.0 mm to 1.1 mm following realignment.

**MRI evaluation:** We were able to perform postoperative MRI for only 11 knees. All MR scans showed restoration of patellar congruency and the stretched attenuated medial retinaculum and MPFL were restored to normal thickness (Figure 7).

**Patient satisfaction:** on a simple subjective rating scale designed by Halbrecht, patients were asked to evaluate the results of their surgery. Two female patients one aged 14 years and the other aged 15 years with bilateral chronic lateral patellar instability had a common complaint that they cannot sleep as their patellae dislocate constantly when they go to the deep faze of sleep.

These two patients reported the highest patient satisfaction outcome as they were able to have a normal sleep pattern and participate in regular school and sport activities.

These two patients decided to have the same procedure for the other knee 6 months after the first surgery. %74 of the patients reported that their knees are normal or near normal. %21 felt that they are significantly better. We had no case of redislocation (Figures 2, 3, 8 and 9).

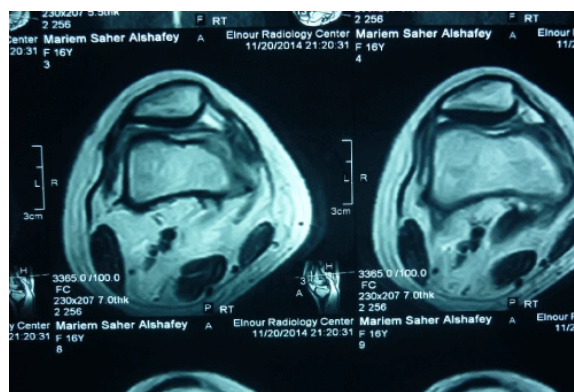


Figure 7: Post op MRI after arthroscopic imbrication of the MPFL and medial retinaculum showing well centralized patella and restored thickness of the MPFL.

One patient with loss of the last 10 degrees of extension reported the least satisfaction score of slight improvement after surgery.

### Discussion

For first time acute patellar dislocation a conservative approach was considered to be a valuable treatment option.

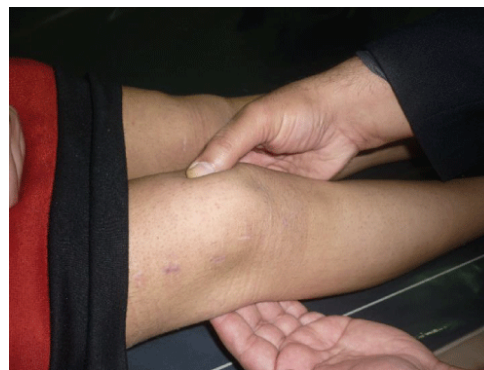
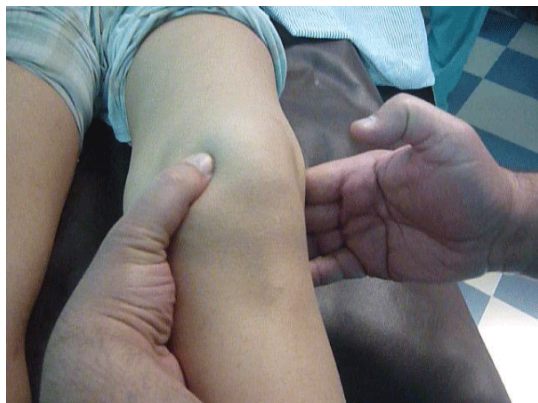
Figure 8: Post op clinical photo showing restoration of lateral patellar glide to normal for the right knee at 30° flexion.

However, depending on the literature the redislocation rate is reported to be in the range between 15% and 44% [6].

Acute surgical repair of the medial parapatellar retinaculum and/or MPFL with various methods has been described to have a recurrence rate between 10% and 20% [7]. White and Sherman in a recent literature review on patellofemoral instability concluded that accepted indications for surgery in the acute setting to be osteochondral fragments, persistent patellar subluxation and detachment of the VMO and medial retinaculum from the medial aspect of the patella [8].



**Figure 9:** Post op clinical photo showing restoration of lateral patellar glide to normal for the left knee of the same patient at 30° flexion.

The only prospective randomized clinical trial on conservative versus operative treatment after acute patellar dislocation was published in 1997 by Nikku et al. [9]. Two to 5 years postoperatively they did not find any significant difference between groups in recurrent instability. Their recommendation was that patients will be best treated initially with nonoperative management. Additionally they noted that between 2- and 5-year studies, an additional one third of their patients had a subsequent episode of instability.

Arthroscopic medial capsular and retinacular repair in acute patellar dislocation was first reported by Yamamoto et al. [4]. Yamamoto treated 30 acute patella dislocations with arthroscopic lateral release along with an arthroscopically assisted repair of the medial retinaculum. He recommended the transcutaneous passage of sutures through the retinaculum using a large curved needle, although the sutures were still tied through a medial skin incision. Only acute dislocations were treated. Reported results were excellent, with only one reported case of redislocation. The authors concluded that the procedure was successful in the stabilization of the acute dislocation of the patella.

Small et al. [10] reported a modified version of the Yamamoto technique, also utilizing an arthroscopically assisted method and a small medial incision. They concluded that this procedure should be considered in patients with recurrent patellar instability and cases of first time dislocation in an athletic individual wishing to return to full sports with improved patellofemoral stability within a reasonable short period of time.

Henry et al. [11] described their experience of the same technique. They described an arthroscopically assisted technique using cannulated needles, but tied the sutures through a medial incision as

well. After 6 years they concluded that the procedure was of low technical demand, consistency of results and it was associated with a low morbidity and cosmesis making it a “worthwhile” technique. They did experience no recurrent patellar dislocations and a significant improvement in patellofemoral pain.

Halbrecht, et al. [3] described the first all arthroscopic procedure for proximal patella realignment. They examined 29 knees 2-5 years after an all-inside arthroscopic medial reefing (knots tied arthroscopically in the joint) combined with a lateral release for acute patellar dislocation (n=23) or subluxation (n=6). Ninety-three percent of the patients reported a significant subjective clinical improvement for pain, swelling, stair climbing and their ability to return to sports. The Lysholm Score was reported to be improved from 41.5 to 79.3 points and there was a significant improvement of the congruence angle, lateral patellofemoral angle and lateral patella displacement on postoperative radiographs. There was no complications or redislocation. The authors concluded that an arthroscopic all-inside patella realignment may be recommended and may offer comparable or superior results to published open or arthroscopically assisted repairs. It eliminates the need for medial incisions for knot-tying and the vastus medialis obliquus is not violated.

The author believed that conservative treatment is not a reliable option to address this problem as the failure rate reported in the literature is up to 52%. The author also criticized lateral retinacular release as a single procedure to address this problem stating that there is a high incidence of recurring instability as the procedure does not address the disrupted anatomy of the medial retinaculum and is not considered by most authors to be an effective treatment for true patellar instability or malalignment [3].

In 2002 Haspl et al. [12] presented their arthroscopic technique for the treatment of patellofemoral instability. It consisted of plication of the medial patellar retinaculum and release of the lateral patellar retinaculum. Indications were acute, but also recurrent patellar dislocation. The procedure was performed in 17 patients between the ages of 14 and 27 years. The short-term results with an average follow-up of 13.3 months did not show any recurrent dislocations or subluxations. They recommended the procedure for patella maltracking as well as acute and recurrent patellar dislocations particularly in adolescents and young adults.

The influence of predisposing factors was assessed on radiographs by Rillmann et al. [13]. They reported results of arthroscopic repair of the medial retinaculum after first time dislocation in 38 knees. Patella Alta (according to Caton index) was seen in 37% of patients and trochlear dysplasia (TD) (according to lateral x-ray) in 15% respectively. The redislocation rate after a mean follow-up of 25 months was only 10% and two out of three redislocations occurred in patients with predisposing factors. Rillmann et al. [13] reported that 84% of their patients showed a very good or good result and only 16% a fair result including the cases with redislocations. Based on these findings the authors concluded that an arthroscopic repair of the medial retinaculum after first time dislocation is a minimal invasive method with very low peri- and postoperative morbidity. Furthermore they stated, that the redislocation rate can be reduced to at least 50% compared to the published data on conservative treatment.

The influence of underlying bony trochlear dysplasia (TD) on clinical outcomes of arthroscopic medial retinacular repair was further described by Schöttle et al. [14]. Ninety-one patients were included and the trochlear dysplasia was assessed according to H. Dejour [15] in

48 patients on axial CT scans. The overall redislocation rate was 8.3%. Patients without or with grade A trochlear dysplasia had a significant better postoperative outcome than those with a grade B or C TD. All redislocations occurred with severe TD. From these results they concluded that the reefing of the medial retinaculum is an effective treatment for patients who suffer from a patellar dislocation without having a severe trochlear dysplasia. However in patients with underlying TD, patellofemoral stability cannot be completely restored and clinical results are less successful. They advised to perform a precise preoperative radiologic determination of trochlear geometry to predict short-term outcome in patients with patellofemoral instability [14].

In our study, we followed the surgical principles of Dr. Halbrecht [3]. In the Halbrecht study, they enlisted 29 knees, 23 were actual dislocators and 6 were subluxators. The recommendations of the international patellofemoral study group [2] is that arthroscopic proximal patella realignment should be performed for patients with mild lateral patellar instability (an increased glide of 1–2 quadrants, with no trochlear dysplasia). The group recommended that actual dislocators with of 3 to 4+ lateral patellar instability, (particularly when trochlear dysplasia is present) should be treated with MPFL reconstruction. We examined two teenage girls (14 and 15 years) with bilateral chronic lateral patellar instability with 4+ lateral glide and mild trochlear dysplasia. These are the only two cases (4 knees) in which we overruled the recommendations of the group. Surprisingly, these two cases reported the best patient outcome in this study.

According to the recent literature it was necessary to make some modifications to the Halbrecht technique. The first modification is that we never performed lateral retinacular release in a routine base for all of our cases. That was based on the well-established biomechanical principle that the MPFL and the lateral retinaculum are important structures preventing lateral instability of the patella [15].

Desio et al. [16] explained why there is no biomechanical advantage to performing a lateral release. They demonstrated that the MPFL provides 60% of the lateral displacement restraint, but surprisingly, the lateral retinaculum also provided 10% of the lateral restraint. This is in agreement with Fithian et al. [17] who stated that a lateral release has no role in the treatment of a hyper-lax PFJ and should be used judiciously on a case by case basis.

The ideal indication for lateral retinacular release is excessive lateral pressure syndrome (ELPS) hallmarked by pain in the lateral part of the patellofemoral compartment, associated with negative passive patellar tilt (Kolowich sign), a negative Sage sign (medial glide of patella less than one quadrant, with the knee at 15–20° of flexion), and imaging evidence of lateral patellar tilt, either by radiographs, CT, or MRI. Lateral release may also be necessary in patellar realignment surgery for recurrent lateral patellar instability, with the above signs, when lateral release is necessary to re-center the patella. The most feared complication after lateral retinacular release is medial patellar instability, a very disabling condition, which is usually far worse than the condition that the patient started off with [2].

The second modification was that using only one arthroscopic cannula to retrieve the medial sutures and perform suture tying at the same time was cumbersome. The sutures frequently got tangled, twisted and rotated around each other. There was a lot of surgical time wasted to identify matching suture pairs so we decided to add another arthroscopic cannula placed in the accessory proximal superolateral patellar portal and used this cannula for suture storage and we used

the other cannula placed in the superolateral patellar portal for arthroscopic knot tying. This made the procedure easier and saved a lot of surgical time.

Our results are comparable to the Halbrecht [3] study in which Lysholm score improved from 41.5 preoperatively to 79.3 postoperatively in our study Lysholm score improved from 35 preoperatively to 81 postoperatively.

Concerning patient satisfaction, 74% of our patients reported that their knees are normal or near normal. 21% felt that they are significantly better. These results are slightly better than those reported by Halbrecht as he reported that 93% felt that they were significantly better, 1 patient felt that she was worse, and 1 felt that there was no change. Halbrecht reported no postoperative dislocations. In our study we had no postoperative dislocations.

Our results are comparable to the study of Haspl, et al. [12] although they performed lateral retinacular release and they included acute cases in their study. The short-term results with an average follow-up of 13.3 months did not show any recurrent dislocations or subluxations.

In our study there were two teenage girls, 14 and 15 years old with bilateral chronic recurrent lateral patellar dislocation and mild trochlear dysplasia. They reported a quiet disturbing complaint that they are afraid to sleep as their patellae constantly dislocate as they go to the deep phase of sleep. According to the recommendations of the International Patellofemoral Study Group we should go for MPFL reconstruction. Due to the very young age of the patients and the bilateral involvement, we discussed with their parents the possibility of performing arthroscopic medial reefing based on Halbrecht study [3]. After taking the parents' consent surgery was performed. Surprisingly these two cases reported the best patient satisfaction scores and had a high subjective outcome score. This finding supports Halbrecht recommendations that arthroscopic allinside proximal patellar realignment can be performed for actual dislocators with 3 to 4+ lateral patellar glide especially in teenagers below 16 years of age.

The fact that arthroscopic techniques employ few stab incisions added more to the improved cosmeses after surgery and was reflected on the patient outcome scores especially in teenage girls.

Surgeons attending such complex problem of patellofemoral instability may benefit the following protocol for assessment and management.

Careful history taking to distinguish acute from recurrent cases. The nature of trauma may give a clue to proper diagnosis e.g. violent trauma with an element of external rotation may suggest MPFL rupture whereas, habitual subluxation or dislocation is strongly suggesting high grades of trochlear dysplasia.

### **If you are dealing with chronic recurrent subluxation or dislocation of the patella, here are some pearls to consider**

Look for signs of generalized ligamentous laxity. Examine the Hip and the foot to exclude cases of severe femoral anteversion associated with patellar instability as it requires a derotational osteotomy of the femur. Examine the knee, as a valgus alignment may need distal femoral varus osteotomy.

## Radiologic evaluation

MRI study is the most valuable tool to wrap up your final diagnosis and to plan the accurate management and to avoid catastrophic decisions. Look for the integrity of the MPFL:

Intact attenuated MPFL, with plus + or ++ lateral patellar glide, consider arthroscopic all-inside proximal medial patellar retinacular imbrication. Ruptured MPFL, consider MPFL reconstruction.

## Look for the trochlear morphology

Mild trochlear dysplasia (TD), Dejour type A or B with lateral patellar glide of + or ++, consider arthroscopic all-inside proximal patellar retinacular imbrication.

Mild trochlear dysplasia (TD), Dejour type A or B with lateral patellar glide of +++ or ++++, consider MPFL reconstruction.

Severe TD, Dejour type C or D, consider deepening trochleoplasty plus MPFL reconstruction.

## Measure the TT-TG distance

Through the MRI or CT scans calculate the TT-TG distance. If the TT-TG distance is more than 20 MM, consider distal patella realignment procedure such as the medicalization osteotomy of the tibial tubercle with or without proximal realignment procedure if needed. It would be a catastrophic decision to perform proximal patellar realignment procedure alone if the TT-TG distance is more than 20 MM.

## Estimate the Patellar height

Estimate the patellar height on the sagittal T1-weighted images according to the index of Insall and Salvati (the patellar tendon length to the longest sagittal dimension of the patella). Patella Alta is considered with a ratio greater than 1.3.

If patella Alta is diagnosed, consider a distalisation osteotomy of the tibial tubercle.

## Lateral release

Never perform lateral retinacular release routinely in patella-femoral instability surgery. Put in mind that the lateral retinaculum, in fact is not a cause of lateral patellar dislocation, but in the contrary it is a stabilizer against lateral patellar dislocation. The ideal indication for lateral retinacular release is Excessive Lateral Pressure Syndrome (ELPS) hallmarked by pain in the lateral part of the patellofemoral compartment, associated with negative passive patellar tilt (Kolowich sign), a negative Sage sign (medial glide of patella less than one quadrant, with the knee at 15–20° of flexion), and imaging evidence of lateral patellar tilt, either by radiographs, CT, or MRI. Lateral release may also be necessary in patellar realignment surgery for recurrent lateral patellar instability, with the above signs, when lateral release is necessary to re-center the patella.

**If you are dealing with acute dislocation or subluxation of the patella here are some pearls to consider:**

The concept that all acute patellar dislocations should be managed by a plaster cast is false and can end up with recurrent dislocation. All cases of acute patellar dislocation should have the before mentioned

radiologic investigations including, plain X-rays, CT scan and MRI examination.

If all the static and the dynamic stabilizers of the patella-femoral joint (especially the integrity of the MPFL) are within normal and the history is suggesting a considerable force causing the dislocation, consider a plaster cast treatment followed by aggressive rehabilitation program.

## Conclusion

All-inside arthroscopic technique can be used to correct mild patellar instability. The procedure can be considered in cases of teenagers with 3 to 4+ lateral patellar glide with no or mild trochlear dysplasia. It can also be utilized in conjunction with distal realignments when both the distal and the proximal realignment are necessary. It has cosmetically better results and relatively few complications if proper rules are followed. It does not burn any bridges so that if this fails, the surgeon still has the ability to perform a more extensive open reefing or, more likely, formal medial patellofemoral reconstruction.

## References:

1. Senavongse W, Amis AA (2005) The effects of articular, retinacular, or muscular deficiencies on patellofemoral joint stability. *J Bone Joint Surg Br* 87: 577-582.
2. Michael VE, Scott Z, Anthony AS (2009) Avoiding and Managing Complications in Patella Surgery. *Complications in Knee and Shoulder Surgery* 133-163.
3. Halbrecht J (2001) Arthroscopic patella realignment: An all-inside technique. *Arthroscopy* 17: 940-945.
4. Yamamoto RK (1986) Arthroscopic repair of the medial retinaculum and capsule in acute patellar dislocations. *Arthroscopy* 2: 125-131.
5. Jones RB, Barlett EC, Vainright JR, Carroll RG (1995) CT determination of tibial tubercle lateralization in patients presenting with anterior knee pain. *Skeletal Radiol* 24: 505-509.
6. Tuxoe JI, Teir M, Winge S, Nielsen PL (2002) The medial patellofemoral ligament: a dissection study. *Knee* 10: 138-140.
7. Vainionpää S, Laasonen E, Silvennoinen T, Vasenius J, Rokkanen P (1990) Acute dislocation of the patella. A prospective review of operative treatment. *J Bone Joint Surg Br* 72: 366-368.
8. White BJ, Sherman OH (2009) Patellofemoral instability. *Bull NYU Hosp Joint Dis* 67: 22-29.
9. Nikku R, Nietosvaara Y, Kallio PE, Aalto K, Michelsson JE (1997) Operative versus closed treatment of primary dislocation of the patella. Similar 2-year results in 125 randomized patients. *Acta Orthop Scand* 68: 419-423.
10. Small NC, Glogau AI, Berezin MA (1993) Arthroscopically assisted proximal extensor mechanism realignment of the knee. *Arthroscopy* 9: 63-67.
11. Henry JE, Pflum FA Jr (1995) Arthroscopic proximal patellar realignment and stabilization. *Arthroscopy* 11: 424-425.
12. Haspl M, Cicak N, Klobucar H, Pecina M (2002) Fully arthroscopic stabilization of the patella. *Arthroscopy* 18: 2.
13. Rillmann P, Fischer A, Berbig R, Holzach P (1999) Arthroscopic repair of the medial retinaculum after first time dislocation of the patella. *Unfallchirurg* 102: 167-172.
14. Schöttle PB, Scheffler SU, Schwarck A, Weiler A (2006) Arthroscopic medial retinacular repair after patellar dislocation with and without underlying trochlear dysplasia: a preliminary report. *Arthroscopy* 22: 1192-1198.
15. Dejour D, Reynaud P, Lecoultré B (1998) Douleurs et instabilité rotulienne: Essai de classification. *Med Hyg* 56: 1466-1471.

16. Desio SM, Burks RT, Bachus KN et al. (1996) Soft tissue restrains to lateral patellar translation in the human knee. *Am J Sports Med* 26: 59-65.
17. Fithian D, Paxton E, Post W, International Patellofemoral Study Group et al. (2004) Lateral retinacular release: a survey of the International Patellofemoral Study Group. *Arthroscopy* 20: 463-468.