

Acute Appendicitis: Diagnosis and Treatment, with Special Attention to a Laparoscopic Approach

Samir Delibegovic*

University Clinical Center Tuzla, Tuzla, Bosnia and Herzegovina

*Corresponding author: Samir Delibegovic, Chief of colorectal department, University Clinical Center Tuzla, Bosnia and Herzegovina, Tel: +38761149131; E-mail: delibegovic.samir@gmail.com

Received date: March 10, 2015; Accepted date: April 24, 2015; Published date: May 01, 2015

Copyright: © 2015 Delibegovic S. This is an open-access article distributed under the terms of the Creative Commons Attribution License, which permits unrestricted use, distribution, and reproduction in any medium, provided the original author and source are credited.

Abstract

Acute appendicitis is one of the most common causes of acute abdomen. It may occur from the time of infancy to old age, but the peak age of incidence is in the second and third decades of life. The diagnosis is based on a careful history and physical examination. In patients who have atypical clinical and laboratory findings, US, CT, MRI, a scoring system and laparoscopy can be used. Laparoscopic appendectomy is a safe and effective method for the treatment of appendicitis. It has proven advantages in relation to the open method: less post-operative pain, and a short stay in hospital, quicker recovery and return to normal activities. The causes of unsuccessful procedures vary, and most of the reasons for conversion occur due to the operator's lack of experience.

In general, laparoscopic appendectomy has advantages, but it must be borne in mind that surgical experience in laparoscopic techniques is a pre-condition for surgeons to expect clinical benefits from laparoscopic appendectomy. In clinical conditions, where surgical experience is present, and the necessary equipment, the use of laparoscopy and laparoscopic appendectomy may be recommended in all patients with suspected appendicitis, if laparoscopy itself is not contra-indicated or is not feasible.

Keywords: Appendicitis; Appendectomy; Laparoscopic appendectomy

Introduction

Acute appendicitis is one of the most common causes of acute abdomen. It may occur from the time of infancy to old age, but the peak age of incidence is in the second and third decades of life [1-3]. The lifetime risk of appendicitis is approximately 7-8% [2]. Today in developed countries, about 8% of the population is treated for acute appendicitis in the course of their lifetime [2].

Pathogenesis

The exact mechanisms leading to appendicitis are not still clear. It is likely that luminal obstruction by external (lymphoid hyperplasia) or internal (fecalith) compression, followed by secondary bacterial invasion of the wall, plays a key pathogenic role [4]. That is why it is conceivable that early surgical intervention prevents the progression of the disease. But cases of spontaneous recovery, treatment of this disease only with antibiotics, shed doubt in this hypothesis.

There are other hypotheses which could explain other pathways. It has suggested that viral infection (enteroviruses) may induce mucosal ulceration, which is then followed by secondary bacterial invasion [5]. Ischemia is another possible cause. Cases have been observed in which obstruction of the blood supply to the appendix is associated with morphological changes resembling ischemic colitis [6]. The hygiene hypothesis proposes that appendicitis is triggered by enteric infection during childhood and early adulthood [7]. The diet hypothesis suggests that a diet relatively low in fibre and high in refined carbohydrates, was in some way responsible for the low incidence of

appendicitis in Western countries [7,8]. Genetic factors have been suggested as important. However, separating environmental, dietary, and genetic influences is very difficult.

We may conclude that it is most likely that there are several aetiologies of appendicitis; each leads to the final common pathway of invasion of the wall of the appendix by intraluminal bacteria.

Diagnosis

Clinical examination

The diagnosis of acute appendicitis is based on a careful history and physical examination.

In patients with the typical picture, the diagnosis is easy. Symptoms such as: localization of pain, nausea, vomiting, sensitivity and leukocytes, are clear criteria for diagnosis of acute appendicitis. However, 20-30% of patients have atypical clinical and laboratory findings [9,10], and in these patients we can use Ultrasound (US), Computerized tomography (CT), Magnetic resonance imaging (MRI), a scoring system and laparoscopy.

Laboratory tests

The most commonly used laboratory tests in the diagnosis of acute appendicitis are leukocyte count and C-reactive protein (CRP) [11]. They are used routinely, and their advantage is low cost, where CRP has the advantage in relation to leukocyte count, and may be a useful marker in evaluation of acute appendicitis. Also, as a predictor of perforated appendicitis, serum bilirubin may be used. Other inflammatory markers are also used, such as: D-dimer, Procalcitonin (PCT) but their diagnostic value in acute appendicitis is low [11].

A leukogram is a useful test in the diagnostics of acute appendicitis. In general, patients have a moderately raised number of leukocytes ($1,000/\text{mm}^3$) with a prevalence of neutrophils. Leukocytes above $20,000/\text{mm}^3$ may indicate complications [12-16]. However, a major problem is the low specificity of the leukocyte count of about 25% and sensitivity of about 85% [11]. CRP levels are related to the evolution of the infection of the appendix, and values above 50 mg/dl indicate necrosis and perforation of the appendix. The specificity of this method is slightly higher in relation to the leukocyte count, amounting to about 38-87%, and its sensitivity is up to 94% [17-19].

The serum bilirubin is significantly raised in patients with a perforated appendix, in relation to a simple acute appendicitis without perforation. Its sensitivity varies between 38 and 77%, and specificity from 70 to 87% [20].

Imaging techniques

The clinical accuracy of diagnosis of appendicitis is approximately 80% [21-25], and US and CT are valuable imaging tools, with which it is possible to achieve diagnostic precision greater than using a purely clinical approach. US and CT are used in establishing the diagnosis of acute appendicitis, but also for establishing alternative diagnosis of illness, which may have the same clinical picture of acute appendicitis.

US is an accessible and cheaper method than CT and should be the first imaging method used. However, its accuracy depends on the experience and skill of the operator. In obese and uncooperative patients, it is sometime impossible to diagnose appendicitis using US. In experienced hands, sensitivity is 76-90%, specificity 86-100%, with a positive predictive value of 71-95%, and a negative predictive value of 76-98% [26-28]. US is especially an adequate diagnostic tool in female patients when adnexal pathology can be ruled out as part of the differential diagnosis.

CT significantly reduces the percentage of negative appendectomies in most studies. It has all the corresponding values greater than 85%, even without enteral or intravenous contrast [29-30].

Various combinations of oral, intravenous or rectal contrast are most often used, but no contrast protocols are being used more often, since there is no need to wait for the transit of the oral contrast, no risk of contrast induced nephropathy, or risk of allergic reaction [31]. However, CT diagnosis of acute appendicitis may be uncertain or difficult in patients with scarce intraperitoneal fatty tissue, with suboptimal opacification of the terminal ileum, retrocecal appendix or an appendix located by the adnexa [32]. In such patients it is recommended, apart from a transversal CT scan, to use a coronal or curved scan, which may ease diagnosis, and exclude acute appendicitis. Also, coverage from the diaphragmatic crus to the pubis, but not focused on the pelvis alone, is recommended in adults with suspected appendicitis. It should certainly be pointed out that even with this imaging method, the experience of the radiologist can affect the precision of the interpretation. It may be said that only patients with unclear clinical signs and symptoms should be subjected to pre-operative US and CT, but that this should be a routine imaging method for all patients who have appendicitis.

MRI increases diagnostic precision and improves the clinical outcome [33-35], without any risk of radiation or from contrast media. It may effectively document the various phases of appendicitis. It greatly improves preoperative diagnosis, especially in cases when the typical clinical manifestations are lacking. It may ease differential diagnosis between simple appendicitis and appendiceal abscess. It has

91.7% sensitivity and 100% specificity [36]. It should be preferred in pregnant women.

The endoscopy method

In unclear cases, with persistent pain and normal levels of inflammatory markers, in rare cases ileocolonoscopy may be indicated as an alternative method [37]. It shows interluminal bulging and mucous erythema on the appendicular lumen. A biopsy may be taken.

Scores for appendicitis

In order to facilitate clinical diagnosis of acute appendicitis, various scores have been introduced, such as the Alvarado score, Eskelin and Fenyo, The Van Way, Teicher and Arnbjorson score. Common to all these scores is that they use symptoms, (the duration of pain, migration of pain, nausea, vomiting), signs (sensitivity, fever) and findings (leukocytes, CRP) [38]. However, the Alvarado score goes beyond these scores.

The Alvarado score has medium to high sensitivity (82-87%) and 81% specificity. Systematic reviews support the use of the Alvarado score as a triage tool, which may be used to exclude appendicitis, where the score is below 5 points (sensitivity 94-99%), but not to "include" acute appendicitis. The Alvarado score may be a valuable diagnostic aid when it is suspected that there is some other cause of acute abdomen imitating acute appendicitis, especially in low-resource countries, where the use of imaging techniques is not possible [39].

Treatment

For more than 100 years McBurney's appendectomy was the gold standard in the treatment of acute appendicitis, and right up until the recent development of laparoscopic surgery, little in the diagnosis and treatment of appendicitis has changed since then.

Laparoscopic appendectomy for a non-inflamed appendix was reported in 1983 by the gynae-cologist Semm [40] and then in 1987 Schreiber reported a laparoscopic assisted appendectomy for the treatment of acute appendicitis [41]. Since then many reports have been published indicating that laparoscopic appendectomy is a safe and feasible procedure [40-44].

Although laparoscopic appendectomy was performed several years before laparoscopic chole-cystectomy, it has only recently become a common laparoscopic procedure. One of the reasons is that classic appendectomy through McBurney's incision is a simple, quick and efficient procedure, which can be performed by most surgeons. Laparoscopic appendectomy, on the other hand, needs some level of knowledge of laparoscopic surgery and more expensive equipment. Possible advantages, such as fewer infections of wounds, shorter hospital stay, faster recovery and return to everyday activities, are most often accompanied by a longer operative procedure (which is shorter as the number of appendectomies performed rises) and higher costs.

The results of many randomized studies show that laparoscopic appendectomy is a safe and effective method for treatment of appendicitis [44]. It may be performed safely in patients with perforated appendicitis. This approach may be preferred method in obese patients, fertile women, and elderly patients [4,45]. Many international associations have included the results of this study in their guidelines [45] (Table 1).

	Level of Evidence
The indications for appendectomy are identical whether performed laparoscopically or open.	Level III, Grade A
Laparoscopic appendectomy is a safe and effective method for treatment of uncomplicated appendicitis and may be used as an alternative to standard open appendectomy.	Level I, grade A
Laparoscopic appendectomy may be performed safely in patients with perforated appendicitis.	Level II, grade B
Laparoscopic appendectomy is possibly the preferred approach	Level III, Grade C
Laparoscopic approach for fertile women with presumed appendicitis should be the preferred method of treatment.	Level I, grade A
Laparoscopic approach may be the preferred method of treatment in elderly patients.	Level II, grade B
Laparoscopic appendectomy may be performed safely in pregnant patients with suspicion of appendicitis	Level II, grade B
Laparoscopic appendectomy is safe and effective in obese patients.	Level II, grade B
Laparoscopic appendectomy may be the preferred approach in obese patients.	Level III, Grade C
If no other pathology is identified, the decision to remove the appendix should be considered but based on the individual clinical scenario.	Level III, Grade A
Developing a consistent operative method decreases costs, OR time, and complications.	level II, Grade B

Table 1: SAGES guidelines.

Indications for laparoscopic appendectomy are:

1. Clinical signs of acute appendicitis.
2. Laparoscopic removal of a normal appendix is indicated if the indication for laparoscopic procedure was pain in the right lower quadrant, and no other cause is found of acute abdomen.
3. If another cause of acute abdomen is found (e.g. extra-uterine pregnancy, bleeding from the ovaries) an unchanged appendix should not be removed.

Technique of laparoscopic appendectomy

Laparoscopic appendectomy traditionally requires three laparoscopic ports (Figure 1). In all approaches, a 10 or 12 mm umbilical port is used, whilst the positions of the other ports vary. Some authors place a 5 mm trocar in the upper right quadrant and a 12 mm trocar in the lower left quadrant (Figure 2). However, a sub-pubic trocar position, where a 5 mm trocar is placed in the lower right quadrant (Technique 1) seems the best, with the best cosmetic effect, and especially easier manipulation of the retrocecal positioned appendix. When the trocar is in this position, it is easy to make an incision along the Toldt line and mobilize the cecum, whilst when the trocar is in different position; this is very difficult (Technique 2).

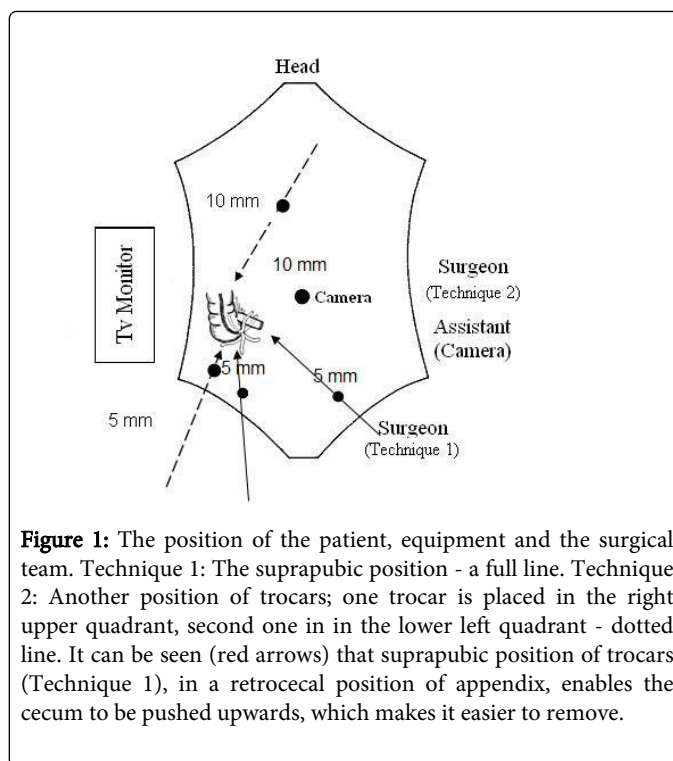


Figure 1: The position of the patient, equipment and the surgical team. Technique 1: The suprapubic position - a full line. Technique 2: Another position of trocars; one trocar is placed in the right upper quadrant, second one in in the lower left quadrant - dotted line. It can be seen (red arrows) that suprapubic position of trocars (Technique 1), in a retrocecal position of appendix, enables the cecum to be pushed upwards, which makes it easier to remove.

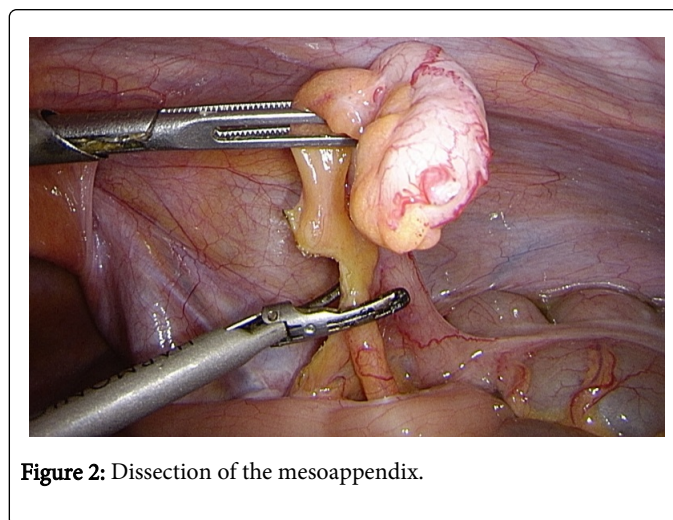


Figure 2: Dissection of the mesoappendix.

The position of the patient, equipment and the surgical team

The patient is on the operation table, on his back, in the Trendelenburg position (with his head down) sloping at 10° to 15°, towards the operator. The operator and the assistant stand to the left of the patient, and the monitor is on the right of the patient. Some surgeons operate with the operator between the patient's legs, and the assistant on the patient's left. The monitor is set up to the right of the patient.

The operation is performed under general anaesthetic. The bladder is emptied using a Foley catheter, which is removed immediately, or the patient urinates immediately prior to the procedure. After making the umbilical incision, a pneumoperitoneum is created with a Veress needle, or a 10 mm trocar is introduced by open technique and then the camera.

Under direct control, another 12 mm trocar is placed along the medial line, above the symphysis, (if a linear stapler is being introduced, or a 10 mm or 5 mm trocar if clips or ultrasound stapler are being used) and a 5 mm one in the lower right quadrant, taking care of the epigastric blood vessels, in order to obtain triangulation.

The end of the appendix is seized by the grasper for the mesoappendix placed through the right lower abdominal 5 mm port. The mesoappendix is skeletonized from the top to the base using a harmonic scalpel (Figure 3) an electrocauter, clips, loop ligature or linear intestinal stapler, introduced through the supra-pubic trocar. After that, an endoloop is introduced through the same trocar, three endoloops are passed over the tip of the appendix whereby the base is secured. The appendix is resected, leaving two ligatures on the base, and the mucous is cauterized. The appendix may also be resected using a linear stapler, a plastic non-resorptive clip or a titanium clip. The appendix is removed by introducing an endobag through a 12 mm supra-pubic trocar.

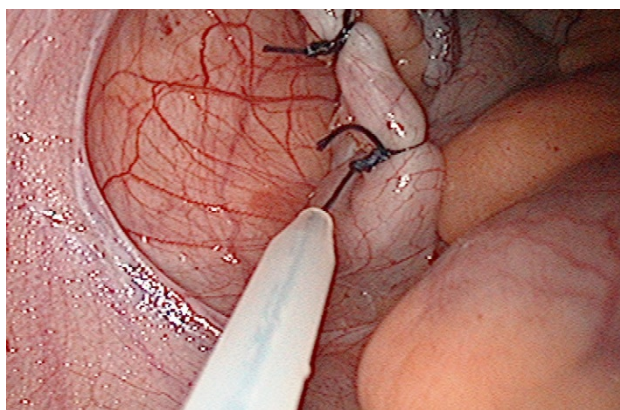


Figure 3: Securing the base of the appendix with an endoloop.

In complicated forms of appendicitis, very often the dissection of the mesoappendix is very difficult and may cause complications. Then the "base first" technique is the only solution, and after taking care of the base of the appendix, the mesoappendix is dealt with gradually.

The usual technique of securing the base of the appendix is a single endoloop ligature, if the base of the appendix is healthy (Figure 4). A stapler provides reliable closure of all forms of acute appendix (Figure 5) and clinical evidence favors the routine use of endoscopic staplers. Non-resorptive polymer plastic clips are an alternative technique by which the base of the appendix may be secure with more quickly and cheaply than using standard techniques [46] (Figure 6).

The differences between the level of inflammation and foreign body reaction to different materials used in laparoscopic appendectomy favour the use of a stapler and plastic clips [47]. Also, the creation of adhesion in the area of the base of the appendix is lowest when a stapler is used [48]. It may be said that these characteristics of the stapler may be an advantage in taking care of the base of the appendix during laparoscopic appendectomy.

DS titanium clips (Braun, Germany) retain the advantages of the use of titanium [49], are much cheaper than endoscopic staplers, and may have an advantage in relation to other methods (Figure 7).

But the problem of clips is that both plastic and titanium clips are produced in a single size, and sometimes, although rarely, they are not able to encompass the entire circumference of the base of the appendix, and it is necessary to apply an additional clip.

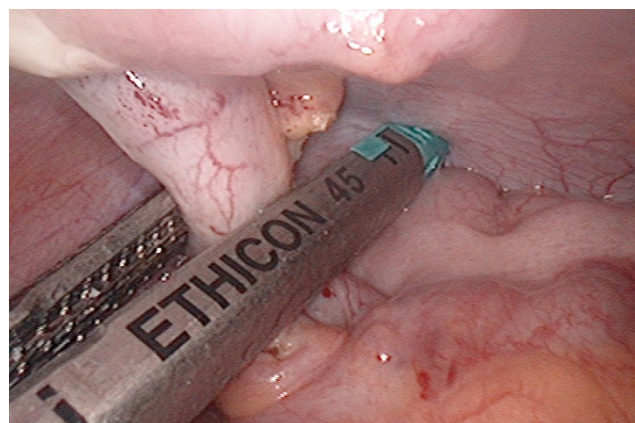

Figure 4: Securing the base of the appendix using a stapler.

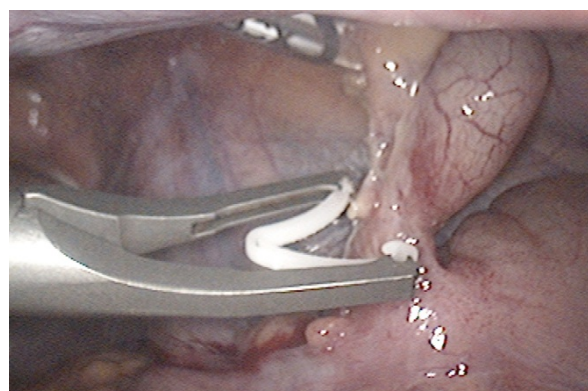


Figure 5: Securing the base of the appendix with a Hem-o-lok XL clip.

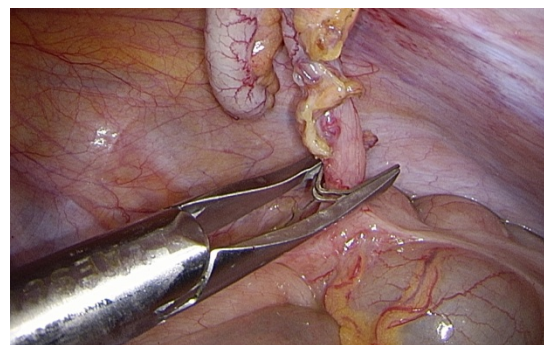
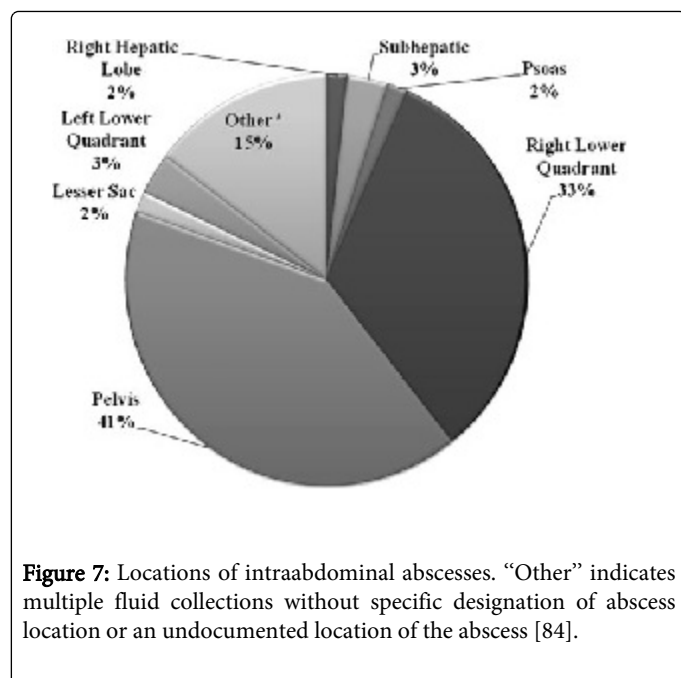


Figure 6: Securing the base of appendix with DS titanium clip.



Alternative techniques

Alongside the classical laparoscopic appendectomy described above using three trocars, various alternative techniques have been described whose aim is to increase the benefit of the classical technique, reduce post-operative pain and have an even better cosmetic result.

Needlescopic laparoscopic appendectomy

Needlescopic instruments are defined as those of 3 mm or less in diameter, which create an even smaller trocar wound and thereby less tissue trauma [50]. The longer duration of the surgery and the larger conversion rate to open appendectomy should be emphasized at the beginning, but following the learning curve these parameters improve. It may be said that this is a feasible procedure but only in experienced hands and in selected patients, especially young girls. It is less invasive and cosmetically superior to classical appendectomy [51].

Two-port laparoscopic appendectomy

This technique includes a 12 mm infra-umbilical port and one 5 mm port in the lower left quadrant. It may be said that this technique is a transition to single port laparoscopic appendectomy [52].

Appendectomy with a single, transumbilical trocar

This is the method where the appendix, after laparoscopic dissection, is exteriorized and the appendectomy is performed externally, as in open appendectomy [53,54]. However, very often this procedure cannot be completed using only one trocar. This method in fact represents a transition to single access laparoscopic appendectomy.

Single Access Laparoscopic Appendectomy (SALA)

SALA further minimizes surgical trauma, and is increasingly considered as an alternative technique to the classical laparoscopic technique. There is no difference in the degree of wound infection, the

time of regulated diet, the length of hospitalization and the time of return to work between laparoscopic appendectomy and SALA [55]. But there is longer operation time, a larger dose of narcotics and hospital costs with SALA are higher. It is said that this method gives better cosmetic results than laparoscopic appendectomy. However, there is a higher degree of re-interventions in cases of complicated appendicitis treated by SALA [56].

It may be said therefore, that SALA does not have any advantages over conventional laparoscopic appendectomy, since the cosmetic effect is minimal, and triangulation is lacking, which is key, especially in severe forms of appendicitis. Alongside the reduced field of vision and compromised motor function, this makes extraction of severe forms of appendicitis impossible.

Transgastric appendectomy

With the development of the concept of natural orifice transluminal endoscopic surgery (NOTES) surgery, an increasing number of reports are appearing on transgastric appendectomy [57]. However, this method of appendectomy is extremely difficult in cases of generalized peritonitis, with accompanying severe inflammation, and the existence of adhesion.

Adjuvant antibiotic therapy

Antibiotic prophylaxis is considered routine in emergency appendectomies. The most common bacteria which cause acute appendicitis are intestinal bacteria, including *Escherichia coli* and bacteria belong to the *Bacteroides fragilis* group [58,59].

For uncomplicated appendicitis, the recommended regimen is a single dose of a cephalosporin with anaerobic activity (cefoxitin or cefotetan) or a single dose of a first-generation cephalosporin (cefazolin) plus metronidazole [60].

Complicated appendicitis includes perforated or gangrenous appendicitis, including peritonitis or abscess formation. Because complicated appendicitis is treated as a complicated intraabdominal infection and antimicrobial therapy of should be limited to 4-7 days, unless it is difficult to achieve adequate source control [61].

Conservative antibiotic treatment of acute appendicitis

Despite the fact that appendectomy is the standard treatment of acute appendicitis, several authors have studied conservative antibiotic treatment of acute appendicitis [62]. They suggest that antibiotics may be used as primary treatment for selected patients with suspected uncomplicated appendicitis [6,63,64]. However, due to the small number of patients included and the lack of the characteristics of the patients, it is very difficult to analyse these studies. The advantage of surgical treatment in comparison to antibiotic treatment is the opportunity to establish a histological diagnosis of the removed appendix.

Better quality randomized studies are needed on the effectiveness of antibiotic therapy, compared with appendectomy. However, conducting such studies with high quality methodology remains very difficult [62].

Complications of Appendicitis

Retrocecal appendix

If the appendix is in the retrocecal position, the signs and symptoms of appendicitis may be atypical and imitate other ailments. US is often insufficient for diagnosis, but CT is a quick and effective way of localizing the appendix.

If the appendix is not identified during the initial exploration, the cecum is mobilized by electrocautery or a harmonic scalpel along the Told line. Atraumatic bowel graspers are used for retraction of the cecum - reflecting the cecal pole up and to the left will expose the appendix. However, in this location, however, the appendix, especially the tip, may be covered by adhesions, making the operation difficult [63]. In that case, retrograde dissection should be performed. The trocar placement is the same as for the usual antegrade resection. Once the cecum and the base of the appendix have been identified, the appendix can be resected between the ligatures or by stapler.

In cases of retrocecal appendix, in literature “fingerscopy” is described, which is a laparoscopic assisted procedure, where mobilization of the appendix is performed with a finger [64-66], after which laparoscopic appendectomy is performed. However, this form of mobilization is indicated extremely rarely.

Gangrenous appendix

When the appendix is gangrenous, the anatomy is often obscure. In the area of the cecum or in the pelvis an exudate is found. The appendix is identified with careful blunt dissection, and removed in the usual manner.

Perforated appendix

Perforated appendicitis occurs in 20-30% of patients with acute appendicitis [22]. This condition is associated with a significant risk of postoperative complications. But, laparoscopic approach results in significantly fewer incisional SS and similar organ/space infection rates compared to open approach [67]. If the perforation is close to the base of the appendix, securing with endoloop, or stapling of the stump may be impossible. The cecum should be mobilized adequately and the appendix removed by applying the stapler across the base appendix. Sometimes, the suturing of the base of appendix is only way for the closure the base of appendix.

Periappendicular abscess

If a periappendicular abscess is suspected, the Trendelenburg position is avoided to prevent contamination of the upper abdomen [65]. The abscess is identified by bluntly dissecting the adherent bowel loops away. The abscess cavity is aspirated, dried and irrigated. Then the appendectomy is performed as described above. A drain should be placed in the abscess cavity.

Thoracic empyema

It is very rare complication of perforated appendicitis, only few cases have been previously reported [68,69]. Empyema could be explained by bacterial translocation of bacteria from peritoneal cavity. Although, quite rare, it is need to know this possible clinical entity.

Conversion to open procedure

The only absolute contraindication for laparoscopic appendectomy is the inability to safely obtain a pneumoperitoneum under general anesthesia [65]. Insufficient experience with laparoscopic appendectomy or advanced and complicated appendicitis may be indications for conversion to an open procedure.

However, with increased experience, most appendicular conditions can be managed laparoscopically. Moreover, most skilled laparoscopic surgeons find that complicated appendicitis can often be better managed through the laparoscope than through a McBurney incision [65]. The view is better, abscesses are more easily identified and treated, and the entire abdomen may be explored and lavaged.

Nevertheless, a prudent surgeon will occasionally have to convert a laparoscopic appendectomy into an open procedure for various reasons that include the inability to gain exposure, fear of intestinal injury, inability to recognize the base of the appendix, extensive adhesions and uncontrolled bleeding.

Complications of laparoscopic appendectomy

Most reports of laparoscopic appendectomy indicate a low incidence of intraoperative and postoperative complications [70-77].

Bleeding

Bleeding is usually overestimated during laparoscopic procedures, because of the magnification of the camera [65], but most conversions to open procedure occur for this complication [42].

The major source of bleeding is placement of trocars through the central rectus muscle and laceration of inferior epigastric artery. The inferior epigastric artery can be avoided by placing trocars either medially or laterally through rectus muscle.

Aggressive dissection of the mesoappendix may lead to bleeding, and it can be from the retroperitoneum, during dissection of an inflamed, retrocecal appendix. Careful dissection with control of the mesoappendix can prevent this complication.

Bleeding is not difficult to recognize. Suction, pressure of the site of bleeding with an instrument or gauze and an additional trocar facilitate identification and control of the site of bleeding. Haemostasis may be achieved by coagulation, clips, or by an endoloop. In very rare situations conversion to open procedure is needed.

Fecalith

This is a rare, but frustrating complication [78]. During dissection of a distended, gangrenous appendix, a fecalith may drop into the peritoneal cavity. Retained fecaliths may cause an intrabdominal abscess. Therefore fecaliths need to be dealt with carefully and cautiously to avoid them being lost between the loops of the intestine and the pelvis. Fecaliths should be thrown into an endobag and careful lavage performed.

This complication will be found more often as laparoscopic appendectomy becomes a more common method in the treatment of acute appendicitis [79]. Surgeons should be aware of this complication in order to treat fecalith adequately when recognized intra or postoperatively.

Gentle treatment of an inflamed, gangrenous appendix and the use of an endobag prevent this complication. Since in all described cases of

a dropped fecalith after open appendectomy, an abscess develops, it is recommended to remove the fecalith when it is established that one has dropped intraoperatively. If the presence of a fecalith is confirmed postoperatively, its removal by relaparoscopy is possible [78]. A retained fecalith which is manifested as an intra-abdominal abscess is treated like any other abscess [79].

Stump appendicitis

Stump appendicitis is delayed obstruction and inflammation of residual tissue left after an incomplete appendectomy [80]. This is a serious but very rare complication. However, incomplete appendectomy may lead to recurrent appendicitis. Some reports suggest an increased incidence of incomplete appendectomy with laparoscopy, but most published cases appear after open appendectomy.

This complication arises when the appendix is cut a long way from the base. Poor identification of the join between the appendix and the cecum appears to play an important role. Following the taenia coli from the cecum to the appendix helps to identify the base. Alternatively, dissection and ligation of recurrent branches of the appendicular artery help to mark the base of the appendix [81]. It is therefore necessary to treat the join of the base of the appendix with the cecum carefully. As laparoscopic surgery does not have the three dimensional perspective and tactile feedback, it can be sometimes possible cause of longer stump left [82].

Accepted treatment of acute appendicitis is appendectomy, during this procedure the stump must be left shorter than 5 mm. If the stump is longer than 5 mm, it may serve as a reservoir for the fecalith and cause this complication [83].

It is necessary to take this rare complication into account, if a patient who has undergone appendectomy again has symptoms and signs of acute appendicitis.

Postoperative abscesses

Postoperative abscesses are uncommon with laparoscopic appendectomy [71]. With improvement of camera quality, better lavage and cleaning of the operative field, this complication is rarely seen, and recent reports have noted a significant decrease in abscesses after laparoscopic appendectomy [84]. There are reports of subhepatic and subphrenic abscesses, possibly due to the spread of infected fluid while the patient is in the Trendelenburg position, but this is an unproven theory. Abscesses are treated by ultrasound guided puncture and drainage, with antibiotic therapy.

Stump dehiscence

Stump dehiscence is a very rare complication. It may be related to excessive coagulation of the stump and the consequent necrosis [65], an inadequately placed endoloop. It is manifested by a stercoral fistula.

Post-operative wound infection

Infection of a surgical wound is rarer than in open appendectomy, even in cases of gangrenous appendicitis. The reduction in the level of wound infection has probably been achieved due to the extraction of the appendix without direct contact with the wound [85,86], through the port or in a plastic bag (endobag).

Laparoscopic appendectomy in women of childbearing age

The incidence of misdiagnosis is between 26% and 45% in premenopausal women [87,88]. Therefore early laparoscopy potentially leads to more accurate diagnosis and reduces the risk of complications related to postponing diagnosis [89]. Other benefits (the improvement of the quality of life, pain reduction, reduction in the length of hospitalization, and the particular cosmetic effect) are present as in other patients after laparoscopic appendectomy.

Laparoscopic appendectomy in pregnant women

Pregnancy is not an absolute contra-indication [90], but the increased size of the uterus reduces the working space and makes laparoscopic appendectomy more difficult. Laparoscopic appendectomy in pregnancy may be performed in any trimester [91-94], but appendicitis occurs more frequently in the second trimester [95-99]. Pre-operative, maternal end-tidal CO₂ concentrations and arterial blood gases must be monitored in order to control maternal hyper-ventilation and prevent fetal acidosis [90].

Laparoscopic appendectomy in children

The range of acute illnesses in children is completely different than in adults, but older children and adolescents are suitable candidates for laparoscopic appendectomy which has all the benefits it has in adults, shorter hospitalization, lower levels of wound infection, quicker return to normal activities, better cosmetic effect, and better visualization of the peritoneal space [100]. Laparoscopic appendectomy usually involves the 3 trocar technique described above, in that in children hybrid and single-port techniques are popular, with or without exteriorization of the appendix through the umbilical port [100-103]. The umbilical region is less innervated than other areas of the abdomen [104] so there is less post-operative pain, and in children, the distance between the cecum and the umbilicus is shorter, and the abdomen is more flexible [105].

Transumbilical laparoscopic assisted appendectomy (TULAA) is often used [106], which is a combination of open and laparoscopic techniques, where the appendix is pulled through a 5 mm cannula in the lower right quadrant, and the base is dealt with extra-corporeally. The technique is cost-effective and gives excellent cosmetic results, and if there are any technical problems, it may easily be transformed into standard three-port laparoscopic appendectomy.

This technique is impossible in older children due to the greater distance of the base of the appendix from the umbilicus.

Laparoscopic appendectomy in obese persons

Laparoscopic appendectomy is also a safe and effective method in obese persons. It has the advantage over the open approach due to the improved visualization, the reduced complications relating to the wound, but it should be pointed out that longer trocars and instruments are needed [107].

Conclusion

Acute appendicitis is one of the most common causes of acute abdomen. Although the diagnosis is based on a careful history and physical examination, in patients who have atypical clinical and laboratory findings, US, CT, MRI, a scoring system and laparoscopy can be used. Laparoscopic appendectomy is a safe and effective

method for the treatment of appendicitis. The causes of unsuccessful procedures vary - most often the position of the appendix, adhesion, adiposity, bleeding and abscess are mentioned [108]. Most of these reasons lead to conversion due to the lack of experience of the operator. Two situations make laparoscopic appendectomy especially difficult: the retrocecal position and the presence of an abscess. Even in these cases, laparoscopy facilitates open access, indicating the exact location of the incision [109].

In cases of generalized peritonitis, the laparoscopic method makes the complete cleansing of the abdominal space possible, with less traumatized tissue and less irritation of the bowels. There is less post-operative pain and a shorter hospital stay, and quicker recovery and return to normal activities, which is especially important in patients who are going back to work. The economic importance and implications which favor this approach should also not be overlooked [110].

All in all, the effects of laparoscopic appendectomy are astounding, but it must be borne in mind that the laparoscopy surgeons included in published studies are experts in laparoscopy. Therefore, surgical experience in laparoscopic techniques is a precondition for surgeons to expect clinical benefit from laparoscopic appendectomy.

In clinical conditions, where surgical experience is present, and the necessary equipment, the use of laparoscopy and laparoscopic appendectomy may be recommended in all patients with suspected appendicitis, if laparoscopy itself is not contra-indicated or is not feasible.

References

- Williams NM, Jackson D, Everson NW, Johnstone JM (1998) Is the incidence of acute appendicitis really falling? *Ann R Coll Surg Engl* 80: 122-124.
- Addiss DG, Shaffer N, Fowler BS, Tauxe RV (1990) The epidemiology of appendicitis and appendectomy in the United States. *Am J Epidemiol* 132: 910-925.
- Hale DA, Molloy M, Pearl RH, Schutt DC, Jaques DP (1997) Appendectomy: a contemporary appraisal. *Ann Surg* 225: 252-261.
- Ditillo MF, Dziura JD, Rabinovici R (2006) Is it safe to delay appendectomy in adults with acute appendicitis? *Ann Surg* 244: 656-660.
- Sisson RG, Ahlvin RC, Harlow MC (1971) Superficial mucosal ulceration and the pathogenesis of acute appendicitis. *Am J Surg* 122: 378-380.
- Carr NJ1 (2000) The pathology of acute appendicitis. *Ann Diagn Pathol* 4: 46-58.
- Walker AR, Segal I (1990) What causes appendicitis? *J Clin Gastroenterol* 12: 127-129.
- Burkitt DP (1971) The aetiology of appendicitis. *Br J Surg* 58: 695-699.
- Sivit CJ, Newman KD, Boenning DA, Nussbaum-Blask AR, Bulas DI, et al. (1992) Appendicitis: usefulness of US in diagnosis in a pediatric population. *Radiology* 185: 549-552.
- Wen SW, Naylor CD (1995) Diagnostic accuracy and short-term surgical outcomes in cases of suspected acute appendicitis. *CMAJ* 152: 1617-1626.
- Kaya B, Sana B, Eris C, Karabulut K, Bat O, et al. (2012) The diagnostic value of D-dimer, procalcitonin and CRP in acute appendicitis. *Int J Med Sci* 9: 909-915.
- Andersson RE (2004) Meta-analysis of the clinical and laboratory diagnosis of appendicitis. *Br J Surg* 91: 28-37.
- Humes DJ, Simpson J (2006) Acute appendicitis. *BMJ* 333: 530-534.
- Kamran H, Naveed D, Nazir A, Hameed M, Ahmed M, et al. (2008) Role of total leukocyte count in diagnosis of acute appendicitis. *J Ayub Med Coll Abbottabad* 20: 70-71.
- Paulson EK, Kalady MF, Pappas TN (2003) Clinical practice. Suspected appendicitis. *N Engl J Med* 348: 236-242.
- Sengupta A, Bax G, Paterson-Brown S (2009) White cell count and C-reactive protein measurement in patients with possible appendicitis. *Ann R Coll Surg Engl* 91: 113-115.
- al-Saigh AH (1992) C-reactive protein in the differential diagnosis of the acute abdomen, especially acute appendicitis. *J R Coll Surg Edinb* 37: 238-240.
- Gurleyik E, Gurleyik G, UnalmiÅYer S (1995) Accuracy of serum C-reactive protein measurements in diagnosis of acute appendicitis compared with surgeon's clinical impression. *Dis Colon Rectum* 38: 1270-1274.
- Yang HR, Wang YC, Chung PK, Chen WK, Jeng LB, et al. (2005) Role of leukocyte count, neutrophil percentage, and C-reactive protein in the diagnosis of acute appendicitis in the elderly. *Am Surg* 71: 344-347.
- Burcharth J, Pommergaard HC, Rosenberg J, Gögenur I (2013) Hyperbilirubinemia as a predictor for appendiceal perforation: a systematic review. *Scand J Surg* 102: 55-60.
- Berry J Jr, Malt RA (1984) Appendicitis near its centenary. *Ann Surg* 200: 567-575.
- Andersson RE, Hugander A, Thulin AJ (1992) Diagnostic accuracy and perforation rate in appendicitis: association with age and sex of the patient and with appendectomy rate. *Eur J Surg* 158: 37-41.
- Körner H, Söndena K, Söreide JA, Andersen E, Nysted A, et al. (1997) Incidence of acute nonperforated and perforated appendicitis: age-specific and sex-specific analysis. *World J Surg* 21: 313-317.
- Hale DA, Molloy M, Pearl RH, Schutt DC, Jaques DP (1997) Appendectomy: a contemporary appraisal. *Ann Surg* 225: 252-261.
- Temple CL, Huchcroft SA, Temple WJ (1995) The natural history of appendicitis in adults. A prospective study. *Ann Surg* 221: 278-281.
- Birnbaum BA, Jeffrey RB Jr (1998) CT and sonographic evaluation of acute right lower quadrant abdominal pain. *AJR Am J Roentgenol* 170: 361-371.
- Jeffrey RB Jr, Laing FC, Townsend RR (1988) Acute appendicitis: sonographic criteria based on 250 cases. *Radiology* 167: 327-329.
- Rioux M1 (1992) Sonographic detection of the normal and abnormal appendix. *AJR Am J Roentgenol* 158: 773-778.
- Lane MJ, Liu DM, Huynh MD, Jeffrey RB Jr, Mindelzun RE, et al. (1999) Suspected acute appendicitis: nonenhanced helical CT in 300 consecutive patients. *Radiology* 213: 341-346.
- Ege G, Akman H, Sahin A, Bugra D, Kuzucu K (2002) Diagnostic value of unenhanced helical CT in adult patients with suspected acute appendicitis. *Br J Radiol* 75: 721-725.
- Hlibczuk V, Dattaro JA, Jin Z, Falzon L, Brown MD (2010) Diagnostic accuracy of noncontrast computed tomography for appendicitis in adults: a systematic review. *Ann Emerg Med* 55: 51-59.
- Paulson EK, Harris JP, Jaffe TA, Haugan PA, Nelson RC (2005) Acute appendicitis: added diagnostic value of coronal reformations from isotropic voxels at multi-detector row CT. *Radiology* 235: 879-885.
- Wan MJ, Krahn M, Ungar WJ, Caku E, Sung L, et al. (2009) Acute appendicitis in young children: cost-effectiveness of US versus CT in diagnosis--a Markov decision analytic model. *Radiology* 250: 378-386.
- Watters JM1 (2008) The appendicitis inflammatory response score: a tool for the diagnosis of appendicitis that outperforms the Alvarado score. *World J Surg* 32: 1850.
- Cengiz M, Yildiz F, Selekt U, Ozyigit G (2007) Comment on "computed tomography versus magnetic resonance imaging-based contouring in cervical cancer brachytherapy: results of a prospective trial and preliminary guidelines for standardized contours" by Viswanathan et al. (2007) (*Int j radiat oncol biol phys* 68: 491-498). *Int J Radiat Oncol Biol Phys* 69: 963; author reply 963-964.
- Zhu B, Zhang B, Li M, Xi S, Yu D, et al. (2012) An evaluation of a superfast MRI sequence in the diagnosis of suspected acute appendicitis. *Quant Imaging Med Surg* 2: 280-287.

37. Tursi A (2013) Endoscopic diagnosis of appendicitis. *Intern Med* 52: 1141.
38. Ohle R, O'Reilly F, O'Brien KK, Fahey T, Dimitrov BD (2011) The Alvarado score for predicting acute appendicitis: a systematic review. *BMC Med* 9: 139.
39. Tade AO (2007) Evaluation of Alvarado score as an admission criterion in patients with suspected diagnosis of acute appendicitis. *West Afr J Med* 26: 210-212.
40. Semm K (1983) Endoscopic appendectomy. *Endoscopy* 15: 59-64.
41. Schreiber JH1 (1987) Early experience with laparoscopic appendectomy in women. *Surg Endosc* 1: 211-216.
42. Pier A, Götz F, Bacher C (1991) Laparoscopic appendectomy in 625 cases: from innovation to routine. *Surg Laparosc Endosc* 1: 8-13.
43. Ludwig KA, Cattet RP, Henry LG (1993) Initial experience with laparoscopic appendectomy. *Dis Colon Rectum* 36: 463-467.
44. Sauerland S, Jaschinski T, Neugebauer EA (2010) Laparoscopic versus open surgery for suspected appendicitis (review). *The Cochrane collaboration*. John Wiley & Sons 10: 1-139.
45. Korndorffer JR Jr, Fellinger E, Reed W (2010) SAGES guideline for laparoscopic appendectomy. *Surg Endosc* 24: 757-761.
46. Delibegovic S, Matovič E (2009) Hem-o-lok plastic clips in securing of the base of the appendix during laparoscopic appendectomy. *Surg Endosc* 23: 2851-2854.
47. Delibegovic S, Iljazovi E, Katica M, Koluh A (2011) Tissue reaction to absorbable endoloop, nonabsorbable titanium staples, and polymer Hem-o-lok clip after laparoscopic appendectomy. *JLS* 15: 70-76.
48. Delibegovic S, Katica M, Latič J, Jakič-Razumovič J, Koluh A, et al. (2013) Biocompatibility and adhesion formation of different endoloop ligatures in securing the base of the appendix. *JLS* 17: 543-548.
49. Rickert A, Bönninghoff R, Post S, Walz M, Runkel N, et al. (2012) Appendix stump closure with titanium clips in laparoscopic appendectomy. *Langenbecks Arch Surg* 397: 327-331.
50. Gagner M, Garcia-Ruiz A (1998) Technical aspects of minimally invasive abdominal surgery performed with needlescopic instruments. *Surg Laparosc Endosc* 8: 171-179.
51. Schier F (1998) Laparoscopic appendectomy with 1.7-mm instruments. *Pediatr Surg Int* 14: 142-143.
52. Panait L, Bell RL, Duffy AJ, Roberts KE (2009) Two-port laparoscopic appendectomy: minimizing the minimally invasive approach. *J Surg Res* 153: 167-171.
53. Rispoli G, Armellino MF, Esposito C (2002) One-trocar appendectomy. *Surg Endosc* 16: 833-835.
54. Deie K, Uchida H, Kawashima H, Tanaka Y, Masuko T, et al. (2013) Single-incision laparoscopic-assisted appendectomy in children: exteriorization of the appendix is a key component of a simple and cost-effective surgical technique. *Pediatr Surg Int* 29: 1187-1191.
55. St Peter SD, Adibe OO, Juang D, Sharp SW, Garey CL, et al. (2011) Single incision versus standard 3-port laparoscopic appendectomy: a prospective randomized trial. *Ann Surg* 254: 586-590.
56. Teoh AY, Chiu PW, Wong TC, Wong SK, Lai PB, et al. (2011) A case-controlled comparison of single-site access versus conventional three-port laparoscopic appendectomy. *Surg Endosc* 25: 1415-1419.
57. Kaehler G, Schoenberg MB, Kienle P, Post S, Magdeburg R (2013) Transgastric appendectomy. *Br J Surg* 100: 911-915.
58. Rautio M, Saxén H, Siitonen A, Nikku R, Jousimies-Somer H (2000) Bacteriology of histopathologically defined appendicitis in children. *Pediatr Infect Dis J* 19: 1078-1083.
59. Soffer D, Zait S, Klausner J, Kluger Y (2001) Peritoneal cultures and antibiotic treatment in patients with perforated appendicitis. *Eur J Surg* 167: 214-216.
60. Bratzler DW, Dellinger EP, Olsen KM, Perl TM, Auwaerter PG, et al. (2013) Clinical practice guidelines for antimicrobial prophylaxis in surgery. *Am J Health-Syst Pharm* 70: 195-283.
61. Solomkin JS, Mazuski JE, Bradley JS, Rodvold KA, Goldstein EJC, et al. (2010) Diagnosis and Management of Complicated Intra-abdominal Infection in Adults and Children: Guidelines by the Surgical Infection Society and the Infectious Diseases Society of America. *Complicated Intra-abdominal Infection Guidelines* CID 50: 133-164.
62. Wilms IM, de Hoog DE, de Visser DC, Janzing HM (2011) Appendectomy versus antibiotic treatment for acute appendicitis. *Cochrane Database Syst Rev* : CD008359.
63. Varadhan KK, Humes DJ, Neal KR, Lobo DN (2010) Antibiotic therapy versus appendectomy for acute appendicitis: a meta-analysis. *World J Surg* 34: 199-209.
64. Andersson RE, Schein M (2012) Antibiotics as first-line therapy for acute appendicitis: evidence for a change in clinical practice. *World J Surg* 36: 2037-2038.
65. Oddsdottir M, Hunter JG (1995) Laparoscopic approach to suspected appendicitis. In: Arregui ME, Sackier JM. Eds. *Minimal access coloproctology*. Radcliffe Medical Press. Oxford and New York 103-121.
66. Katkhoua N, Mason RJ, Mavor E, Campos GM, Rivera RT, et al. (1999) Laparoscopic finger-assisted technique (fingerscopy) for treatment of complicated appendicitis. *J Am Coll Surg* 189: 131-133.
67. Galli R, Banz V, Fenner H, Metzger J (2013) Laparoscopic approach in perforated appendicitis: increased incidence of surgical site infection? *Surg Endosc* 27: 2928-2933.
68. Law DK, Murr P, Bailey WC (1978) Empyema. A rare presentation of perforated appendicitis. *JAMA* 240: 2566-2567.
69. Herline A, Burton EM, Hatley R (1994) Thoracic empyema in a patient with acute appendicitis: a rare association. *J Pediatr Surg* 29: 1623-1625.
70. McAnena OJ, Austin O, O'Connell PR, Hederman WP, Gorey TF, et al. (1992) Laparoscopic versus open appendectomy: a prospective evaluation. *Br J Surg* 79: 818-820.
71. Kum CK, Ngoi SS, Goh PM, Tekant Y, Isaac JR (1993) Randomized controlled trial comparing laparoscopic and open appendectomy. *Br J Surg* 80: 1599-1600.
72. Ortega AE, Hunter JG, Peters JH, Swanstrom LL, Schirmer B (1995) A prospective, randomized comparison of laparoscopic appendectomy with open appendectomy. *Laparoscopic Appendectomy Study Group*. *Am J Surg* 169: 208-212.
73. Hansen JB, Smithers BM, Schache D, Wall DR, Miller BJ, et al. (1996) Laparoscopic versus open appendectomy: prospective randomized trial. *World J Surg* 20: 17-20.
74. McCall JL, Sharples K, Jadallah F (1997) Systematic review of randomized controlled trials comparing laparoscopic with open appendectomy. *Br J Surg* 84: 1045-1050.
75. Moberg AC, Montgomery A (1997) Appendicitis: laparoscopic versus conventional operation: a study and review of the literature. *Surg Laparosc Endosc* 7: 459-463.
76. Fallahzadeh H1 (1998) Should a laparoscopic appendectomy be done? *Am Surg* 64: 231-233.
77. Richardson WS, Hunter JG (1997) Complications in appendectomy. In: Ponsky JL. Ed. *Complications of endoscopic and laparoscopic surgery, Prevention and management*, Philadelphia. Lippincot-Raven 171-176.
78. Smith AG, Ripepi A, Stahlfeld KR (2002) Case report. Retained fecalith. *Laparoscopic removal. Surgical Laparoscopy; Endoscopy and percutaneous techniques* 12: 441-442.
79. Strathern DW, Jones BT (1999) Retained fecalith after laparoscopic appendectomy. *Surg Endosc* 13: 287-289.
80. Liang MK, Lo HG, Marks JL (2006) Stump appendicitis: a comprehensive review of literature. *Am Surg* 72: 162-166.
81. Greene JM, Peckler D, Schumer W, Greene EI (1958) Incomplete surgical removal of the appendix; its complications. *J Int Coll Surg* 29: 141-146.
82. Walsh DC, Roediger WE (1997) Stump appendicitis--a potential problem after laparoscopic appendectomy. *Surg Laparosc Endosc* 7: 357-358.
83. Durgun AV, Baca B, Ersoy Y, Kapan M (2003) Stump appendicitis and generalized peritonitis due to incomplete appendectomy. *Tech Coloproctol* 7: 102-104.

84. Katkhouda N, Friedlander MH, Grant SW, Achanta KK, Essani R, et al. (2000) Intraabdominal abscess rate after laparoscopic appendectomy. *Am J Surg* 180: 456-459.
85. Asarias JR, Schlusell AT, Cafasso DE, Carlson TL, Kasprenski MC, et al. (2011) Incidence of postoperative intraabdominal abscesses in open versus laparoscopic appendectomies. *Surg Endosc* 25: 2678-2683.
86. Tate JJ (1996) Laparoscopic appendectomy. *Br J Surg* 83: 1169-1170.
87. Tzovaras G, Liakou P, Baloyiannis I, Spyridakis M, Mantzos F, et al. (2007) Laparoscopic appendectomy: differences between male and female patients with suspected acute appendicitis. *World J Surg* 31: 409-413.
88. Borgstein PJ, Gordijn RV, Eijsbouts QA, Cuesta MA (1997) Acute appendicitis--a clear-cut case in men, a guessing game in young women. A prospective study on the role of laparoscopy. *Surg Endosc* 11: 923-927.
89. Golash V, Willson PD (2005) Early laparoscopy as a routine procedure in the management of acute abdominal pain: a review of 320 patients. *Surg Endosc* 19: 882-885.
90. Neudecker J, Sauerland S, Neugebauer EAM, Bergamaschi R, Bonjer HJ, et al. (2006) The EAES clinical practice guidelines on the pneumoperitoneum for laparoscopic surgery (2002). In: EAES guidelines for endoscopic surgery. Eds. Neugebauer EAM, Sauerland S, Fingerhut A, Millat B, Buess G. Springer 39-85.
91. Affleck DG, Handrahan DL, Egger MJ, Price RR (1999) The laparoscopic management of appendicitis and cholelithiasis during pregnancy. *Am J Surg* 178: 523-529.
92. Barnes SL, Shane MD, Schoemann MB, Bernard AC, Boulanger BR (2004) Laparoscopic appendectomy after 30 weeks pregnancy: report of two cases and description of technique. *Am Surg* 70: 733-736.
93. Suttie SA, Seth S, Driver CP, Mahomed AA (2004) Outcome after intra- and extra-corporeal laparoscopic appendectomy techniques. *Surg Endosc* 18: 1123-1125.
94. Carver TW, Antevil J, Egan JC, Brown CV (2005) Appendectomy during early pregnancy: what is the preferred surgical approach? *Am Surg* 71: 809-812.
95. Guttman R, Goldman RD, Koren G (2004) Appendicitis during pregnancy. *Can Fam Physician* 50: 355-357.
96. Gilo NB, Amini D, Landy HJ (2009) Appendicitis and cholecystitis in pregnancy. *Clin Obstet Gynecol* 52: 586-596.
97. Yilmaz HG, Akgun Y, Bac B, Celik Y (2007) Acute appendicitis in pregnancy--risk factors associated with principal outcomes: a case control study. *Int J Surg* 5: 192-197.
98. Ueberrueck T, Koch A, Meyer L, Hinkel M, Gastinger I (2004) Ninety-four appendectomies for suspected acute appendicitis during pregnancy. *World J Surg* 28: 508-511.
99. Rollins MD, Chan KJ, Price RR (2004) Laparoscopy for appendicitis and cholelithiasis during pregnancy: a new standard of care. *Surg Endosc* 18: 237-241.
100. Esposito C, Calvo AI, Castagnetti M, Alicchio F, Suarez C, et al. (2012) Open versus laparoscopic appendectomy in the pediatric population: a literature review and analysis of complications. *J Laparoendosc Adv Surg Tech A* 22: 834-839.
101. Esposito C (1998) One-trocar appendectomy in pediatric surgery. *Surg Endosc* 12: 177-178.
102. Visnjic S (2008) Transumbilical laparoscopically assisted appendectomy in children: high-tech low-budget surgery. *Surg Endosc* 22: 1667-1671.
103. Lee SY, Lee HM, Hsieh CS, Chuang JH (2011) Transumbilical laparoscopic appendectomy for acute appendicitis: a reliable one-port procedure. *Surg Endosc* 25: 1115-1120.
104. Rozen WM, Tran TM, Ashton MW, Barrington MJ, Ivanusic JJ, et al. (2008) Refining the course of the thoracolumbar nerves: a new understanding of the innervation of the anterior abdominal wall. *Clin Anat* 21: 325-333.
105. Ohno Y, Morimura T, Hayashi S (2012) Transumbilical laparoscopically assisted appendectomy in children: the results of a single-port, single-channel procedure. *Surg Endosc* 26: 523-527.
106. Valla J, Ordorica-Flores RM, Steyaert H, Merrot T, Bartels A, et al. (1999) Umbilical one-puncture laparoscopic-assisted appendectomy in children. *Surg Endosc* 13: 83-85.
107. Enochsson L, Hellberg A, Rudberg C, Fenyo G, Gudbjartson T, et al. (2001) Laparoscopic vs open appendectomy in overweight patients. *Surg Endosc* 15: 387-392.
108. Götz F, Pier A, Bacher C (1990) Modified laparoscopic appendectomy in surgery. A report on 388 operations. *Surg Endosc* 4: 6-9.
109. Bouillot JL, Salah S, Fernandez F, al-Hajj G, Dehni N, et al. (1995) Laparoscopic procedure for suspected appendicitis. A prospective study in 283 consecutive patients. *Surg Endosc* 9: 957-960.
110. Long KH, Bannon MP, Zietlow SP, Helgeson ER, Harmsen WS, et al. (2001) A prospective randomized comparison of laparoscopic appendectomy with open appendectomy: Clinical and economic analyses. *Surgery* 129: 390-400.