

Acanthosis Nigricans in Areas of Resolving Psoriatic Plaques after Adalimumab Therapy

Giana Paula Müller*, Laura de Mattos Milman, Ana Leticia Boff and André Vicente Esteves de Carvalho

Department of Dermatology, Santa Casa de Misericórdia de Porto Alegre, Porto Alegre, RS Brazil

*Corresponding author: Giana Paula Müller, Department of Dermatology, Santa Casa de Misericórdia de Porto Alegre, Porto Alegre, RS Brazil, Tel: 555596133680; E-mail: gipaula@hotmail.com

Received date: July 13, 2016; Accepted date: August 03, 2016; Published date: August 06, 2016

Copyright: © 2016 Müller GP, et al. This is an open-access article distributed under the terms of the Creative Commons Attribution License, which permits unrestricted use, distribution, and reproduction in any medium, provided the original author and source are credited.

Abstract

Confined hyperpigmentation over areas of resolving psoriatic plaques have been described as lentiginosis, post-inflammatory hyperpigmentation, nevus spillus and speckled pigmentation. We present a case of a 46 year-old patient who developed acanthosis nigricans (AN) and lentiginosis after resolution of psoriasis when treated with adalimumab. The concomitance of the appearance of AN and the use of adalimumab, may reveal that the drug is involved in the development and persistence of the disorder.

Keywords: Acanthosis; Psoriasis; Adalimumab; Immunobiological

Introduction

Confined hyperpigmentation over areas of resolving psoriatic plaques have been described as lentiginosis, post-inflammatory hyperpigmentation, nevus spillus and speckled pigmentation [1]. We present a case of a 46 year-old patient who developed acanthosis nigricans (AN) and lentiginosis after resolution of psoriasis when treated with adalimumab.

Case Report

White, obese, hypertensive, diabetic and dyslipidemic 46 year-old female patient. The patient has also bipolar disorder and is currently taking metformin, propranolol, omeprazole, insulin, simvastatin, topiramate, amlodipine and fluoxetine.

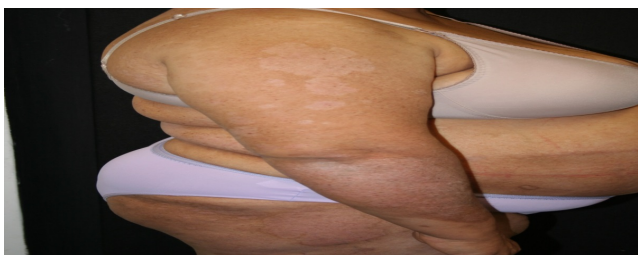

Figure 1: Brownish velvety plaques on the exterior surface of upper limbs, trunk and inferior membranes.

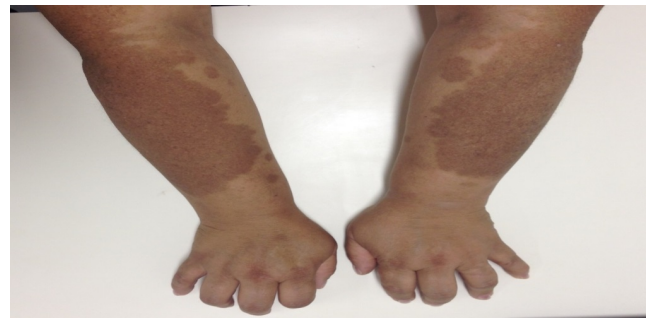

Figure 2: Brownish plaques appeared over the same areas.

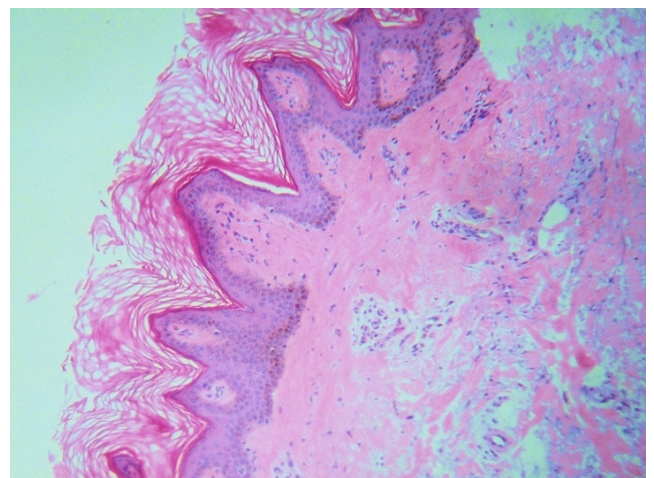


Figure 3: Biopsy and histopathological examination results.

She has a personal history of psoriasis of more than twenty years. During physical examination, extensive erythematous and

desquamative plaques were observed on the upper and lower limbs (Figure 1), torso and scalp (PASI 17,4). The patient has been previously treated with methotrexate, acitretin and cyclosporine without success. Has not been treated with phototherapy. Due to the progressive worsening of the disease, adalimumab was prescribed. Improvement of psoriasis was observed but, as the psoriatic plaques vanished, brownish plaques appeared over the same areas (Figure 2). No lesions of this kind were observed outside areas of previous psoriatic plaques. During dermatological consultation, there were brown velvety plaques, speckled with hyperchromic macules over its surface. Lesions were distributed over lower and upper limbs and trunk.

Biopsy and histopathological examination showed acanthosis, papillomatosis, hyperkeratosis and hyperpigmentation of the basal layer, which is typical of acanthosis nigricans (Figure 3).

Discussion

Acanthosis nigricans (AN) is characterized by hyperpigmented, velvety, symmetric macules and plaques, located mainly in intertriginous areas. Endocrine diseases are the main causes, being obesity the most common, usually associated with insulin resistance [2].

A process is initiated with the activation of three cell receptors, among them EGFR (epidermal growth factor receptor), that acts modulating keratinocyte proliferation, is over expressed in psoriasis and can be a link between the two diseases [3]. Moreover, this association has been reported in a 14 year-old patient that developed psoriatic lesions over areas of AN through Koebner phenomenon and it has been suggested that the abnormal keratinocyte proliferation in AN could be a promoter of epidermal micro traumas needed to incite the isomorphic response [4].

There are reports of AN after organ transplantation and subsequent immunosuppression. Pandya et al reported a case of a 51 year-old woman who underwent lung transplantation due to idiopathic pulmonary fibrosis and was in use of tacrolimus, azathioprine and oral corticosteroids. Schnakenburg et al also described a case of AN in a 12 year-old boy who had a renal transplant in use of cyclosporine and oral corticosteroid. Both cases developed AN after 3 months after transplantation, without metabolic imbalance [5,6]. There are also reports after bone marrow transplantation due to host-versus-graft disease and cases related to the antiretroviral therapy in AIDS, with complete resolution of the lesions after therapy suspension [6].

The patient reported here has insulin resistance and obesity, features known to be associated to the development of AN, but the atypical sites inflicted and the concomitance with the introduction of adalimumab, makes it probable that the drug is implicated in the development of the lesions.

Lentiginosis over psoriatic plaques after phototherapy have been reported but we did not find, until this moment, any case of AN after use of anti-factor necrosis tumoral (anti-TNF) [1,7]. Recently, cases of lentiginosis after use of anti-TNF were reported, even without previous use of phototherapy [7].

Two cases have been reported after use of etanercept and phototherapy, but the hyperpigmentation was thought to be related to the psoriatic inflammation and not to the drug. Other three cases of hyperpigmentation on resolving psoriatic lesions were reported after

adalimumab, infliximab and ustekinumab treatment, without previous phototherapy. On those cases, pigmentation was thought to be the result of ultraviolet light interaction by some authors or considered to be post inflammatory hyperpigmentation by others, what is reinforced by the fact that lentiginosis only happens on psoriatic patients and not on other inflammatory diseases treated with the same drugs [7].

Pigmentary disorders associated to inflammation are fairly common and isn't yet well established how cytokines affect the melanocytes. Interleukin 17 (IL-17) and TNF synergistically inhibit pigmentation signalling and melanin production. It has been observed that on psoriatic lesions, on which IL-17 and TNF are elevated, the number of melanocytes is high, but pigmentation signalling is suppressed. Anti-IL-17 and anti-TNF drug would act recovering expression of pigmentation signalling and lowering number of melanocytes, what would restore pigmentation process in 2-4 weeks. The elevated number of melanocytes on psoriatic skin would cause an excessive production of melanin that would remain in the keratinocyte during the early stages of clinical improvement, leading to post inflammatory hyperpigmentation [8]. This pigmentation could persist for weeks to months until the number of melanocytes return to normal, or even be persistent [8,9].

We report an association not yet described of AN over resolving psoriatic plaques after use of adalimumab. In this case, the concomitance of the appearance of AN and the use of adalimumab, may reveal that the drug is involved in the development and persistence of the disorder, both by its immunosuppressant effect and by the action on the keratinocytes, melanocytes, cytokines and possibly EGFR.

References

1. Santos-Juanes J, Coto P, Mallo S, Galache C, Sánchez del R, et al. (2008) Multiple lentiginosis confined to resolving psoriatic plaques in a patient treated with adalimumab. *Dermatology* 216: 279.
2. Barbato MT, Criado PR, Silva AK, Averbeck E, Guerin MB, et al. (2012) Association of acanthosis nigricans and skin tags with insulin resistance. *An Bras Dermatol* 87: 97-104.
3. Torley D, Bellus GA, Munro CS (2002) Genes, growth factors and acanthosis nigricans. *Br J Dermatol* 147: 1096-1101.
4. Deklotz CM, Eshagh K, Krakowski AC (2014) Psoriatic plaques "koebnerizing" to areas of acanthosis nigricans in an obese female: clues to a common pathway? *J Clin Aesthet Dermatol* 7: 40-41.
5. von Schnakenburg C, Enke B, Jürgens K, Offner G (2001) Pseudo-Acanthosis nigricans in a 12 year old boy after kidney transplantation. *Klin Padiatr* 213: 288-289.
6. Pandya C, Blazey H, Budev MM, Mehta AC, Minai OA (2006) Acanthosis nigricans following single lung transplantation: a case report. *Prog Transplant* 16: 239-241.
7. Gutierrez-Gonzales E, Batalla A, de la Mano D (2014) Multiple lentiginosis in areas of resolving psoriatic plaques after ustekinumab therapy. *Dermatol Online* 20: 22338.
8. Wang CQ, Akalu YT, Suarez-Farinas M, Gonzales J, Mitsui H, et al. (2013) IL-17 and TNF synergistically modulate cytokine expression while suppressing melanogenesis: potential relevance to psoriasis. *J Invest Dermatol* 133: 2741-2752.
9. Di Cesare, Fagnoli MC, Marinuccio A, Peris K (2015) Rationale for the development of speckled hyperpigmentation in the areas of psoriatic plaques after treatment with biologic agents. *J Invest Dermatol* 135: 318-320.