

A Surgical Lung Biopsy Case of Pulmonary Veno-occlusive Disease Associated with Limited Cutaneous Systemic Sclerosis

Satoshi Ikeo¹, Hiromi Tomioka^{1*}, Masahiro Kaneko¹, Eiji Katsuyama² and Yoshinori Kawabata³

¹Department of Respiratory Medicine, Kobe City Medical Center West Hospital, Japan

²Department of Pathology, Kobe City Medical Center West Hospital, Japan

³Division of Diagnostic Pathology, Saitama Cardiovascular and Respiratory Center, Japan

*Corresponding author: Hiromi Tomioka, Department of Respiratory Medicine, Kobe City Medical Center West Hospital, Japan, Tel: 81-078-576-5251; E-mail: htomy@kobe-nishishimin-hospi.jp

Received date: October 27, 2014; Accepted date: November 17, 2014; Published date: November 27, 2014

Copyright: © 2014 Ikeo S, et al. This is an open-access article distributed under the terms of the Creative Commons Attribution License, which permits unrestricted use, distribution, and reproduction in any medium, provided the original author and source are credited.

Abstract

Pulmonary veno-occlusive disease (PVOD), a rare form of pulmonary arterial hypertension (PAH) characterized by a progressive obstruction of small pulmonary veins, is both difficult to diagnose and treat effectively. We reported a case of limited cutaneous systemic sclerosis complicated with PAH in which early definitive diagnosis of PVOD was made by surgical lung biopsy. A 53-year-old Japanese woman, with no history of smoking, was admitted to our hospital because of dry cough and progressive dyspnea. She had Raynaud's phenomenon, gastroesophageal reflux and skin sclerosis and she was positive for anticentromere antibody. Chest high-resolution computed tomography (HRCT) revealed diffuse centrilobular ground-glass opacities and septal lines in addition to mediastinal lymph node enlargement; radiographic triad of HRCT signs of PVOD. PAH was found by right heart catheterization. Although limited cutaneous systemic sclerosis-associated PAH was diagnosed, histological findings obtained by surgical lung biopsy showed not only wall thickening of muscular arteries and arterioles but diffuse occlusion of pulmonary venules, that is, PVOD. In addition, pleuritis and limited, mild cellular interstitial pneumonia was also observed. First-line corticosteroid therapy and careful combination therapy with sildenafil and ambrisentan initially stabilized her symptoms and pulmonary hemodynamics, but she died due to cardiac arrest approximately 2.5 years after initiating PAH therapy. The need to establish a correct and early diagnosis of PVOD is important because of the impaired prognosis of these patients and their risk of developing severe pulmonary edema with specific PAH therapy. HRCT is a useful noninvasive diagnostic modality in the evaluation of suspected PVOD.

Keywords: Systemic sclerosis; Limited cutaneous systemic sclerosis; Pulmonary arterial hypertension; Pulmonary veno-occlusive disease

Introduction

Systemic sclerosis (SSc) is a disease of unknown cause with microangiopathy and fibrosis. The disease has been internationally classified as having two components, i.e. limited cutaneous systemic sclerosis and diffuse cutaneous systemic sclerosis [1]. Patients with SSc are at risk of developing pulmonary arterial hypertension (PAH) that may lead to heart failure and death, with an estimated prevalence between 5-12% [2-4]. Remarkable progress has been made in the development of effective medical therapy using pulmonary vasodilators, however therapeutic responses in SSc-PAH patients are often disappointing, particularly compared to those with idiopathic PAH [5,6]. The explanation for these poorer results could be that SSc-PAH patients may be more prone to develop pulmonary veno-occlusive disease (PVOD) than patients with idiopathic PAH [4,7,8].

PVOD, an uncommon form of PAH characterized by a progressive obstruction of small pulmonary veins, is both difficult to diagnose and treat [8]. Histological proof of PVOD is usually retrospectively obtained after death or lung transplantation. We reported a case of limited cutaneous SSc complicated with PAH in which early definitive diagnosis of PVOD was made by surgical lung biopsy.

Case report

A 53-year-old woman with no history of smoking became aware of the onset of exertional dyspnea in early June, 2011. Her symptoms gradually increased, and were accompanied by a dry cough. She was admitted to our hospital in the early August, 2011. Her past medical history included hypertension, gastroesophageal reflux, and surgery for right ureteral cancer. She had developed Raynaud's phenomenon in 2003, which disappeared in 2005 after taking nifedipine for her hypertension. The patient was a housewife without occupational dust exposure. She had kept birds in her childhood and a cat for 28 years. Although she had recently had no contact with birds, she used a duvet. Her medications included nifedipine, rabeprazole sodium, and magnesium oxide. The patient's family history was unremarkable.

On admission she was tachycrotic (pulse, 113 beats/min) and hypoxemic (SpO₂, 65-70% on room air), but afebrile (temperature, 36.9°C) and normotensive (BP 140/50 mm Hg). Sclerema on the far side of the bilateral proximal interphalangeal joints with eponychium hemorrhages and telangiectasias on her face were noted. Neither crackles nor cardiac murmur were heard on chest auscultation, but an accentuated pulmonic component to the second heart sound was detected. The rest of her examination was unremarkable.

Laboratory investigations showed the following values: WBC count 8040/mm³; C-reactive protein 0.7 mg/dL; Hb 13.3 g/L; creatinine 0.87 mg/dL; aspartate aminotransferase 31 U/L; alanine aminotransferase 35 U/L; lactate dehydrogenase 251 IU/L; B-type natriuretic peptide

(BNP) 383.9 pg/mL; serum KL-6 346 U/mL (normal range <500 U/mL); surfactant protein D (SP-D) 135 ng/mL (normal range <110 ng/mL). The coagulation profile was unremarkable. Immunological tests showed the patient to be positive for antinuclear antibody ($\times 640$) and anti-centromere antibody (196 index), but negative for other autoimmune antibodies. Arterial blood gas analysis while breathing room air revealed severe hypoxemia (PaO_2 32.2 Torr), with PaCO_2 27.2 Torr and pH 7.428. Both vital capacity and carbon monoxide diffusing capacity (DLco) were reduced to 1.77 L (61.1%) and 4.58 mL/min/Torr (24.7%), respectively.

The chest X-ray showed faint infiltrative shadows in the bilateral lower lung fields (Figure 1A). Chest computed tomography showed mediastinal lymph node enlargement (Figure 1B) and chest high-resolution computed tomography (HRCT) showed diffuse centrilobular ground-glass opacities, septal lines and minimal bilateral pleural effusion (Figure 1C). Ventilation perfusion lung scintigraphy scans were normal.

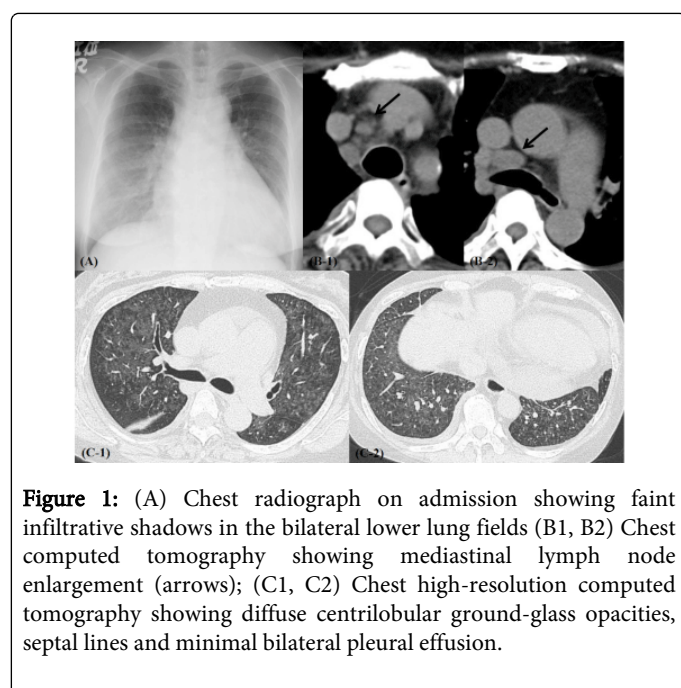


Figure 1: (A) Chest radiograph on admission showing faint infiltrative shadows in the bilateral lower lung fields (B1, B2) Chest computed tomography showing mediastinal lymph node enlargement (arrows); (C1, C2) Chest high-resolution computed tomography showing diffuse centrilobular ground-glass opacities, septal lines and minimal bilateral pleural effusion.

The appearance of bronchoalveolar lavage fluids was not bloody, but was lemon yellow with 5.7×10^5 cells per mL, comprised of 10.5% neutrophils, 9% lymphocytes and 80.5% macrophages. The electrocardiogram showed right axis deviation with peaked P waves in lead II. Estimated right ventricular systolic pressure determined by Doppler echocardiography was 73 mm Hg. Right heart catheterization revealed a pulmonary artery pressure (PAP) of 60/27/38 mm Hg, pulmonary capillary wedge pressure of 12 mm Hg, and pulmonary vascular resistance (PVR) of 489 dyne-sec/cm⁵, leading to a diagnosis of PAH. An upper gastrointestinal series showed constriction and back flow in the lower esophagus.

We diagnosed the patient as having limited cutaneous SSc complicated with PAH (WHO functional classification level III) based on the above-mentioned examinations. After obtaining patient informed consent a video-assisted lung biopsy was performed for diagnostic purposes and to assess treatment options. Histology of tissue obtained from the right S3 and S8 region is shown in Figure 2. Medial mild hypertrophy, intimal thickening, and organized thrombus

in the muscular arteries were observed (Figure 2A), and the arterioles had become arterIALIZED with intimal fibrosis (Figure 2B). Moreover, lumen occlusion and severe stenosis due to the intimal hyalinization were observed in venules (Figure 2C), and local blood pooling and hemosiderosis (Figure 2D) were also identified. A pathological diagnosis of PAH accompanied by advanced PVOD was made. In addition, pleuritis and limited, mild cellular interstitial pneumonia were also observed (Figure 2E,F).

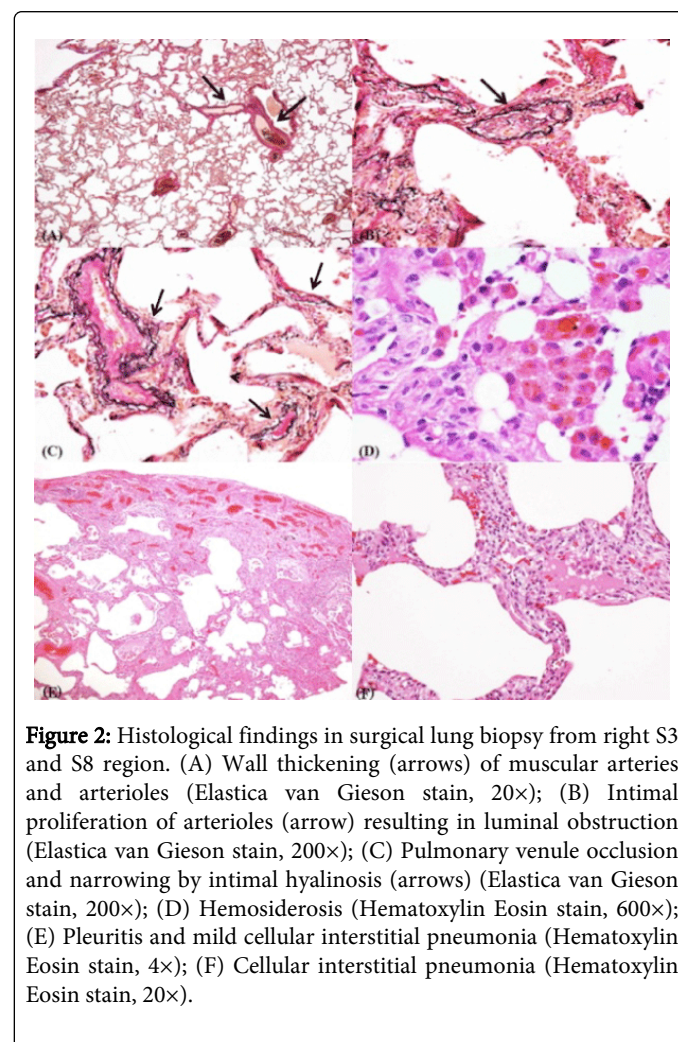


Figure 2: Histological findings in surgical lung biopsy from right S3 and S8 region. (A) Wall thickening (arrows) of muscular arteries and arterioles (Elastica van Gieson stain, 20 \times); (B) Intimal proliferation of arterioles (arrow) resulting in luminal obstruction (Elastica van Gieson stain, 200 \times); (C) Pulmonary venule occlusion and narrowing by intimal hyalinosis (arrows) (Elastica van Gieson stain, 200 \times); (D) Hemosiderosis (Hematoxylin Eosin stain, 600 \times); (E) Pleuritis and mild cellular interstitial pneumonia (Hematoxylin Eosin stain, 4 \times); (F) Cellular interstitial pneumonia (Hematoxylin Eosin stain, 20 \times).

Since vasodilators may precipitate acute pulmonary edema in patients with PVOD, and this case had in addition SSc complicated by cellular interstitial pneumonia, we started 50 mg/day of prednisolone (PSL) in September, 2011. Subsequently laboratory data including hemodynamic evaluation improved as follows: BNP 8.5 pg/mL; PAP 39/17/25 mm Hg; PVR 317 dyne-sec/cm⁵; DLco 2.56 mL/min/Torr.

The patient was concerned about the side effects of PSL, and consequently the agent was tapered and discontinued, resulting in worsening of her symptoms of dyspnea and dry cough. Laboratory data also deteriorated as follows: BNP 163.9 pg/mL; PAP 72/23/40 mmHg; PVR 691 dyne-sec/cm⁵. At this point administration of ambrisentan was initiated at 2.5 mg/day and sildenafil at 20 mg/day was added subsequently, with titration of both agents up to the maximal doses without the development of pulmonary edema. In March, 2012 with worsening of her symptoms of dyspnea with fever

and chest HRCT findings of interstitial opacities, methyl-prednisolone was administered at 500 mg/day for 3 days and then PSL was readministered at 25 mg/day. After her symptoms and HRCT findings were relieved the PSL dose was gradually reduced. She was medically stabilized with maintenance therapy of ambrisentan 10 mg/day, sildenafil 60 mg/day, and PSL 5 mg/day. In March, 2013 the patients underwent a left mastectomy for breast cancer. Her dyspnea began to worsen again in the summer of 2013 and she required repeated hospitalization despite PSL dose escalation. We recommended listing the patient for potential lung transplantation, but she declined. Finally, in April, 2014, approximately 2.5 years after initiating PAH therapy, the patient died due to cardiac arrest.

Discussion

This case was diagnosed as limited cutaneous SSc complicated with PAH based on the positivity of centromere antibody, skin findings, Raynaud's symptoms, esophageal hypoperistalsis, and hemodynamic evaluation by the right heart catheterization. In addition, histopathological findings on lung biopsy showed not only the changes in pulmonary arteries but also fibrous remodeling of the pulmonary venous system, i.e. PVOD.

The diagnosis PVOD was formerly included as a part of PAH, but is now placed in a separate but related category referred to as Group 1' in the recent update of the classification system of pulmonary hypertension [8,9]. Although PVOD is very rare with an annual incidence estimated to be approximately 0.1-0.2 cases per million in the general population [10,11], it has been reported that PVOD lesions are more likely to be observed pathologically in limited cutaneous SSc-associated PAH. Dorfmueller et al. [7] reported a histopathological study using postmortem lung samples (n=5) and explants after lung transplantation (n=3) obtained from 8 connective tissue disease-associated PAH cases. They showed that PVOD lesions were confirmed in 6 cases including 4 cases of limited cutaneous SSc-associated PAH. Overbeek et al. [4] also identified histological pulmonary vasculopathy in all of the 8 cases of limited cutaneous SSc-associated PAH by autopsy (n=5), lung transplantation (n=2) or surgical lung biopsy (n=1). As shown in these reports histological proof of PVOD is usually retrospectively obtained after death or lung transplantation. Although the definitive diagnosis of PVOD requires histological examination of lung tissue samples, lung biopsy is a high-risk procedure in the setting of PAH. After obtaining informed consent from the patient we performed a video-assisted lung biopsy without significant complications. Surgical lung biopsy for PVOD is controversial [8], however, this procedure should be considered to confirm the clinical suspicion of PVOD because a definitive diagnosis can provide important prognostic information for the patient and impact upon the timing of evaluation and listing for lung transplantation [12]. HRCT is also an important noninvasive diagnostic modality in the evaluation of suspected PVOD [8,10,13,14]. The triad of diffuse ground-glass opacification particularly in a centrilobular distribution, septal thickening, and mediastinal lymph node enlargement is common and highly suggestive of PVOD in patients with features of PAH [8,13,14]. This triad was also present in the current case. Günther et al. [14] reviewed chest HRCT data from 26 SSc patients with PAH and 28 SSc patients without PAH or interstitial lung disease. They reported that radiographic triad of HRCT signs of PVOD was significantly more frequent in the former than in the latter. Pulmonary venous involvement was histologically confirmed by autopsy in 2 patients with radiographic signs of PVOD.

The current case is important in that PVOD was histologically confirmed by surgical lung biopsy in a patient with radiographic signs of PVOD.

PVOD is a severe condition with a poor prognosis, and the only curative therapy is lung transplantation. Close monitoring for disease progression is necessary, even if the patients on the transplant waiting list, due to higher risk for death. Few patients survive more than two years after diagnosis [12]. There are no proven effective pharmacological agents for PVOD. Treatment remains challenging as these patients have some risk of developing acute pulmonary edema with the use of PAH-specific drugs. These agents may promote fluid extravasation from the capillaries to the alveoli by acting as arteriolar vasodilators in the presence of venular obstruction due to specific remodeling [10,15,16]. Accordingly, it is important to precisely differentiate PVOD from other diseases presenting with PAH in considering treatment strategies. We initiated immunosuppressive therapy by glucocorticoids as first-line treatment in this case due to the presence of coexistent inflammatory parenchymal lung disease and pleuritis in addition to the PVOD lesions as shown by the surgical lung biopsy. Moreover, in addition to steroid therapy, careful management of PAH therapy using the orally active pulmonary vasodilators ambrisentan and sildenafil resulted in relatively long-term survival that exceeded the usual expectations. Although the effectiveness of immunosuppressive agents has been reported in treating PAH patients with mixed connective tissue disease and systemic lupus erythematosus, this finding is thus far lacking in patients with SSc [17,18]. Hayashi et al. [19] have reported that corticosteroid therapy was successful in a PAH patient with limited cutaneous SSc and accompanying PVOD lesions, but had no effectiveness in administering epoprostenol. Although ambrisentan has been reported to be associated with an increased risk for disease progression in idiopathic pulmonary fibrosis [20], we nonetheless used this agent without difficulty in our patient. Ambrisentan in general has a more favorable interaction profile than other drugs such as bosentan, especially in case of combination therapy with immunosuppressive agent such as cyclosporin.

In summary, we reported a case of limited cutaneous SSc complicated with PAH in which early definitive diagnosis of PVOD was made by surgical lung biopsy. The need to establish a correct and early diagnosis of PVOD is important because of the impaired prognosis of these patients and their risk of developing severe pulmonary edema with specific PAH therapy. HRCT is a useful noninvasive diagnostic modality in such setting.

Acknowledgement

The authors wish to thank Drs Souji Moriwaki, Masahiko Takeo and Hirokuni Ikeda, Kobe City Medical Center West Hospital, and Dr Sahoko Morinobu, Kobe University Hospital for their assistance. A part of this article was published as a medical quiz; 'Series: Diagnosis at a Glance' in the local Japanese journal, *Nihon Naika Gakkai Zasshi* (Journal of Japanese Society of Internal Medicine) 101:3607-3609, 2012 (in Japanese).

References

1. LeRoy EC, Black C, Fleischmajer R, Jablonska S, Krieg T, et al. (1988) Scleroderma (systemic sclerosis): classification, subsets and pathogenesis. *J Rheumatol* 15: 202-205.

2. Avouac J, Aïro P, Meune C, Beretta L, Dieude P, et al. (2010) Prevalence of pulmonary hypertension in systemic sclerosis in European Caucasians and metaanalysis of 5 studies. *J Rheumatol* 37: 2290-2298.
3. Mukerjee D, St George D, Coleiro B, Knight C, Denton CP, et al. (2003) Prevalence and outcome in systemic sclerosis associated pulmonary arterial hypertension: application of a registry approach. *Ann Rheum Dis* 62: 1088-1093.
4. Overbeek MJ, Vonk MC, Boonstra A, Voskuyl AE, Vonk-Noordegraaf A, et al. (2009) Pulmonary arterial hypertension in limited cutaneous systemic sclerosis: a distinctive vasculopathy. *Eur Respir J* 34: 371-379.
5. Badesch DB, Tapson VF, McGoon MD, Brundage BH, Rubin LJ, et al. (2000) Continuous intravenous epoprostenol for pulmonary hypertension due to the scleroderma spectrum of disease. A randomized, controlled trial. *Ann Intern Med* 132: 425-434.
6. Launay D, Sitbon O, Le Pavec J (2010) Long-term outcome of systemic sclerosis-associated pulmonary arterial hypertension treated with bosentan as first-line monotherapy followed or not by the addition of prostanoids or sildenafil. *Rheumatology* 49: 490-500.
7. Dorfmueller P, Humbert M, Perros F (2007) Fibrous remodeling of the pulmonary venous system in pulmonary arterial hypertension associated with connective tissue diseases. *Human Pathol* 38: 893-9028.
8. Montani D, O'Callaghan DS, Savale L, Jaïs X, Yaïci A, et al. (2010) Pulmonary venous occlusive disease: recent progress and current challenges. *Respir Med* 104 Suppl 1: S23-32.
9. Simonneau G, Robbins IM, Beghetti M, Channick RN, Delcroix M, et al. (2009) Updated clinical classification of pulmonary hypertension. *J Am Coll Cardiol* 54: S43-54.
10. Montani D, Achouh L, Dorfmueller P (2008) Pulmonary venous occlusive disease: Clinical, functional, radiologic, hemodynamic characteristics and outcome of 24 cases confirmed by histology. *Medicine (Baltimore)* 87: 220-233.
11. Humbert M, Sitbon O, Chaouat A, Bertocchi M, Habib G, et al. (2006) Pulmonary arterial hypertension in France: results from a national registry. *Am J Respir Crit Care Med* 173: 1023-1030.
12. Mandel J, Mark EJ, Hales CA (2000) Pulmonary venous occlusive disease. *Am J Respir Crit Care Med* 162: 1964-1973.
13. Resten A, Maitre S, Humbert M, Rabiller A, Sitbon O, et al. (2004) Pulmonary hypertension: CT of the chest in pulmonary venous occlusive disease. *AJR Am J Roentgenol* 183: 65-70.
14. Günther S, Jaïs X, Maitre S (2012) Computed tomography findings of pulmonary venous occlusive disease in scleroderma patients presenting with precapillary pulmonary hypertension. *Arthritis Rheum* 64: 2995-3005.
15. Palmer SM, Robinson LJ, Wang A, Gossage JR, Bashore T, et al. (1998) Massive pulmonary edema and death after prostacyclin infusion in a patient with pulmonary venous occlusive disease. *Chest* 113: 237-240.
16. Montani D, Jaïs X, Price LC, Achouh L, Degano B, et al. (2009) Cautious epoprostenol therapy is a safe bridge to lung transplantation in pulmonary venous occlusive disease. *Eur Respir J* 34: 1348-1356.
17. Sanchez O, Sitbon O, Jaïs X, Simonneau G, Humbert M (2006) Immunosuppressive therapy in connective tissue diseases-associated pulmonary arterial hypertension. *Chest* 130: 182-189.
18. Jaïs X, Launay D, Yaïci A (2008) Immunosuppressive therapy in lupus- and mixed connective tissue disease-associated pulmonary arterial hypertension: a retrospective analysis of twenty-three cases. *Arthritis Rheum* 58: 521-531.
19. Hayashi H, Morimoto K, Matsuyama M (2009) A case of systemic sclerosis sine scleroderma showing pulmonary venula lesion that suggests pulmonary venous occlusive disease. *The Journal of The Japanese Respiratory Society* 47: 376-382.
20. Raghu G, Behr J, Brown KK, Egan JJ, Kawut SM, et al. (2013) Treatment of idiopathic pulmonary fibrosis with ambrisentan: a parallel, randomized trial. *Ann Intern Med* 158: 641-649.