

A Rare Case of Chin Cutaneous Metastases from Transitional Cell Carcinoma of Bladder in a Patient Who Underwent Radical Cystectomy

Giovanni Luca Giliberto¹, Carmelo Agostino Di Franco² and Bruno Rovereto²

¹Department Urology Policlinico San Matteo, Pavia, PV 27010, Italy

²Department Urology IRCCS Policlinico San Matteo, Pavia, PV 27010, Italy

*Corresponding author: Giovanni Luca Giliberto, 1Department Urology Policlinico San Matteo, Pavia, Italy, Tel: +393470505571; E-mail: gl.giliberto@gmail.com

Received date: November 23, 2016; Accepted date: December 22, 2016; Published date: December 29, 2016

Copyright: © 2016 Giliberto GL, et al. This is an open-access article distributed under the terms of the Creative Commons Attribution License, which permits unrestricted use, distribution, and reproduction in any medium, provided the original author and source are credited.

Abstract

Facial cutaneous metastases from primary bladder cancers are very rare and usually they are associated with poor prognosis. In literature, very few cases of cutaneous metastases from urothelial malignancies are reported but we did not find any case of bladder cancer metastases localised to chin; usually cutaneous metastases from bladder are localised in chest or scrotal skin. We report a 66 year-old patient affected by muscle-invasive transitional cell carcinoma of bladder who underwent radical cystectomy and who developed in two months after operation a skin lesion localised to chin. Clinical stage of bladder cancer was cT2 N0 M0; the patient was studied before operation through total body CT-scan, TB bone-scan negative for metastases. The patient was totally asymptomatic and he had a good performance status. We discuss the need to have suspicion in presence of cutaneous lesions, apparently benign, in a patient affected by malignancy in order to start quickly a proper treatment.

Keywords: Bladder cancer; Rare metastasis; Radical cystectomy

Case Report

A 66-year old Caucasian man underwent open radical cystectomy for muscle-invasive transitional cell carcinoma of bladder with orthotopic neobladder reconstruction. Around one month before, the patient was admitted to our department because of a single episode of macro haematuria. A US scan showed a single polypoid lesion of right bladder wall around 2 to 5 centimetres. We performed a TURB that showed a transitional cell carcinoma (TCC) of bladder, high grade (WHO 2004) G2-G3 (WHO 1973). The patient was symptomless and he had a good performance status. Histological examination after radical cystectomy reported a TCC muscle-invasive, high grade (WHO 2004), G3 (WHO 1973), mainly localised in right bladder wall (Figure 1). The cancer infiltrated all the bladder wall thickness, microscopically it reached the perivesical fat tissue (pT3a) with images of perineural neoplastic permeation. The remaining mucosa was affected by CIS (carcinoma in situ). We performed LND (from external iliac artery to obturator fossa) removing 19 lymph nodes on the right and 16 on the left side. All lymph nodes were negative for metastases (pN0).

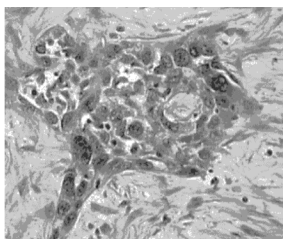


Figure 1: Infiltration of bladder wall by a high grade G3 transitional cells carcinoma (TCC).

After around one month, during follow-up, the patient was evaluated in our department for one single tender purple nodule localised at the chin initially. The lesion was thought to be a furuncle. It continued to enlarge with objective signs of flogosis (reddened skin, oedema, mild pus/necrotic material by squeezing) and relative lack of pain. At this moment, the patient was totally asymptomatic.

We required a maxillofacial surgery consultation. The patient performed a punch biopsy of skin lesion that showed a metastatic carcinoma, histologically identical to the primary bladder cancer. Microscopically, it showed pleomorphic hyperchromatic cells with high mitotic activity and large nucleoli in dermis and epidermis (Figure 2).

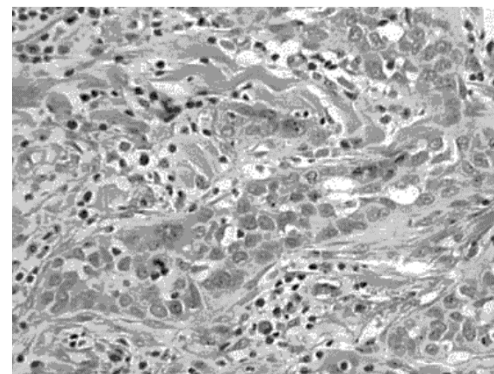


Figure 2: Skin biopsy showing metastatic TCC analogous to the primary bladder cancer.

After less of 1 month from the diagnoses of the chin metastasis, we performed a total body CT-scan that revealed bone metastases of lumbosacral column. We sent the patient to maxillo-facial surgeon to

remove the pathological nodule and to the oncological evaluation in order to do adjuvant chemotherapy.

Discussion

In literature, the overall incidence of cutaneous metastases from primary solid visceral cancers is low, around 2 to 9 to 5.3%; the most common side of metastases is chest and the most common primary cancer is breast [1]. Cutaneous metastases from transitional cells cancers are rare and bladder represents the primary cancer in 0.84% to 3.6% of cases [2]. In literature, cases of cutaneous metastases from TCC bladder cancer are described but we did not find any case of facial metastases, in particular to chin, from bladder cancer [3,4]. Usually, presence of cutaneous metastases is associated with poor prognosis, but in literature some case of regression is described [5]. Cutaneous metastases might mimic other benign cutaneous disorders such as sebaceous cysts or furuncles, but in presence of cutaneous lesion with flogosis signs, lack or low pain and tending to enlarge and ulcerate it is necessary to suspect a metastatic lesion. Cutaneous metastases from bladder TCC usually develop in loco regional skin in particular abdomen, genitalia and thighs and it is supposed to be related to lymphatic spread [6]. In our case, chin localisation could be related to haematogenous spread. We think that histological examination of radical cystectomy could predict a high index risk that a cutaneous lesion could be a metastasis; in particular, the stage T2 or more and

mostly the presence of in situ carcinoma and perineural neoplastic permeation. In our case, lymph nodes were negative (N0 disease) but we had a rapid progression of disease with cutaneous metastases and bone metastases (lumbosacral column) in a patient totally asymptomatic. We think that cutaneous metastases are frequently associated with other more common side of metastatization such as bone and visceral metastases and this is to keep in consideration to start precociously a total body stadiation of the patient.

References

1. Krathen RA, Orengo IF, Rosen T (2003) Cutaneous metastasis: a meta-analysis of data. *South Med J* 96: 164-167.
2. Mueller TJ, Wu H, Greenberg RE (2004) Cutaneous metastases from genitourinary malignancies. *Urology* 63: 1021-1026.
3. Eardley I, Abercrombie J, Wright BJ, Hendry WF (1987) Cystic cutaneous metastases from transitional cell carcinoma of the bladder. *J R Soc Med* 80: 314-315.
4. Safer LF, Pirozzi DJ (1980) Extensive cutaneous metastases from urinary bladder carcinoma. *Cutis* 26: 500.
5. Mancebo JM, de la Pena J, Hidalgo L (1985) Spontaneous regression of cutaneous metastases of transitional cell carcinoma of the bladder. *Arch Esp Urol* 38: 497-501.
6. Zwenger EM, Kaatz M (2006) Skin metastases of "nested type" urothelial carcinoma of the urinary bladder. *J Cutan Pathol* 33: 754.