

## A Pustular Psoriasis of the Face associated with a Perianal Pyoderma Gangrenosum: Same Nosologic Entity?

Ecra Elidjé Joseph<sup>1\*</sup>, Gbéry Ildevert Patrice<sup>1</sup>, Sangaré Abdoulaye<sup>1</sup>, AKA Boussou Romain<sup>1</sup>, Kassi Komenan<sup>2</sup>, Kourouma Sarah<sup>3</sup>, Vagamon Bamba<sup>1</sup>, Djéha Djokouehi<sup>1</sup>, Ahogo Kouadio Celestin<sup>2</sup>, Kouassi Alexandre<sup>3</sup>, Kouassi Yao Isidore<sup>4</sup>, Kaloga Mamadou<sup>2</sup> and Camara Amara<sup>2</sup>

<sup>1</sup>Professor, Department of Dermatology and Venerology, Teaching Hospital of Treichville, Abidjan, Côte d'Ivoire

<sup>2</sup>Assistant professor, Department of Dermatology and Venerology, Teaching Hospital of Treichville, Abidjan, Côte d'Ivoire

<sup>3</sup>Associate professor, Department of Dermatology and Venerology, Teaching Hospital of Treichville, Abidjan, Côte d'Ivoire

<sup>4</sup>Intern, Department of Dermatology and Venerology, Teaching Hospital of Treichville, Abidjan, Côte d'Ivoire

\*Corresponding author: Ecra Elidjé Joseph, Professor, Department of Dermatology and Venerology, Teaching Hospital of Treichville, 15 BP4 Abidjan15, Côte d'Ivoire, Tel: (225)07840978; Fax: 225 21252852; E-mail: joecra@hotmail.com

Received Date: June 29, 2014, Accepted Date: August 7, 2014, Published Date: August 14, 2014

Copyright: © 2014 Joseph EE et al. This is an open-access article distributed under the terms of the Creative Commons Attribution License, which permits unrestricted use, distribution, and reproduction in any medium, provided the original author and source are credited.

### Abstract

Psoriasis can have a pustular feature. When it is associated with a pyoderma gangrenosum, it leads to a nosologic problem. Is it the same entity, neutrophilic dermatosis with different clinical manifestations? Here we report the first clinical case of pustular psoriasis of the face associated with perianal pyoderma gangrenosum. This case comes out with these rare locations of the two diseases, responsible for unclear diagnosis. We highlight the importance of biological examinations, to eliminated the others diseases and the key role of histopathological examination into the positive diagnosis. It doesn't to be save up in our context and it have to be done when the treatment failed. The follow up of these two diseases was successful under corticosteroid therapy.

**Keywords:** Psoriasis; Pyoderma gangrenosum; Neutrophilic dermatosis

### Introduction

Genetic and environmental factors intervene into psoriasis outbreak, including numerous drugs [1]. As for, pyoderma gangrenosum, it can be idiopathic or associated with systemic diseases [2]. The association of these two pathologies is known and includes varies and complex mechanisms [3-5]. Psoriasis can be presented in pustular features, and associated with a pyoderma gangrenosum. Are the two pathologies the same entity, the neutrophilic dermatosis with different clinical manifestations? Here we report the first clinical case of pustular psoriasis of the face associated with perianal pyoderma gangrenosum observed in our department.

### Clinical case

Mr. GG, 50 years of age, presented in 2003 a pustulosis in barber of the chin arising on erythematous skin which extended progressively to the front, to the head, to the nose, to the nasal and genus areas, in vespertilio aspect on the cheekbone and cheeks but the eyelids were normal (Figure 1).

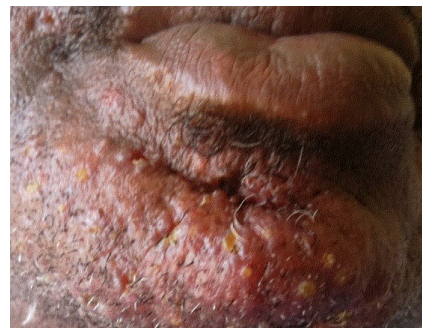
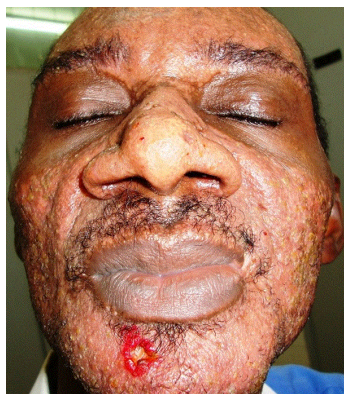
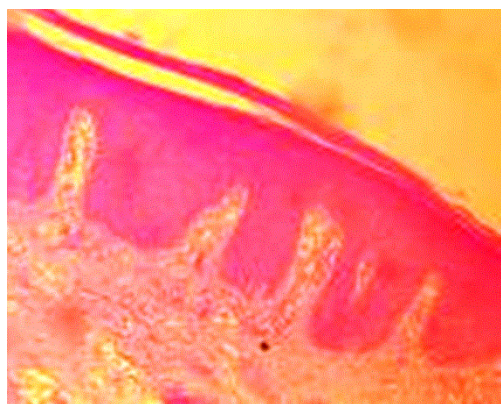
Figure 1: Pustulosis in barber

An antibiotic treatment was done without success and it developed itself into erythematous, yellow crusted and scaling lesions (Figure 2).



**Figure 2:** Pustular psoriasis of the face: Erythematous, scaly, crusted lesions with yellowish crusts

The patient was then sent to our dermatology department for better management. Under topical corticosteroid and antimycotic treatment for seborrheic dermatitis, it showed small improvement. Later, the histopathological examination showed a parakeratotic hyperkeratosis with presence of abscess in the stratum corneum layer and an inflammatory infiltrated dermis; all these features were in favour to psoriasis. Psoriasis diagnosis was retained; the patient was treated by methotrexate (Figure 3).

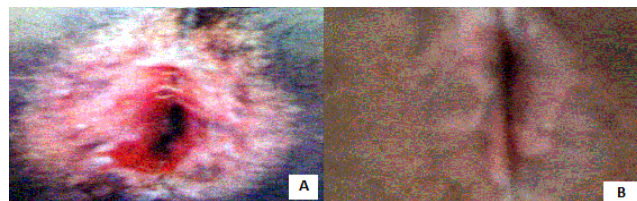


**Figure 3:** Parakeratotic hyperkeratosis and hyperpapillomatose with presence of abscess in the stratum corneum

Small improvement was observed without complete clearance of the face. 6 years later, it occurred superficial perianal ulceration, which was circular, extensive, purulent, well defined, invading the anal margin and painless. There was no inguinal lymphadenopathy. The patient did not present tuberculosis signs and digestive troubles. All these symptoms led us toward chronic herpes.

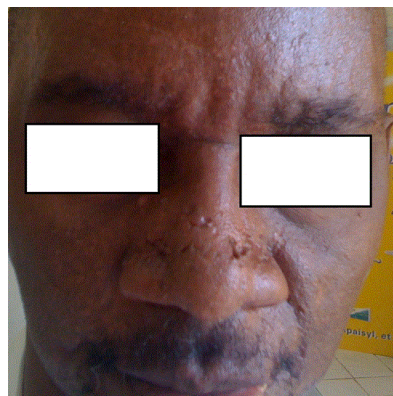Bacterial and parasital examinations did not find tuberculosis, donovanosis or an amibiases. The other biological examinations showed sterile pus, 7 mm of Tuberculin Cutaneous Reaction (CTR), no hyperleucocytosis, and a renal ET hepatic biological examination were normals, and blood sugar level was normal and no inflammatory biological syndrome. HIV test was negative. Due to the impossibility

to realize virological tests, the patient received valaciclovir to treat chronic herpes without success (Figure 4).



**Figure 4:** a) Perianal pyoderma gangrenosum, b) Cicatrization under corticosteroid therapy

The histological examination of this ulceration was less specific but showed a polynuclear infiltration into the dermis and the epidermis, which was for neutrophilic dermatosis. The high and low digestive endoscopy did not show anything in particular. All these signs allow us to conclude to the diagnosis of pustular psoriasis of the face associated with a perianal pyoderma gangrenosum. Under corticotherapy (prednisone) in the dosage 1 mg/kg/day for pyoderma gangrenosum treatment, we observed normal cicatrization of the perianal ulceration, and then a progressive clearance of the all face was observed with a cutaneous reepithelization (Figure 5).



**Figure 5:** Clean et and repigmentation of the face

## Discussion

Pustular psoriasis is characterized by the presence of clinically visible spongiform pustules as we saw in our patient [1]. Its location in the face wasn't described previously. We retained this diagnosis based on clinical aspect (pustules and yellow crusts) and histopathology features that allow us to eliminate a pyoderma gangrenosum in the face. So, it seems the first case reported. As for pyoderma gangrenosum, genital and perineal localisations are already known [6-9]. In our case, it was idiopathic.

Vulgaris psoriasis associated to pyoderma gangrenosum was already described [3,10,11]. Today, as recommended by JH Saurat, the pustular form of psoriasis with pyoderma gangrenosum get into the concept of neutrophilic dermatosis [12]. One case of vulgaris psoriasis as a pyoderma gangrenosum precursor was described in the literature, it shows that pustular psoriasis and pyoderma gangrenosum could be

the same entity with different clinical manifestations [4]. It especially as the course of both diseases is favorable under corticosteroid drugs. The mechanisms are numerous and could be auto-immune. This auto immune mechanism was already suggested by Yurci A, in a case of exacerbated psoriasis associated with pyoderma gangrenosum, which occur in patient suffering from hepatitis C under treatment by interferon pegyle and ribavirine [11].

## Conclusion

Pustular psoriasis and pyoderma gangrenosum are the two clinical manifestations of a same nosologic entity, the neutrophilic dermatosis. Their association is possible; it could be caused by the same mechanism, responding to the same treatment: the corticosteroid therapy.

## References

1. Jullien D (2009) Psoriasis. In: Saurat JH, Lachapelle JM, Lipsker D (Eds.), *Dermatologie et infections sexuellement transmissibles: Troubles de la différenciation épidermique* Paris.
2. Krischer J, Modiano P (2009) Pyoderma gangrenosum. In: Saurat JH, Lachapelle JM, Lipsker D (Eds.), *Dermatologie et infections sexuellement transmissibles: dermatoses par infiltrats cellulaires lympho-mono-myélocytaires: dermatoses neutrophiliques*, Paris.
3. Baglieri F, Scuderi G (2010) Therapeutic hotline. Infliximab for treatment of resistant pyoderma gangrenosum associated with ulcerative colitis and psoriasis. A case report. See comment in PubMed Commons below *Dermatol Ther* 23: 541-543.
4. Klode J, Körber A, Dissemond J (2009) Psoriasis vulgaris as a trigger for a superficial multilocular pyoderma gangrenosum?. See comment in PubMed Commons below *Hautarzt* 60: 569-572.
5. Phan JC, Hargadon AP, Salpeter SR (1996) Association between pyoderma gangrenosum and psoriasis. See comment in PubMed Commons below *Lancet* 348: 547.
6. Bessis D, Guillhou JJ (2007) Affections rhumatismales inflammatoires. In: *Manifestations cutanées et muqueuses des connectivites, vasculites et affections systémiques apparentées: Dermatologie et médecine*, Paris.
7. Ecra E, Ahogo KC, Sangaré A, Kaloga M, Kassi K, et al. (2009) [An uncommon localization of pyoderma gangrenosum on the penis of an HIV infected patient in the Ivory Coast]. See comment in PubMed Commons below *Bull Soc Pathol Exot* 102: 85-87.
8. Rathod SP, Padhiar BB, Karia UK, Shah BJ (2011) Penile pyoderma gangrenosum successfully treated with topical Imiquimod. See comment in PubMed Commons below *Indian J Sex Transm Dis* 32: 114-117.
9. Burgess NA, Lari JL (1991) Pyoderma gangrenosum with large circumferential perianal skin loss in a child. See comment in PubMed Commons below *Br J Clin Pract* 45: 223-224.
10. Kreuter A, Gambichler T, Hoffmann K, Altmeyer P, Brockmeyer NH (2002) Association of HIV infection, pyoderma gangrenosum and psoriasis. See comment in PubMed Commons below *Acta Derm Venereol* 82: 150-152.
11. Yurci A, Guven K, Torun E, Gursoy S, Baskol M, et al. (2007) Pyoderma gangrenosum and exacerbation of psoriasis resulting from pegylated interferon alpha and ribavirin treatment of chronic hepatitis C. *Eur J Gastroenterol Hepatol* 19: 811-815.
12. Saurat JH (2009) Concept de dermatoses neutrophiliques In: Saurat JH, Lachapelle JM, Lipsker D (Eds.), *Dermatologie et infections sexuellement transmissibles: dermatoses par infiltrats cellulaires lympho-mono-myélocytaires: dermatoses neutrophiliques*, Paris.