

A Novel Approach to the Treatment of Sebaceous Hyperplasia and Post-Procedural Purpura with Pulsed-Dye Laser

Paul M Graham^{1*} and Stephen W Eubanks²

¹Dermatology Resident PGY-4, St. Joseph Mercy Hospital, Ann Arbor, USA

²Dermatology and Laser Center at Harvard Park, Denver, Colorado, USA

*Corresponding author: Paul M. Graham, Department of Dermatology, 5333 McAuley Dr # 5003, Ypsilanti, MI 48197, Michigan, USA, Tel: 757-630-9803; E-mail: pmgraham86@gmail.com

Received date: 21 June, 2016; Accepted date: 12 July, 2016; Published date: 18 July, 2016

Copyright: © 2016 Graham PM, et al. This is an open-access article distributed under the terms of the Creative Commons Attribution License, which permits unrestricted use, distribution, and reproduction in any medium, provided the original author and source are credited.

Abstract

Background: Sebaceous hyperplasia is a benign but clinically and cosmetically unappealing lesion. Historical treatments include cauterization, cryotherapy, chemical ablation, and surgical removal, all of which increase the risk for permanent post-operative adverse effects. The pulsed-dye laser (PDL) offers a safe and effective approach to the treatment of sebaceous hyperplasia in Fitzpatrick skin types I-III, but purpura was an unacceptable trade off of this treatment. We describe a subsequent follow-up treatment aimed at reducing the resulting post-PDL purpura.

Methods: Our report presents 5 patients (Fitzpatrick II-III) treated with PDL (595 nm, 5 mm spot, 20 J/cm², 3 ms) for sebaceous hyperplasia with subsequent follow-up treatment, 24-hours later, with the same PDL (595 nm, 7 mm spot, 9 J/cm², 6 ms, DCD 30/20) aimed at improving the post-operative purpura.

Results: Sebaceous hyperplasia and resulting purpura improved after a single combination treatment session with both high and moderate-fluence PDL. Purpura is required for effective treatment of sebaceous hyperplasia, but is subsequently treated with moderate-fluence PDL 24-hours later, offering complete resolution of post-PDL purpura within 72 hours.

Conclusion: Treatment of sebaceous hyperplasia with PDL offers a safe and effective treatment modality aimed at the underlying vasculature associated with the sebaceous gland. The high-fluence and short pulse duration required to remove the sebaceous hyperplasia often leads to the development of purpura. This post-PDL purpura is successfully treated with moderate-fluence PDL with resolution within 72 hours. In the future, we believe that many other conditions requiring high-fluence PDL that leads to purpura may also be treated with a subsequent lower dose treatment to remove any laser induced purpura.

Keywords: Bruising; High fluence; Moderate fluence; Pulsed-dye laser; Purpura; Sebaceous hyperplasia

Introduction

Sebaceous hyperplasia is a benign proliferation of sebaceous glands located predominately on the face. These lesions can be a significant cosmetic concern in men and women, prompting patients to seek out methods of removal. Treatments in the past have been aimed at destroying these lesions with the use of cryotherapy, electrocauterization, curettage, surgical excision, and chemical ablation, all of which had substantial risk associated [1-3]. Significant adverse effects common with these procedures include pain, scarring, dyspigmentation, prolonged recovery time, and high rate of recurrence, thus limiting these modalities as appropriate treatment options. The risk of adverse effects has prompted the use of laser therapy. In 1997, Schönemark et al. first reported the use of PDL for the treatment of sebaceous hyperplasia [1]. They demonstrated that the PDL is a safe and effective treatment option to eliminate sebaceous hyperplasia, but accompanied by the risk of PDL-induced purpura [1]. This PDL-induced purpura is secondary to the high-fluence requirement needed to effectively eliminate the targeted sebaceous gland. We have employed a novel technique for the elimination of this

PDL-induced purpura within 72 hours using our moderate-fluence PDL protocol. To date, there are no reports in the literature describing the use of pulsed-dye laser to rapidly eliminate the purpura that is directly caused by high-fluence pulsed-dye laser therapy.

Materials and Methods

A cohort of five patients (5 males; Fitzpatrick skin types II-III; 44-66 years) with multiple facial sebaceous hyperplasia (1-4 mm diameter) were treated with high-fluence PDL followed by treatment for the PDL-induced purpura after informed consent had been obtained. All five patients had hyperplastic sebaceous glands located on the face (malar cheeks, forehead, and periocular) (Figure 1).

No topical or other anesthetic was used and no test spots were performed prior to treatment. Laser treatment consisted of two consecutive sessions spaced 24-hours apart. Session 1 was directed at eliminating the sebaceous hyperplasia. Session 2 was directed at eliminating the PDL-induced purpura (Figure 2).

For session 1, a single pulse was delivered using a 595 nanometer (nm) PDL (VBeam® Perfecta, Candela Laser Corp, Wayland, MA) with a 5-millimeter (mm) spot size, a fluence of 20.0 joules per square centimeter (J/cm²), a 3 millisecond (msec) pulse width, and a dynamic

cooling device duration of 30/20 (spray/delay). For session 2, we used our novel treatment protocol to eliminate post-procedural purpura.

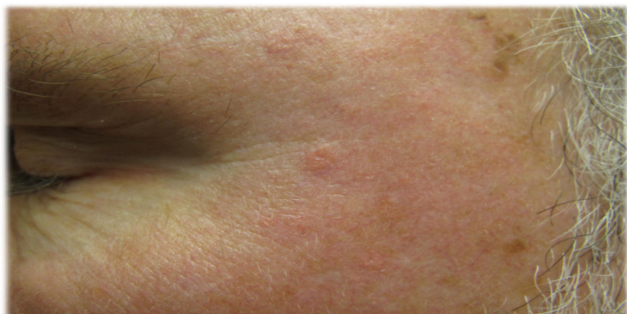

Figure 1: Pretreatment: enlarged yellow umbilicated papule on the left lateral orbit (sebaceous hyperplasia).

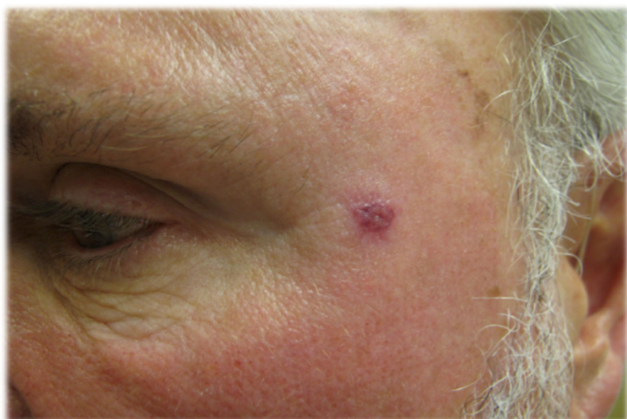

Figure 2: Post-treatment immediately following the 1st PDL treatment for sebaceous hyperplasia demonstrating significant post-PDL induced purpura.

The patient was treated 24-hours later (after the initial PDL treatment for sebaceous hyperplasia) with a single pulse using a 595 nm PDL (VBeam® Perfecta, Candela Laser Corp, Wayland, MA) a 7-mm spot size, a fluence of 9.0 J/cm², a 6 msec pulse width, and a dynamic cooling device duration of 30/20 (spray/delay). No specific aftercare instructions were recommended after each laser session.

Photographs were taken at baseline, after the first and second PDL treatment, and at final follow-up.

Results

The lesions of all five patients responded immediately to the first treatment of sebaceous hyperplasia with development of significant purpura and erythema (Figure 2). After 24-hours, the PDL-induced purpura was subsequently treated with moderate-fluence PDL. The PDL-induced purpura was immediately reduced by 85% after session 2 with only residual erythema and minimal residual purpura (Figure 3).

Two weeks after 1-3 combination treatment sessions (session 1 and 2), all five patients demonstrated near-complete resolution of

sebaceous hyperplasia with no signs of scarring or dyspigmentation. After one combination treatment session for the sebaceous hyperplasia, a 60% clearance rate was observed (Figure 4).

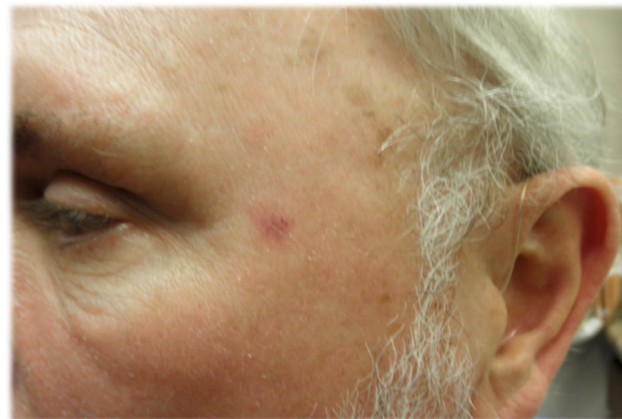

Figure 3: Post-treatment immediately following the 2nd PDL treatment for the purpura demonstrating a significant reduction in purpura.

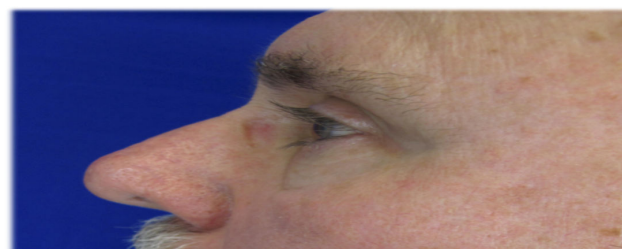


Figure 4: Two weeks after a single combination treatment with PDL demonstrating near-complete resolution of the sebaceous hyperplasia and complete resolution of purpura.

We found that 1-3 treatment sessions were often required for near-complete resolution of sebaceous hyperplasia. A small blister was observed in only one patient in our study. No hyper or hypopigmentation was observed. Mild pain (2-6 out of 10 pain score), purpura, and erythema were the only additional adverse effects observed. Our results demonstrate near-complete resolution of the sebaceous hyperplasia and complete resolution of the resulting post-PDL purpura within 72 hours after 1-3 combination treatment sessions with a combination of both high and moderate-fluence PDL.

Discussion

Historical treatment modalities for sebaceous hyperplasia, including cryotherapy, electrocauterization, curettage, surgical excision, and chemical ablation all have significant risk of scarring and dyspigmentation [1-3]. Laser therapy for sebaceous hyperplasia has been described in the literature previously and is an underutilized tool in dermatologist's armamentarium [1-4].

In 2004, No et al. introduced the use of a 1450-nm Diode laser for the treatment of sebaceous hyperplasia, demonstrating a significant

reduction in size after [1-3] treatments with minimal adverse effects [5]. Despite the promising results in this study, the 1450-nm Diode laser is rarely available to many physicians. In contrast, the PDL is a vascular workhorse in many dermatology offices worldwide and is easily accessible to many physicians for the treatment of sebaceous hyperplasia. Unfortunately, treatment of sebaceous hyperplasia with PDL therapy comes with the risk of significant purpura after adequate energy (fluence [J/cm^2]) is applied. In 1997, Schönemark et al. first introduced the use of PDL for the treatment of sebaceous hyperplasia with excellent results [1]. Unpublished data by Aghassi et al. demonstrated no significant absorption by the sebaceous gland lipids using the 585-595 nm visible light spectrum, suggesting that vasculature plays an important role in eradication of sebaceous glands [3,4]. In 2000, Aghassi et al. used confocal microscopy to reveal a prominent "crown" of blood vessels surrounding the sebaceous gland before and after treatment with PDL [3,4]. The hemoglobin-rich vasculature surrounding the sebaceous gland is the targeted chromophore for high-fluence PDL and thus adequately absorbs the laser energy [3,4]. This triggers coagulation necrosis of the vessel wall and inevitably leads to destruction of the sebaceous gland. This phenomenon was visualized by Aghassi et al. with the use of confocal microscopy after a combination of three stacked pulses of 585 nm PDL, at an energy dose of $7 \text{ J}/\text{cm}^2$ [3,4].

In our study, we increased the fluence to $20 \text{ J}/\text{cm}^2$, with the expectation that the significant energy would trigger further coagulation necrosis of the surrounding vasculature with the tradeoff of producing more post-PDL purpura. It was this purpura that prompted the use of an additional session of moderate-fluence PDL. For the treatment of sebaceous hyperplasia, a single high-fluence pulse using short pulse duration (msec) was chosen after considering the risk of nonspecific thermal injury to surrounding tissue beyond the selective photothermolysis of blood vessels. Although PDL is a safe and effective treatment option for sebaceous hyperplasia, the development of purpura is an expected occurrence. Purpura is often the limiting factor for the use of this treatment modality in clinical practice. In today's modern society, most patients typically prefer non-invasive treatment options with minimal downtime, rendering post-PDL purpura as an unacceptable result. If left untreated, purpura typically resolves within 7-14 days and this is often unacceptable for many patients [6]. It is for this very reason that we developed a novel treatment protocol for the treatment of both sebaceous hyperplasia and post-PDL purpura with a combination of high and moderate-fluence PDL, thus minimizing prolonged downtime in cosmetically sensitive patients. The treatment of purpura with vascular lasers is a common practice and has been thoroughly described in the literature over the years [6]. As mentioned above, the observed purpura arises as a result of the high-fluence PDL requirement needed to adequately and effectively heat the surrounding vasculature of the targeted sebaceous gland. We successfully eliminated 85% of the post-PDL purpura with a single moderate-fluence PDL treatment ($9 \text{ J}/\text{cm}^2$, 6 msec, and a 7 mm spot). The adverse effects were limited to erythema, edema, and purpura, with only one patient developing a small blister. Although the incidence of adverse effects are relatively low in our study, the use of

high-fluence PDL followed 24 hours later by moderate-fluence PDL may slightly increase the risk of developing tissue necrosis. Careful consideration must be used and the patient must be fully informed about the risk of tissue necrosis prior to subsequent treatment. Although we did not experience any significant adverse effects with our protocol settings, we cannot reliably predict the treatment response in every patient. All patients in our study were Fitzpatrick skin type II -III. None of these patients experienced any signs of dyspigmentation following treatment, but we strongly recommend against the use of high-fluence PDL in patients with Fitzpatrick skin type IV-VI due to the significant risk of hypopigmentation. Until now, a combination treatment protocol for both sebaceous hyperplasia and resulting post-PDL purpura has never been described. We are confident that this novel treatment protocol with PDL will offer clinicians a safe and effective treatment option with minimal downtime in cosmetically sensitive patients.

Conclusion

Treatment of sebaceous hyperplasia with PDL offers a safe and effective treatment modality in patients with Fitzpatrick skin type I-III, targeting the underlying vasculature associated with the sebaceous gland. The high-fluence and short pulse duration required to reduce the size of sebaceous hyperplasia often leads to the development of purpura. This post-PDL purpura is successfully treated with moderate-fluence PDL 24-hours later. The PDL is thought to be effective in the treatment of purpura principally due to the abundance of free red blood cells containing the target chromophore, hemoglobin. Hemoglobin is easily destroyed with moderate-fluence PDL and rapidly cleared from the skin with no evidence of long-term sequelae. In the future, we believe that many other conditions requiring high-fluence PDL that leads to purpura may also be treated with a subsequent lower-dose treatment to remove any laser induced purpura within 72 hours.

References

1. Schönemark MP, Schmidt C, Raulin C (1997) Treatment of Sebaceous Gland Hyperplasia with the Pulsed Dye Laser. *Lasers Surg Med* 21: 313-316.
2. Alster TS, Tanzi EL (2003) Photodynamic Therapy with Topical Aminolevulinic Acid and Pulsed Dye Laser Irradiation for Sebaceous Hyperplasia. *J Drugs Dermatol* 2: 501-504.
3. Aghassi D, González E, Anderson RR, Rajadhyaksha M, González S (2000) Elucidating the pulsed-dye laser treatment of sebaceous hyperplasia in vivo with real-time confocal scanning laser microscopy. *J Am Acad Dermatol* 43: 49-53.
4. González S, White WM, Rajadhyaksha M, Anderson RR, González E (1999) Confocal Imaging of Sebaceous Gland Hyperplasia In Vivo to Assess Efficacy and Mechanism of Pulsed Dye Laser Treatment. *Lasers Surg Med* 25: 8-12.
5. No D, McClaren M, Chotzen V, Kilmer SL (2004) Sebaceous Hyperplasia Treated With a 1450-nm Diode Laser. *Dermatol Surg* 30: 382-384
6. Morton LM, Smith KC, Dover JS, Arndt KA (2013) Treatment of purpura with lasers and light sources. *J Drugs Dermatol* 12: 1219-1222.