

A Histological Study on the Treatment of Acne Scars with Fractional Radiofrequency: Preliminary Findings

Tokuya Omi^{1,2*}, Shigeru Sato³, Chikako Kaminaka^{4,5}, Yuki Yamamoto^{4,5}, Seiji Kawana² and Zenya Naito⁶

¹Department of Dermatology, Queen's Square Medical Center, Yokohama, Japan

²Department of Dermatology, Nippon Medical School, Tokyo, Japan

³Division of Morphological and Biomolecular Research, Graduate School of Medicine, Nippon Medical School, Tokyo, Japan

⁴Department of Dermatology, Wakayama Medical University, Wakayama, Japan

⁵Department of Cosmetic Dermatology and Photomedicine, Wakayama Medical University, Wakayama, Japan

⁶Departments of Pathology and Integrative Oncological Pathology, Nippon Medical School, Tokyo, Japan

Abstract

Background and aims: After the inflammatory stage of severe acne vulgaris, atrophic scarring may occur this is problematic to both the patient and surgeon. A variety of treatment techniques including ablative and nonablative lasers have been used, however results have been inconsistent with both over- and under-treatment. Fractional radiofrequency (RF) has recently attracted attention in this field. The present study evaluated changes in the dermal morphology and ultrastructure one month post-fractional RF treatment.

Patients and methods: The study subjects were 4 females and 2 males (Fitzpatrick skin type IV, mean age 39.3 yr) with moderate to severe acne scarring. They were treated with a single session of fractional RF (peak energy level of 25 J). Biopsies were obtained before, immediately after and 1 month after treatment, and examined under both light and transmission electron microscopy.

Results: Before treatment, the dermis in all patients demonstrated dense connective tissue with hyperplasia of elastic fibers with sporadic depositions of elastin. Histological and ultrastructural evaluation at one month after fractional RF treatment revealed remodeling of the dermis, accompanied by elastic fiber remodeling, to give a more normal-looking morphology.

Conclusions: Fractional-type RF therapy is promising, not only as a means of treating acne as reported previously, but also in the treatment of acne scars through remodeling of the dermis to replace acne scar-associated morphological and ultrastructural irregularities with a more normal architecture.

Keywords: Fractional RF; Dermal remodeling; Atrophic scar; Collagenesis

Introduction

In the ordinary course of wound healing after an outbreak of acne, the inflammatory stage of acne vulgaris may often be followed by an atrophic scar, rather than keloid or hypertrophic scar formation [1]. This is probably because the healing process of acne-associated lesions following inflammation involves a change in the dermis specifically associated with the characteristics of this particular dermal lesion. Lasers, fractional and unfractionated, ablative (CO₂) and a variety of nonablative systems, have been reported for the treatment of acne scars [2-5]. However, the ablative laser approach is associated with the problem of a high incidence of hyperpigmentation, especially in Japanese skin types III and IV, and the nonablative approach suffers in terms of the efficacy in reaching the deeper layers of the dermis, absolutely required in the treatment of acne scars. The fractional CO₂ laser and radiofrequency systems (RF) have been reported as creating the desired controlled dermal damage down to the deeper layers of the dermis and have been successfully used in the treatment of atrophic-type acne scars, in addition to their use in the treatment of acne (an established indication of these approaches), with numerous clinical reports published in the literature [6,7]. The present study presents the histological and ultrastructural findings of changes in the dermal architecture at one month following fractional RF treatment for acne scars.

Having had the study and its potential results explained to them, the subjects gave written informed consent to participate. The study was approved by the Ethics Committee of the Queens Square Medical Center.

Materials and Methods

Fractional RF was applied to 6 patients with moderate to severe atrophic acne scars (4 females and 2 males aged 32-54 years, with a mean age of 39.3 years). All patients had a single treatment session. The fractional RF device used was the eMatrix system (Syneron, Irvine, CA), which was used with Program 3 (peak energy level: 25J). Patients were advised to wash their face gently on the evening of treatment without scrubbing, and wash normally thereafter. No post-care regimen was advised, apart from the usual washing of the face with a hypoallergenic soap and application of a UVA/B sunscreen with an SPF>30. Makeup could be applied from postop day 2.

Three-millimeter punch biopsies were obtained before the RF treatment, immediately after the RF treatment, and 1 month after the RF treatment. Each specimen was fixed in glutaraldehyde (2.5%) and then in osmium tetroxide (1%). After dehydration through a graded

***Corresponding author:** Tokuya Omi, Department of Dermatology, Queen's Square Medical Center, 2-3-5 Minatomirai, Yokohama, Japan, Tel: +81-45-682-4112; E-mail: t.omi@queens-sq.or.jp

Received December 19, 2013; **Accepted** January 04, 2014; **Published** January 11, 2014

Citation: Omi T, Sato S, Kaminaka C, Yamamoto Y, Kawana S, et al. (2014) A Histological Study on the Treatment of Acne Scars with Fractional Radiofrequency: Preliminary Findings. J Clin Exp Dermatol Res 5: 203. doi:10.4172/2155-9554.1000203

Copyright: © 2014 Omi T, et al. This is an open-access article distributed under the terms of the Creative Commons Attribution License, which permits unrestricted use, distribution, and reproduction in any medium, provided the original author and source are credited.

ethanol series, the specimens were embedded in Epon 812 (Oken Shoji Co., Ltd, Tokyo, Japan), stained with toluidine blue, and examined with light microscopy. Ultrathin sections were prepared with an Ultracut N ultramicrotome (Reichert-Nissei, Tokyo, Japan) and a diamond knife. Sections were stained with oolong tea extract (OTE) for connective tissue and with uranyl acetate and lead citrate for electron-microscopic examination (75 kV, Hitachi H-7500, Hitachi, Tokyo, Japan) [8].

Results

All patients completed the study, including the follow-up. Immediately after the RF treatment the end point was mild erythema, which gradually increased until about 12 hours after treatment and then spontaneously evolved. By 24 hours post-treatment, erythema had completely disappeared. No patient reported discomfort or any other adverse reaction.

Histology of the acne scar

Since the patients examined in this study showed similar histological findings at each of the sampling times, the findings common to all patients are described below.

The acne scar before fractional radiofrequency irradiation was rich in connective tissue containing capillaries and fibroblasts within the dermis with hyperplasia of the elastic fibers and small string-form structures (Figure 1). In the electron microscopic ultrastructural observation, numerous outgrowths of elastic fibers were observed in the superficial dermis in the region of the acne scars (Figure 2). Examination of the specimens stained with OTE revealed the presence of elastin in the elastic fibers as electron-dense spherical or rod-shaped masses. In addition, when the capillaries, fibroblasts and elastic fibers in the dermis were examined, the fibroblasts were found to assume a thin and long form or a spherical form, but their cytoplasm was small relative to the size of the nuclei and the development of organelles was poor (Figure 3). The elastic fibers of the skin were characterized by sporadic deposition of elastin in the elastic microfilaments.

Histological changes after the fractional RF treatment

A large number of thin and long fibroblasts were noted in the dermis immediately after fractional RF session. However, ultrastructural examination revealed no disturbed arrangement of the collagen fibers

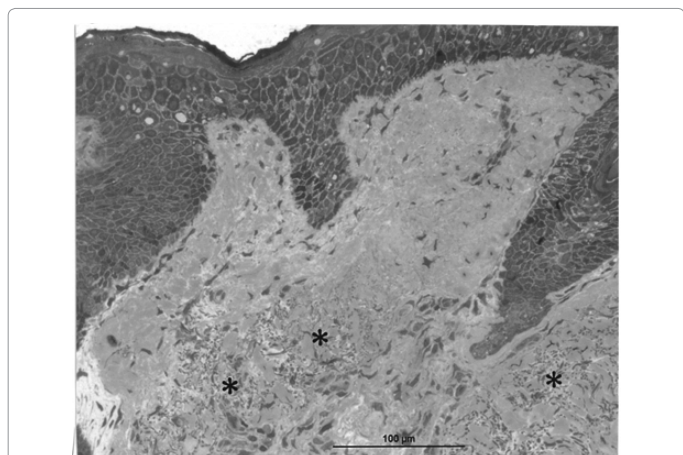


Figure 1: Tissue from an acne scar before irradiation. A matrix rich in capillaries and fibroblasts can be observed in connective tissue within the dermis, with hyperplasia of the elastic fibers seen in some areas (*: small string-form elastic fiber structures showing marked chromatic responses). (Toluidine blue staining, scale bar 100 μm).

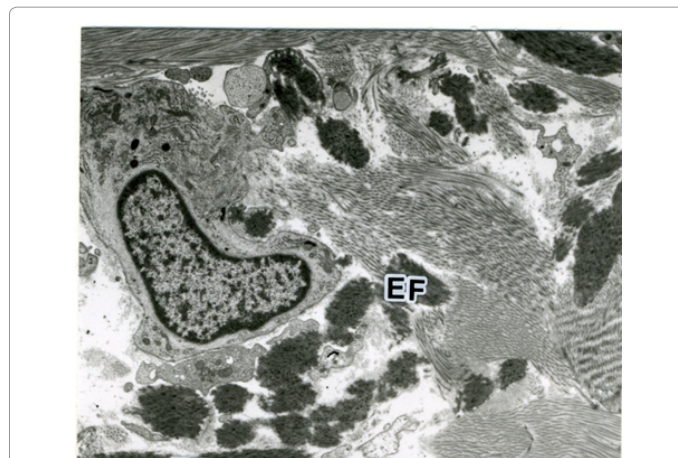


Figure 2: Transmission electron photomicrograph of acne scar tissue before irradiation. Numerous outgrowths of elastic fibers can be observed in the superficial dermis in the region of the acne scars. Examination of the specimens stained with oolong tea extract (OTE) reveal the presence of elastin in the elastic fibers as electron-dense spherical or rod-shaped masses. (EF, elastic fiber. Scale bar, 3 μm).

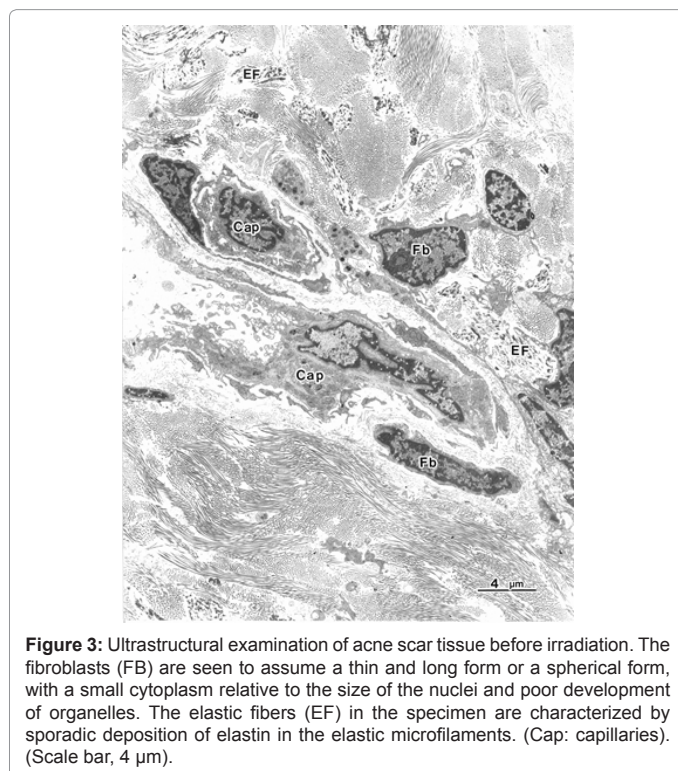


Figure 3: Ultrastructural examination of acne scar tissue before irradiation. The fibroblasts (Fb) are seen to assume a thin and long form or a spherical form, with a small cytoplasm relative to the size of the nuclei and poor development of organelles. The elastic fibers (EF) in the specimen are characterized by sporadic deposition of elastin in the elastic microfilaments. (Cap: capillaries). (Scale bar, 4 μm).

or elastic fibers as would be the case if electrocoagulation had occurred (Figures 4 and 5). Overgrowth of elastic fibers was noted. In contrast to the nearly normal elastic fibers elsewhere in the photomicrograph, the elastic fibers on the upper side of the same figure show massive elastin accumulation, a causative factor associated with the tethering of atrophic acne, scars together with the already accepted hyperfibrosis of the collagen fibers.

When the dermis was observed at one month after the fractional RF session interstitial edema was seen around the capillaries, accompanied by a disturbed collagen fiber arrangement (Figure 6). The fibroblasts were surrounded by well-aligned collagen fibers, and

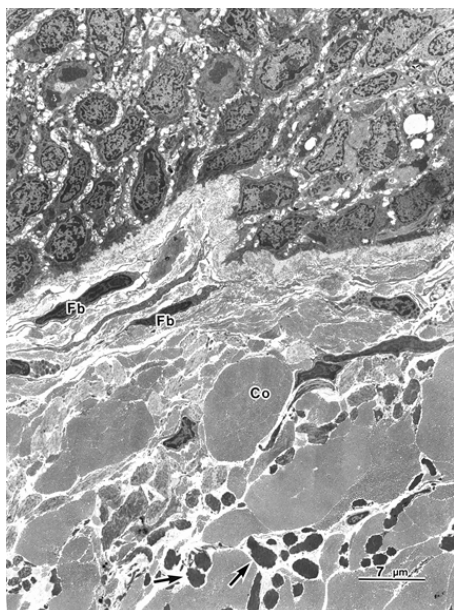


Figure 4: Ultrastructural changes immediately after fractional RF application. No disturbance in the arrangement of the collagen fibers (Co) or elastic fibers (Ef) can be seen, however some outgrowth of elastic fibers was noted in the deeper dermis (Arrows). (Scale bar, 7 μm).

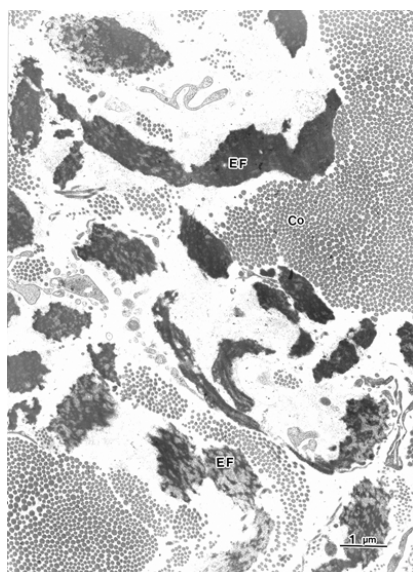


Figure 5: Ultrastructural changes immediately after fractional RF application at a higher magnification. Like Figure 4, no disturbance in the arrangement of the collagen fibers (Co) can be seen. In contrast to the nearly normal elastic fibers (Ef) (lower side), the elastic fibers on the upper side of the same figure show massive elastin accumulation. (Scale bar, 1 μm).

had well-developed rough endoplasmic reticula (RER), suggestive of active protein synthesis associated with the remodeling process (Figure 7). Furthermore, the elastic fibers appeared to be more-or-less normal, without showing excessive elastin deposition (Figure 7).

Discussion

Acne scars can be divided into atrophic-type and hypertrophic-type scars. The former includes ice pick scars, box-type scars and atrophic

macular-type scars, while the latter includes keloids and hypertrophic scars. As to why the post-acne atrophic course is seen much more frequently than hypertrophic or keloid formation, some investigators have suggested the involvement of inflammatory reactions, but there are many open questions over the high frequency of the atrophic course specifically associated with the healing of acne lesions [1].

In the present study, some parts of the acne scars showed hyperplasia of elastic fibers (small string-form structures showing a marked chromatic response to staining with toluidine blue). In the intact skin, thin and long elastic fibers were scattered throughout the

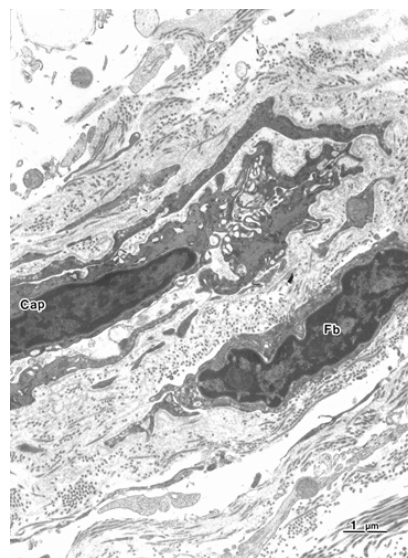


Figure 6: Ultrastructural changes one month after fractional RF application at high magnification. Interstitial edema can be seen around the capillaries (Cap), accompanied by a disturbed collagen fiber arrangement (FB, fibroblast). (Scale bar, 1 μm).

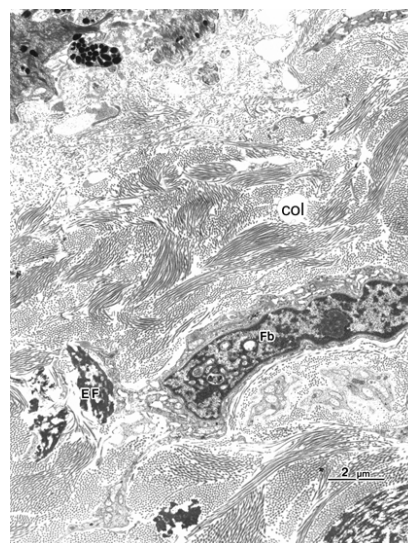


Figure 7: Ultrastructural changes one month after fractional RF application at a lower magnification. Well-developed rough endoplasmic reticula can be seen within the fibroblast (FB), suggestive of active protein synthesis and collagenesis. Bundles of collagen fibers surround the fibroblast (col). The elastic fibers (EF) appear to be more-or-less normal, without showing excessive elastin deposition. (Scale bar, 2 μm).

dermis, and accumulation of many fibers (seen in the acne scar-affected skin) was absent. The hyperplasia and distribution of elastic fibers seemed to be associated with the occurrence of irregularities unique to the area after the healing of acne lesions.

Ultrastructurally, numerous outgrowths of elastic fibers were observed in the superficial dermis in the region of the acne scars. Examination of the specimens stained with OTE revealed the presence of elastin in the elastic fibers as electron-dense spherical or rod-shaped masses. The fibroblasts in the dermis assumed a thin and long form or a spherical form, but their cytoplasm was small relative to the size of the nuclei and their organelles were poorly developed. The elastic fibers of the skin were characterized by sporadic elastin deposition in the elastic microfilaments. These histological findings suggest that atrophic acne scars are characterized by hyperplasia of the intradermal elastic fibers accompanied by mass-forming elastin deposition, and that remodeling of the dermis including these elastic fibers is needed for the treatment of acne scar, in particular, the deeper portion of the dermis. It may therefore be said that when any form of treatment is applied for acne scars, rather than the treatment of acne itself, the effect of the device being used must be delivered deeper into the dermis, to elicit deeper dermal remodeling of the disturbed architecture specific to acne scars.

The effectiveness of ablative laser treatment of acne scars has been reported [3] with lasers in the near-infrared region (e.g., 1320 nm, 1450 nm and 1540 nm) reportedly especially effective on both acne and acne scars [4,5]. Because lasers in this waveband range have been reported to heat the deeper layers of the dermis, it is considered that these lasers alleviate acne by injuring the sebaceous glands through thermal degeneration. Furthermore, since thermal effects stimulate dermal remodeling, lasers at these wavelengths have been reported to have a rejuvenation effect on the dermal matrix via remodeling induced by photothermal damage, and this same mechanism and penetrative capability could be used to explain their efficacy on acne scars. Lasers at wavelengths of 1400-1600 nm can also penetrate the skin deeply, but are associated with higher photothermal activity due to increased absorption in water, with an increased likelihood of being associated with adverse reactions such as erythema, edema and hyperpigmentation.

To reduce these adverse reactions, fractionation of the laser beam into a series of microbeams was developed, i.e., fractional laser technology whereby the treatment area has a large percentage of untreated tissue surrounding the grid-like formation of microbeams. This untreated tissue assists with the wound repair mechanism, allowing for faster healing and shorter downtime compared with conventional laser technology. Reports are available on the effectiveness of fractional lasers of various wavelengths primarily pertaining to the effect of rejuvenation [6,9,10]. These lasers also seem to be effective for acne and post-acne scars or pigmented lesions. Recently, fractional RF has also been introduced, exerting its effect through transmission of heat to the deeper layers of the dermis, and its efficacy on acne and acne scars has been reported clinically [11].

The device employed in the present study is described as a so-called bipolar RF system, whereby the delivery and return electrodes are incorporated in the hand piece [7,12]. RF-based technologies depend for their effect of the resistance or impedance of target tissue to the RF energy, resulting in the creation of heat through Joule's law, and delivery of electrothermal damage, with subsequent greater heat diffusion to deeper tissues as compared to laser-based technologies. The effectiveness of RF energy for the treatment of acne and acne scars has also been reported clinically [13]. Hence we designed the present

study to examine what changes RF energy brought about in the dermal architecture of acne scar tissues.

In the histological evaluation of our cases, there was no disturbance in the arrangement of collagen fibers or elastic fibers immediately after the irradiation, although some elongation of fibroblasts was seen ultrastructurally, possible as a result of the controlled heat produced by the electrothermal effect of the RF energy passing through the tissue. When the dermis of the patients was histologically examined one month after the irradiation, interstitial edema was noted around the capillaries, accompanied by disturbed collagen fiber arrangement. The fibroblasts had well-developed rough-surfaced endoplasmic reticulum, suggestive of active protein synthesis and potential increase in collagen synthesis. This is a possible explanation for the 'plumming up' of the atrophic areas in acne scars. Unlike the condition before treatment, at one month post-treatment the elastic fibers were more-or-less normal, without excessive elastin deposition. Both of the effects in the collagen and elastic fibers, which clearly resulted from the remodeling process induced by the electrothermal effect mentioned already, combined to help in the release and reformation of the fibrous tether associated with atrophic acne scars.

According to a previous report on the histological changes after an attempt at rejuvenation with a device similar to the one used in the present study both the epidermis and the dermis showed an approximately intact structure 24 hours after the therapy at an energy level of 8 J [14]. In the present study using a higher energy level (25 J), there was still no disturbance in the arrangement of the fibers within the dermis even immediately after the irradiation, even though there was undoubtedly a mild RF-mediated electrothermal effect.

Hantash et al. reported that no inflammatory reaction was noted immediately after the fractional RF irradiation and that the inflammatory reaction increased over time thereafter until the 14th day, with generalized inflammatory reactions noted on the 28th day, primarily affecting the thermally denatured area [15]. According to the same report, significant increase of the amount of elastin (positive staining with EVG) was noted by 10 weeks after the irradiation. In the present study, edematous changes in the dermis were absent immediately after the irradiation, but increased dermal volume was noted one month after the irradiation. This finding is very noteworthy in comparison to a previous report on dermal remodeling which demonstrated intense edematous changes seen with laser treatment immediately after the irradiation [4].

The well-developed RER observed within the fibroblasts one month after the irradiation in the present study is interpreted as indicating activation of the fibroblasts. This is consistent with a previous report on rejuvenation with LLLT [16]. Disappearance of elastin deposition and resumption of an approximately normal elastic fiber structure at one month after the irradiation are also consistent with the report by Hantash et al. [15]. However, unlike the findings reported by Hantash et al. who noted new formation of fibrous components by 10 weeks after the irradiation, we noted a similar finding within just one month after the irradiation [15]. This discrepancy is estimated to be attributable to differences in the patients' age groups, energy level or the method of histological observation (ultrastructural observation under an electron microscope in the present study).

This study was limited by the small number of subjects, which cannot allow generalization of the findings without a much larger patient population in a controlled study. However, the authors believe the results are interesting enough to warrant reporting herein, and could pave the way for a future larger scale study in which clinical

results should be compared with the histological changes. Taken together, the study findings suggest that fractional RF, which can act on the dermis, especially the deeper layers, of the dermis and stimulate remodeling within the dermal tissues associated with scar formation post-inflammatory acne, is expected to be very useful as a means of treating acne scars arising from the recognized hyperfibrosis of collagen fibers, coupled with rectification of the elastic fiber degeneration specifically shown in the present study, and especially in the deeper layers of the dermis.

Conclusions

Fractional-type RF therapy is promising, not only as a means of treating acne as reported previously, but also in the treatment of atrophic acne scars through remodeling of the dermis to replace acne scar-associated morphological and ultrastructural irregularities with a more normal architecture, particularly in the case of elastic fibers and over-deposition of elastin.

References

1. Cunliffe WJ, Gollnick HPM (2001) Clinical features of acne. In: *Acne -diagnosis and management*. Martin Dunitz 49-67.
2. Khatri KA, Mahoney DL, McCartney MJ (2011) Laser scar revision: A review. *J Cosmet Laser Ther* 13: 54-62.
3. Babilas P, Schremel S, Eames T, Hohenleutner U, Landthaler M, et al. (2011) Experience with non-ablative fractional photothermolysis with a dual-mode laser device (1,440/1,320 nm): no considerable clinical effect on hypertrophic/ acne scars and facial wrinkles. *Lasers Med Sci* 26: 473-479.
4. Omi T, Kawana S, Sato S, Takezaki S, Honda M, et al. (2005) Cutaneous immunological activation elicited by a low-fluence pulsed dye laser. *Br J Dermatol* 153: 57-62.
5. Cho SB, Lee SJ, Cho S, Oh SH, Chung WS, et al. (2010) Non-ablative 1550-nm erbium-glass and ablative 10 600-nm carbon dioxide fractional lasers for acne scars: a randomized split-face study with blinded response evaluation. *J Eur Acad Dermatol Venereol* 24: 921-925.
6. Omi T, Kawana S, Sato S, Bonan P, Naito Z (2011) Fractional CO₂ laser for the treatment of acne scars. *J Cosmet Dermatol* 10: 294-300.
7. Elsaie ML, Choudhary S, Leiva A, Nouri K (2010) Nonablative radiofrequency for skin rejuvenation. *Dermatol Surg* 36: 577-589.
8. Sato S, Sasaki Y, Adachi A, Dai W, Liu XL, et al. (2003) Use of oolong tea extract (OTE) for elastin staining and enhancement in ultrathin sections. *Med Electron Microsc* 36: 179-182.
9. Hedelund L, Haak CS, Togsverdt-Bo K, Bogh MK, Bjerring P, et al. (2012) Fractional CO₂ laser resurfacing for atrophic acne scars: a randomized controlled trial with blinded response evaluation. *Lasers Surg Med* 44: 447-452.
10. Ong MW, Bashir SJ (2012) Fractional laser resurfacing for acne scars: a review. *Br J Dermatol* 166: 1160-1169.
11. Lolis MS, Goldberg DJ (2012) Radiofrequency in cosmetic dermatology: a review. *Dermatol Surg* 38: 1765-1776.
12. Brightman L, Goldman MP, Taub AF (2009) Sublative rejuvenation: experience with a new fractional radiofrequency system for skin rejuvenation and repair. *J Drugs Dermatol* 8: s9-13.
13. Lee SJ, Goo JW, Shin J, Chung WS, Kang JM, et al. (2012) Use of fractionated microneedle radiofrequency for the treatment of inflammatory acne vulgaris in 18 Korean patients. *Dermatol Surg* 38: 400-405.
14. Hruza G, Taub AF, Collier SL, Mulholland SR (2009) Skin rejuvenation and wrinkle reduction using a fractional radiofrequency system. *J Drugs Dermatol* 8: 259-265.
15. Hantash BM, Ubeid AA, Chang H, Kafi R, Renton B (2009) Bipolar fractional radiofrequency treatment induces ne elastogenesis and neocollagenesis. *Lasers Surg Med* 41: 1-9.
16. Takezaki S, Omi T, Sato S, Kawana S (2006) Ultrastructural observations of human skin following irradiation with visible red light-emitting diodes(LEDs): Apreliminary in vivo report. *Laser Therapy*, 14: 153-160.