

## A Comparison between Methicillin Resistant Organism and Non-Methicillin Resistant Organism in 2-Stage Reimplantation of Periprosthetic Hip Infection

Byung-woo Min, Kyung-Jae Lee, Jin Hyun Park, Ki-cheor Bae, Si Wook Lee and Jung Hoon Choi

Dong San Medical Center, Keimyung University School of Medicine, Daegu, Korea

### Abstract

**Background:** The prevalence of resistant organisms has increased in periprosthetic hip infection. The purpose of this study is to evaluate the effectiveness of staged reimplantation for the treatment of periprosthetic hip infection caused by methicillin resistant microorganisms.

**Methods:** We performed a retrospective case-control study on 25 consecutive patient (15 men, 10 women) who had periprosthetic hip infection treated using a 2-stage reimplantation.

**Results:** 13 patients infected by methicillin resistant microorganisms were compared with 12 patients infected by non-methicillin resistant microorganisms. The 2-stage reimplantation was possible in all patients. At a mean follow-up of 4.8 years, no significant differences were found between 2 groups with age, sex, body mass index, diabetes, primary diagnosis and kind of primary hip arthroplasty. But methicillin resistant group had much longer period with intravenous antibiotics and oral antibiotics. Erythrocyte sedimentation rate (ESR) and C-reactive protein (CRP) was much higher in methicillin resistant group after 2-stage reimplantation. Harris Hip Score was lower in methicillin resistant group after 2-stage reimplantation. There were 3 recurrent infections after 2-stage reimplantation in methicillin resistant group. But there was no recurrent infection in non-methicillin resistant group.

**Conclusion:** Periprosthetic hip infection caused by methicillin resistant bacterial strain need cautious care of operation and infection control.

**Keyword:** Hip; Periprosthetic infection; Methicilli; 2 - Stage reimplantation

### Introduction

Deep infection after hip arthroplasty is one of the severe complications in orthopedic surgery, and remains as a big challenge to orthopedic surgeons [1]. Although there are a variety of treatment methods for deep infection after hip arthroplasty, the most common and effective treatment method is 2-stage reimplantation [1,2]. 2-stage reimplantation consist of debridement and removal of implant, insertion of antibiotics-loaded spacer and then final implantation. In recent years, periprosthetic hip infection caused by methicillin resistant microorganisms among pathogens inducing deep infection has shown an increasing trend [3,4]. However, 2-stage reimplantation has been performed without considering difference between treating infections caused by methicillin and non-methicillin resistant microorganisms after hip arthroplasty. Several studies have reported the results of treating deep infection caused by methicillin resistant microorganisms after hip arthroplasty [5-8]. Also epigenetic mechanism of methicillin resistant bacteria infection was reported [9-12]. But the difference between treating infections caused by methicillin and non-methicillin resistant microorganisms still remains controversial.

The purpose of this study is to compare and analyze the results of treating infections caused by methicillin and non-methicillin resistant microorganisms in patients who underwent 2-stage reimplantation for periprosthetic hip infection.

### Materials and Methods

This study comprised 25 patients (15 men, 10 women; 9 bipolar hemiarthroplasties, 12 total hip arthroplasties, 4 revision total hip arthroplasties) who underwent 2-stage reimplantation for periprosthetic hip infection from November 1, 2000 to June 31, 2011, with minimal

follow-up of two years. The mean follow-up period was 4.8 years. Our institutional review board approved the study protocol and all patients gave informed consent prior to their inclusion in the study.

Subjects falling one or more than one of the following criteria were diagnosed as deep infection: those who had more than two same microorganisms detected in culture tests of aspirated fluid from the hip joint and tissues around the hip joint after hip arthroplasty; those with purulent joint fluid; those who suspected of acute periprosthetic hip infection; those with formation of a fistulous tract connected to the hip joint prosthesis [13].

Of 25 subjects, 13 (52%) were referred to our hospital due to deep infection after primary hip arthroplasty from other hospitals, 12 (48%) underwent primary hip arthroplasty in our hospital. Infected prostheses were detected in 12 (48%) total hip arthroplasties, 9 (36%) bipolar hemiarthroplasties, and 4 (16%) revision total hip arthroplasties. Previous causes for primary hip arthroplasties excluding revision arthroplasties were avascular necrosis of femoral head in 8 cases, femoral neck fracture in 6 cases, osteoarthritis of the hip joint in

**\*Corresponding author:** Kyung-Jae Lee, Department of Orthopedic Surgery, School of Medicine, Keimyung University, 56 Dalseong-ro, Jung-gu, Daegu, Korea, Tel: +82-53-250-8161; Fax: +82-53-250-7205; E-mail: [oslee@dsmc.or.kr](mailto:oslee@dsmc.or.kr)

**Received** August 29, 2016; **Accepted** October 17, 2016; **Published** October 24, 2016

**Citation:** Min BW, Lee KJ, Park JH, Bae KC, Lee SW, et al. (2016) A Comparison between Methicillin Resistant Organism and Non-Methicillin Resistant Organism in 2-Stage Reimplantation of Periprosthetic Hip Infection. J Infect Dis Preve Med 4: 137. doi: [10.4172/2329-8731.1000137](https://doi.org/10.4172/2329-8731.1000137)

**Copyright:** © 2016 Min BW, et al. This is an open-access article distributed under the terms of the Creative Commons Attribution License, which permits unrestricted use, distribution, and reproduction in any medium, provided the original author and source are credited.

3 cases, intertrochanteric fracture in 2 cases, and rheumatoid arthritis of the hip joint and acetabular osteolysis in a case each. The cause for all revision arthroplasties in 4 cases was loosening of the acetabular cup followed after hip arthroplasties. 2-stage reimplantation included primary infection treatment modality performed after diagnosis of deep infection and revision arthroplasty performed after controlling infection, and all operations in this study were conducted by a single surgeon. One of or both acetabular cup and femoral stem suspected of infection were removed for controlling infection, and meticulous debridement was performed. Gram stain, aerobic and anaerobic bacterial cultures, fungal culture, and acid-fast bacillus stain and culture were done in infected tissues. To treat the acetabulum, exposed hip joint was washed and then, an articulating cement spacer was used. When no microorganisms were identified preoperatively, CMW3 (Bluecross, Depuy, USA) bone cement containing 1g gentamicin-sulfate in each 40 g was used. When microorganisms were detected, bone cement was used by mixing cephalosporin antibiotics with susceptibility.

When pathogens were identified after infection management and before revision arthroplasty, intravenous antibiotics with susceptibility were used. When no pathogens were identified, empirical antibiotic treatment was done using first-generation cephalosporins. The mean duration of intravenous antibiotic use was 5.6 weeks. In all patients, oral antibiotics were used after using intravenous antibiotics. The mean duration of oral antibiotic use was 3.2 months. Revision arthroplasty was performed when there was no clinical evidence suspected of infection and normalized erythrocyte sedimentation rate (ESR) and C-reactive protein (CRP) during at least two weeks without using antibiotics.

The mean interoperational period between infection treatment modality and revision hip arthroplasty was 8 months. For 6 patients at high risk for recurrence of infection during revision arthroplasty, frozen section biopsy was performed in tissues suspected of infection. Since all 6 patients had 0-1 polymorphonuclear leukocyte observed under a microscope at high magnification (x400) in more than 10 different parts, 2-stage reimplantation was conducted [14].

Gram stain, aerobic and anaerobic bacterial cultures, fungal culture,

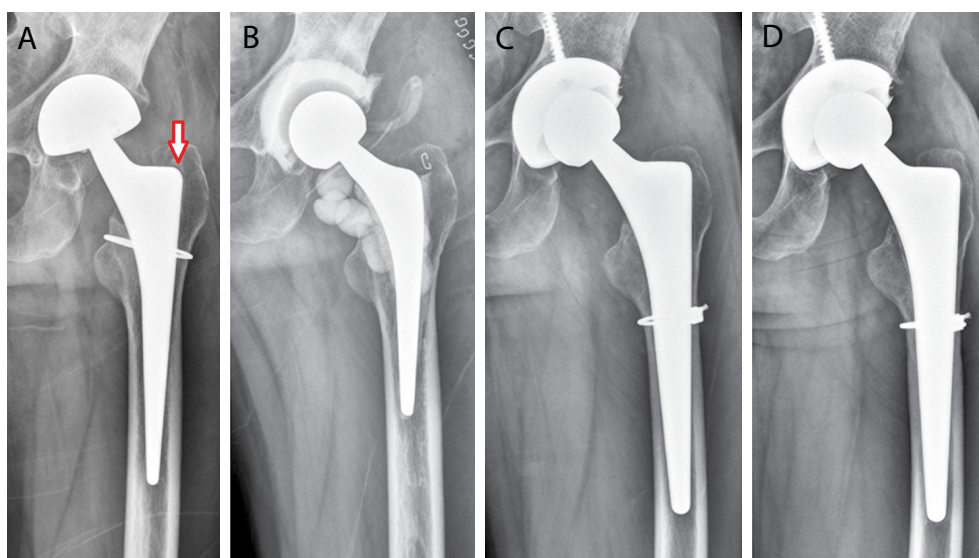
and acid-fast bacillus stain and culture were conducted in the tissues around the hip joint after removing bone cement and a temporary prosthesis used in infection treatment modality. Cementless artificial joints were used in all patients. After performing reimplantation, administration of antibiotics was discontinued when bacterial culture and pathological test were negative, and oral antibiotics were not used.

To compare treatment results of infections caused by methicillin and non-methicillin resistant microorganisms, this study analyzed pre- and post- clinical symptoms of infection treatment modality and revision hip arthroplasty, radiological findings, ESR, CRP, Harris hip score (HHS), patient's function and complication during insertion of the prosthesis, and recurrence rate. All statistical analyses were performed using SPSS ver. 12.0 (SPSS Inc., Chicago, IL, USA). A paired t-test was conducted to test for differences between two groups. P-values of less than 0.05 were considered statistically significant.

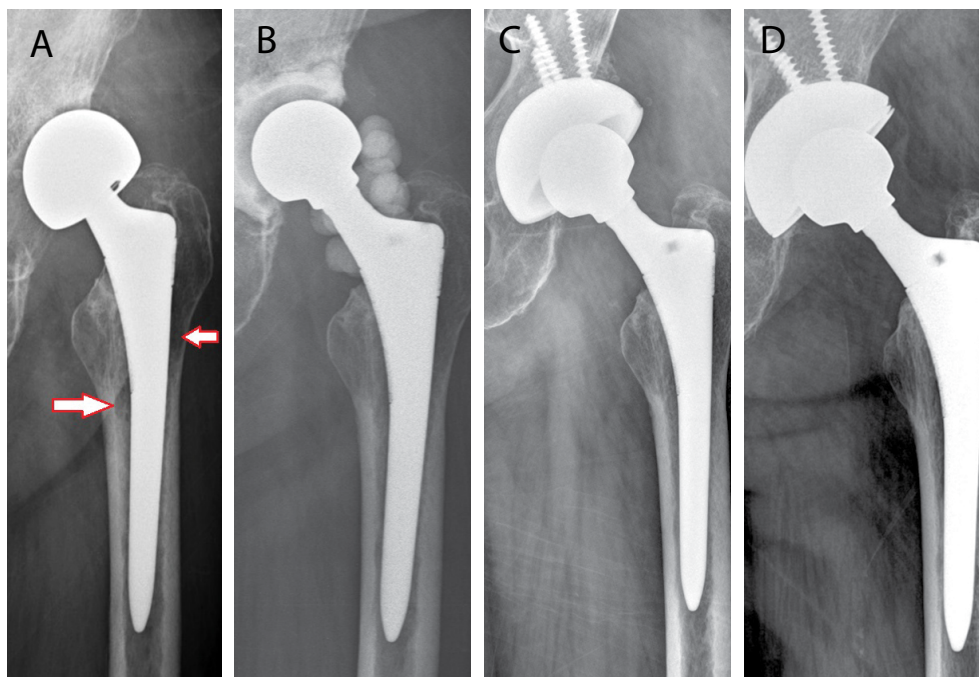
## Results

Of all 25 subjects, periprosthetic hip infection was caused by methicillin resistant microorganisms in 13 (52%) patients and non-methicillin resistant microorganisms in 12 (48%) patients. In the resistant group, pathogens were methicillin-resistant *Staphylococcus epidermidis* (MRSE) in 7 patients, and methicillin-resistant *Staphylococcus aureus* (MRSA) in 6 patients (Figures 1 and 2). In the non-resistant group, pathogens detected in 5 patients were methicillin-sensitive *Staphylococcus aureus* (MSSA) in 3 patients, and methicillin-sensitive *Staphylococcus epidermidis* (MSSE) and *Enterococcus faecalis* in a patient each. No microorganisms were found in the other 7 patients.

No significant differences were found between two groups with age, gender, BMI, presence of diabetes, causes and types of primary hip arthroplasty, interoperational period between infection treatment modality and revision hip arthroplasty, types of surgical modality, and use of bone cement beads ( $p > 0.05$ ). The duration of intravenous antibiotic use was 3.1 weeks longer in the resistant group than non-resistant group. Moreover, the duration of oral antibiotic use was 1.3 months longer at average in the resistant group, showing statistical significance



**Figure 1:** (a) 42-years-old male patient who had biopolar arthroplasty. He diagnosed as periprosthetic hip infection. (b) PROSTALAC was done for infection control. In culture study, MRSE was identified and vancomycin's added. (c) After 13 months, following 2<sup>nd</sup> revision hip arthroplasty was performed. (d) There was no complication at 4 years follow-up.

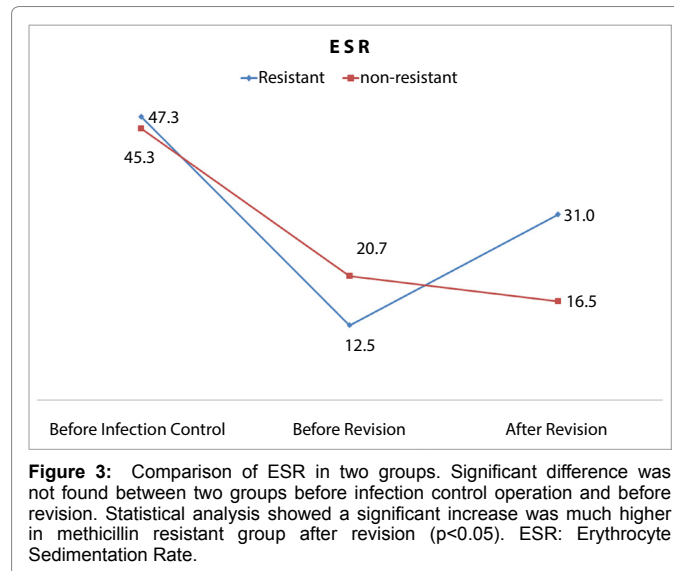


**Figure 2:** (a) 74-years-old female patient who had bipolar arthroplasty at local clinic. She diagnosed as periprosthetic hip infection. (b) PROSTALAC was done for infection control. In culture study, MRSA was identified and vancomycin's added. (c) After 12 months, following 2<sup>nd</sup> revision hip arthroplasty was performed. (d) There were no complications at 5 years follow-up.

	Resistant (n=13)	Nonresistant (n=12)	p
Age (years)	60.8	60.3	>0.05
Sex (male/female)	8 / 5	7 / 5	>0.05
Body mass index (kg/m <sup>2</sup> )	23.0	23.5	>0.05
Diabetes Mellitus	5	4	>0.05
<b>Primary diagnosis</b>			>0.05
Osteonecrosis	3	5	
Fracture	5	3	
Osteoarthritis	3	1	
Others	2	3	
<b>Primary hip arthroplasty</b>			>0.05
Total hip arthroplasty	5	7	
Bipolar hemiarthroplasty	6	3	
Revision hip arthroplasty	2	2	
Interoperational period (months)	7.9	8.2	>0.05
<b>Surgical modality used</b>			>0.05
Cup	9	7	
Stem	0	0	
Cup and Stem	4	5	
Cement bead used	9	9	>0.05
Intravenous antibiotics period (weeks)	7.1	4.0	<0.05
Oral antibiotics period (months)	3.8	2.5	<0.05

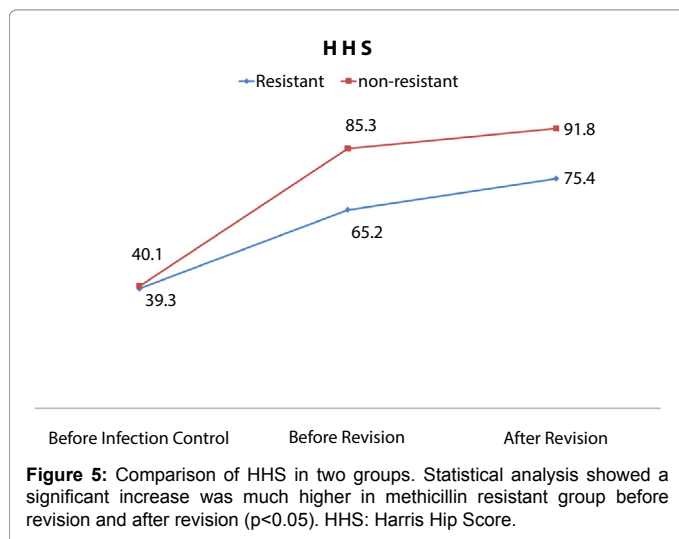
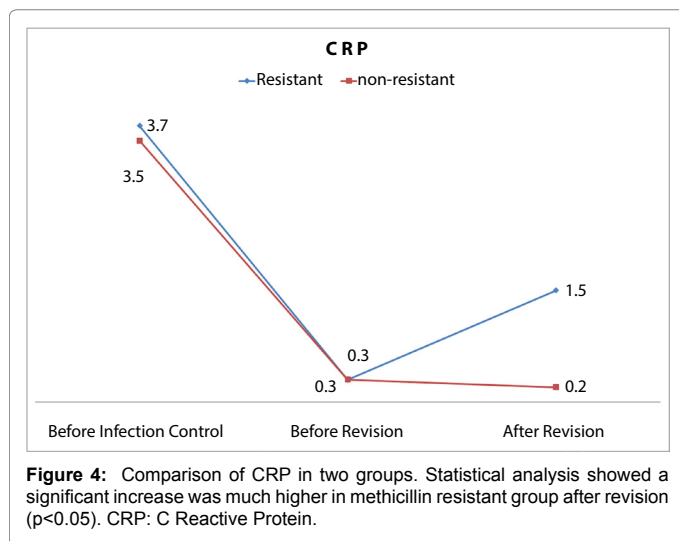
**Table 1:** Summary of Patient Demographics.

( $p < 0.05$ ) (Table 1). There was no difference between two groups in ESR and CRP before infection treatment and revision arthroplasty. After reimplantation, ESR and CRP were higher in the resistant group than non-resistant group at final follow-up. Statistical significance was found between two groups ( $p < 0.05$ ) (Figures 3 and 4). No difference was found in HHS between two groups before infection treatment, but



**Figure 3:** Comparison of ESR in two groups. Significant difference was not found between two groups before infection control operation and before revision. Statistical analysis showed a significant increase was much higher in methicillin resistant group after revision ( $p < 0.05$ ). ESR: Erythrocyte Sedimentation Rate.

HHS was lower in the resistant group before reimplantation and at final follow-up ( $p < 0.05$ ) (Figure 5). After reimplantation, infection recurred in 3 (23%) patients in the resistant group, but infection did not recur in any of the patients in the non-resistant group. Statistically significant difference was found between two groups ( $p < 0.05$ ). Of 3 cases in the resistant group, duration to recurrence was 4 months (range, 1-13) at average. Pathogens of relapsed infection were MRSE in 2 cases and MRSA in 1 case. Recurrent infection was caused by the same pathogen in 2 patients, but the pathogen was changed from MRSA to MRSE in 1 patient. After removing prosthesis due to recurrent infection, 1-stage reimplantation with bone cement was performed.



In 22 subjects without recurrent infections, radiologic examination revealed no findings of loosening or position change of prosthetic components, osteolysis at final follow-up. After reimplantation, posterior dislocation occurred in 1 patient in the resistant group. The patient was diagnosed as deep infection due to an increase in ESR and CRP and radiologic findings of osteolysis and erythema in surgical site. After removing prosthesis, 1-stage reimplantation was performed and MRSA was detected. 1 case of periprosthetic femoral fracture was developed in the resistant and non-resistant groups each open reduction and internal fixations were conducted.

## Discussion

The aims of treating deep infection after hip arthroplasty are to prevent the spread of infection and to recover the normal function of the hip joint. Although a variety of treatment methods for deep infection after hip arthroplasty have been introduced, the most common and effective treatment method is 2-stage reimplantation, and success rate is reported to range 82-96% [8,15-19].

In recent years, the prevalence of periprosthetic hip infection caused by methicillin resistant microorganisms such as MRSA or MRSE has increased, and a large number of studies have addressed

the results of treating deep infection caused by methicillin resistant microorganisms [3-8]. Voin et al. and Sanchez-Sotelo et al. [8] reported that no difference was found in treatment results of infections following hip arthroplasty according to pathogen resistance to methicillin.

In a study of Kilgus et al. [5] implant success rate was 81% in 16 patients with periprosthetic hip infection caused by microorganisms susceptible to methicillin. On the other hand, implant success rate was 47% in 19 patients infected by microorganisms resistant to methicillin. Lim et al reported that the failure rate of infection treatment was 33% in 24 patients with periprosthetic hip infection caused by methicillin resistant microorganisms but, was 0% in 13 patients infected by non- methicillin resistant microorganisms. The results showed that difference was present between two groups according to pathogens of deep infection. Similarly, Salgado et al. [6] suggested that treatment success rate of infection caused by methicillin resistant microorganisms was low. The results of this study were comparable to those of previous studies with unfavorable clinical outcome and low treatment rate of infection caused by methicillin resistant microorganisms.

Several previous studies performed infection treatment procedure only, instead of revision hip arthroplasty, for patients infected by methicillin resistant microorganisms, and involved subjects under observation without undergoing any surgical treatment. In contrast, this study comprised subjects completed with 2-stage reimplantation by performing both infection treatment and revision hip arthroplasty. No difference was found between two groups with age, gender, BMI, and presence of diabetes. In addition, two groups had no difference in the cause and type of primary hip arthroplasty, and this was comparable to the outcome of previous studies [5-8,20].

However, the duration of both intravenous and oral antibiotic use was longer in the resistant group than non-resistant group of this study. The result of this study aligned with that of Salgado et al. [6] who addressed that the period of hospital stay was longer in patients infected by MRSA. The outcome is thought to be related with economic loss of patients infected by methicillin resistant microorganisms. Among 25 patients completed with 2-stage reimplantation due to periprosthetic hip infection, the recurrence rate of infection was 23% in the resistant group, unlike 0% in the non-resistant group. The results of this study were comparable to those of Lim et al. [20] who reported that the recurrence rate of infection was 33% in patients infected with by methicillin resistant microorganisms but was 0% in patients infected by microorganisms susceptible to methicillin. A relatively lower recurrence rate of this study is anticipated to be attributable to inclusion of subjects who underwent 2-stage reimplantation.

In addition to recurrence rate, HHS was statistically significantly lower in the resistant group than that of non-resistant group. Patients with deep infection caused by methicillin resistant microorganisms had unfavorable outcomes in clinical symptoms and social functions such as pain and range of motion.

In the comparison of hematological and clinical results, no difference was found in 10 succeed patients and 3 recurrent patients in the resistant group. However, bone cement beads were not used and only acetabular cup and artificial femoral head were treated excluding femoral stem in all 3 patients with recurrent infection. Although there was no statistical difference, the use of expanded adaptability is anticipated to be beneficial in determining extent of surgery during surgical treatment of infection. But, additional studies are thought to be crucial.

Limitations of this study were a retrospective analysis of patient-control groups and the relatively small sample size. The advantage of this study was involving subjects who underwent 2-stage reimplantation, a uniform surgical method, unlike previous studies on periprosthetic hip infection treated with different surgical methods.

In summary, poorer clinical outcomes and higher recurrence rate were observed in periprosthetic hip infection caused by methicillin resistant microorganisms than non-methicillin resistant microorganisms. Periprosthetic hip infection caused by methicillin resistant microorganisms requires cautious surgical treatment, and thorough infection control is crucial.

## References

1. Garvin KL, Hanssen AD (1995) Infection after total hip arthroplasty. Past, present, and future. *J Bone Joint Surg Am* 77: 1576-1588.
2. Yamamoto K (2009) Cement spacer loaded with antibiotics for infected implants of the hip joint. *J Arthroplasty* 24: 83-89.
3. Patel A (2008) Methicillin-resistant *Staphylococcus aureus* in orthopaedic surgery. *J Bone Joint Surg Br* 90: 1401-1406.
4. Garvin KL, Hinrichs SH, Urban JA (1999) Emerging antibiotic-resistant bacteria. Their treatment in total joint arthroplasty. *Clin Orthop Relat Res* 369: 110-123.
5. Kilgus DJ, Howe DJ, Strang A (2002) Results of periprosthetic hip and knee infections caused by resistant bacteria. *Clin Orthop Relat Res* 404: 116-124.
6. Salgado CD (2007) Higher risk of failure of methicillin-resistant *Staphylococcus aureus* prosthetic joint infections. *Clin Orthop Relat Res* 461: 48-53.
7. Volin SJ, Hinrichs SH, Garvin KL (2004) Two-stage reimplantation of total joint infections: a comparison of resistant and non-resistant organisms. *Clin Orthop Relat Res* 427: 94-100.
8. Sanchez-Sotelo J (2009) Midterm to long-term followup of staged reimplantation for infected hip arthroplasty. *Clin Orthop Relat Res* 467: 219-224.
9. Salimi M (2013) A role for IL-25 and IL-33-driven type-2 innate lymphoid cells in atopic dermatitis. *J Exp Med* 210: 2939-2950.
10. Chung HJ (2008) Epidemiological characteristics of methicillin-resistant *Staphylococcus aureus* isolates from children with eczematous atopic dermatitis lesions. *J Clin Microbiol* 46: 991-995.
11. Tachibana M (2002) G9a histone methyltransferase plays a dominant role in euchromatic histone H3 lysine 9 methylation and is essential for early embryogenesis. *Genes Dev* 16: 1779-1791.
12. Zhang T ((2016) G9a/GLP Complex Maintains Imprinted DNA Methylation in Embryonic Stem Cells. *Cell Rep* 15: 77-85.
13. Zimmerli W, Trampuz A, Ochsner PE (2004) Prosthetic-joint infections. *N Engl J Med* 351: 1645-1654.
14. Feldman DS (1995) The role of intraoperative frozen sections in revision total joint arthroplasty. *J Bone Joint Surg Am* 77: 1807-1813.
15. Hanssen AD, Spangehl MJ (2004) Treatment of the infected hip replacement. *Clin Orthop Relat Res* 420: 63-71.
16. Lieberman JR (1994) Treatment of the infected total hip arthroplasty with a two-stage reimplantation protocol. *Clin Orthop Relat Res* 301: 205-212.
17. McDonald DJ, Fitzgerald RH, Ilstrup Jr DM (1989) Two-stage reconstruction of a total hip arthroplasty because of infection. *J Bone Joint Surg Am* 71: 828-834.
18. Nestor BJ (1994) The use of porous prostheses in delayed reconstruction of total hip replacements that have failed because of infection. *J Bone Joint Surg Am* 76: 349-359.
19. Younger AS, Duncan CP, Masri BA (1998) Treatment of infection associated with segmental bone loss in the proximal part of the femur in two stages with use of an antibiotic-loaded interval prosthesis. *J Bone Joint Surg Am* 80: 60-69.
20. Lim SJ (2009) Treatment of periprosthetic hip infection caused by resistant microorganisms using 2-stage reimplantation protocol. *J Arthroplasty* 24: 1264-1269.