

## A Case of Drug-Induced Hypersensitivity Syndrome with Recurrent Varicella

Sakiko Shimura<sup>\*</sup>, Makiko Ueno, Kazuaki Ito, Keisuke Kobayashi and Kazumoto Katagiri

Department of Dermatology, Dokkyo Medical University, Koshigaya Hospital, Japan

<sup>\*</sup>Corresponding author: Sakiko Shimura, Department of Dermatology, Dokkyo Medical University, Koshigaya Hospital, 2-1-50, Minami-Koshigaya, Koshigaya, Saitama 343-8555, Japan, Tel: +81-48-965-1111; Fax: +81-48-965-8927; E-mail: [stomatsu@juntendo.ac.jp](mailto:stomatsu@juntendo.ac.jp)

Received date: November 24, 2016; Accepted date: December 09, 2016; Published date: December 12, 2016

Copyright: © 2016 Shimura S, et al. This is an open-access article distributed under the terms of the Creative Commons Attribution License, which permits unrestricted use, distribution, and reproduction in any medium, provided the original author and source are credited.

### Abstract

Drug-induced hypersensitivity syndrome (DIHS) is attributed to immunodeficiency caused by certain drugs. Herein, we report a patient with DIHS due to recurrent varicella caused by reactivation of the varicella-zoster virus (VZV). The patient was a 39-year-old woman, who had started oral carbamazepine treatment for trigeminal neuralgia eight weeks before developing a high-grade fever and dark red plaques appearing over the entire body. She was diagnosed as having DIHS with liver dysfunction, atypical lymphocytes in peripheral blood, and lymphadenopathy. Oral administration of prednisolone at 50 mg/day was started and then tapered to 40 mg/day 13 days after the onset. Vesicles and blisters with bleeding in part subsequently appeared sporadically on the trunk and limbs. At that time, anti-VZV-IgM and VZV IgG antibody titers exceeded the normal ranges, and the patient was thus considered to have recurrent varicella. Mild symptoms including scattered blisters disappeared without treatment. This case suggested that VZV is one of the earliest viruses to reactivate in the development of DIHS.

**Keywords:** Drug-induced hypersensitivity syndrome; Early reactivation of viruses; Recurrent varicella; Herpes zoster

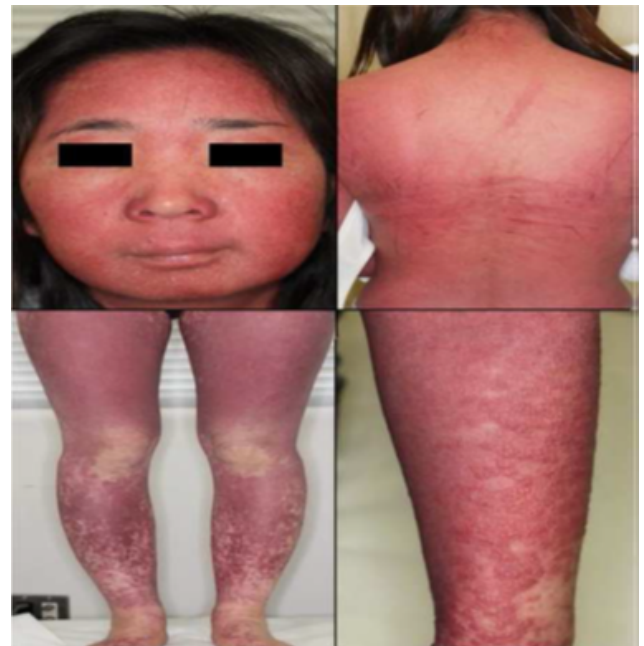
### Introduction

Drug-induced hypersensitivity syndrome (DIHS) and drug reaction with eosinophilia and systemic symptoms (DRESS) are considered to be closely related to reactivation of various herpes viruses including human herpesvirus 6 (HHV-6) and the development of a severe systemic hypersensitivity reaction [1,2]. We herein report a very rare case with DIHS associated with recurrent varicella secondary to reactivation of the varicella-zoster virus (VZV).

### Case Report

The patient was a 39-year-old woman, who had been taking sodium valproate as epilepsy treatment for several years. She was started on oral carbamazepine 100 mg/day for trigeminal neuralgia eight weeks before developing a high-grade fever and blisters on her forearms. The eruption spread, becoming generalized, and she was referred to our hospital on the fifth day of illness.

Dark red spots with patchy infiltration were observed over the entire body, along with dense clusters of blisters on the dark red spots on the upper limbs (Figure 1), diffuse erythema with purpura on the lower limbs, bleeding of the buccal mucosa, and enlarged cervical lymph nodes. Laboratory tests revealed hepatic dysfunction (AST 397 U/L, ALT 666 U/L, ALP 512 U/L), an increased white blood cell count (14200/ $\mu$ l) with 3% atypical lymphocytes, elevated C-reactive protein (3.18 mg/dl), and a normal immunoglobulin (Ig) G level (990 mg/dl). On the fifth day of illness, histopathological examination of the skin revealed lymphocytic infiltration and vacuolar degeneration at the epidermal-dermal junction, as well as mild lymphocytic infiltration and edema in the superficial dermis.



**Figure 1:** Clinical pictures of patient on 5<sup>th</sup> day of illness. Dark red spots or papules with patchy infiltration are seen over the entire body. The perioral region has scales, the back shows diffuse erythema with numerous scratch-like marks, and the lower limbs have a purpuric rash. Blister-like eruptions and blisters are seen on the extremities.

She had symptoms including liver dysfunction, atypical lymphocytes in peripheral blood, high-grade fever, lymphadenopathy along with typical eruption after cessation of carbamazepine as specific

medications for DIHS, and was ultimately diagnosed as having atypical DIHS because there was no detection of reactivation of HHV-6 according to the diagnostic criteria [1,3]. Oral administration of prednisolone (PSL) at 50 mg (1 mg/kg)/day was started immediately, resulting in fever reduction within a few days and gradual resolution of the skin eruption. However, new blood blisters and blisters developed on her trunk and extremities on the 19<sup>th</sup> day of illness (Figure 2), suggesting recurrence of DIHS. After additional administration of PSL for 10 days, the blisters crusted, and finally disappeared within 10 days with no relapse of liver dysfunction without treatment. The PSL was

then tapered, and discontinued three months later. We measured anti-VZV antibodies on the 24<sup>th</sup> day of illness, suspecting the eruption to be varicella. The anti-VZV IgG titer exceeded the normal ranges, and anti-VZV IgM was also positive. Thus, the scattered blisters were diagnosed as recurrent varicella, because she had not been in contact with any patients with varicella, and had no zosteriform lesions although she did have a past history of varicella, which was confirmed by her mother. The titers of anti-HHV-6 IgG were similar on the 9<sup>th</sup> and 35<sup>th</sup> days of illness, indicating that HHV-6 virus had not been reactivated in this case (Table 1).

DIHS criteria	
1	Maculopapular rash developing >3 weeks after starting with a limited number of drugs
2	Prolonged clinical symptoms 2 weeks after discontinuation of the causative drug
3	Fever (38 degrees)
4	Liver abnormalities* (alanine aminotransferase >100 U/L)
5	Leukocyte abnormalities (at least one present)
	a. Leukocytosis (>11 times 10 <sup>9</sup> /L)
	b. Atypical lymphocytosis (>5%)
	c. Eosinophilia (>1.5 times 10 <sup>9</sup> /L)
6	Lymphadenopathy
7	Huma herpesvirus 6 reactivation

**Table 1:** Diagnostic criteria for drug-induced hypersensitivity syndrome (DIHS) established by a Japanese consensus group.

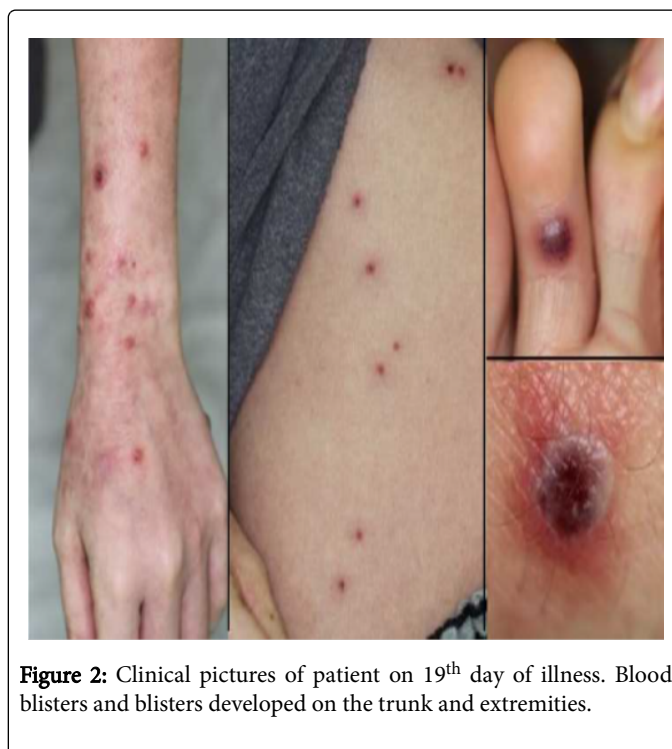The diagnosis is confirmed by the presence of the seven criteria above (typical DIHS) or of the five (1-5) (atypical DIHS). This can be replaced by other organ involvement, such as renal involvement [3].

## Discussion

DIHS is considered to arise from immunodeficiency caused by long-term administrations of certain drugs; after these drug are discontinued, immunocompetent cells rapidly recover and are activated, thereby inducing strong immune responses and leading to reactivation of latent viruses such as HHV-6 and cytomegalovirus, ultimately causing organ damage [4]. The most common causes are anticonvulsants, among which carbamazepine is the most frequent. Carbamazepine is known to inhibit the differentiation of B cells, which might have effects on the mechanism of DIHS onset [5].

Our patient was diagnosed as having atypical DIHS due to carbamazepine based on the diagnostic criteria, and also diagnosed with recurrent varicella based on clinical and serological findings. During immunodeficiency associated with acquired immunodeficiency syndrome [6] or biological products [7], reactivation of VZV may manifest as varicella, which is referred to as recurrent varicella. Only one recurrence of varicella in a patient with DIHS has been reported [8]. In contrast to our patient, the previously reported case showed reactivation of HHV-6, but, like our patient, experienced early recurrence of varicella (on the 17<sup>th</sup> day of illness) with mild clinical symptoms. Herpes zoster, another form of reactivation of VZV, was also reportedly observed 2-5 months after developing DIHS as an immune reconstitution syndrome when PSL

was tapered or discontinued [9]; this occurred 3 years after the onset in one patient [2].



**Figure 2:** Clinical pictures of patient on 19<sup>th</sup> day of illness. Blood blisters and blisters developed on the trunk and extremities.

Similarly, herpes zoster described in association with DIHS also showed mild cutaneous manifestations without complications. Reactivation of VZV, which appears as recurrent varicella or herpes zoster, might be overlooked due to very mild symptoms in some cases. Kano et al. also stated that significant increases in anti-VZV IgG antibody titers were detected in 2 of their 11 patients with DIHS/DRESS who had no clinical symptoms as unpublished observations [9]. Thus, reactivation of VZV could occur in the early phase and long after the onset of DIHS, as seen in bone marrow transplantation cases with a latency period ranging from days to several years after the transplantation procedure.

## Conclusion

We report a second case of DIHS associated with recurrent varicella secondary to reactivation of the VZV, which had mild clinical symptoms. It is well known that DIHS is associated with the cascade of reactivation initiated by herpesviridae such as HHV-6, cytomegalovirus and VZV. This case suggested that VZV is one of the earliest viruses to reactivate in the development of DIHS. Clinicians should be careful not to miss early reactivation of VZV in DIHS from the beginning of patient management, even when their symptoms have thus far been mild.

## References:

1. Shiohara T, Inaoka M, Kano Y (2006) Drug-induced hypersensitivity syndrome (DIHS): a reaction induced by a complex interplay among herpesviruses and antiviral and antidrug immune responses. *Allergol Int* 55: 1-8.
2. Kano Y, Tohyama M, Aihara M, Matsukura S, Watanabe H, et al. (2015) Sequelae in 145 patients with drug-induced hypersensitivity syndrome/drug reaction with eosinophilia and systemic symptoms: survey conducted by the Asian Research Committee on Severe Cutaneous Adverse Reactions (ASCAR). *J Dermatol* 42: 276-282.
3. Toyama M, Hashimoto K (2011) New aspects of drug-induced hypersensitivity syndrome. *JDE* 38: 222-228.
4. Sakuma K, Kano Y, Shiohara T (2006) Herpes zoster during the course of the drug-induced hypersensitivity syndrome. *JPN J Clin Dermatol* 60: 920-923.
5. Prussick R, Shear NH (1996) Dapsone hypersensitivity syndrome. *J Am Acad Dermatol* 35: 346-349.
6. Shibuya H, Kanai T, Oyake S (1995) Recurrent varicella observed in an AIDS patient. *JPN J Clin Dermatol* 49: 787-790.
7. Mizugaki N, Takahashi H, Nakahashi K, Kagaya M, Takahashi H (2014) Recurrent varicella developed in a patient under treatment with adalimumab. *Pract Dermatol* 36: 417-420.
8. Tsutsumi R, Adachi K, Yoshida Y, Yamamoto O (2015) Drug-induced hypersensitivity syndrome in association with varicella. *Acta Derm Venereol* 95: 503-504.
9. Kano Y, Horie C, Inaoka M, Tadashi I, Mizukawa Y, et al. (2012) Herpes zoster in patients with drug-induced hypersensitivity syndrome/DRESS. *Acta Derm Venereol* 92: 206-207.