

# Fomepizole and Concomitant Hemodialysis Regimen are Effective in Overdue Methanol Poisoning

Sinan Yavuz<sup>1\*</sup>, Selman Kesici<sup>1</sup>, Gorkem Abdikan<sup>2</sup>, Nesrin Tas<sup>3</sup>, Ali Duzova<sup>3</sup>, Benan Bayrakci<sup>1</sup>

<sup>1</sup>Department of Pediatric Critical Care Medicine, Life Support Practice and Research Center, Hacettepe University, Ankara, Turkey;

<sup>2</sup>Department of Pediatric, Pediatric Intensive Care Unit, Hacettepe University, İhsan Doğramacı Children's Hospital, Ankara, Turkey; <sup>3</sup>Department of Pediatric Nephrology Medicine, İhsan Doğramacı Children's Hospital, Hacettepe University, Ankara, Turkey

## ABSTRACT

Methanol, also known as wood alcohol, commonly used in laboratories and industry, can cause severe metabolic acidosis and visual disturbances in case of accidental or suicidal intake. We reported a 17-year-old male presented with blurred vision, which ingested homemade drink 36 hours before his admission to the hospital. In physical examination bilateral mydriasis and horizontal nystagmus were present and his optic disc boundaries were indistinct. Severe metabolic acidosis was detected in blood gas analysis and bicarbonate infusion, fomepizole and hemodialysis were applied. Eventually acidosis and blurred vision completely recovered and patient was discharged on the fourth day of admission. In case of methanol intoxication prompt treatment with fomepizole and hemodialysis should be considered to prevent irreversible complications.

**Keywords:** Methanol; Bilateral mydriasis; Nystagmus; Fomepizole; Hemodialysis

## INTRODUCTION

Methanol (CH<sub>3</sub>OH) is also known as wood alcohol and its intake may cause severe metabolic acidosis and visual impairments, which can be permanent despite aggressive treatment [1]. It is used in as a synthetic precursor in laboratories and as a solvent in industry. It is used for some plastic materials, synthetic textile products and paints as a precursor. Methanol intoxication is most often caused by the intake of methanol containing commercial products and consuming alcoholic beverages containing these products. Intentional use may also occur when desperate alcoholics who could not reach ethanol (C<sub>2</sub>H<sub>5</sub>OH) containing beverages, either don't know the substance is toxic or know it is toxic [2]. In this case report, we will present a methanol poisoning case presenting with visual complaints.

## CASE PRESENTATION

A 17-year-old male patient was admitted to the Pediatric Intensive Care Unit with the complaint of blurred vision. It was

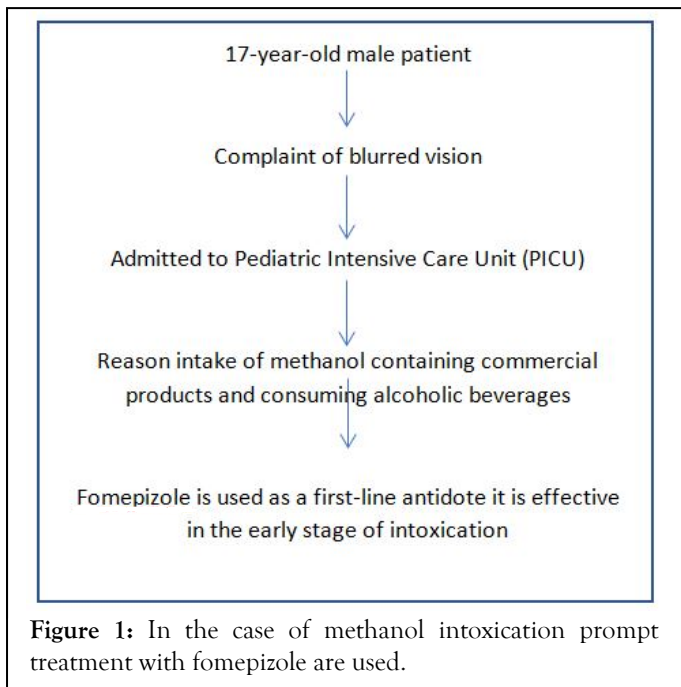
learned that he drank 200 ml of homemade drink two days ago and spent the night sleeping. In physical examination, bilateral mydriasis and nystagmus with normal vital signs were recorded. His visual acuity and optic disc margins were indistinct. Blood gas analysis revealed severe metabolic acidosis (pH 7.17, CHCO<sub>3</sub> 11.2 mmol/L, anion gap 15 mmol/L). One-session emergency hemodialysis was started because of ongoing acidosis despite bicarbonate infusion. After hemodialysis, 15 mg/kg/dose fomepizole was administered, followed by a dose of 10 mg/kg 12 hours later. Venous blood gas was found as (pH 7.38, HCO<sub>3</sub> 23.4 mmol/L, anion gap 10 mmol/L) at the fourth hour of the follow-up. Acidosis and blurred vision were improved after hemodialysis. Eye drops including coenzyme Q and vitamin E TPGS (D- $\alpha$ -tocopheryl polyethylene glycol 1000 succinate) were started with the diagnosis of optic neuritis due to methanol intoxication. The patient's vision was completely recovered and he was discharged on the fourth day (Figure 1).

**Correspondence to:** Sinan Yavuz, Department of Pediatric Critical Care Medicine, Life Support Practice and Research Center, Hacettepe University, Ankara, Turkey, E-mail: sinan2438@hotmail.com

**Received:** 09-Feb-2022, Manuscript No. JCT-21-14778; **Editor assigned:** 11-Feb-2022, PreQC No. JCT-21-14778 (PQ); **Reviewed:** 25-Feb-2022, QC No. JCT-21-14778; **Revised:** 04-Mar-2022, Manuscript No. JCT-21-14778 (R); **Published:** 11-Mar-2022, DOI: 10.35248/2161-0495-22.S21.005.

**Citation:** Yavuz S, Kesici S, Abdikan G, Tas N, Duzova A, Bayrakci B (2022) Fomepizole and Concomitant Hemodialysis Regimen are Effective in Overdue Methanol Poisoning. J Clin Toxicol. S21:005.

**Copyright:** © 2022 Yavuz S, et al. This is an open-access article distributed under the terms of the Creative Commons Attribution License, which permits unrestricted use, distribution, and reproduction in any medium, provided the original author and source are credited.



## RESULTS AND DISCUSSION

Methanol intoxication mostly occurs due to oral intake while dermal absorption and inhalation can also cause intoxication. Methanol is rapidly absorbed from the gastrointestinal tract. The volume of distribution after absorption is similar to that of body water, reaches a peak concentration in the blood within 30-40 minutes. Its half-life is 14-30 hours when taken alone, 43-96 hours when taken with ethanol [3]. Since the price of methanol is cheaper than ethanol, it has caused an outbreak of poisoning even in Libya and Kenya, where alcohol consumption rates are low [4]. Regardless of the price of ethanol, bulk methanol can be bought cheaper, which has led to outbreaks in countries such as Estonia, the Czech Republic, Finland, and Poland.

Methanol toxicity has been extensively studied since it is considered as a serious neurotoxin in humans. It is well known that the nervous system and especially the visual system are vulnerable to methanol poisoning [5]. Alcohol is converted into formate by Alcohol Dehydrogenase (ADH) and Aldehyde Dehydrogenase Enzymes [6]. Retinal and optic nerve neurons are particularly sensitive to the harmful effects of formate due to the difference in their mitochondria density [7]. An oral intake of 3.16-11.85 g/person of pure methanol could cause blindness and onset of optic neuritis and blindness has been demonstrated at a concentration of 228.5-1103 mg/ml for 12-hour exposure [8]. Basal ganglia, especially putamen and subcortical white matter are also more sensitive to formate toxicity. Our case had already the complaint of blurred vision.

As formate accumulates, the most characteristic and often the most obvious symptom is vision impairment. This visual finding can range from mild impairment in visual acuity to complete blindness. In the survivors, visual findings may be permanent or recover partially or completely [2]. When enough methanols are metabolized severe metabolic acidosis and secondary hyperpnea

may be seen. Our patient had severe metabolic acidosis on admission. Apart from the initial inebriation, CNS findings such as headache, confusion and stupor; in severe cases, coma, brain edema, brain damage, and herniation may be seen. Severe heart failure and shock have also been reported.

Since methanol is absorbed very quickly, decontamination with gastric lavage or activated charcoal is not recommended. Sodium bicarbonate is recommended to correct severe acidosis [9]. An antidote to block ADH metabolism due to severe morbidity and potential mortality should be started quickly. Before fomepizole was available, ethanol was routinely used to treat toxic methanol intake. Today, fomepizole is used as a first-line antidote in North America and Western European countries due to its effectiveness and reliability [10]. Fomepizole and ethanol are more effective in the early stage of intoxication before toxic metabolites reach a significant level. There are several reasons why fomepizole is preferred as an antidote rather than ethanol. Fomepizole is more potent with longer duration of action in ADH inhibition. The administration regimen is easy and there is no need to monitor fomepizole concentration in the blood, it is generally well tolerated. In oral or intravenous ethanol treatment, blood ethanol concentration monitoring and frequent dose adjustments are required. In our case we started immediately sodium bicarbonate infusion and fomepizole treatment.

Hemodialysis (HD) is indicated in case of significant metabolic acidosis, visual abnormality, vital signs deteriorated despite intensive supportive treatment, renal failure or electrolyte imbalance that does not respond to conventional treatment [11]. Methanol molecular size is 0.45 nm and formate molecular size is 0.43 nm and they can be easily removed with HD [12]. These procedures contribute to clinical recovery with direct removal of toxin, correction of acidosis, or both. Since the inhibition of ADH significantly increases the half-life of methanol by an average of 54 hours, the removal of methanol with HD shortens the treatment time [13].

## CONCLUSION

Since our patient had blurred vision and severe metabolic acidosis, hemodialysis was started immediately. As a conclusion we would like to draw attention to the effectiveness of fomepizole and concomitant HD for reversing the visual complications of methanol even if applied during the late stages of the intoxication.

## REFERENCES

- Suit PF, Estes ML. Methanol intoxication: Clinical features and differential diagnosis. *Cleve Clin J Med.* 1990;57(5):464-471.
- Kruse JA. Methanol and ethylene glycol intoxication. *Crit Care Clin.* 2012;28(4):661-711.
- Kraut JA, Kurtz I. Toxic alcohol ingestions: Clinical features, diagnosis, and management. *Clin J Am Soc Nephrol.* 2008;3(1):208-225.
- Rostrup M, Edwards JK, Abukalish M, Ezzabi M, Some D, Ritter H, et al. The methanol poisoning outbreaks in Libya 2013 and Kenya 2014. *PLoS One.* 2016;11(3):e0152676.

5. Meyer RJ, Beard ME, Ardagh MW, Henderson S. Methanol poisoning. *N Z Med J*. 2000;113(1102):11.
6. McLean DR, Jacobs H, Mielke BW. Methanol poisoning: A clinical and pathological study. *Ann Neurol*. 1980;8(2):161-167.
7. Sharpe JA, Hostovsky M, Bilbao JM, Rewcastle NB. Methanol optic neuropathy: A histopathological study. *Neurology*. 1982;32(10):1093-1100.
8. Moon CS. Estimations of the lethal and exposure doses for representative methanol symptoms in humans. *Ann Occup Environ Med*. 2017;29(1):1-6.
9. Rietjens SJ, De Lange DW, Meulenbelt J. Ethylene glycol or methanol intoxication: Which antidote should be used, fomepizole or ethanol. *Neth J Med*. 2014;72(2):73-79.
10. Mégarbane B. Treatment of patients with ethylene glycol or methanol poisoning: Focus on fomepizole. *Open Access Emerg Med*. 2010;2:67.
11. Barceloux DG, Randall Bond G, Krenzelok EP, Cooper H, Allister Vale J. American Academy of Clinical Toxicology practice guidelines on the treatment of methanol poisoning. *J Toxicol Clin Toxicol*. 2002;40(4):415-446.
12. Sharma N, Sharma N, Srinivasan P, Kumar S, Rayappan JB, Kailasam K. Heptazine based organic framework as a chemiresistive sensor for ammonia detection at room temperature. *J Mat Chem*. 2018;6(38):18389-18395.
13. Roberts DM, Yates C, Megarbane B, Winchester JF, Maclaren R, Gosselin S, et al. Recommendations for the role of extracorporeal treatments in the management of acute methanol poisoning: A systematic review and consensus statement. *Crit Care Med*. 2015;43(2):461-472.